

## CASE REPORT

# Effectiveness of Lamivudine in Treatment of Acute Recurrent Hepatitis B After Liver Transplantation

J. IGNACIO HERRERO, MD, JORGE QUIROGA, MD, BRUNO SANGRO, MD, IOSU SOLA, MD, JOSE IGNACIO RIEZU-BOJ, MD, FERNANDO PARDO, MD, and JESUS PRIETO, MD

**KEY WORDS:** lamivudine; hepatitis B; liver transplantation.

In spite of long-term prophylaxis with hepatitis B immune globulin (HBIG), recurrence of hepatitis B virus (HBV) infection in the graft constitutes the leading cause of morbidity and mortality among patients undergoing liver transplantation (LT) due to HBV-induced liver cirrhosis (1). In many of these patients accelerated HBV replication overcomes the protective effect of HBIG (2).

Interferon therapy, which is partially effective against HBV in immunocompetent patients (3), is of limited value in post-LT HBV graft infection (4). Lamivudine, a nucleoside analog that inhibits the reverse transcriptase activity of HBV, has shown promising results in HBV infection in both immunocompetent (5) and HIV-immunosuppressed patients (6). Significant improvements in liver histology have been demonstrated after one year treatment with lamivudine in immunocompetent patients (7). Indeed, administration of lamivudine before and after LT has also been effective in preventing hepatitis B recurrence after LT (8), and this drug lacks the serious side effects found with other nucleoside analogues (9).

We report on a LT patient in whom lamivudine was an effective therapy for acute recurrent HBV hepatitis.

## CASE REPORT

A 48-year-old white man received a liver graft in March 1995 because of HBV liver cirrhosis. Preoperatively, hepatitis B surface antigen (HBsAg) and antibodies to the core and e antigens (anti-HBc and anti-HBe, respectively) were detectable in the serum, but hepatitis B e antigen (HBeAg) and HBV DNA (dot blot) were not detectable. He received high-dose anti-HBs immunoglobulin, according to Samuel et al (10) and standard immunosuppression with cyclosporine, azathioprine, and prednisone.

Intraoperative and postoperative courses were unremarkable, liver function tests became normal within two weeks after LT, and serum HBsAg became undetectable. Five months after transplantation he developed graft dysfunction secondary to HBV infection. Liver function tests revealed severe cytolysis and progressively declining hepatic function (Figure 1). Biliary and vascular complications, rejection, and other viral infections were ruled out. Liver biopsy showed lobular hepatitis with marked cholestasis and the presence of HBsAg and HBeAg in 100% and 60% of hepatocytes, respectively (Figure 2). Serum HBsAg became detectable and serum HBV DNA levels, as determined by the Digene Hybrid Capture assay (Digene Diagnostics, Beltsville, Maryland) were greater than 2000 pg/ml, demonstrating accelerated viral replication. Famciclovir (500 mg every 8 hr) was initiated; HBIG, azathioprine, and prednisone were discontinued; and the cyclosporine dose was reduced to maintain blood trough levels below 100 ng/ml.

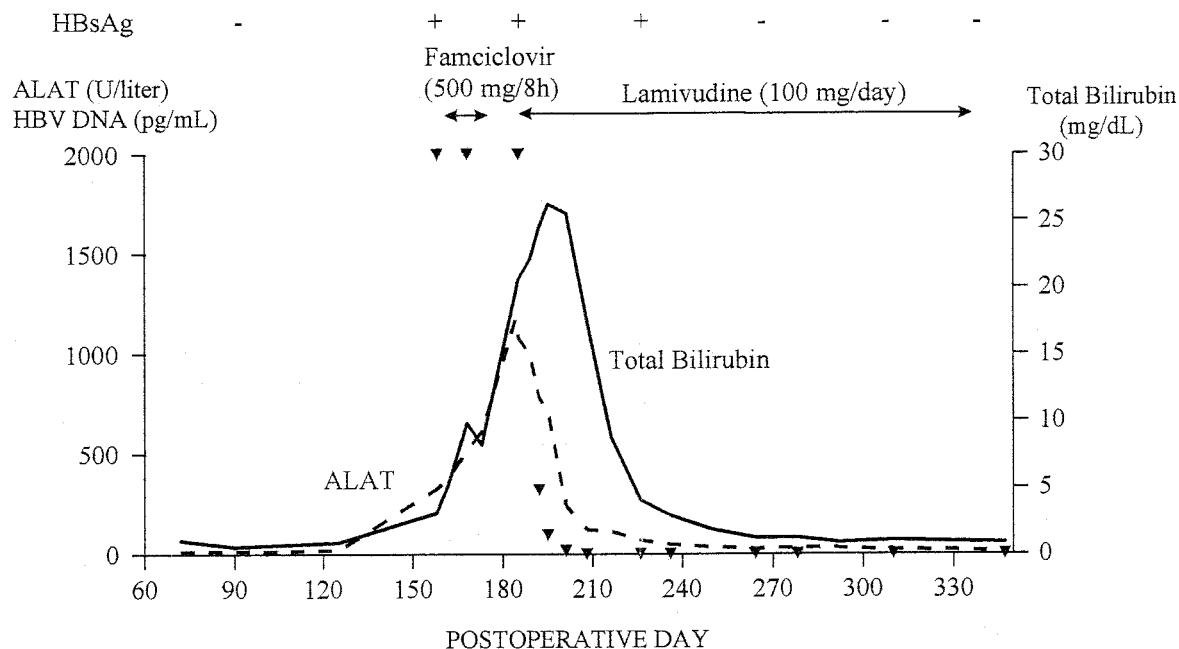
Despite this treatment, liver function tests continued to worsen, and the patient was switched from famciclovir to oral lamivudine (100 mg/day). Shortly thereafter, liver function improved and aminotransferase levels rapidly diminished, reaching normal levels three months after lamivudine was initiated. Serum HBV DNA levels decreased rapidly and became negative within the first month of lamivudine therapy. Serum HBsAg remained positive one month after initiation of lamivudine, but became undetectable two months later. Aminotransferase values remain within normal limits and HBV DNA and HBsAg have remained negative for two years. Six months after starting lamivudine,

---

Manuscript received October 27, 1997; revised manuscript received January 29, 1998; accepted February 5, 1998.

From the Liver Unit, Clínica Universitaria de Navarra, Pamplona, Spain.

Address for reprint requests: Dr. J. Ignacio Herrero, Liver Unit, Clínica Universitaria de Navarra, Avda. Pío XII, s/n. 31008 Pamplona, Spain.



**Fig 1.** Evolution of serum transaminase (dotted line), bilirubin (solid line), and hepatitis B virus DNA levels (arrowheads) before and after lamivudine therapy.

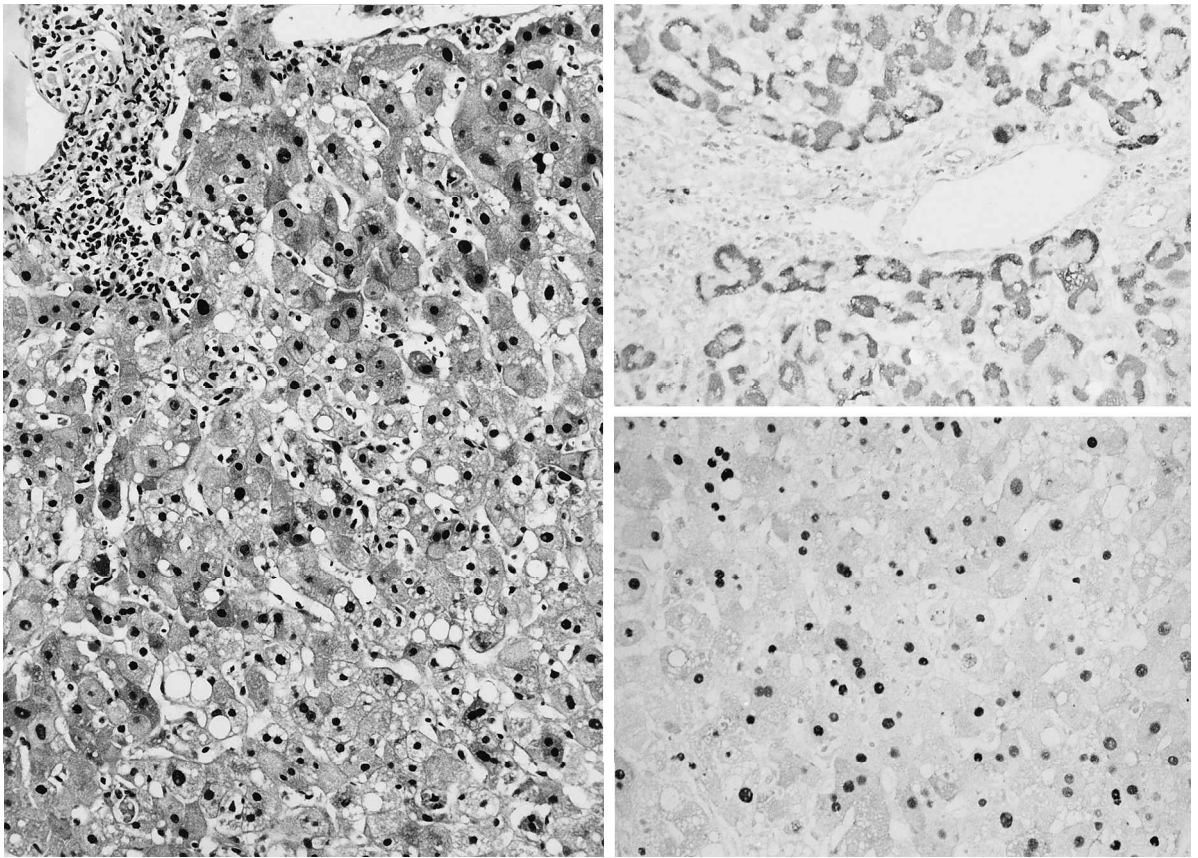
the patient was both HBsAg- and anti-HBs-negative, becoming anti-HBs-positive six months later; currently, his serum anti-HBs concentration is 188 mIU/ml. A liver biopsy performed five months after initiating lamivudine therapy showed a significant improvement, with only mild to moderate lymphocyte inflammatory activity. Immunostaining against HBsAg and HBcAg were both negative. This histological improvement was confirmed in a second liver biopsy performed after one year of lamivudine therapy. No adverse event related to this drug was recorded. Currently, the patient is still on lamivudine and immunosuppressive therapy includes cyclosporine, maintaining trough levels at a range of 50–75 ng/ml.

## DISCUSSION

Passive immunoprophylaxis with HBIG reduces but does not eliminate the risk of recurrent HBV infection after LT (2). The natural history of HBV reinfection after LT is usually accelerated because of immunosuppression. Moreover, some of the patients develop fibrosing cholestatic hepatitis, a clinicopathological syndrome characterized by cholestasis, severe fibrosis, and marked expression of HBV antigens in hepatocytes, which leads to a rapidly progressive liver failure (11) due to a direct cytopathic effect. There is no effective therapy for this condition. The high viral replication secondary to immunosuppression makes interferon therapy of limited efficacy (4). Adenine arabinoside monophosphate has shown only a partial and transient effectiveness (12) and may cause neu-

rotoxicity (13). Long-term therapy with ganciclovir has been shown to be partially effective in a pilot study (14). Although this treatment caused significantly reduced HBV DNA in several patients, ALT values remained increased in most of them and serum HBeAg and liver HBsAg remained detectable in all the patients, demonstrating the inability of ganciclovir to fully inhibit HBV replication. Furthermore, as its effect over HBV DNA was transient, ganciclovir had to be administered indefinitely. The need for intravenous administration precludes the long-term use of this drug. Recent reports on famciclovir, the oral form of penciclovir, in the treatment of post-LT HBV infection has shown only partial activity (15).

The patient reported in this paper had a recurrent HBV infection of the liver graft presenting as a severe acute hepatitis, with remarkably high viral replication and progressive worsening of liver function. Although immunosuppression was markedly reduced and famciclovir was started, liver function deteriorated further and viral replication remained extremely high. In this setting, lamivudine dramatically changed the clinical picture. The patient began to feel better, aminotransferase and bilirubin values immediately decreased, and viral replication was fully inhibited, as demonstrated by the abrupt fall in serum HBV DNA levels, the rapid loss of serum HBsAg, the persistent



**Fig 2.** Histopathologic appearance of posttransplant hepatitis B at the time of its recurrence (left) and immunostaining against HBsAg (upper right) and HBcAg (lower right).

histological improvement, and the loss of HBsAg and HBcAg in liver tissue.

The effectiveness of lamivudine in this case and in other preliminary trials warrants further investigation in the transplant setting and in nontransplant HBV infection. Preliminary results from a multicenter trial of lamivudine after LT have shown promising results (16), but several points, such as duration of therapy, need to be clarified because short-term treatment (12 weeks) has only a transient effect on HBV DNA levels (5). Finally, this drug may be useful not only in chronic infection but also in acute hepatitis B, as demonstrated by the dramatic improvement of the patient reported here.

## REFERENCES

1. Wright TL: Liver transplantation in patients with chronic hepatitis B and hepatitis C. *In* Transplantation of the Liver, 2nd ed. WC Maddrey, MF Sorrell (eds.). Norwalk, Appleton & Lange, 1995, pp 477-501
2. Samuel D, Muller R, Alexander G, Fassati L, Ducot B, Benhamou JP, Bismuth H: Liver transplantation in European patients with the hepatitis B surface antigen. *N Engl J Med* 329:1842-1847, 1993
3. Perrillo RP, Schiff ER, Davis GL, Bodenheimer HC, Lindsay K, Payne J, Dienstag JL, O'Brien C, Tamburro C, Jacobson MI, Sampliner R, Feit D, Lefkowitz J, Kuhns M, Meschievitz C, Sanghvi B, Albrecht J, Gibas A, Hepatitis Interventional Therapy Group: A randomized, controlled trial of interferon alfa-2b alone after prednisone withdrawal for the treatment of chronic hepatitis B. *N Engl J Med* 323:295-301, 1990
4. Terrault NA, Combs Holland C, Ferrell L, Hahn JA, Lake JR, Roberts JP, Ascher NL, Wright TL: Interferon alfa for recurrent hepatitis B infection after liver transplantation. *Liver Transplant Surg* 2:132-138, 1996
5. Dienstag JL, Perrillo RP, Schiff ER, Bartholomew M, Vicary C, Rubin M: A preliminary trial of lamivudine for chronic hepatitis B infection. *N Engl J Med* 333:1657-1661, 1995
6. Lai CL, Liaw YF, Leung NWY, Chang TT, Guan R, Tai DI, Ng KY, Wu PC, Dent JC, Gray DF: 12 months of lamivudine (100 mg od) therapy improves liver histology: Results of a placebo controlled multicentre study in Asia. *J Hepatol* 26(suppl 1):79, 1997
7. Benhamou Y, Dohin E, Luniel-Fabiani F, Poynard T, Huraux JM, Katlama C, et al: Efficacy of lamivudine in replication of

- hepatitis B virus in HIV-infected patients. *Lancet* 345:396–397, 1995
8. Grellier L, Mutimer D, Ahmed M, Brown D, Burroughs AK, Rolles K, McMaster P, Beranek P, Kennedy F, Kibbler H, McPhillips P, Elias E, Dusheiko G: Lamivudine prophylaxis against reinfection in liver transplantation for hepatitis B cirrhosis. *Lancet* 348:1212–1215, 1996
  9. McKenzie R, Fried MW, Sallie R, Conjeevaram H, Di Bisceglie AM, Park Y, Savarese B, Kleiner D, Tsokos M, Luciano C, Pruett T, Stotka JL, Straus SE, Hoofnagle JH: Hepatic failure and lactic acidosis due to fialuridine (FIAU), an investigational nucleoside analogue for hepatitis B. *N Engl J Med* 333:1099–1105, 1995
  10. Samuel D, Bismuth A, Mathieu D, Arulnaden J, Raynes M, Benhamou J, Brechot C, et al: Passive immunoprophylaxis after liver transplantation in HBsAg-positive patients. *Lancet* 337:813–815, 1991
  11. Lau JYN, Davies SE, Bain VG, O'Grady JG, Alberti A, Alexander GJM, Williams R: High level expression of hepatitis B viral antigens in fibrosing cholestatic hepatitis. *Gastroenterology* 102:956–962, 1992
  12. Marcellin P, Samuel D, Lioriot MA, Areias J, Bismuth H, Benhamou JP: Antiviral effect of adenine arabinoside monophosphate (ARA-AMP) in patients with recurrence of hepatitis B virus (HBV) infection after liver transplantation. *Hepatology* 12:966A, 1990
  13. Lok ASF, Wilson LA, Thomas HC: Neurotoxicity associated with adenine arabinoside monophosphate in the treatment of chronic hepatitis B virus infection. *J Antimicrob Chemother* 14:93–99, 1984
  14. Gish RG, Lau JYN, Brooks L, Fang JWS, Steady SL, Imperial JC, Garcia-Kennedy R, et al: Ganciclovir treatment of hepatitis B virus infection in liver transplant recipients. *Hepatology* 23:1–7, 1996
  15. Rabinovitz M, Dodson F, Rakela J: Famciclovir for recurrent hepatitis B (HBV) infection after liver transplantation (OLT). *Hepatology* 24:282A, 1996
  16. Perrillo R, Rakela J, Martin P, Levy G, Schiff E, Wright T, Dienstag J, Gish R, Villeneuve J, Caldwell S, Brown N, Self P, Lamivudine Transplant Study Group: Lamivudine for hepatitis B after liver transplantation (OLT). *Hepatology* 24:182A, 1996