

How to do it

Surgical approach for cardiac surgery in a patient with tracheostoma

data, citation and similar papers at core.ac.uk

brought to you

provided by Dadun, S.L.

Juan José Legarra*, José Aurelio Sarralde, José Luis López Coronado, Alejandro Martín Trenor

Department of Cardiovascular Surgery, Clínica Universitaria, Universidad de Navarra, Pamplona, Spain

Received 30 March 1998; revised version received 17 June 1998; accepted 22 June 1998

Abstract

The thoracic approach for cardiac surgery in a patient with a tracheostoma can result in difficult problems, such as mediastinitis, stoma necrosis or inadequate operative exposure. We present a distinct approach consisting of an incision at the second intercostal space, transverse sternum transection and longitudinal median sternotomy to the xiphoid process, performed for coronary artery bypass grafting and aortic valve replacement, in a patient with previous tracheotomy. This approach permitted adequate surgical exposure for cardiopulmonary bypass, aortic valve replacement and coronary revascularization procedures. © 1998 Elsevier Science B.V. All rights reserved

Keywords: Cardiac surgery; Tracheostoma; Thoracic approach

Open-heart surgery can be more complex in patients with previous tracheotomy or cervical esophagostomy. Several modifications of conventional median sternotomy have been described [1,2], and transverse thoracosternotomy ('clam shell' incision) is probably the most extensively used alternative to median sternotomy [3]. Modifications of bilateral thoracotomy, performing lower median sternotomy have also been used [4]. We present a distinct approach that consists of transverse sternotomy at the second intercostal space and longitudinal median sternotomy to the xiphoid process. All of these thoracic approaches permit adequate operative exposure and separate the stoma from the operative field. We chose this atypical approach because we believed it would be better tolerated by our patient, in the seventh decade of life.

The technique was carried out in a 77-year-old man with severe two-vessel coronary artery disease and critical aortic stenosis (maximum gradient, 90 mmHg; median gradient, 50 mmHg; and aortic valve area of 0.9 cm²). Angiographic study showed a hypertrophied left ventricle with a depressed left ventricle ejection fraction (0.30). Open heart surgery for double aortocoronary bypass grafting and aortic valve replacement was required. The patient had a history of arterial hypertension, heavy smoking, per-

ipheral atherosclerosis and diabetes mellitus under treatment with insulin therapy. Chronic obstruction of airway flow and high serum creatinine levels (1.74 mg/dl) were complementary risk factors. He had undergone total laryngectomy and lymphadenectomy for carcinoma of the larynx 36 years before. Pre-operatively, the patient was categorized as functional class III-IV according to the New York Heart Association (NYHA) classification system.

1. Technique

The patient was prepared in the operating room in the supine position, as for conventional cardiac surgery. The tracheostoma was cannulated for respiratory support. A semi-circular skin incision was made at the second intercostal space ('collar skin incision') (Fig. 1). From just below the middle of it, a longitudinal incision was started and continued to the xiphoid process. The internal mammary arteries (IMAs) were not required as we preferred saphenous vein grafts to revascularize the first left marginal and right coronary artery. The IMAs were divided and a transverse sternotomy was performed, followed by conventional median sternotomy from the xiphoid process to the transverse sternotomy. With this approach, we were able to open the pericardium to the reflection in the aorta and use standard aortic and right atrial cannulation techniques. A 21 mm

* Corresponding author. Marie Curie 1, 1 D, 14011 Córdoba, Spain.
Tel.: +34 919 222925.

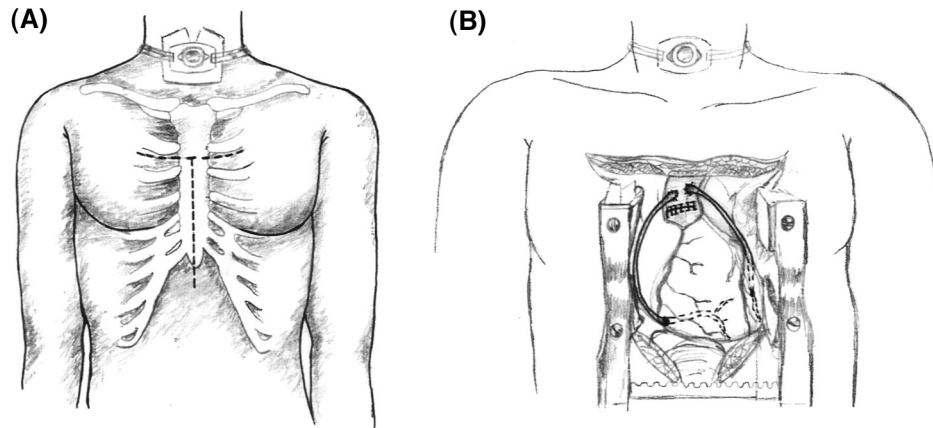


Fig. 1. (A) Semi-circle skin incision at the second intercostal space and prolongation to the xiphoid process. (B) The exposure after this atypical approach will permit us to perform conventional open heart surgery.

Hancock bioprosthesis was implanted in the aortic position and double aortocoronary bypass was carried out (Fig. 1). There were no complications during the open heart procedure.

The ribs were approximated with paracostal sutures and the sternum with interrupted stainless steel wire sutures. Chest tubes were placed in the mediastinum and pleural spaces for drainage.

Right basal atelectasis was present in the post-operative period and heavy respiratory physiotherapy was needed to avoid major respiratory complications. The patient left the Intensive Care Unit (ICU) after 96 h. The wound showed no evidence of infection, and he was discharged from the hospital 12 days after the procedure. At the present time, 5 months after the operation, the patient is classified as NYHA functional class II.

2. Discussion

Bilateral transverse submammary thoracotomy provides excellent exposure for aortic cannulation and for heart procedures. We have performed this approach in two cases involving younger patients and the outcome was excellent. We do not believe that lower median sternotomy is necessary for coronary artery bypass surgery. In the case of our 77-year-old patient, we preferred this atypical approach to decrease potential post-operative respiratory complications. Operative exposure was adequate and there were no problems in performing cardiac surgery.

The distance from the area of the tracheostoma to the thoracic incision in both approaches is large enough to minimize the risk of mediastinal infection. No dissection was carried out in the subcutaneous tissue near the tracheostoma, and we do not believe it is necessary to do so.

The IMAs were not needed in our case, but in our opinion, mobilization of the proximal portion of the left or right IMA is not excessively difficult. Careful evaluation of IMA location is mandatory before performing transverse sternotomy. When the sternal spreader is inserted, it should be opened just enough to permit dissection of the undersurface of the left sternal fragment and the left IMA. Care should be taken to avoid excessive retraction of the IMA when the sternal spreader is opened. The most difficult harvesting area is the proximal portion below the first and second ribs.

The surgeon can use femoral cannulation for cardiopulmonary bypass to maintain a cannula-free surgical field, if it is preferred. Exposure for aortic and atrial cannulation was adequate using this approach and we encountered no problems with cannulation or with the surgical procedure.

The presence of a tracheostomy imposes a considerable risk for infection in cardiac sternotomy procedures. This modification of classical median sternotomy is an interesting alternative approach to the heart.

References

- [1] Kaiser LR, Salerno TA. Coronary artery bypass in patients with total laryngectomy. *Ann Thorac Surg* 1985;39:481.
- [2] Bowman GA, Grishkin BA, Head HD. Sternotomy with tracheostoma (letters to the editor). *Ann Thorac Surg* 1986;42:119.
- [3] Marshall WG, Meng RL, Ehrenhaft JL. Coronary artery bypass grafting in patients with a tracheostoma: use of bilateral thoracotomy incision. *Ann Thorac Surg* 1988;46:465–466.
- [4] Smedira NG, Eng J, Rice TW. Bilateral thoracotomy and inferior sternotomy for bypass grafting after esophagostomy. *Ann Thorac Surg* 1997;63:847–849.