

Is expectant management of sonographically benign adnexal cysts an option in selected asymptomatic premenopausal women?

Juan Luis Alcázar¹, Gerardo Castillo, Matías Jurado and Guillermo López García

Department of Obstetrics and Gynecology, Clínica Universitaria de Navarra, School of Medicine, University of Navarra, 31008 Pamplona, Spain.

¹To whom correspondence should be addressed. E-mail: jlalcazar@unav.es

BACKGROUND: The objective was to assess whether expectant management of sonographically benign ovarian cysts may be an option for selected asymptomatic premenopausal women. **METHODS:** This is a prospective observational longitudinal study. Between January 1997 and December 2002, 323 asymptomatic premenopausal women (mean age: 40.6 years; range: 19–50 years) diagnosed as having a sonographically benign ovarian cyst measuring <6 cm were offered conservative management with periodic follow-up at 6–12 month intervals. In all cases, a first check was performed 3 months after diagnosis to confirm the ‘persistent’ nature of the cyst. A total of 120 women agreed to participate in this study and constitute the basis of the data presented. **RESULTS:** Mean diameter at diagnosis for the most frequent lesions were as follows: endometrioma 3.3 cm (SD 1.5); simple cyst 4.1 cm (SD 1.6); dermoid cyst 3.2 cm (SD 1.4); haemorrhagic cyst 3.5 cm (SD 1.2); hydrosalpinx 2.9 cm (SD 1.0). With a median follow-up of 42 months (range: 18–94 months), most lesions remained unchanged, both in size and sonographic appearance. Ten cysts (8.3%) disappeared during follow-up, all of them after more than 2 years of follow-up. No patient has developed signs or symptoms suggesting ovarian cancer. **CONCLUSION:** Most sonographically benign ovarian cysts remain unchanged during long-term follow-up. Our data would support conservative management in these cases.

Key words: conservative management/follow-up/ovarian cyst/premenopausal/ultrasound

Introduction

Ovarian tumours are a common clinical problem, affecting women of all ages. Traditional management of persistent ovarian masses has been surgical removal (Curtin, 1994). This is mainly due to concerns about malignant potential and the occurrence of possible complications such as torsion, rupture and haemorrhage. However, the natural history of adnexal masses is largely unknown.

Specifically, in premenopausal women, functional cysts are known to regress spontaneously (Alcázar *et al.*, 1997a). Other non-neoplastic lesions of the ovary, such as endometriosis and inflammatory enlargements, will often respond to medical treatment. True benign neoplasms of the ovary will probably not resolve spontaneously. Whether these benign lesions are precursors of malignancies is an unanswered question. However, the prevalence of ovarian cancer in premenopausal women is low (Morrow, 1998) and the incidence of complications related to benign ovarian masses is unknown.

Transvaginal sonography has been shown to be an excellent method to characterize ovarian masses in both premenopausal and postmenopausal women (Granberg *et al.*, 1990; Osmer *et al.*, 1996). The false negative rate may be considered very low. The correlation of sonography features with histological diagnosis has been found to be high in some benign ovarian

tumours such as endometrioma (Alcázar *et al.*, 1997b), mature teratoma (Caspi *et al.*, 1996), haemorrhagic cyst (Okai *et al.*, 1994), simple cyst (Castillo *et al.*, 2004), hydrosalpinx (Guerriero *et al.*, 2000), peritoneal cyst (Guerriero *et al.*, 2004) and cystadenofibroma (Alcázar *et al.*, 2001a).

The aim of the present study is to assess whether expectant management of sonographically benign ovarian cysts may be an option for selected asymptomatic premenopausal women.

Materials and Methods

This is an ongoing prospective observational longitudinal study. Institutional Review Board (IRB: Clínica Universitaria de Navarra) approval was obtained and all patients gave oral informed consent to participate in the study.

Inclusion criteria were as follows:

- (i) premenopausal asymptomatic woman;
- (ii) diagnosis of benign-appearing persisting adnexal masses on transvaginal B mode and colour Doppler ultrasonography;
- (iii) serum CA-125 level < 65 IU/ml;
- (iv) maximum diameter of lesion <6 cm. This was an arbitrary cut-off as no-one has evaluated the risk of complication for adnexal masses in relation with its size.

All patients were evaluated by transvaginal colour Doppler ultrasound during routine gynaecological check-up using three commercially

available ultrasound machines equipped with multifrequency endovaginal probes as well as pulsed and colour Doppler capabilities. After the endovaginal probe was gently inserted into the vagina, the uterus and adnexal regions were scanned thoroughly. If an adnexal mass was found, a thorough morphological and vascular assessment of such a mass was performed by B-mode and colour Doppler ultrasound. The technique is described in detail elsewhere (Alcázar *et al.*, 1996).

Diagnosis of benign-appearing masses such as endometrioma, mature teratoma, haemorrhagic cyst, simple cyst, hydrosalpinx and peritoneal cyst was performed based on morphological and vascular features. Those lesions with questionable or suspicious findings for malignancy such as thick papillary projections, solid areas, solid echogenicity, central blood flow location and low velocimetric indexes (Alcázar *et al.*, 2001b) were not included in this study. The same physician (J.L.A.) performed all ultrasound examinations.

The same day as ultrasound examination, a blood sample collection was obtained to determine serum CA-125 levels (Cobas-Core CA-125-IIä, Laboratories Roche, Basel, Switzerland) in all patients. The sensitivity was <5 IU/ml. The inter- and intra-assay coefficients of variation were <7.5% and <5.3%, respectively. We used a cut-off of CA-125 < 65 IU/ml to consider a lesion as benign because some benign entities such as endometriomas and haemorrhagic cysts may provoke slight increases of this tumoural marker (Gadducci *et al.*, 1992).

Once a presumed diagnosis of sonographically benign appearing adnexal mass had been made, the findings were fully explained to the patient. In all cases, a first check was performed after 2–3 months during the early follicular phase of the menstrual cycle to confirm the persistent nature of the cyst. Once this persistent nature was confirmed, expectant management with serial follow-up or surgical removal was offered to the patient. Only those patients who chose the first option were included in this study.

Serial follow-up was performed only by ultrasound at 6-month intervals during the first two years and then annually. All examinations were performed during the early follicular phase of the menstrual cycle.

Results

From January 1997 to December 2002, 14 661 premenopausal women underwent transvaginal ultrasound at our hospital and 375 consecutive asymptomatic premenopausal women were diagnosed as having a persisting, benign sonographically appearing adnexal mass. In 52 patients, the tumour measured >6 cm and, in 323 women, the mass measured <6 cm. In all these 323 patients, conservative management was initially offered after diagnosis. However, 203 patients underwent surgery subsequently because of the referring physician or their own decision. One hundred and twenty women agreed to participate in this study and chose conservative management. This selected group constitutes the basis of the data presented herein.

The mean age of the patient was 40.6 years (SD 7.9; range: 19–50 years).

Ultrasound diagnosis at the point of inclusion in the study were as shown in Table I and mean lesion diameter at diagnosis in Table II.

After a median follow-up time of 42+ months (range: 18–94 months), 10 cysts (8.3%) disappeared (initial diagnosis of these cysts were: three endometrioma; three haemorrhagic cyst; four simple cyst). The median time elapsed from diagnosis to disappearance was 34 months (range: 30–40 months). Eleven women (9.2%) were lost to follow-up.

Table I. Ultrasound diagnosis at inclusion in the study

Diagnosis	Number of patients	Percentage of patients
Endometrioma	47	39.2%
Simple cyst	32	26.7%
Mature teratoma	17	14.2%
Haemorrhagic cyst	10	9.1%
Hydrosalpinx	6	4.9%
Peritoneal cyst	4	3.2%
Cystadenofibroma	3	2.4%
Mucinous cystadenoma	1	0.8%

Table II. Mean lesion diameter at diagnosis (in cm)

Diagnosis	Mean diameter	SD	Range
Endometrioma	3.3	1.5	1.5–6.0
Simple cyst	4.1	1.6	1.5–6.0
Mature teratoma	3.2	1.4	1.5–6.0
Haemorrhagic cyst	3.5	1.2	1.5–5.5
Hydrosalpinx	2.9	1.0	1.6–3.9
Peritoneal cyst	3.1	1.2	2.3–4.5
Other	4.9	3.2	2.7–6.0

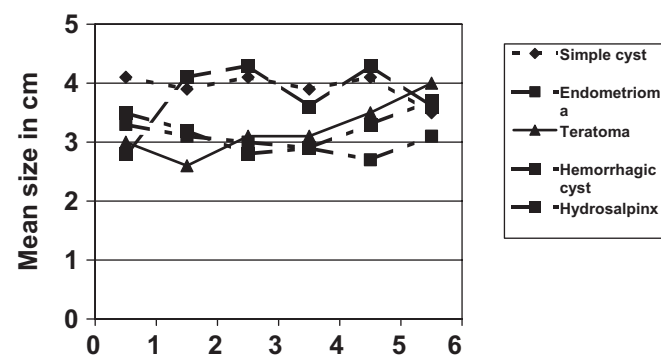


Figure 1. Mean diameter changes (in cm) according to suspected histology during follow-up

No significant change in mean diameter for the lesions was found during follow-up except for mature teratomas, which tended to increase (Fig. 1).

During this period, no patient developed signs or symptoms suggesting ovarian cancer or complications related to adnexal mass. No patient underwent surgery for the adnexal mass during follow-up.

Discussion

Asymptomatic premenopausal women diagnosed as having an adnexal mass often undergo surgical removal of the lesion (Curtin, 1994). This might be explained by concerns about malignant potential and complications related to adnexal tumours such as torsion, haemorrhage or rupture. However, the natural history of benign ovarian tumours is unknown.

However, prevalence of ovarian cancer in premenopausal women is quite low (Morrow, 1998). Furthermore, it has been shown that the removal of benign ovarian tumours does not reduce the mortality for ovarian cancer (Crayford *et al.*, 2000)

and there are data indicating that at least half of ovarian cancers may have a 'de novo' origin and do not develop from pre-existing benign lesions (Horiuchi *et al.*, 2003). In our study, no patient developed signs or symptoms suggesting ovarian cancer after a median follow-up of 3 years.

Expectant management for ovarian masses in asymptomatic premenopausal women has been proposed for functional cysts (MacKenna *et al.*, 2000) because it is known that a large proportion of these lesions will resolve spontaneously (Alcázar *et al.*, 1997a). Spontaneous resolution of cysts has also been proposed in pregnancy (Zanetta *et al.*, 2003). However, the role of expectant management of sonographically benign appearing ovarian tumours in asymptomatic non-pregnant premenopausal women has been little explored.

We are aware that a potential selection bias could exist because not all women chose conservative management and, therefore, we do not know what would have happened to those women who underwent surgery. However, we think that our data add information that could be clinically relevant for physicians faced with premenopausal women diagnosed as having a sonographically benign adnexal mass.

In our study, only 8.3% of the lesions disappeared during follow-up, confirming the persistent nature of the lesions (both non-neoplastic and neoplastic). However, the median time elapsed from diagnosis to disappearance was 34 months. Late spontaneous resolutions might therefore be expected in some cases.

After a relatively long follow-up, we found that most cysts did not change significantly in diameter, except for mature teratomas. This latter finding is in agreement with a previous study that assessed the growth pattern of dermoid cysts in premenopausal and postmenopausal women which showed that this kind of lesion trends to grow at a rate of 1.8 mm per year (Caspi *et al.*, 1997). In these cases, surgical removal should be recommended after diagnosis because growth can be expected.

In our study, no patient suffered complications related to ovarian tumour such as torsion, rupture or haemorrhage. This is consistent with the data reported by Zanetta *et al.* (2003) and Condous *et al.* (2004) in pregnant women. They found that complications in stable ovarian cysts after the first trimester were extremely uncommon. This was confirmed recently by Lee *et al.*, (2004), who reported that ovarian torsion due to ovarian tumour is uncommon in pregnant women and usually occurs in the first trimester and in tumours larger than 6 cm. These three studies concluded that expectant management was successful in most cases.

Although management of benign adnexal masses with laparoscopic removal is found to be easy and relatively safe in most hospitals and settings (Canis *et al.*, 2002), it is not exempt from risk (Canis *et al.*, 2000). This should be borne in mind when counselling patients.

Clinicians should also bear in mind that most premenopausal women are of childbearing age and, though the presence of an ovarian cyst might jeopardize ovarian function, surgery may reduce fertility potential due to oophorectomy, salpingectomy or tubal adhesions.

One important question to address when recommending conservative management of adnexal tumours is the accuracy of transvaginal ultrasound and colour Doppler in excluding

malignant tumours. However, a large number of papers demonstrate that this technique is highly reliable for excluding ovarian cancer, with a low false negative rate (as shown in a recent meta-analysis by Kinkel *et al.*, 2000).

In conclusion, the results of our study support the conservative management of ultrasound benign appearing ovarian masses in selected asymptomatic premenopausal women. This option could safely be offered to these patients after proper counselling.

References

- Alcázar JL, Ruiz-Pérez ML and Errasti T (1996) Transvaginal colour Doppler sonography in adnexal masses: which parameter performs best? *Ultrasound Obstet Gynecol* 8,114–119.
- Alcázar JL, Errasti T and Jurado M (1997a) Blood flow in functional cysts and benign ovarian neoplasms in premenopausal women. *J Ultrasound Med* 16,819–124.
- Alcázar, J.L., Laparte C, Jurado M and López-García G (1997b) The role of transvaginal ultrasonography combined with colour velocity imaging and pulsed Doppler in the diagnosis of endometrioma. *Fertil Steril* 67,487–491.
- Alcázar JL, Errasti T, Mínguez JA, Galán MJ, García-Manero M and Ceamanos C (2001a) Sonographic features of ovarian cystadenofibroma: spectrum of findings. *J Ultrasound Med* 20,5–9.
- Alcázar JL, Errasti T, Laparte C, Jurado M and López-García G (2001b) Assessment of a new logistic model in the preoperative evaluation of adnexal masses. *J Ultrasound Med* 20,841–848.
- Canis M, Botchorishvili R, Manhes H, Wattiez A, Mage G, Pouly JL and Burhat MA (2000) Management of adnexal masses: role and risk of laparoscopy. *Semin Surg Oncol* 19,28–35.
- Canis M, Rabischong B, Houille C, Botchorishvili R, Jardon K, Safi A, Wattiez A, Mage G, Pouly JL and Bruhat MA (2002) Laparoscopic management of adnexal masses: a gold standard? *Curr Opin Obstet Gynecol* 14,423–428.
- Caspi B, Appelman Z, Rabinerson D, Elchalal U, Zalel Y and Katz Z (1996) Pathognomonic echo patterns of benign cystic teratomas of the ovary: classification, incidence and accuracy rate of sonographic diagnosis. *Ultrasound Obstet Gynecol* 7,275–279.
- Caspi B, Appelman Z, Rabinerson D, Zalel Y, Tulandi T and Shoham Z (1997) The growth pattern of ovarian dermoid cysts: a prospective study in premenopausal and postmenopausal women. *Fertil Steril* 68,501–505.
- Castillo G, Alcázar JL and Jurado M (2004) Natural history of sonographically detected simple unilocular adnexal cysts in asymptomatic postmenopausal women. *Gynecol Oncol* 92,965–969.
- Condous G, Khalid A, Okaro E and Bourne T (2004) Should we be examining the ovaries in pregnancy? Prevalence and natural history of adnexal pathology detected at first-trimester sonography. *Ultrasound Obstet Gynecol* 24,62–66.
- Crayford TJ, Campbell S, Bourne TH, Rawson HJ and Collins WP (2000) Benign ovarian cysts and ovarian cancer: a cohort study with implications for screening. *Lancet* 355,1060–1063.
- Curtin JP (1994) Management of adnexal masses. *Gynecol Oncol* 55,S42–S46.
- Gadducci A, Ferdeghini M, Prontera C, Moretti L, Mariani G, Bianchi R and Fioretti P (1992) The concomitant determination of different tumour markers in patients with epithelial ovarian cancer and benign ovarian masses: relevance for differential diagnosis. *Gynecol Oncol* 44,147–154.
- Granberg S, Norstrom A and Wikland M (1990) Tumours of the lower pelvis as imaged by vaginal sonography. *Gynecol Oncol* 37, 224–229.
- Guerrero S, Ajossa S, Lai MP, Mais V, Paoletti AM and Melis GB (2000) Transvaginal ultrasonography associated with colour Doppler energy in the diagnosis of hydrosalpinx. *Hum Reprod* 15,1568–1572.
- Guerrero S, Ajossa S, Mais V, Angiolucci M, Paoletti AM and Melis GB (2004) Role of transvaginal sonography in the diagnosis of peritoneal inclusion cysts. *J Ultrasound Med* 23,1193–1200.
- Horiuchi A, Itoh K, Shimizu M, Nakai I, Yamazaki T, Kimura K, Suzuki A, Shiozawa I, Ueda N and Knonishi I (2003) Toward understanding the natural history of ovarian carcinoma development: a clinicopathological approach. *Gynecol Oncol* 88,309–317.
- Kinkel K, Hricak H, Lu Y, Tsuda K and Filly RA (2000) US characterization of ovarian masses: a meta-analysis. *Radiology* 217,803–311.
- Lee GS, Hur SY, Shin JC, Kim SP and Kim SJ (2004) Elective vs. conservative management of ovarian tumours in pregnancy. *Int J Gynaecol Obstet* 85,250–254.

- MacKenna A, Fabres C, Alam V and Morales V (2000) Clinical management of functional ovarian cysts: a prospective and randomized study. *Human Reprod* 15,2567–2569.
- Morrow CP (1998) Tumours of the ovary: neoplasms derived from the celomic epithelium. In: Morrow CP, Curtin JP (eds). *Synopsis of gynecologic oncology*. Churchill-Livingstone, Philadelphia, USA, pp. 233–280.
- Okai T, Kobayashi K, Ryo E, Kagawa H, Kozuma S and Taketani Y (1994) Transvaginal sonographic appearance of hemorrhagic functional ovarian cysts and their spontaneous regression. *Int J Gynaecol Obstet* 44,47–52.
- Osmers R, Osmers M, Von Maydell B, Wagner B and Huhn W (1996) Preoperative evaluation of ovarian tumours in the premenopause by transvaginosonography. *Am J Obstet Gynecol* 175,428–434.
- Zanetta G, Mariani E, Lissoni A, Ceruti P, Trio D, Strobelt N and Mariani S (2003) A prospective study of the role of ultrasound in the management of adnexal masses in pregnancy. *BJOG* 110,578–583.

Submitted on January 11, 2005; resubmitted on June 1, 2005; accepted on June 22, 2005