



REVIEW

Reconstruction of pharyngeal defects

Juan M. Alcalde,* Carlos Gimeno-Vilar, Lourdes Montes-Jovellar, Raquel Manrique, and Ignacio Sanhueza

Departamento de Otorrinolaringología, Clínica Universitaria de Navarra, Universidad de Navarra, Pamplona, Navarra, Spain

Received September 29, 2008; accepted March 5, 2009
Available online June 21, 2009

KEYWORDS

Head and neck reconstruction;
Pharynx;
Pedicle flaps;
Microvascular free flaps

Abstract

Reconstruction of pharyngeal defects continues to present a clinical challenge for the head and neck surgeon. We have different reconstructive options to preserve speech, airway, and swallowing functions. Reconstructive surgery implies a balance between oncologic cure, patient morbidity, and quality of life.

Classical reconstructive techniques include pedicled cervical cutaneous or myocutaneous flaps and distal myocutaneous flaps such as from the pectoralis major. Current microvascular technique options have a differing incidence of complications but always with high success rates.

This article reviews the most current options on reconstructive techniques in pharyngeal defects

© 2008 Elsevier España. All rights reserved.

PALABRAS CLAVE

Reconstrucción de cabeza y cuello;
Faringe;
Colgajos pediculados;
Colgajos libres microvascularizados

Reconstrucción de defectos faríngeos

Resumen

La reconstrucción de defectos faríngeos sigue siendo un reto para el cirujano de cabeza y cuello. Las diferentes opciones reconstructivas van orientadas a mantener la función vocal, la vía aérea y la deglución. La técnica de reconstrucción supone un equilibrio entre la curación oncológica, la morbilidad del paciente y la calidad de vida.

Las técnicas reconstructivas clásicas incluyen los colgajos pediculados cutáneos y miocutáneos cervicales y los colgajos miocutáneos distales, como el de pectoral mayor. Actualmente, las técnicas de reconstrucción microvascular difieren en la incidencia de complicaciones, pero siempre con un alto nivel de viabilidad.

Este trabajo tiene como objetivo revisar las opciones actuales en técnicas reconstructivas de defectos faríngeos.

© 2008 Elsevier España, S.L. Todos los derechos reservados.

*Corresponding author.

E-mail address: jalcalde@unav.es (J.M. Alcalde).

Reconstruction of pharyngeal defects

Of the surgical defects of the pharynx, those of the hypopharynx are the most frequent in our speciality and we are going to concentrate on them when reviewing the reconstruction options currently available.

Most of these defects are related to oncological pathologies and may include only one segment of the pharynx, or extend to a part or all of the larynx, ie, partial pharyngectomies, partial pharyngo-laryngectomies, total laryngectomies with partial or subtotal pharyngectomy and total pharyngo-laryngectomies. In general, the fundamental goals of any reconstruction of a pharyngeal defect are:

- To restore the integrity of the digestive track, allowing an adequate intake of food by mouth.
- To maintain phonation, either through the conservation of part of the larynx, or by any rehabilitation technique if accompanied by a total laryngectomy.
- To perform the technique in a single surgical operation.

Depending on the type of pharyngeal defect and the different surgical options in pharyngolaryngeal oncological surgery, we also have a choice of different reconstructive techniques. Thus, we can use the skin of the neck (Mikulicz technique), the superficial cervical fascia, the skin of the neck and platysma (dermo-platysmo-fascial flap), pedicled flaps of the cervical region (like the platysma flap or the sternocleidomastoid [SCM] or infrahyoid muscles), distant pedicled flaps (such as the *pectoralis major*), or the free microvascular flaps, either visceral (and among these mainly the jejunum) or fasciocutaneous flaps, including the radial as the most frequent, or the more recently incorporated anterolateral thigh flap (ALT) as a perforating flap.

Other techniques, such as the use of the tubulized deltopectoral flap have now been discarded and replaced.

In more complex cases, which include some part of the oropharynx and primarily the base of the tongue at the upper limit of resection or the oesophagus at the lower limit, we must think of alternatives other than those mentioned.

As in all reconstructive procedures of the head and neck, in addition to taking into account the surgical defect to be rebuilt, we must also assess the conditions of the tissues of the neck, especially regarding the prior history of surgery and/or radiotherapy, and the physical condition of the patient with regard to tolerance to a more protracted and complex surgical procedure.

On the other hand, currently, all reconstruction techniques identified present a viability at least above 90%, thus they are completely reproducible techniques for the majority of specialists in otorhinolaryngology (ENT) with expertise in oncology surgery of the head and neck.

We shall now review each of the referred techniques and their application in pharyngeal defects.

Pharyngeal reconstruction options

Pedicled flaps

Local cutaneous flaps

The use of the skin of the neck to create a neopharynx was devised in 1884 by Mikulicz. The anterior cervical skin is

sutured to the pre-vertebral fascia to form the posterior pharyngeal wall and from here 2 lateral skin flaps are designed which will configure the posterior pharyngeal wall. Although currently this technique is rarely used as such, since it requires various surgical times and the result is poor compared with other techniques, it can be used with some modification for the closure of small pharyngostomes, especially in non-irradiated patients with loose cervical skin.

Dermo-platysmo-fascial flap

This flap is based on the use of the anterior cervical skin flap, carried out at the beginning of surgery in the neck approach to reconstruct pharyngeal defects that do not allow a pharyngeal closure without significant risk of fistula or secondary stenosis. The pharyngeal segment not removed is used as the posterior pharyngeal wall and the dermo-platysmo-fascial flap as the anterior wall. It allows a wide pharyngeal diameter without the need to carry out any additional reconstruction.

Platysma flap

The platysma flap is based on the use of this muscle, vascularized from the facial artery and mainly from its sub-mentonian branch, in the reconstruction of defects in both oral and pharyngeal mucosa. Its main drawback is that the arc of rotation is limited by the broad muscle pedicle required and which must be maintained in all its extension; nevertheless, its dissection is simple and in obese patients an important part of the subcutaneous fat mass can be included, so vascularization of the flap is maintained better (Figures 1 and 2).

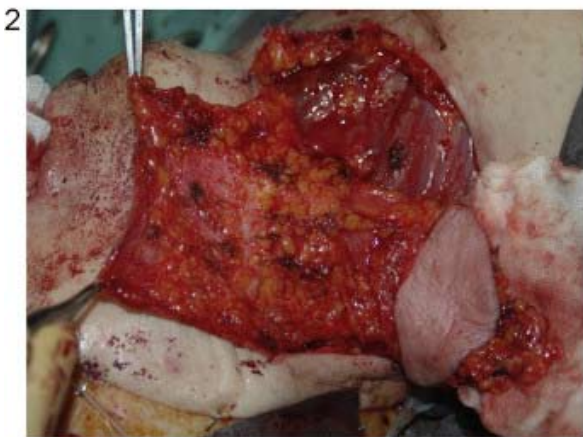
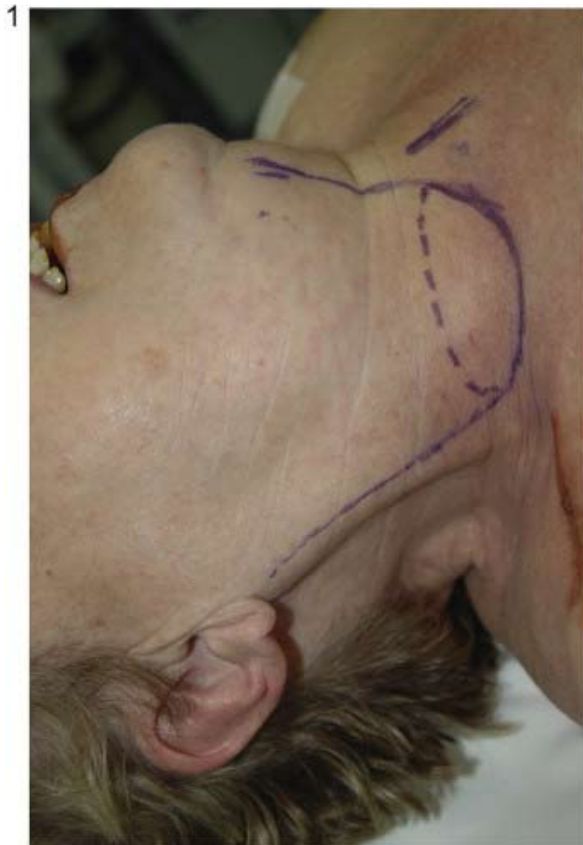Although the use of this flap for the reconstruction of pharyngeal defects is uncommon, it is important to bear it in mind as a possible option according to the experience reported by some authors¹³ in surgery of both pharynx and larynx.⁴

SCM muscle flap

Although surgery of laryngeal-pharyngeal neoplasms is often associated with lymph node dissection excluding a significant portion of the perforators going to the SCM muscle from its main pedicle originating in the occipital artery, or from its 3 minor pedicles originating in the posterior auricular artery, the superior thyroid and the transverse cervical, the SCM muscle maintains an adequate and sufficient vascularization for use in some reconstructions. While we can use it with both upper and lower pedicles, the latter option is usually the most frequently used as it provides a greater arc of rotation. Its use has been described in initial surgery,⁵ although there are currently other preferable or more frequently used options, in pharyngeal stenosis or of the retrocricoid region⁶ or, in our experience, muscle flap in the closure of oral-hypopharyngeal fistulae in patients with cervical re-irradiation as an alternative to the use of a *pectoralis major* flap (Figures 3-5).

Infrahyoid flap

The infrahyoid flap is based on the use of the infrahyoid musculature (sternohyoid and sternothyroid muscles and the anterior side of the omohyoid) together with the skin covering them. The vascularity of these muscles is



Figures 1, 2 Platysma flap.

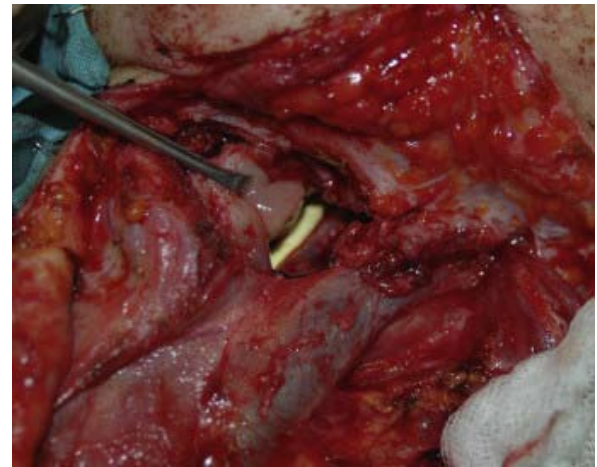


Figure 3 Pharyngeal defect.

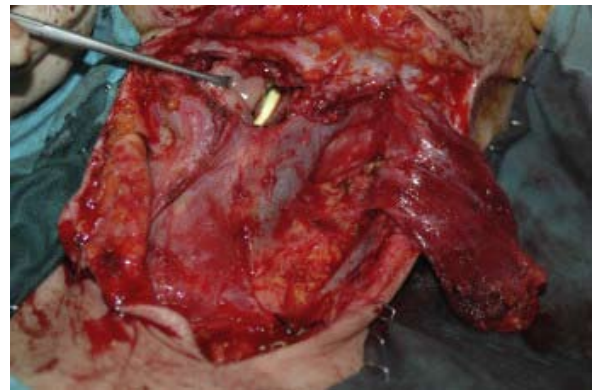


Figure 4 Dissection of muscle flap.

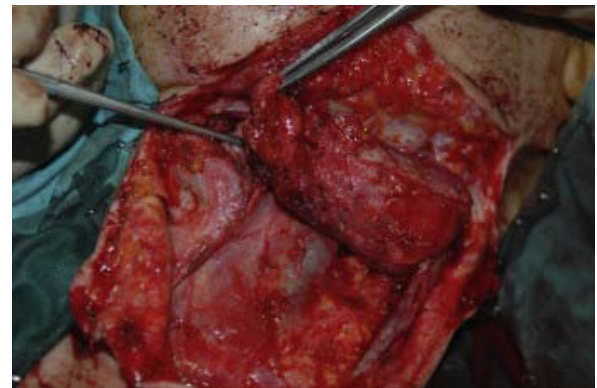


Figure 5 Closure of the pharyngeal defect with the sternocleidomastoid muscle.

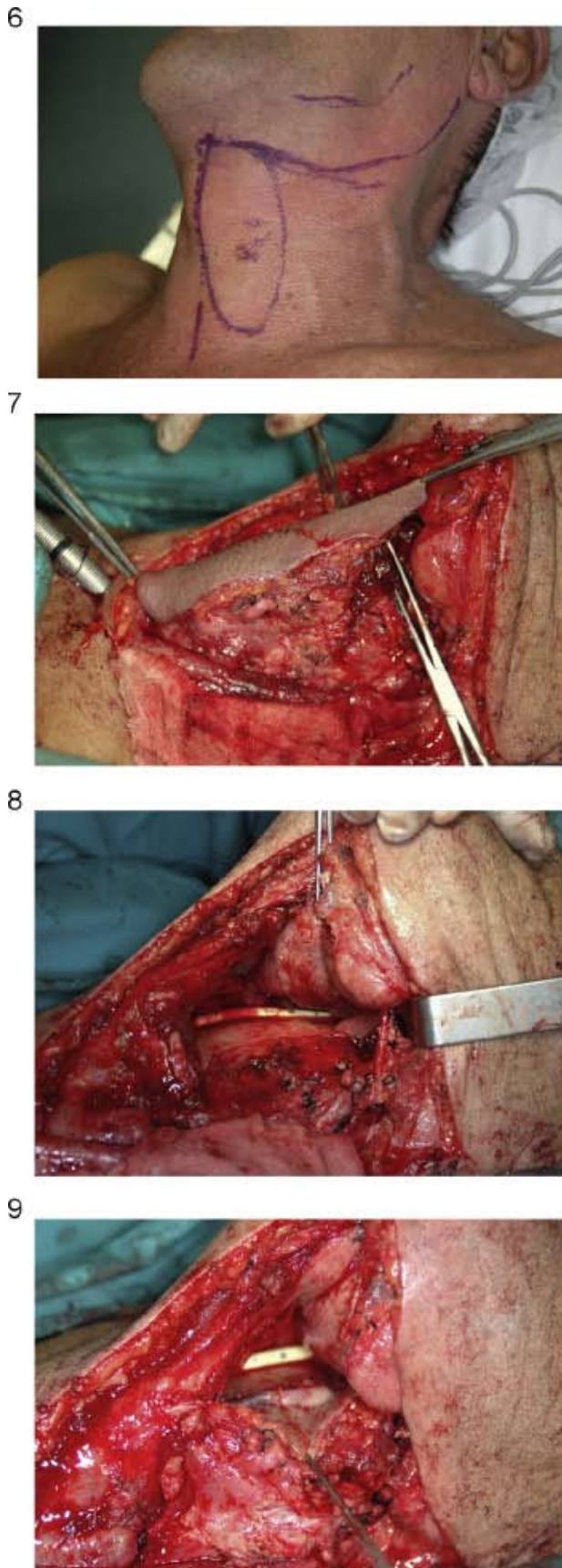
via the superior thyroid pedicle and their innervation can be maintained and, therefore, muscle atrophy can be prevented by retaining the descending branch of the hypoglossal nerve. Although its use became widespread after 1986 following Wang's experience, it had been in use in some of its variants since 1969.

Its main application is in defects of the oral cavity, and it can also be used in small pharyngeal or pharyngo-laryngeal defects, taking into account that the usual dimensions are around 8x4 cm (Figure 6).

It is also possible to use it bilaterally, albeit with difficulty in skin closure on the neck except in patients with redundant skin. Moreover, although it is not noted in the medical literature, personal experience indicates that in obese

patients, the viability of the skin flap may be lower due to the distance between the muscle and the skin, making it difficult for the perforators to reach it.

The portion of the arterial pedicle from the superior thyroid artery is fairly constant, although the superior thyroid vein, in at least 20% of cases, is not included in the thyrolinguofacial pedicle, but instead reaches the internal



Figures 6-9 In some selected cases unilaterally conserving this muscle: infrahyoid flap.

jugular vein in an inferior segment. This anatomic variant has no significance in pharyngeal reconstruction, but does matter in that of the oral cavity due to its lower arc of rotation.

It is important to note, from the beginning of the surgery, the design of the skin flap for the incisions in the skin, as well as maintaining intact the superior thyroid pedicle during cervical dissection. It is contraindicated, therefore, in those cases in which the internal jugular vein is included or when the entire thyrolinguofacial trunk is joined in the dissection and, in a relative way, in patients with a history of cervical radiation therapy, although in these cases it depends on the dose. Although the viability of this flap is over 90%, in some cases it can show a superficial dermal necrosis with subsequent scarring by secondary intention from the subjacent musculature^{7,8} (Figures 7-9).

Pectoralis major flap

Since its application in head and neck surgery was described at the end of the 1970s, it has been the battle horse of our reconstructive surgery, even in that of pharyngeal defects.

The main disadvantage of this flap is its thickness. This volume of the tissue impedes the acquisition of erygmophonic voice as well as adaptation to the pharyngeal defect in obese patients. Its greatest advantages are its ease of dissection, as well as providing a muscle that facilitates healing in frequently radiated areas.

Although in most cases its use has been replaced by microvascular flaps, it is still useful in patients with partial pharyngeal defects and in those in whom prior treatment hinders the obtention of suitable donor vessels for microvascular reconstruction.

In partial pharyngectomies it can be designed with a width of about 5-6 cm, sufficient to provide a suitable diameter to the neopharynx, with suture to the lateral edges of the pharyngeal remnant, whilst at the same time carrying out a few points of fixation to the pre-vertebral fascia, more resistant than the pharyngeal mucosa (Figures 10, 11).

In the reconstruction of total pharyngeal defects, their adaptation was initially described through tubulization,⁹ although the high rate of local complications they presented and subsequent experience have shown that it is preferable to use the pre-vertebral fascia with or, more usually, without skin graft over it, as the posterior pharyngeal wall and to adapt the *pectoralis* to reconstruct an anterior neowall. This is what some authors call U shaped flap.^{10,11} In addition, some papers¹² recommend the joint use of a Montgomery salivary bypass to maintain the pharyngeal space.

The incidence of local complications in the use of this flap for pharyngeal reconstruction is relatively high, with the incidence of fistula between 0% and 46% according to different authors.

Another important application of this flap, and in some cases with preference over microvascular flaps, is for the closure of pharyngostoma. In these cases, postoperative radiation is often associated with local fibrosis, and the *pectoralis major* myocutaneous flap allows us to reconstruct the anterior pharyngeal wall with pectoral skin, while we can place a skin graft on the muscle surface to rebuild cervical skin. In these patients, the edge of the pharyngostoma of the side on which the pectoral dissection was carried out is well protected by the muscular pedicle, but fistulae often

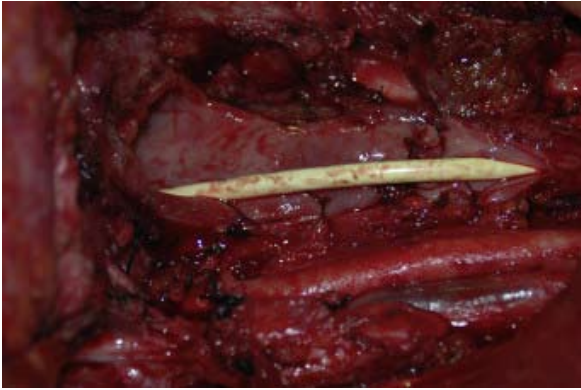


Figure 10 Pharyngeal remnant after total laryngectomy and ample pharyngectomy.

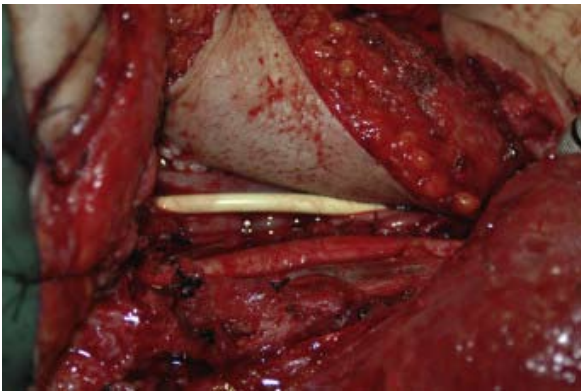


Figure 11 *Pectoralis major* flap.

arise at the contralateral edge, and to prevent these it is very important to pass far enough over the edge of the pharyngostoma with the pectoral muscle.

The *pectoralis major* flap can also be used as a muscular flap or myocutaneous flap, in addition to a microvascular flap in wide in pharyngo-cutaneous defects.¹³

Microvascular flaps

Since the 1970s the use of microvascular flaps has become popular in the reconstruction of pharyngeal defects, mainly in those cases with wide resections or after total pharyngolaryngectomy.

Among the options for microvascular reconstruction we can differentiate 2 types of donor tissue; on the one hand, the abdominal viscera, mainly the jejunum and occasionally the gastro-omental flap and, on the other hand, the fascio-cutaneous tissue, highlighting the radial flap and, more recently, the anterolateral thigh flap mainly as perforator flap.

Probably, the current trend is towards using a fascio-cutaneous flap in the reconstruction of partial defects, and this same flap or a jejunal flap for total pharyngectomies. The main advantages of fascio-cutaneous flaps are less general morbidity in the donor area with respect to the need for abdominal surgery and an increased tissue tolerance to ischaemia time. The main drawback is a higher incidence of fistulas and stenosis in the total reconstruction of the hypopharynx, compared with the radial flap of the jejunum.

In those cases in which cervical skin is included, a pedicled flap can be associated, as we have stated previously, mainly from *pectoralis major*, or a gastro-omental flap that also allows adequate coverage of the vascular axis, so a free skin graft can be completed on it.

Visceral flaps

- **Jejunal flap:** since Seidenberg described it in 1956 for hypopharyngeal reconstruction, it has been the most widely used. The abdominal dissection of this flap may be performed by laparotomy or laparoscopy, although its use is contraindicated in cases of chronic intestinal disease (eg, Crohn's disease), chronic liver pathology with ascites, or relatively contraindicated in cases of prior abdominal surgery with posterior presence of adhesences.¹⁴

The viability of the jejunal flap is over 95%, although in those cases where thrombosis of the pedicle may present, the chances of rescue are slim due to its low tolerance to ischaemia, as noted above.

In patients with a history of prior radiation therapy, there is a higher incidence of local complications, mainly fistulae (10%) usually treated conservatively, and stenosis (10%), mainly in relation to the distal suture and the oesophagus, although it may also be observed in cases of excessive length of the flap promoting angling.

Although the segment of jejunum adapts isoperistaltically to the pharynx, this peristalsis is not carried out synchronously with the pharyngo-oesophagus and may be a source of dysphagia. Postoperative radiation therapy and spontaneous evolution in time decrease peristalsis in this regard.

In order to improve dysphagia some authors recommend the implementation of a double open flap attached to the antimesenteric edge which, while providing a larger diameter, interrupts the intestinal circular musculature¹⁵ (Figures 12, 13).

Regarding the donor site, there is a risk of approximately 5.8% for complications including dehiscence of the abdominal wall, intestinal obstruction, abdominal haemorrhage, and paralysis of the ileus.¹⁶

- **Gastro-omental flap:** as stated earlier, it can be used, albeit infrequently, in the reconstruction of pharyngeal defects and normally in these cases accompanied by extensive resection of cervical skin.

It uses the major curvature of the stomach and omentum for pharyngeal reconstruction, allowing their tubulisation.¹⁷

Fascio-cutaneous flaps

- **Radial flap/anterolateral leg flap:** within the fasciocutaneous flaps, the radial flap is the most used,

although there are other alternatives, such as the lateral arm flap or, more recently, the anterolateral leg flap, described as perforator flaps. Similarly to other microvascular flaps, fasciocutaneous flaps show viability in excess of 95%.

In 1985, Harii introduced the radial flap for reconstruction of the hypopharynx. From the beginning, despite the lower morbidity of the donor area and the increased tolerance to ischaemia in these tissues with respect to visceral flaps, many centres have continued to use the jejunum flap in reconstructions of total pharyngo-laryngectomies, mainly as has already been mentioned due to a higher observed rate of fistulae (17%-28%) and stenosis (10%-36%) in the reconstructions made with radial flaps in comparison with that of jejunum.^{18,19}

However, recent experience with the anterolateral leg flap is positive with regard to an incidence of fistulae and stenosis similar to that observed for the jejunum flap (0%-13% and 12%-27%, respectively^{20,21}), with less dysphagia also observed. This decrease in the incidence of complications is probably related to the provision of a wide area of skin and conservation in the anterolateral leg flap of the fascia of the *vastus lateralis*. Moreover, in the event a fistula appears, its resolution time is shorter compared with that of a jejunal flap.

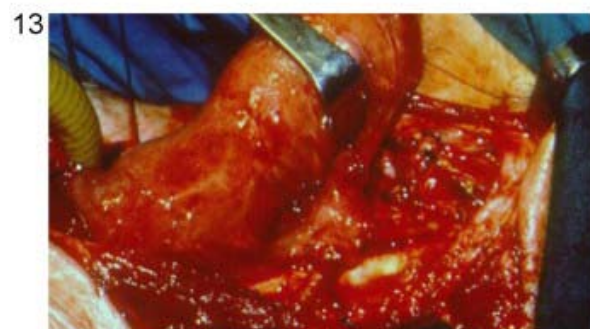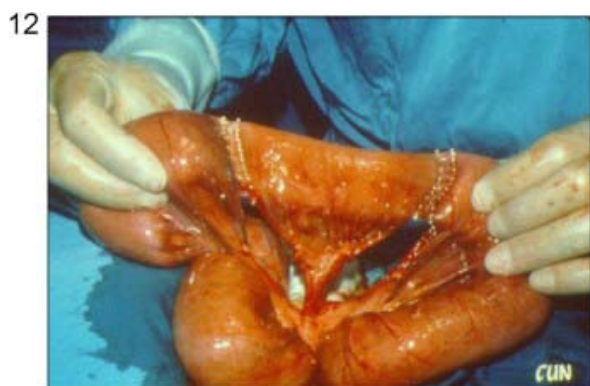Other additional advantages mentioned by some authors are a greater ease in the monitoring of fasciocutaneous flaps, either in total or partial reconstructions of the pharynx²² (Figures 14-23), the possibility of reconstructing pharyngo-

cutaneous defects with 2 islands of skin simultaneously²³ and greater ease for voice rehabilitation.

In this regard, patients with jejunal flap often present a wet voice. To improve this aspect, the use of the ileocolic valve has been proposed.²⁴ However, the possibility of using a tracheo-oesophageal prosthesis or even an erymphonetic voice seems simpler in cases reconstructed with fasciocutaneous flaps.

Although the most optimal choice of reconstruction method is influenced, as already noted, not only by the type of surgical defect, but also by the characteristics of the neck of the patient and the general conditions, from the point of view of classification of the most frequent pharyngeal defects we can summarize reconstructive options in a theoretically preferential order:

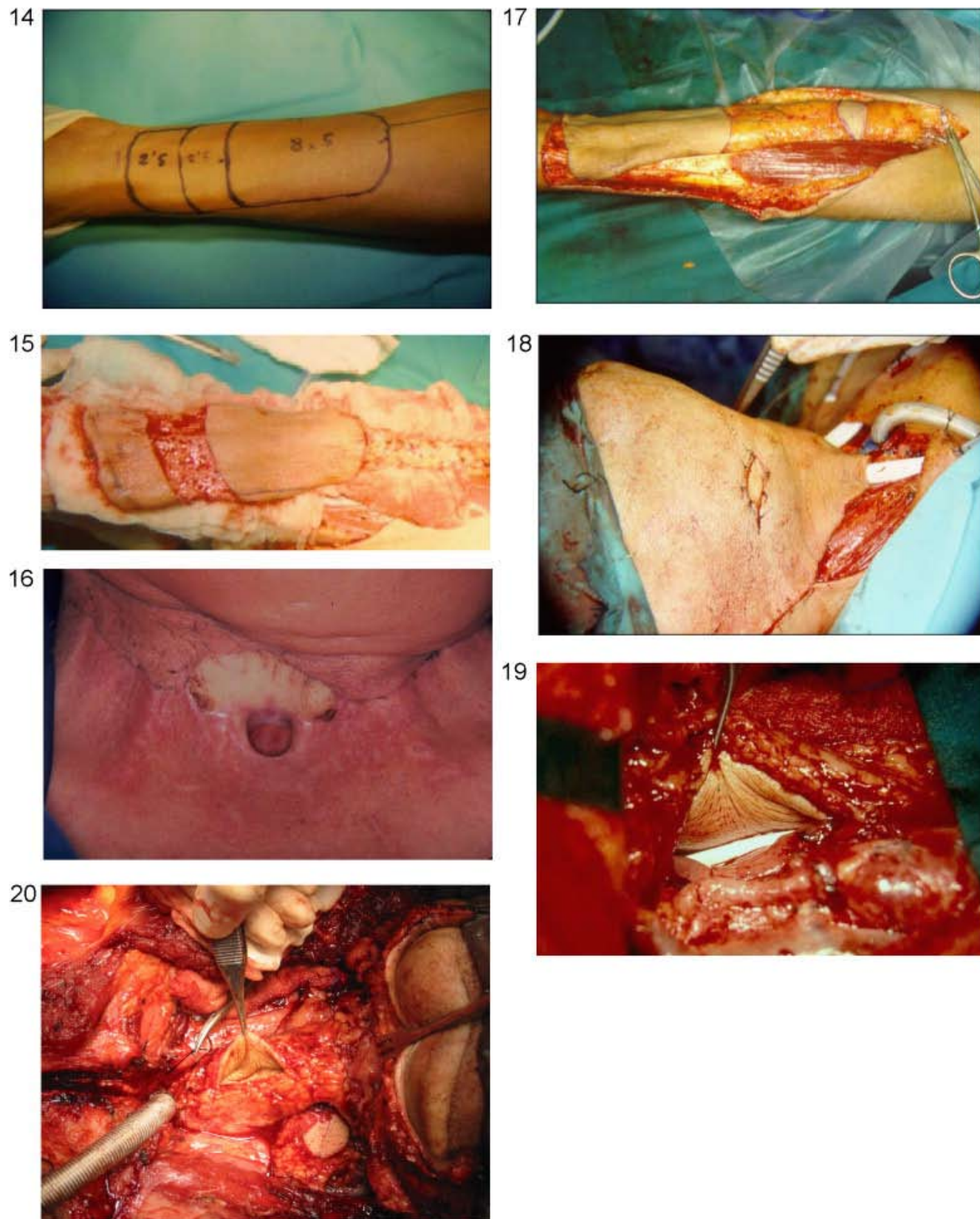
1. Partial pharyngectomies and partial pharyngolaryngectomies with wide resection toward the posterior pharyngeal wall:
 - Infrahyoid flap.
 - Platysma flap.
 - Radial flap.
2. Total laryngectomy with subtotal pharyngectomy:
 - Radial flap.
 - Dermo-platysmo-fascial flap.
 - Pectoralis major flap.
 - Anterolateral perforator leg flap.
 - Jejunum flap.
 - In some selected cases unilaterally conserving this musculature: infrahyoid flap.
3. Total laryngopharyngectomy:
 - Jejunum flap/radial flap (depending on the preference of the surgeon).
 - Anterolateral perforator leg flap.
 - Pectoralis major flap.



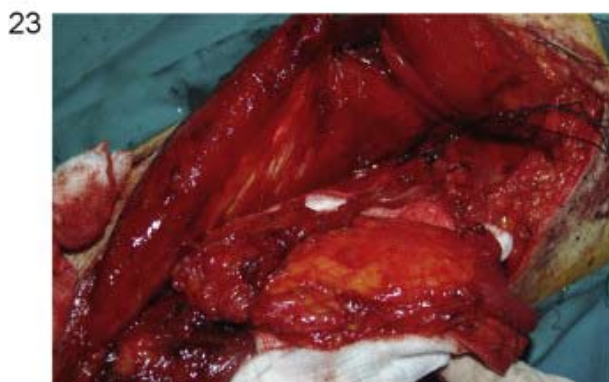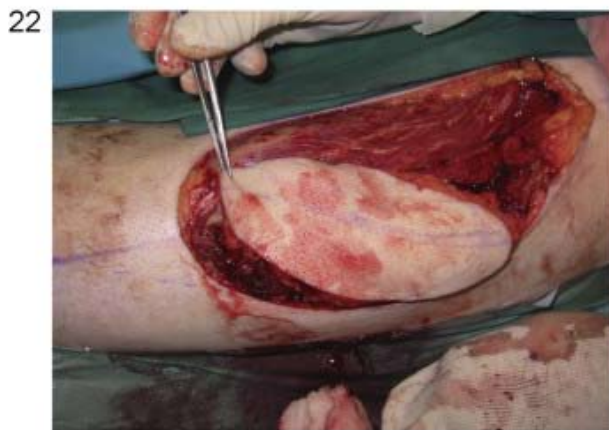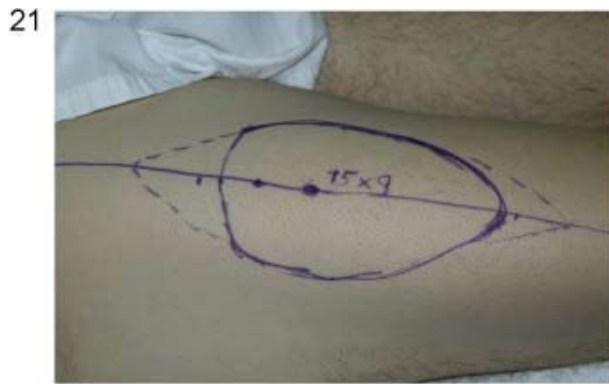
Figures 12, 13 Jejunal flap.

References

1. Suárez Nieto C, Lorenzo Gallego L, Galan Cortés JC. Reconstruction of the posterior wall of the pharynx using a myocutaneous platysma flap. *Br J Plast Surg.* 1983;36:36-9.
2. Ruark DS, McClairn WC, Schlehaider UK, Abdel-Misih RZ. Head and neck reconstruction using the platysma myocutaneous flap. *Am J Surg.* 1993;165:713-8.
3. Friedman M, Schild JA, Venkatesan TK. Platysma myocutaneous flap for repair of hypopharyngeal strictures. *Ann Otol Rhinol Laryngol.* 1990;99:945-50.
4. Dursun G, Ozgursoy OB. Laryngeal reconstruction by platysma myofascial flap after vertical partial laryngectomy. *Head and Neck.* 2005;27:762-70.
5. Ariyan S. Pectoralis major, sternocleidomastoid, and other musculocutaneous flaps for head and neck reconstruction. *Clin Plast Surg.* 1980;7:89-109.
6. Haller JR, Gray SD. Severe pharyngeal stenosis treated with inferiorly based sternocleidomastoid myocutaneous flap. *Ann Otol Rhinol Laryngol.* 1999;108:731-4.
7. Rojananin S, Suphaphongs N, Ballantyne A. The infrahyoid musculocutaneous flap in head and neck reconstruction. *Am J Surg.* 1991;162:400-3.
8. Hell B, Heissler E, Gath H, Menneking H, Langford A. The infrahyoid flap. A technique for defect closure in the floor of the mouth, the tongue, the buccal mucosa, and the lateral pharyngeal wall. *Int J Oral Maxillofac Surg.* 1997;26:35-41.



Figures 14-20 Radial flap.



Figures 21-23 Perforator anterolateral thigh flap.

9. Neifeld JP, Merritt WA, Theogaraj SD, Parker GA. Tubed pectoralis major musculocutaneous flaps for cervical esophageal replacement. *Ann Plast Surg.* 1983;11:24-30.

10. Morshed K, Szymanski M, Golabek W. Reconstruction of the hypopharynx with U-shaped pectoralis major myocutaneous flap after total pharyngo-laryngectomy. *Eur Arch Otorhinolaryngol.* 2005;262:259-62.
11. Spriano G, Pellini R, Roselli R. Pectoralis major myocutaneous flap for hypopharyngeal reconstruction. *Plast Reconstr Surg.* 2002;110:1408-13.
12. León X, Quer M, Burgués J. Montgomery salivary bypass tube in the reconstruction of the hypopharynx. Cost-benefit study. *Ann Otol Rhinol Laryngol.* 1999;108:864-8.
13. Dubsy PC, Stift A, Rath T, Kornfehl J. Salvage surgery for recurrent carcinoma of the hypopharynx and reconstruction using jejunal free tissue transfer and pectoralis major muscle pedicled flap. *Arch Otolaryngol Head Neck Surg.* 2007;133:551-5.
14. Disa JJ, Pusic A, Mehrara BJ. Reconstruction of the hypopharynx with the free jejunum transfer. *J Surg Oncol.* 2006;94:466-70.
15. Harashina T, Inoue T, Andoh T, Sugimoto C, Fujino T. Reconstruction of cervical oesophagus with free double-folded intestinal graft. *Br J Plast Surg.* 1985;38:483-7.
16. Shangold LM, Urken ML, Lawson W. Jejunal transplantation for pharyngoesophageal reconstruction. *Otolaryngol Clin North Am.* 1991;24:1321-42.
17. Righini CA, Bettega G, Lequeux T, Chaffanjon P, Lebeau J, Rey E. Use of tubed gastro-omental free flap for hypopharynx and cervical esophagus reconstruction after total laryngopharyngectomy. *Eur Arch Otorhinolaryngol.* 2005;262:362-7.
18. Genden EM, Jacobson AS. The role of the anterolateral thigh flap for pharyngoesophageal reconstruction. *Arch Otolaryngol Head Neck Surg.* 2005;131:796-9.
19. Scharpf J, Esclamado RM. Reconstruction with radial forearm flaps after ablative surgery for hypopharyngeal cancer. *Head and Neck.* 2003;25:261-6.
20. Yu P, Robb GL. Pharyngoesophageal reconstruction with the anterolateral thigh flap: A clinical and functional outcomes study. *Plast Reconstr Surg.* 2005;116:1845-55.
21. Yu P, Lewin JS, Reece GP, Robb GL. Comparison of clinical and functional outcomes and hospital costs following pharyngoesophageal reconstruction with the anterolateral thigh free flap versus the jejunal flap. *Plast Reconstr Surg.* 2006;117:968-74.
22. Alcalde JM, Quesada JL. Monitoring of partial pharyngeal reconstruction. *Laryngoscope.* 2002;112:580-2.
23. Agarwal JP, Stenson KM, Gottlieb LJ. A simplified design of a dual island fasciocutaneous free flap for simultaneous pharyngoesophageal and anterior neck reconstruction. *J Reconstr Microsurg.* 2006;22:105-12.
24. Leu YS, Hsiao HT, Chang YC, Yang CC, Lee JC, Chen YJ, et al. Ileocolic free flap reconstruction, concomitant chemotherapy and radiotherapy and assessment of speech and swallowing function during management of advanced cancer of the larynx and hypopharynx: Preliminary report. *Acta Otolaryngol.* 2005;125:642-6.