



# Diagnostic Yield of Electromagnetic Navigation Bronchoscopy Is Highly Dependent on the Presence of a Bronchus Sign on CT Imaging

## Results From a Prospective Study

Luis M. Seijo, MD; Juan P. de Torres, MD; María D. Lozano, MD; Gorka Bastarrika, MD; Ana B. Alcaide, MD; Maria M. Lacunza, RN; and Javier J. Zulueta, MD

**Background:** Electromagnetic navigation bronchoscopy (ENB) has been developed as a novel ancillary tool for the bronchoscopic diagnosis of pulmonary nodules. Despite successful navigation in 90% of patients, ENB diagnostic yield does not generally exceed 70%. We sought to determine whether the presence of a bronchus sign on CT imaging conditions diagnostic yield of ENB and might account for the discrepancy between successful navigation and diagnostic yield.

**Methods:** We conducted a prospective, single-center study of ENB in 51 consecutive patients with pulmonary nodules. ENB was chosen as the least invasive diagnostic technique in patients with a high surgical risk, suspected metastatic disease, or advanced-stage disease, or in those who demanded a preoperative diagnosis prior to undergoing curative resection. We studied patient and technical variables that might condition diagnostic yield, including size, cause, location, distance to the pleural surface, and fluorodeoxyglucose uptake of a given nodule; the presence of a bronchus sign on CT imaging; registration point divergence; and the minimum distance from the tip of the locatable guide to the nodule measured during the procedure.

**Results:** The diagnostic yield of ENB was 67% (34/51). The sensitivity and specificity of ENB for malignancy in this study were 71% and 100%, respectively. ENB was diagnostic in 79% (30/38) patients with a bronchus sign on CT imaging but only in 4/13 (31%) with no discernible bronchus sign. Univariate analysis identified the bronchus sign ( $P = .005$ ) and nodule size ( $P = .04$ ) as statistically significant variables conditioning yield, but on multivariate analysis, only the bronchus sign remained significant (OR, 7.6; 95% CI, 1.8-31.7). No procedure-related complications were observed.

**Conclusions:** ENB diagnostic yield is highly dependent on the presence of a bronchus sign on CT imaging. *CHEST 2010; 138(6):1316-1321*

**Abbreviations:** ENB = electromagnetic navigation bronchoscopy; TBB = transbronchial biopsy; TTNA = CT scan-guided transthoracic needle biopsy

The diagnostic yield of conventional transbronchial biopsy (TBB) for peripheral nodules measuring <2 cm has been reported to be 15% to 54%.<sup>1</sup> TBB has a higher yield if the nodule is malignant or close to the hilum, or when a bronchus sign is evident on CT imaging but may be futile when the nodule is located in basal or apical lung segments.<sup>2-4</sup> CT scan-guided transthoracic needle biopsy (TTNA) or surgery are diagnostic alternatives with higher overall yields but also greater morbidity and mortality. Pneumothorax occurs in as many as 23% of TTNAs,

and up to one-fourth of these require chest-tube drainage.<sup>5</sup> Unfortunately, neither radiograph fluoroscopy nor CT scan-guided TBB have contributed to increased yields.<sup>6,7</sup>

---

**For editorial comment see page 1290**

---

The introduction of novel guidance techniques has renewed interest in bronchoscopy as a diagnostic tool in the periphery of the lung. Studies have demonstrated

that the use of radial ultrasound probes or electromagnetic navigation bronchoscopy (ENB) may increase the diagnostic yield of conventional TBB.<sup>8-13</sup> However, despite navigation success in a majority of patients (90%) and the availability of rapid onsite evaluation by a cytopathologist, diagnostic yields with ENB generally do not exceed 70%.<sup>11</sup> Few authors have investigated prospectively the reasons for this discrepancy, which we hypothesized might be accounted for by the presence of a bronchus sign on CT imaging (Fig 1).

## MATERIALS AND METHODS

We conducted a single-center, prospective, observational study between October 2007 and March 2009, enrolling 51 consecutive patients with pulmonary nodules or masses undergoing ENB (Table 1). The primary end points of the study were to identify patient and/or technical variables that might condition ENB yield and to determine whether the presence of a bronchus sign on CT imaging conditions the yield of ENB (inReach system; superDimension, Inc; Minneapolis, MN). Because the published discrepancy between ENB navigation success and diagnostic yield approximates 20%, we estimated that 50 patients might be sufficient to identify variables conditioning yield. Patients were selected for ENB based on surgical risk, advanced-stage disease in which the lung was deemed the most accessible biopsy site, or personal preference (patients who were unwilling to undergo surgical resection without a prior attempt at minimally invasive diagnosis). Alternative diagnostic procedures, including surgery and transthoracic needle aspiration, and their potential risks and benefits were discussed with all patients. During the study period, five ENB-eligible patients opted for surgery. All patients included in data analysis had either declined the transthoracic approach or were referred for ENB by a pulmonologist, oncologist, or radiologist eschewing TTNA for technical reasons or because of risk (eg, distance of the nodule to the pleural surface > 20 mm, small nodule size, presence of severe emphysema, or anatomic barriers such as the scapula or a rib, which might preclude a successful transthoracic approach). We relied solely on the navigation software for guidance during the procedure. Fluoroscopy was never used during navigation or while obtaining biopsy specimens. All patients signed a consent form approved by the institutional review board.

The details of ENB and procedure planning have been described elsewhere.<sup>12</sup> superDimension's inReach system consists of four key elements: an electromagnetic field; a steerable, locatable guide; an extended working channel; and procedure-planning software. A therapeutic, flexible video bronchoscope with a 2.8-mm

working channel was used in all procedures (Pentax Inc; Tokyo, Japan). All patients underwent ENB under conscious sedation with a combination of midazolam (mean dose 5 mg) and fentanyl (mean dose 75 µg). Patients undergoing ENB were not intubated but continued breathing spontaneously throughout the procedure (mean procedure duration 56 min). Procedure planning and registration of virtual reference points were performed on a satellite console using CT imaging data in Digital Imaging and Communications in Medicine format. Tissue samples were obtained by alternating a cytology needle and biopsy forceps with rapid onsite cytopathology assessment.

### Planning CT Scan

Scanning was performed in a single breath-hold at full inspiration after hyperventilation using a four-row multidetector scanner (Somatom Volume Zoom; Siemens Medical Systems; Erlangen, Germany). Low-dose CT imaging parameters were employed whenever possible (120 kVp, 20 mAs). Patients were examined in the supine position and slices were obtained contiguously from the thoracic inlet to the adrenal glands with or without the use of IV contrast material. From the raw data, 2-mm-thick sections at 1-mm intervals were reconstructed with a soft tissue algorithm (B30f).

### Statistical Analysis

Statistical analysis was performed using SPSS, version 15, software (SPSS Inc; Chicago, IL) and verified by a commercial university-affiliated partner. Categorical variables are presented as numbers and percentages, and continuous variables are presented as means ± SD or medians (25% to 75% percentile or interquartile range). Univariate analysis was performed using contingency tables and Fisher exact test for categorical variables, and nonparametric testing using the Mann-Whitney *U* test for continuous variables. Only those variables found to be statistically significant on univariate analysis were included in the multiple linear regression analysis (nodule size and the presence of a bronchus sign). *P* < .05 was considered statistically significant.

## RESULTS

Fifty-one patients (37 men and 14 women) participated in the study, with a mean age of 62 ± 12 years. Thirty-one percent had a history of cancer, and 45% were active smokers. Only 16% had a history of COPD. The median size of the pulmonary nodules biopsied was 2.5 cm (1.5-3.5 cm), and the median standard uptake on PET-CT scan, quantified as maximal standard uptake value, was 4.9 (2.8-7.8). The median distance of the nodules to the pleural surface was 11 mm (2-21 mm), and a bronchus sign was identified in 38 cases (74%) on the preprocedure planning CT scan. The majority of nodules (61% [31/51]) were located in the upper lobes, 12% (6/51) in the middle lobe or lingula, and 23% (12/51) in the lower lobes. Two nodules were either close to the hilar region or near the mediastinum. The median divergence between virtual and actual registration points was 4 mm (3.7-5 mm), and the minimum median distance from the tip of the locatable guide to the center of the nodule was 8 mm (4-9 mm).

Manuscript received November 25, 2009; revision accepted February 17, 2010.

**Affiliations:** From the Pulmonary Department (Drs. Seijo, de Torres, and Zulueta, and Ms Lacunza), the Department of Pathology (Dr Lozano), and the Department of Radiology (Dr Bastarrika), Clínica Universidad de Navarra, Universidad de Navarra, Pamplona, Spain.

**Correspondence to:** Luis M. Seijo, Departamento de Neumología, Clínica Universitaria de Navarra, Avda. Pío XII, 36, Pamplona, Spain 31008; e-mail: lmseijo@unav.es

© 2010 American College of Chest Physicians. Reproduction of this article is prohibited without written permission from the American College of Chest Physicians (<http://www.chestpubs.org/site/misc/reprints.xhtml>).

DOI: 10.1378/chest.09-2708

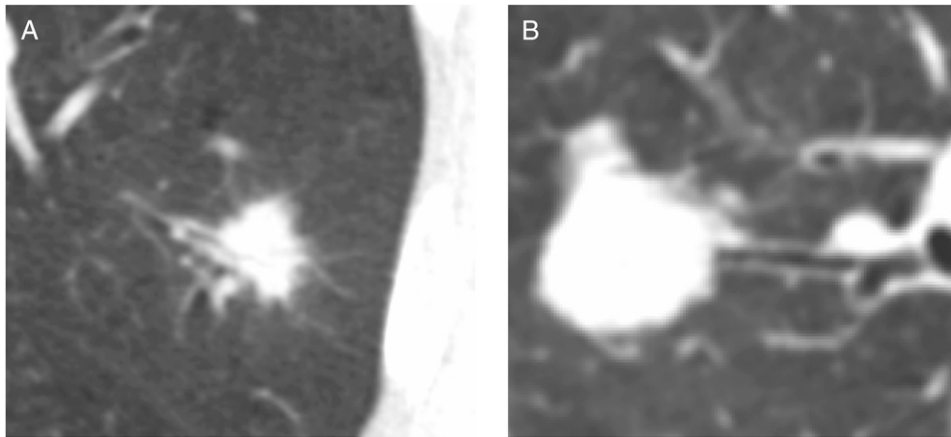


FIGURE 1. A, Bronchus sign in a patient with a pulmonary adenocarcinoma diagnosed by electromagnetic navigation bronchoscopy (ENB). B, Magnified CT image of a pulmonary nodule with a visible bronchus sign. ENB was also diagnostic in this case.

The diagnostic yield of ENB in the study population was 67% (34/51 bronchoscopies were diagnostic of 20 non-small cell carcinomas, two carcinoid tumors, four metastatic nodules, three cases of TB, one bronchiolitis obliterans, two abscesses, one bronchogenic cyst, and one case of focal fibrosis). Nondiagnostic cases prompted additional procedures, including five TTNA, four surgical biopsies, one repeat bronchoscopy, and one upper esophageal endoscopy to diagnose 11 patients (seven non-small cell carcinomas, one small cell carcinoma, one atypical hyperplasia, and two cases of TB). Five high-risk patients underwent CT imaging at follow-up. In two cases in which ENB-guided biopsy was inconclusive, the nodules disappeared during follow-up, one patient had no growth on CT imaging, and two patients had progression on CT imaging. One patient was lost to follow-up. Mild hypoxemia, which did not require termination

of the procedure, was noted in four patients (8%). No significant bleeding was reported, and no procedure-related pneumothoraces occurred.

Univariate analysis is reported in Table 2. Multivariate analysis identified the presence of a bronchus sign ( $P = .005$ ) as the only variable conditioning ENB diagnostic yield with an OR of 7.6 (95% CI, 1.8-31.7). ENB obtained a diagnosis in 79% (30/38) of cases in which a bronchus sign was identified during pre-procedure planning, but only in 31% (4/13) without an identifiable bronchus sign (Fig 2).

## DISCUSSION

The diagnostic yield of ENB reported in our study is in consonance with published data. In general, ENB yields do not exceed 67% to 74%.<sup>8-11</sup> One study comparing ENB with radial endobronchial ultrasound probe-guided navigation showed an even lower yield of 60%, although the combination of both techniques obtained a diagnosis in 88% of patients.<sup>8</sup> In that study, ENB biopsies using only forceps without fluoroscopic guidance were diagnostic in only 29% of cases when the nodule was located in the lower lobes. This pitfall of ENB is directly related to diaphragmatic excursion, because respiratory gating is not possible with ENB, and may be an indication for combined ENB and fluoroscopic guidance, which was routinely used in prior studies.<sup>13</sup> Another prospective study from the Cleveland Clinic combining ENB and fluoroscopy reported better results with a 74% diagnostic rate,<sup>9</sup> whereas the largest study published to date reported a 70% diagnostic yield of ENB in 248 patients.<sup>11</sup>

Although TTNA yields are better (64%-97%), this technique is associated with greater morbidity.<sup>14</sup> Another publication confirms the excellent results

**Table 1—Patient, Nodule, and Procedure Characteristics**

No. patients	51
Age, y	62 ± 11
Gender, M (F)	37 (14)
Nodule size, cm	2.5 (1.5-3.5)
Nodule location	
Upper lobes	31
Middle lobe and lingula	6
Lower lobes	12
Hilar or mediastinal	2
Nodule FDG uptake, SUV <sub>m</sub>	4.9 (2.8-7.8)
Distance to pleura, mm	11 (2-21)
Bronchus sign, No. (%)	38/51 (74)
Divergence, mm	4.0 (3.7-5)
Minimum distance, mm	8 (4-9)
Diagnostic yield, %	67

Data are presented as counts, counts and percentages, mean ± SD, or median (25-75 percentile). FDG = fluorodeoxyglucose; SUV<sub>m</sub> = maximal standard uptake value.

**Table 2—Variables Conditioning Electromagnetic Navigation Bronchoscopy Diagnostic Yield: Univariate Analysis**

Variable	Diagnostic (n = 34)	Nondiagnostic (n = 17)	P Value
Bronchus sign <sup>a</sup> , No. (%)	30 (88)	8 (47)	.005
Size, <sup>b</sup> cm	2.6 (2-3.3)	1.9 (1.4-2.5)	.04
Distance to pleura, <sup>b</sup> mm	10 (2-19)	17.5 (1.5-30)	.25
Location, <sup>a</sup> upper lobe (nonupper lobe)	19 (15)	12 (5)	.37
Uptake on PET-CT scan <sup>b</sup>	5.2 (3.2-7.8)	4.5 (2.2-7.4)	.54
Distance to nodule, <sup>b</sup> mm	8 (4-9)	8 (4-8)	.54
Divergence, <sup>b</sup> mm	4.0 (3.7-5)	4.0 (3.6-5.1)	.72
Definitive diagnosis, <sup>a</sup> benign (malignant)	9 (25)	5 (10)	.74

Data are presented as counts, counts and percentages, or median (25-75 percentile).


<sup>a</sup>Fisher exact test.

<sup>b</sup>Mann-Whitney *U* test.

obtained with needle aspiration in a cohort of patients with relatively large nodules with a mean diameter > 3 cm, but the incidence of pneumothorax was 27%.<sup>15</sup> In addition, significant bleeding occurred in 3% of the cases. The risk of pneumothorax with TTNA is 11 times greater if the nodule measures < 2 cm, or four times greater if the distance from the lesion to the pleural space is > 20 mm.<sup>5</sup> ENB appears much safer because the risk of bleeding is negligible, and that of pneumothorax has been reported to be 3% to 5%. These data make ENB especially attractive in high-risk patients.<sup>8,9</sup> Neither pneumothorax nor bleeding were seen in our study, although at our center, the risk of pneumothorax with ENB has been 4% overall. Side effects common to ENB procedures

include chest and/or throat pain and nausea, all of which are probably related to the anesthesia or orotracheal intubation.<sup>9</sup> We perform all our ENB procedures under conscious sedation rather than general anesthesia and have not seen untoward effects beyond those common to bronchoscopy in general.

Historically, navigation during ENB is successful in 90% of cases, yet the overall diagnostic yield remains a comparatively frustrating 70%.<sup>11</sup> Despite this well-known discrepancy, few authors have sought to identify prospectively those variables that condition diagnostic yield of ENB, and none, to our knowledge, have considered the bronchus sign as a key variable. Cost is an issue with ENB because locatable guides and extended working channels are single use only.



**FIGURE 2.** Sequential 2-mm slices from an ENB planning CT scan. In this case, no bronchus sign was identified. The nearest airway is highlighted by the white arrow. Despite successful navigation, ENB was not diagnostic. See Figure 1 legend for expansion of abbreviation.



The radial endobronchial ultrasound probe, on the other hand, can be reused as many as 100 times, thereby reducing procedural costs. Cost containment would therefore compel us to identify those patients who might not benefit from ENB. We have already mentioned location as a potentially significant variable because nodules close to the diaphragm or fissures demonstrate respiratory excursion, which is hard to compensate for with static data obtained from a CT scan.<sup>8</sup> We did not find location to be statistically significant, although it has been reported in other studies.<sup>8</sup> Divergence and the distance from the locatable guide to the nodule were not significant either, although this finding is misleading because we seek to keep both to a minimum during the procedure in order to maximize yields. At our center, we will not proceed with ENB-guided biopsies unless we can keep divergence below 6 mm and the distance to the nodule under 2 cm. Larger studies might show that relatively small fluctuations in either variable might be relevant. Counter to this argument are the results of the study by Gildea et al<sup>9</sup>, which found no significant differences despite a rather large mean divergence of  $6.6 \pm 2.1$  mm.

The results of prospective studies using various diagnostic techniques, including transbronchial needle aspiration and fluoroscopy, confirm the importance of the bronchus sign for any endobronchial approach.<sup>16,17</sup> In our study, the diagnostic yield of ENB in patients with a bronchus sign identified on the planning CT scan was remarkably high (79%) and approximates the rate of navigation success. We believe this sign is a key variable conditioning overall ENB diagnostic yield and may account, in part, for the discrepancy between successful navigation (90%) and diagnostic rates (70%). It is conceivable that reaching the immediate vicinity of a nodule with a locatable guide is not enough to obtain a diagnosis, especially if the relationship between the bronchus and the lesion is tangential because either the forceps or the needle will tend to follow the trajectory of the airway. Published data using radial ultrasound probes to reach and biopsy lung nodules support this reasoning. In a study by Herth et al,<sup>18</sup> navigation with a radial endobronchial ultrasound probe was successful in 89% (48/54) of the cases, but a diagnosis was obtained in only 70% (38/54). In a Japanese study using a radial ultrasound probe, the diagnostic yield overall was 67%. In that study, diagnostic success depended on the relationship between the airway, the nodule, and the probe. Yields were higher when the probe was situated within the nodule, rather than adjacent to it (88% vs 61%).<sup>19</sup> Diagnostic yield was extremely low when the probe did not reach the nodule (4%). The absence of a bronchus sign is no obstacle for TTNA because the needle reaches the nodule

without following an endobronchial route. Yields with this approach are understandably higher but come at the expense of more pneumothoraces.

## CONCLUSIONS

Our study suggests that the bronchus sign may be the key variable determining the diagnostic yield of ENB, independent of navigation success, nodule size, or location. A diagnosis with ENB appears to be eight times more likely in patients with an identifiable bronchus sign on CT imaging. Procedural costs related to ENB warrant careful consideration of alternative diagnostic procedures when a bronchus sign is absent in a given patient. The cost of ENB may not be justified even in patients with large masses, in the absence of a bronchus sign. Future randomized studies comparing diagnostic yields of ENB and conventional bronchoscopy in patients with an identifiable bronchus sign might help clarify the role of ENB in the bronchoscopic approach to pulmonary nodules.

## ACKNOWLEDGMENTS

**Author contributions:** *Dr Seijo*: contributed to the writing of the manuscript and is the corresponding and principal author.

*Dr de Torres*: contributed to the writing of the manuscript and statistical analysis.

*Dr Lozano*: contributed to the evaluation of all cytology and pathology samples, providing rapid onsite evaluation in all cases.

*Dr Bastarrika*: contributed to the provision and review of all CT imaging data and the review of all cases referred for TTNA.

*Dr Alcaide*: contributed to the writing of the manuscript and statistical analysis.

*Ms Lacunza*: contributed to electromagnetic navigation bronchoscopy, all procedures, and data collection.

*Dr Zulueta*: contributed to the writing of the manuscript and statistical analysis.

**Financial/nonfinancial disclosures:** The authors have reported to *CHEST* the following conflicts of interest: Dr Seijo has received <5000 Euros in professional fees for directing several training courses in electromagnetic navigation bronchoscopy and is a nonpaid member of the superDimension, Inc European Scientific Advisory Committee. Dr Zulueta is shareholder of VisionGate, Inc. Drs de Torres, Alcaide, Lozano, and Bastarrika, and Ms Lacunza have reported that no potential conflicts of interest exist with any companies/organizations whose products or services may be discussed in this article.

## REFERENCES

1. Baaklini WA, Reinoso MA, Gorin AB, Sharafkaneh A, Manian P. Diagnostic yield of fiberoptic bronchoscopy in evaluating solitary pulmonary nodules. *Chest*. 2000;117(4):1049-1054.
2. Cortese DA, McDougall JC. Biopsy and brushing of peripheral lung cancer with fluoroscopic guidance. *Chest*. 1979; 75(2):141-145.
3. Chechani V. Bronchoscopic diagnosis of solitary pulmonary nodules and lung masses in the absence of endobronchial abnormality. *Chest*. 1996;109(3):620-625.
4. Levitt RG. Thin-section CT and the solitary pulmonary nodule. *Chest*. 1988;93(3):451-452.

5. Yeow KM, Su IH, Pan KT, et al. Risk factors of pneumothorax and bleeding: multivariate analysis of 660 CT-guided coaxial cutting needle lung biopsies. *Chest*. 2004;126(3):748-754.
6. Ost D, Shah R, Anasco E, et al. A randomized trial of CT fluoroscopic-guided bronchoscopy vs conventional bronchoscopy in patients with suspected lung cancer. *Chest*. 2008;134(3):507-513.
7. Shinagawa N, Yamazaki K, Onodera Y, et al. CT-guided transbronchial biopsy using an ultrathin bronchoscope with virtual bronchoscopic navigation. *Chest*. 2004;125(3):1138-1143.
8. Eberhardt R, Anantham D, Ernst A, Feller-Kopman D, Herth F. Multimodality bronchoscopic diagnosis of peripheral lung lesions: a randomized controlled trial. *Am J Respir Crit Care Med*. 2007;176(1):36-41.
9. Gildea TR, Mazzone PJ, Karnak D, Meziane M, Mehta AC. Electromagnetic navigation diagnostic bronchoscopy: a prospective study. *Am J Respir Crit Care Med*. 2006;174(9):982-989.
10. Makris D, Scherpereel A, Leroy S, et al. Electromagnetic navigation diagnostic bronchoscopy for small peripheral lung lesions. *Eur Respir J*. 2007;29(6):1187-1192.
11. Wilson DS, Bartlett RJ. Improved diagnostic yield of bronchoscopy in a community practice: combination of electromagnetic navigation system and rapid on-site evaluation. *J Bronchol*. 2007;14(4):227-232.
12. Seijo LM, Bastarrika G, Lozano MD, Zulueta JJ. Preliminary experience with the use of electromagnetic navigation for the diagnosis of peripheral pulmonary nodules and enlarged mediastinal lymph nodes [in Spanish]. *Arch Bronconeumol*. 2007;43(8):460-463.
13. Schwarz Y, Greif J, Becker HD, Ernst A, Mehta A. Real-time electromagnetic navigation bronchoscopy to peripheral lung lesions using overlaid CT images: the first human study. *Chest*. 2006;129(4):988-994.
14. Gupta S, Krishnamurthy S, Broemeling LD, et al. Small ( $\leq 2$ -cm) subpleural pulmonary lesions: short- versus long-needle-path CT-guided biopsy—comparison of diagnostic yields and complications. *Radiology*. 2005;234(2):631-637.
15. Geraghty PR, Kee ST, McFarlane G, Razavi MK, Sze DY, Dake MD. CT-guided transthoracic needle aspiration biopsy of pulmonary nodules: needle size and pneumothorax rate. *Radiology*. 2003;229(2):475-481.
16. Bilaçeroğlu S, Kumcuoğlu Z, Alper H, et al. CT bronchus sign-guided bronchoscopic multiple diagnostic procedures in carcinomatous solitary pulmonary nodules and masses. *Respiration*. 1998;65(1):49-55.
17. Haro Estarriol M, Rubio Goday M, Vizcaya Sánchez M, Baldó Padró X, Casamitjá Sot MT, Sebastian Quetglás F. Bronchoscopic lung biopsy with fluoroscopy to study 164 localized pulmonary lesions [in Spanish]. *Arch Bronconeumol*. 2004;40(11):483-488.
18. Herth FJ, Eberhardt R, Becker HD, Ernst A. Endobronchial ultrasound-guided transbronchial lung biopsy in fluoroscopically invisible solitary pulmonary nodules: a prospective trial. *Chest*. 2006;129(1):147-150.
19. Yamada N, Yamazaki K, Kurimoto N, et al. Factors related to diagnostic yield of transbronchial biopsy using endobronchial ultrasonography with a guide sheath in small peripheral pulmonary lesions. *Chest*. 2007;132(2):603-608.

**Diagnostic Yield of Electromagnetic Navigation Bronchoscopy Is Highly Dependent on the Presence of a Bronchus Sign on CT Imaging : Results From a Prospective Study**

Luis M. Seijo, Juan P. de Torres, María D. Lozano, Gorka Bastarrika, Ana B. Alcaide, Maria M. Lacunza and Javier J. Zulueta  
*Chest* 2010;138; 1316-1321; Prepublished online April 30, 2010;  
DOI 10.1378/chest.09-2708

**This information is current as of June 2, 2012**

**Updated Information & Services**

Updated Information and services can be found at:  
<http://chestjournal.chestpubs.org/content/138/6/1316.full.html>

**References**

This article cites 19 articles, 15 of which can be accessed free at:  
<http://chestjournal.chestpubs.org/content/138/6/1316.full.html#ref-list-1>

**Cited By**

This article has been cited by 5 HighWire-hosted articles:  
<http://chestjournal.chestpubs.org/content/138/6/1316.full.html#related-urls>

**Permissions & Licensing**

Information about reproducing this article in parts (figures, tables) or in its entirety can be found online at:  
<http://www.chestpubs.org/site/misc/reprints.xhtml>

**Reprints**

Information about ordering reprints can be found online:  
<http://www.chestpubs.org/site/misc/reprints.xhtml>

**Citation Alerts**

Receive free e-mail alerts when new articles cite this article. To sign up, select the "Services" link to the right of the online article.

**Images in PowerPoint format**

Figures that appear in *CHEST* articles can be downloaded for teaching purposes in PowerPoint slide format. See any online figure for directions.

A M E R I C A N C O L L E G E O F



**C H E S T**

P H Y S I C I A N S<sup>®</sup>