

PRACTITIONER'S CORNER

Cold Urticaria: its Importance in the Operating Room

JM De la Borbolla,¹ S Tapias,² C Mbongo,² A Lafuente,² G Gastaminza¹

¹*Department of Allergology and Clinical Immunology, Clínica Universidad de Navarra, Pamplona, Spain*

²*Department of Anaesthetics, Clínica Universidad de Navarra, Pamplona, Spain*

Key words: Cold urticaria. General anesthesia. Allergy.

Palabras clave: Urticaria a frigore. Anestesia general. Alergia.

Cold urticaria is one of the least common types of urticaria, affecting approximately 1% to 3% of all patients with urticaria [1]. Patients present generalized or local wheal lesions in areas that come into contact with cold stimuli such as cold air, water, or objects. The symptoms may or may not be accompanied by angioedema. Cold urticaria can be primary or associated with other pathologies such as cryoglobulinemia, infections, leukocytoclastic vasculitis, or neoplasia.

The greatest risk with this kind of urticaria is the development of a systemic reaction resulting in hemodynamic collapse during generalized cold exposure (eg, swimming in the sea or a swimming pool).

We report the case of an 82-year-old man with a background of allergy to penicillin. The patient had been scheduled for aortic endoprosthesis implantation to treat an aortic aneurysm. On the day of surgery, he was premedicated with 2 mg of midazolam in a saline solution with no additives. Some minutes later, he was transferred to the operating room and the saline solution was infused again. He immediately presented erythema and itching in the perfusion area on the left arm, following the outline of the veins. The peripheral catheter was consequently removed and placed in the right arm, but the same reaction appeared after infusion of the saline solution. The nurse had used sterile latex gloves to place the catheter.

Methylprednisolone 125 mg and a vial of dexchlorpheniramine were administered, and the symptoms yielded. Nevertheless, when the saline solution was infused again, the symptoms returned, and surgery was stopped.

In the allergy study, skin tests to latex, which was considered a possible triggering factor, were negative, as were prick and intradermal tests to midazolam. An ice cube test was performed by placing an ice cube covered with parafilm on the patient's forearm for 10 minutes, with readings taken at 5 and 20 minutes. A positive wheal of 35x30 mm exceeding the limits of the ice cube was observed after 20 minutes. At this time, the patient reported having experienced on other

occasions symptoms of acute urticaria after contact with cold water, with no other symptoms

Surgery was rescheduled for the next day. The temperature in the operating room was increased and the sera were heated. Corticosteroid and antihistamine premedication was administered, and the operation was performed without complications. The administration of midazolam was avoided.

Allergic reactions to the drugs used in anesthesia are a frequent cause of morbidity in the operating room. We report the case of a patient who experienced a skin reaction before the administration of anesthetics. Once latex allergy had been ruled out as a possible trigger, the patient was questioned again about his history, and he reported reactions compatible with cold urticaria. This is a rare form of allergy in the operating room, where the temperature is usually 19°C to 21°C [2], but patients can sometimes present hypothermia symptoms before the beginning of surgery. Data about the temperature of solutions administered to patients are not available, but solutions administered during surgery are usually cold, since in most cases they are at the same temperature as the room and are not heated before being infused into the patient. Consequently, they can cause reactions such as that experienced by our patient.

Avoidance of exposure to cold is the most important prevention measure and in patients in whom symptoms are frequent, the administration of antihistamines is common [3]. For patients with an insufficient response to antihistamines, antileukotrienes [4] or even an anti-immunoglobulin E monoclonal antibody (omalizumab) [5] should be considered.

References

1. Buss YL, Sticherling M. Cold urticaria; disease course and outcome—an investigation of 85 patients before and after therapy. *Br J Dermatol*. 2005. 153(2): 440-1.
2. Wang CS, Chen CL, Huang CJ, Cheng KW, Chen KH, Wang CC, Concejero AM, Cheng YF, Huang TL, Wang SH, Lin CC, Liu YW, Yong CC, Yang CH, Jawan B. Effects of different operating room temperatures on the body temperature undergoing live liver donor hepatectomy. *Transplant Proc*. 2008. 40(8): 2463-5.
3. Siebenhaar F, Weller K, Mlynek A, Magerl M, Altrichter S, Vieira dos Santos R, Maurer M, Zuberbier T. Acquired cold urticaria: clinical picture and update on diagnosis and treatment. *Clin Exp Dermatology*, 32, 241-5.
4. Bonadonna P, Lombardi C, Senna G, Canonica GW, Passalacqua G. Treatment of acquired cold urticaria with cetirizine and zafirlukast in combination. *J Am Acad Dermatol*. 2003. 49(4): 714-6.
5. Boyce JA. Successful treatment of cold-induced urticaria/anaphylaxis with anti-IgE. *J Allergy Clin Immunol*. 2006. 117(6): 1415-8.

■ Manuscript received December 16, 2009; accepted for publication, March 25, 2010.

Gabriel Gastaminza

Departamento de Alergología e
Inmunología Clínica
Clínica Universidad de Navarra
Pamplona, Spain
E-mail: gastaminza@unav.es

Desensitization Protocol Administered Successfully With Interferon- α 2a in a Child With Chronic Hepatitis B Infection

M Kilic,¹ Y Dogan,² E Taskin,³ Y Sen,⁴ AF Kalpaklioglu⁵
¹Department of Paediatric Allergy and Immunology, Firat University, Faculty of Medicine, Elazığ, Turkey
²Department of Paediatric Gastroenterology and Metabolism, Firat University, Faculty of Medicine, Elazığ, Turkey
³Department of Paediatric Neonatology, Firat University, Faculty of Medicine, Elazığ, Turkey
⁴Department of Paediatric Endocrinology, Firat University, Faculty of Medicine, Elazığ, Turkey
⁵Department of Pulmonary Diseases, Kirikkale University, Faculty of Medicine, Kirikkale, Turkey

Key words: Chronic Hepatitis B. Interferon- α . Children. Desensitization. Drug allergy.

Palabras clave: Hepatitis B crónica, Interferon- α . Niños, Desensibilización, Alergia a medicamentos.

Interferon (IFN) α is used worldwide for the treatment of chronic hepatitis B (CHB) infection, and acute adverse effects during treatment are very common [1,2]. Dermatological effects include urticaria and angioedema. It has been demonstrated that the allergic reactions that appear during treatment can involve both immunoglobulin (Ig) E-mediated and non-IgE-mediated mechanisms [3,4]. We present a case where desensitization was successfully performed with IFN α -2a in a child with CHB.

A 3-year-old boy diagnosed with CHB was initiated on IFN α -2a treatment and developed angioedema and urticaria 10 hours after receiving the second dose. He was not on any other medication at the time. The treatment was discontinued and the lesions disappeared within 18 to 20 hours. INF α -2a treatment was re-administered using the same dosage 2 days later and the same lesions reappeared. The treatment was interrupted again, this time for a 2-week period, after which it was decided to start treatment with IFN α -2b. However, the patient developed angioedema and urticaria 10 to 12 hours after the first dose, leading to a suspicion of allergy to IFN- α . The drug was immediately stopped and the lesions disappeared without relapse in 12 to 18 hours. The patient underwent a skin prick test followed by an intradermal test with IFN α -2a and IFN α -2b, with no late or early reactions observed in any of the tests. The desensitization protocol shown in the Table

was carried out with IFN α -2a. No reactions were observed on the first day. On the second day, the patient developed angioedema and urticaria 8 to 10 hours after administration of the 0.5 mL injection with 2 MIU/mL solution. The patient was given a single dose of antihistamine and the lesions disappeared without relapse 8 to 10 hours later. On the third day of desensitization, 0.2 mL of 2 MIU/mL dilution was administered to the patient by going 2 steps back from the previous dose. Except for the reaction that developed on the second day, no other reactions were observed and the desensitization protocol was successfully completed. Subsequently, IFN α treatment was maintained continuously with 6 MIU/m²/dose 3 days a week. No further reactions were observed during a 100-day follow-up period.

Desensitization is a process that aims to remove IgE-induced sensitivity to a particular drug when there is no alternative treatment. Although the term desensitization is generally limited to IgE-mediated reactions, it also describes the nonresponsive condition that occurs as a result of repeated and ever-increasing encounters with a drug. It can also include delayed-type, non-IgE-mediated reactions [5,6]. There are a limited number of studies reporting the successful application of desensitization in adults with IFN allergy. Kalpaklioglu et al [7] successfully implemented a desensitization process with IFN β -1a in a 41-year-old patient, as did Taghavi et al [8] with IFN α -2b in a 65-year-old patient. The skin tests for IFN were positive in both cases. Ours is the first case in the literature that describes the successful application of a desensitization protocol with IFN α -2a in childhood. No early or late reactions with either IFN α -2a or IFN α -2b were detected in either the

Table. Desensitization Protocol for Interferon α -2a^a

Day	Dilution	Amount, mL	Drug dose, MIU ^b
1	1 MIU/mL		
	1/1 000 000	0.5	0.5
	1/100 000	0.5	5
	1/10 000	0.5	50
	1/1 000	0.5	500
	1/100	0.5	5000
	1/10	0.5	50 000
	1/1	0.1	100 000
			Total dose=0.155 MIU
2	1 MIU/mL	0.1	100 000
	2 MIU/mL	0.1	200 000
		0.2	400 000
		0.4	800 000
		0.5	1 000 000
			Total dose=2.5 MIU
3	4.5 MIU/0.5mL	0.1	900 000
		0.2	1 800 000
			Total dose=2.7 MIU
4	4.5 MIU/0.5mL	0.44	4 000 000
			Total dose=4 MIU

Abbreviations: MIU, million international units.

^aPatient's weight: 16 kg (0.67 m²).

^bInjections were administered subcutaneously at 30-minute intervals.

skin prick or intradermal tests in our patient. Although skin tests performed with IFN α have not yet been completely standardized, we considered a non-IgE mediated reaction against IFN α in our patient. The young age of the patient may partly explain the negative skin test with IFN α . However, it has been reported that desensitization can be successfully applied in non-IgE mediated drug reactions [9].

In the present study, we successfully applied a desensitization protocol with IFN α -2a in a child. We believe that IFN α desensitization should be considered in diseases in which there is no alternative treatment.

References

1. Yeung LT, Roberts EA, Current issues in the management of paediatric viral hepatitis. *Liver Int.* 2009 Oct 19. [Epub ahead of print].
2. Wilt TJ, Shamliyan T, Shaikat A, Taylor BC, MacDonald R, Yuan JM, Johnson JR, Tacklind J, Rutks I, Kane RL. Management of chronic hepatitis B. *Evid Rep Technol Assess.* 2008; 174:1-671.
3. Kirkwood JM, Bender C, Agarwala S, Tarhini A, Shipe-Spotloe J, Smelko B, Donnelly S, Stover L. Mechanisms and management of toxicities associated with high-dose interferon alfa-2b therapy. *J Clin Oncol.* 2002; 20:3703-18.
4. Beckman DB, Mathisen TL, Harris KE, Boxer MB, Grammer LC. Hypersensitivity to IFN-alpha. *Allergy.* 2001; 56 :806-7.
5. Solensky R, Drug desensitization. *Immunol Allergy Clin North Am* 2004; 24: 425-43.
6. Greenberger PA. Drug challenge and desensitization protocols. *Immunol Allergy Clin North Am* 1998; 18: 759-71.
7. Kalpaklioglu AF, Baccioglu Kavut A, Erdemoglu AK. Desensitization in Interferon-1a Allergy: A Case Report. *Int Arch Allergy Immunol* 2009;149:178-80.
8. Taghavi SA, Eshraghian A. Successful interferon desensitization in a patient with chronic hepatitis C infection. *World J Gastroenterol* 2009; 33 : 4196-8.
9. Castells M. Desensitization for drug allergy. *Curr Opin Allergy Clin Immunol*, 2006; 6 :476-81.

■ Manuscript received, December 26, 2009; accepted for publication, March 31, 2010.

Mehmet Kilic

Fırat Üniversitesi Tıp Fakültesi
Çocuk Salı ve Hastalıkları AD
23119 Elazığ, Turkey
E-mail: drmkilic@gmail.com

Omalizumab: A Potential New Therapeutic Approach for Aspirin-Exacerbated Respiratory Disease

I Bobolea,¹ P Barranco,¹ A Fiandor,¹ R Cabañas,¹ S Quirce^{1,2}
¹Allergy Department, Hospital Universitario La Paz, Madrid, Spain

²Spanish Network of Centers for Biomedical Research on Respiratory Diseases (CibeRes), Spain

Key words: Omalizumab. Aspirin. Asthma. Nasal polyps. Aspirin-exacerbated respiratory disease.

Palabras clave: Omalizumab. Aspirina. Asma. Poliposis nasal. Enfermedad respiratoria exacerbada por aspirina (EREA).

Patients with aspirin-exacerbated respiratory disease (AERD) have chronic rhinosinusitis, recurrent nasal polyposis, and persistent asthma. Aspirin desensitization is currently the only procedure that has proven successful in stopping the natural course of this disease; it prevents regrowth of nasal polypoid tissue, achieves better asthma control, and allows the patient to take any cyclooxygenase-1 (COX-1) inhibitor [1].

Omalizumab, a humanized recombinant monoclonal antibody that blocks the binding of immunoglobulin (Ig) E to its high-affinity Fc receptor, is approved for the treatment of moderate to severe persistent allergic asthma, but off-label uses have also been reported and include food allergy, atopic dermatitis, chronic urticaria, mastocytosis, anaphylaxis [2,3], allergic bronchopulmonary aspergillosis [4], and more recently refractory chronic rhinosinusitis and recurrent nasal polyps [5,6].

We report on an 18-year-old woman, initially diagnosed with seasonal rhinoconjunctivitis and asthma due to sensitization to grass pollen at the age of 10. In 2008, during a follow-up visit at our clinic, she reported the typical onset of AERD: a viral cold followed by persistent rhinitis (nasal obstruction, progressive hyposmia), difficult-to-control asthma, and 3 episodes of severe bronchoconstriction after taking ibuprofen 600 mg (twice) and paracetamol 1 g [5].

A methacholine inhalation test was performed and resulted positive (0.94 mg/mL of methacholine required to cause a 20% decrease in forced expiratory volume in the first second [FEV₁] from baseline [PC₂₀]). To confirm the diagnosis of AERD, challenge tests with aspirin were programmed but could not be performed due to the unstable asthma (despite continuous treatment with salmeterol/fluticasone 50/250 μ g twice a day, montelukast 10 mg/day, and various cycles of systemic corticosteroids) and a FEV₁ of 65% of predicted. For the same reason, it was not possible to try alternative analgesics such as COX-2 inhibitors. The patient had to take tramadol for the severe headaches she experienced due to her chronic rhinosinusitis. Polyps were also diagnosed in 2008, when the patient underwent bilateral endoscopic sinus surgery, with histological evidence of eosinophilic nasal polyposis.

In June 2009, she was prescribed omalizumab 225 mg every 2 weeks (total serum IgE 403 IU/mL, body weight, 48 kg) to treat persistent severe asthma symptoms.

Within the first month of treatment the patient experienced an

improvement in nasal symptoms (congestion and rhinorrhea, and, to a lesser extent, hyposmia); 2 months later she had also achieved better asthma control (no further need for rescue bronchodilator use and no asthma symptoms, leading to the withdrawal of inhaled corticosteroids and long-acting β_2 agonists, and a significant improvement of FEV₁ up to 90% of predicted). After 16 weeks of treatment with omalizumab, the Asthma Control Test score had risen from 11 to 25 points, and the asthma-related quality of life questionnaire (AQLQ) revealed a score of 6.8. Before starting the anti-IgE therapy, she had a severely impaired quality of life, with an AQLQ of 3.68 (>1.5 points improvement).

In September 2009, a specific bronchial challenge with lysine-acetylsalicylate yielded a negative result, and in October 2009, an oral challenge with aspirin with a cumulative dose of 750 mg was also negative. In the follow-up visit in December 2009, a certain degree of hyposmia persisted, despite continuous therapy with intranasal corticosteroids, and the methacholine test was still positive (PC₂₀ 1.84 mg/mL). The patient, however, had no asthma symptoms under treatment with montelukast and omalizumab only. She had also tolerated ibuprofen 600 mg perfectly on several occasions.

Omalizumab could prove effective in the treatment of AERD, as demonstrated by the experience of our patient, who not only succeeded in controlling the disease and significantly improving her quality of life but is also now capable of tolerating aspirin and other COX-1 inhibitors. Further studies are required in order to confirm the effectiveness of omalizumab in patients with AERD.

References

- Berges-Gimeno M, Simon RA, Stevenson DD. Treatment with aspirin desensitization in patients with aspirin exacerbated respiratory disease. *J Allergy Clin Immunol*. 2003;111:180-6.
- Incorvaia C, Mauro M, Riario-Sforza GG, Frati F, Tarantini F, Caserini M. Current and future applications of the anti-IgE antibody omalizumab. *Biologics*. 2008;2:67-73.
- Güzelbey O, Magerl M, Zuberbier T, Maurer M, Metz M. Successful treatment of solar urticaria with anti-immunoglobulin E therapy. *Allergy*. 2008;63:1563
- Kanu A, Patel K. Treatment of allergic bronchopulmonary aspergillosis (ABPA) in CF with anti-IgE antibody (omalizumab). *Pediatr Pulmonol*. 2009 ;44:516.
- Grundmann SA, Hemfort PB, Luger TA, Brehler R. Anti-IgE (omalizumab): A new therapeutic approach for chronic rhinosinusitis. *J Allergy Clin Immunol*. 2008;121:257-8
- M Guglielmo, C Gulotta, F Mancini, M Sacchi, F Tarantini. Recalcitrant Nasal Polyposis: Achievement of Total Remission Following Treatment with Omalizumab. *J Investig Allergol Clin Immunol*. 2009; 19(2): 158-66.

■ Manuscript received, March 1, 2010; accepted for publication, April 8, 2010.

Irina Bobolea
Allergy Department
Hospital Universitario La Paz
Paseo La Castellana, 261
28046 Madrid, Spain
E-mail: irinabobolea@yahoo.com

Deflazacort: A Possible Alternative in Corticosteroid Allergy

NG Sousa, E Faria, I Carrapatoso, E Almeida, L Galdes, C Chieira

Immunoallergology Department, Coimbra University Hospitals, Coimbra, Portugal

Key words: Systemic corticosteroids. Hypersensitivity. Allergy. Skin testing. Drug challenge test.

Palabras clave: Corticoides sistémicos. Hipersensibilidad. Alergia. Pruebas cutáneas. Prueba de provocación con fármacos.

While cutaneous delayed-type hypersensitivity to topical corticosteroids is common, immediate reactions to systemic corticosteroids (SC) are rare, with little more than 100 cases reported [1-3]. Anaphylaxis and other types of immediate reaction to SCs (including urticaria, angioedema, and bronchospasm) have been described [4-6]. Hydrocortisone, prednisolone, and methylprednisolone are the agents most frequently implicated [1,7,8], although hypersensitivity to dexamethasone is exceedingly rare. Not only should the corticosteroid itself be considered potentially responsible, but its specific ester, and even the excipients (especially carboxymethylcellulose), should be also be taken into account [1,9].

We retrospectively studied all patients attending the drug allergy clinic at Coimbra University Hospitals in the last 10 years with an immediate reaction to SCs and positive skin test results. Clinical records were consulted to obtain information on concomitant medication, timing of administration, the reaction, and treatment. Skin prick tests (SPT) to parenteral dexamethasone, methylprednisolone, hydrocortisone, prednisolone, and latex had been performed using an undiluted formulation.

If the SPT results were negative, intradermal tests (IDT) to the same SC were performed in 10-fold increasing concentrations (0.002 mg/dL, 0.02 mg/dL, 0.2 mg/dL). Ten atopic volunteers (controls) also underwent the same skin tests. Specific immunoglobulin (Ig) E to methylprednisolone (PhadiaTM, Uppsala, Sweden) was determined in the most recent reactions (patients 3 and 6).

All patients gave their informed consent to undergo an oral challenge test with deflazacort (cumulative dose, 60 mg). Dexamethasone was also tested in patients 3 and 5.

Six patients (4 women/2 men, mean [SD] age 48.2 [13.6] y) were evaluated. All had been administered the suspect SC intravenously. All SPTs to latex were negative. The results are summarized in the Table.

All atopic controls had negative skin test results. Specific IgE to methylprednisolone was positive in patient 3 (1.6 kU_A/L). The challenge test with deflazacort was negative in all patients; the challenge test with dexamethasone was positive in patient 5.

Although the most frequent manifestations were cutaneous, life-threatening anaphylaxis with hypotension

Table. Population and Skin Test Results

Patient	Signs and Symptoms	SC Implicated	Time From Reaction to Skin Tests, y	Skin Tests				Associated Condition
				D	MP	H	P	
1	Bronchospasm	MP	6	SPT (-) IDT (-)	SPT (-) IDT (+) (0.002 mg/dL)	SPT (-) IDT (-)	SPT (-) IDT (ND)	Atopic asthma
2	Bronchospasm	P	13	SPT (-) IDT (ND)	SPT (-) IDT (-)	SPT (-) IDT (ND)	SPT (-) IDT (+) (0.002 mg/dL)	AERD
3	1st episode: U, AE, hypotension	H	2 months	SPT (-) IDT (-)	SPT (+) IDT (ND)	SPT (+)	SPT (+)	
4	1st episode: U 2nd episode: bronchospasm, anaphylactic shock	1st, MP 2nd, P	7	SPT (-) IDT (-)	SPT (-) IDT (+) (0.002 mg/dL)	SPT (-) IDT (+) (0.2 mg/dL)	SPT (-) IDT (ND)	AERD
5	Anaphylactic	MP	13	SPT (-) IDT (-)	SPT (-) IDT (+) (0.02 mg/dL)	SPT (-) IDT (-)	SPT (-) IDT (-)	Atopic asthma
6	Bronchospasm	P	3	SPT (-) IDT (-)	SPT (-) IDT (+) (0.2 mg/dL)	SPT (-) IDT (-)	SPT (-) IDT (-) (0.02 mg/dL)	Atopic asthma

Abbreviations: AE, angioedema; AERD, aspirin-exacerbated respiratory disease; D, dexamethasone; H, hydrocortisone; IDT, intradermal test; SC, systemic corticosteroid; MP, methylprednisolone; P, prednisolone; SPT, skin prick test; U, urticaria.

occur in 2 patients. Latex allergy and concomitant drug hypersensitivity were ruled out in all participants. In contrast to the results of previous reports [1,7], hypersensitivity attributed to hydrocortisone was rare, and both methylprednisolone and prednisolone were the most commonly implicated SCs in 3 out of 6 patients each. This may be related to the generalized use of these SCs in our hospital.

The literature associates intravenous administration with a higher frequency of hypersensitivity reaction [1]. Our results support this association, as the drugs were administered intravenously in all patients.

Consistent with the findings of other studies, the positive skin test results we observed point to an IgE-mediated reaction [1,3,8].

In our population, 3 out of 6 patients were sensitized to 2 or more corticosteroids, suggesting cross-reactivity. This has also been observed by some authors [2,8,10], but not by others [1].

Deflazacort was well tolerated in all cases, thus proving to be a viable alternative. Similar results have been reported elsewhere [8,10]. The results of skin tests to dexamethasone were negative, suggesting that it may be an appropriate parenteral option, although the result of challenge testing was positive in a patient with a negative skin test result.

Asthma and renal transplant have been identified as risk factors for hypersensitivity to SCs [7]. This is supported in our series, as 5 out of 6 patients were asthmatics.

In conclusion, although rare, immediate reactions to SCs

can be life-threatening. Both IgE-mediated and non-IgE-mediated mechanisms have to be considered, and skin tests can be a valuable ally in the workup. Cross-reactivity can occur between different corticosteroids. Finally, deflazacort seems to be a viable alternative in patients who experience hypersensitivity reaction to SCs.

References

- Venturini M, Lobera T, del Pozo MD, González I, Blasco A. Immediate hypersensitivity to corticosteroids. *J Invest Allergol Clin Immunol*. 2006;16:51-6.
- Burgdorff T, Venelmalm L, Vogt T, Landthaler M, Stolz W. IgE-mediated anaphylactic reaction induced by succinate ester of methylprednisolone. *Ann Allergy Asthma Immunol*. 2002;89:425-8.
- Karsh J, Yang WH. An anaphylactic reaction to intra-articular triamcinolone: a case report and review of the literature. *Ann Allergy Asthma Immunol*. 2003;90:254-8.
- Sams WM, Smith JG Jr. Contact dermatitis due to hydrocortisone ointment: report of a case of sensitivity to emulsifying agents in a hydrophilic ointment base. *J Am Med Assoc*. 1957;164:1212-3.
- Sheth A, Reddymasu S, Jackson R. Worsening of asthma with systemic corticosteroids: a case report and review of literature. *J Gen Intern Med*. 2006;21:C11-3.
- Partridge MR, Gibson GJ. Adverse bronchial reactions to

- intravenous hydrocortisone in two aspirin-sensitive asthmatic patients. *Br Med J*. 1978;1:1521-2.
7. Kamm GL, Hagmeyer KO. Allergic-type reactions to corticosteroids. *Ann Pharmacother*. 1999;33:451-60.
 8. Rodrigues-Alves R, Spinola-Santos A, Pedro E, Branco-Ferreira M, Pereira-Barbosa M. Immediate hypersensitivity to corticosteroids: finding an alternative. *J Investig Allergol Clin Immunol*. 2007;17:277-85.
 9. Beaudouin E, Kanny G, Gueant JL, Moneret-Vautrin DA. Anaphylaxis caused by carboxymethylcellulose: report of 2 cases of shock from injectable corticoids. *Allerg Immunol*. 1992;24:333-5.
 10. Ventura MT, Calogiuri GF, Matino MG, Dagnello M, Buquicchio R, Foti C, Di Corato R. Alternative glucocorticoids for use in cases of adverse reaction to systemic glucocorticoids: a study on 10 patients. *Br J Dermatol*. 2003;148:139-41.

■ Manuscript received December 19, 2009; accepted for publication February 24, 2010.

Nuno Alexandre Gaspar de Sousa
 Immunoallergy Department,
 Coimbra University Hospitals
 Praceta Mota Pinto
 3000-075 Coimbra, Portugal
 E-mail: nunogasparsousa@gmail.com

Omalizumab in Severe Allergic Asthma: Efficacy Assessment by Comparison of Symptom Score and Peak Expiratory Flow Values Before and After Therapy

G Kourtis,¹ AS Rucco,¹ F Loconte,¹ MF Caiaffa,² L Macchia¹

¹Department of Allergology and Clinical Immunology, University of Bari, Bari, Italy

²Department of Allergology and Clinical Immunology, University of Foggia, Foggia, Italy

Key words: Severe asthma. Asthma management. Monoclonal antibody therapy. Monitoring. Visual pattern recognition.

Palabras clave: Asma grave. Tratamiento de asma. Terapia con anticuerpos monoclonales. Monitorización. Patrones visuales de reconocimiento.

The anti-immunoglobulin (Ig) E monoclonal antibody omalizumab (Xolair) has been proposed as an innovative pharmacological tool in the treatment of poorly controlled moderate to severe allergic asthma, which is characterized by frequent exacerbations, functional instability, and the need for high-dose inhaled corticosteroids, systemic corticosteroids, or both [1-3].

Management of severe asthma can benefit from both prospective and retrospective monitoring in order to control the disease and prevent exacerbations [4,5].

We developed a retrospective monitoring procedure

based on daily recording of the symptom score and of peak expiratory flow (PEF), which we routinely apply for as long as 10 months (or more, when necessary) in new patients with poorly controlled severe asthma. The valuable information we collect enables us to confirm our diagnosis and fine-tune therapy. The data recorded by patients at follow-up visits on monitoring cards are processed in real time by the graphic software Sigmaplot 1.0-11.0 (Systat, London, UK), which produces high-quality self-explanatory charts that can aid management-related rapid decision making through visual pattern recognition [5].

We describe our application of these monitoring techniques in patients with severe asthma treated with omalizumab (at the recommended individually tailored dose). The procedure has enabled us to assess the clinical and functional effects of omalizumab on asthma before and after treatment in a measurable and detailed manner (as in 4 of the 35 cases we are currently managing).

As an example of this concept, the Figure depicts the results for a 52-year-old male farmer sensitized to *Parietaria judaica* (a perennial allergen in Southern Italy), grass pollen, cypress pollen, and cat, and who had been receiving omalizumab from March 2007. Comparison of monitoring data collected from March 18 to April 16, 2005 (*P judaica* peak pollen season) with those from the same period in 2008 revealed a clear-cut decline in symptom scores: a constant score of 3 (maximum, 12) in 2005 compared with absence of symptoms in 2008. Moreover, PEF values stabilized and increased, with a mean (SD) morning value of 437 (16) L/min in 2005 vs 498 (12) L/min in 2008, and mean evening values of 428 (6) L/min and 493 (6) L/min, in 2005 and 2008, respectively. Both differences, which were analyzed using the *t* test for unpaired data, were statistically significant ($P < .0001$). The concomitant pharmacological treatment (inhaled budesonide 1200 µg tid, nedocromil sodium 4 mg tid, formoterol 12 µg bid, and montelukast 10 mg daily) remained unchanged over the 2 monitoring periods.

Similar results were obtained in the other cases we analyzed. A 65-year-old housewife had a mean morning PEF of 259 (9) L/min in 2005 compared with 308 (11) L/min in 2008 (monitoring period, April 1-30; $P < .0001$). A 49-year-old male police officer had an average morning PEF of 536 (18) L/min in 2005 compared with 591 (15) L/min in 2008 (monitoring period, April 15-May 14; $P < .0001$).

Analysis of monitoring data for a 67-year-old housewife during December 13-January 11 in 2004/2005 and 2008/2009 revealed a sharp reduction in PEF variability, from 26% to 8%, as assessed using the method of minimum morning prebronchodilator PEF over 1 week and expressed as a percentage of the recent best (Min%Max) [6].

We conclude that retrospective card-based monitoring of the symptom score and PEF followed by appropriate graphic rendering of the data collected is essential in the management of patients with poorly controlled severe asthma. This is particularly true when assessing the efficacy of novel therapeutic agents such as omalizumab. The effects of this treatment in individual patients can be appraised using visual pattern recognition after generation of high-quality charts and quantitative determination of changes in PEF values and PEF variability.

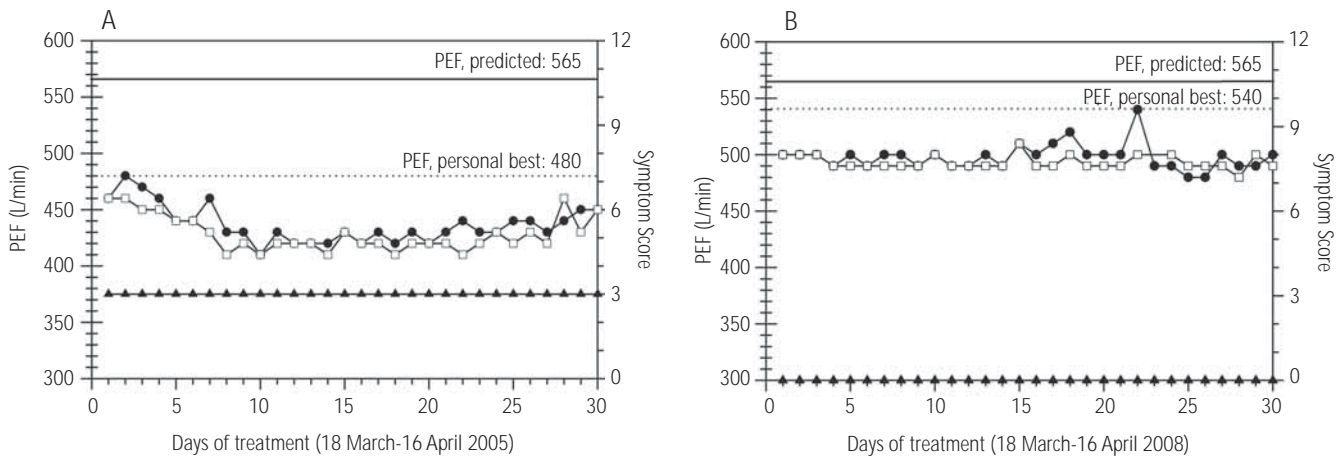


Figure. Effect of omalizumab (375 mg every 2 weeks) in a 52-year-old male patient with severe asthma. Graphic rendering (Sigmaplot 1.0) of data from retrospective monitoring based on daily recording of symptom scores (triangles; right Y axis: range 0-12^a), morning PEF values (circles), and evening PEF values (squares) (left Y axis). The data were from exactly the same period of time. A, Spring 2005 (before treatment with omalizumab) and B, Spring 2008 (during treatment with omalizumab). Predicted PEF values (continuous line) and personal best PEF values (dotted line) can be identified visually. While taking omalizumab, the personal best PEF value was reached on April 8, 2008, during the *P judaica* peak pollen season.

^aScores from 0 (absence/normality) to 3 (maximum) were recorded for wheezing, cough, everyday activities, and sleep.

Conflicts of Interest

GK, ASR, and MFC have received travel grants from Novartis. LM has received travel grants, research grants, and conference honoraria from Novartis.

References

1. Global Initiative for Asthma (GINA). Global Strategy for Asthma Management and Prevention. <http://www.ginasthma.org/Guidelineitem.aspx?i1=2&l2=1&intId=1561>. Updated 2008. Date last accessed: October 7 2009.
2. Holgate ST, Djukanovi R, Casale T, Bousquet J. Anti-immunoglobulin E treatment with omalizumab in allergic diseases: an update on anti-inflammatory activity and clinical efficacy. *Clin Exp Allergy*. 2005;35:408-16.
3. Holgate S, Casale T, Wenzel S, Bousquet J, Deniz Y, Reisner C. The anti-inflammatory effects of omalizumab confirm the central role of IgE in allergic inflammation. *J Allergy Clin Immunol*. 2005;115:459-65.
4. Gibson PG, Powell H, Wilson A, Abramson MJ, Haywood P, Bauman A, Hensley MJ, Walters EH, Roberts JLL. Self-management education and regular practitioner review for adults with asthma. *Cochrane Database Syst Rev* 2002; (3): CD001117.
5. Reddel HK, Vincent SD, Civitico J. The need for standardization of peak flow charts. *Thorax*. 2005;60:164-7.
6. Reddel HK, Salome CM, Peat JK, Woolcock AJ. Which index of peak expiratory flow is most useful in the management of stable asthma? *Am J Respir Crit Care Med*. 1995;151:1320-5.

■ Manuscript received February 1, 2010; accepted for publication March 22, 2010.

Luigi Macchia

Dept. of Allergology and Clinical Immunology
University of Bari
Piazza Giulio Cesare
70124 Bari, Italy
E-mail: l.macchia@allergy.uniba.it

Self-Injectable Adrenaline Devices: Is Training Necessary?

L Diwakar, J Heslegrave, AG Richter, AP Huissoon, MT Krishna

Department of Allergy and Immunology, Heartlands Hospital, Birmingham, UK Madrid, Spain

Key words: Anaphylaxis. Adrenaline. Epipen. Self-injectable adrenaline devices. Training.

Palabras clave: Anafilaxia. Adrenalina. Epipen. Dispositivos de autoinyección de adrenalina. Formas.

Self-injectable adrenaline (SIA) devices can save the lives of patients who experience anaphylaxis [1]. However, their effectiveness depends upon early usage, which in turn depends upon early recognition of anaphylaxis by patients (or their carers) and familiarity with the device [2]. Training in the use of SIA devices has been investigated in pediatric patients [3], but not in adults.

We carried out a questionnaire-based survey for a prospective clinical audit in the allergy clinic of the Heart of England NHS Foundation Trust (Birmingham, UK) between August and October 2007 in order to assess patients' knowledge of SIA devices and confidence in their use. All patients carrying an SIA device ($n=80$) and who were attended at the allergy clinic during the audit period completed the questionnaire. Patients were divided into 3 categories: those previously trained in our allergy clinic and attending for follow-up (specialist-trained), and newly referred patients who were issued SIA devices by nonallergy specialists (such as general practitioners, nurses, hospital physicians, pharmacists) and either received training (nonspecialist-trained) or did not (untrained). Questions were designed to assess training, understanding, and confidence with regard to use of the device. Knowledge and confidence scores (maximum scores of 7 and 2, respectively) were derived from the responses.

A total of 80 questionnaires were completed: 74 (92.5%) were eligible for analysis. Mean (SD) age of the respondents was 36.9 (15.17) years and 56 (76%) were female. Thirty (41%) of our respondents were specialist-trained, 20 (27%) were untrained, and 24 (32%) were trained by nonspecialists. All of the untrained patients had their device issued by nonspecialists. There was a significant difference in knowledge and confidence scores between specialist-trained and untrained patients: 5.97 (0.72) vs 5.05 (1.57), $P=.007$, and 1.5 (0.63) vs 0.75 (0.79), $P=.001$. The differences between knowledge and confidence scores of patients trained by nonspecialists and those who were untrained were not significant: 5.75 (0.94) vs 5.05 (1.57), $P=.075$, and 1.13 (0.63) vs 0.75 (0.79), $P=0.126$. Patient confidence scores between specialist-trained and nonspecialist-trained patients showed a trend towards significance: 1.5 (0.63) vs 1.13 (0.8), $P=.06$.

The most concerning finding in our cross-sectional study was that a quarter of patients with SIA devices appeared to have received no training whatsoever in their use, with the subsequent negative effects on knowledge and confidence. SIA training in our allergy clinic is protocol-driven and involves a trainer device and a written management plan. Details of training given by nonspecialists were not available, although this is likely to be less comprehensive. Indeed, many nonspecialists may not be familiar with SIA devices, and this could prove detrimental for patients [4].

Anaphylaxis is a serious and potentially fatal condition. To

issue an SIA device without proper training is dangerous, as this can give patients (or carers) a false sense of security, thus putting lives at risk in a situation of extreme duress [5].

Our study is limited by its small sample size and the lack of objective testing (eg, practical demonstration by the patient). Nevertheless, we feel that our results highlight pertinent points in the management of adult patients with serious allergies. Improving outcomes for patients with anaphylaxis at a time when the incidence of allergic diseases is growing to epidemic proportions requires nonspecialists to be better educated about anaphylaxis and SIA device use. Only then can these vulnerable patients take full advantage of this truly life saving device.

These data have been presented orally at the EAACI conference, Barcelona, Spain, June 2008, and as a poster presentation at the BSACI conference, Nottingham, UK, July 2008.

References

1. McLean-Tooke AP, Bethune CA, Fay AC, Spickett GP. Adrenaline in the treatment of anaphylaxis: what is the evidence? *BMJ*. 2003;327(7427):1332-5.
2. Pumphrey RS. Lessons for management of anaphylaxis from a study of fatal reactions. *Clin Exp Allergy*. 2000;30(8):1144-50.
3. Sicherer SH, Forman JA, Noone SA. Use assessment of self-administered epinephrine among food-allergic children and pediatricians. *Pediatrics*. 2000;105(2):359-62.
4. Grouhi M, Alshehri M, Hummel D, Roifman CM. Anaphylaxis and epinephrine auto-injector training: who will teach the teachers? *J Allergy Clin Immunol*. 1999;104(1):190-3.
5. Huang SW. A survey of Epi-PEN use in patients with a history of anaphylaxis. *J Allergy Clin Immunol*. 1998;102(3):525-6.

■ Manuscript received April 6, 2010; accepted for publication May 6, 2010.

Dr L Diwakar

Department of Immunology
Birmingham Heartlands Hospital
Bordesley Green East
Birmingham B9 5SS
UK

E-mail: klavanya99@yahoo.com