

ARCHIVOS DE LA SOCIEDAD ESPAÑOLA DE OFTALMOLOGÍA

www.elsevier.es/ofthalmologia



Original article

Acrysof® toric intraocular lens implantation in cataract surgery

J. Zarranz-Ventura*, J. Moreno-Montañés, J. Caire y González-Jáuregui,
E. de Nova Fernández-Yáñez, L.M. Sádaba-Echarri

Departamento de Oftalmología, Clínica Universidad de Navarra, Pamplona, Spain

ARTICLE INFORMATION

Article history:

Received on May 31, 2009

Accepted on July 8, 2010

Keywords:

Acrysof

Toric

Intraocular lens

Cataract surgery

Astigmatism

Phacoemulsification

A B S T R A C T

Aim: To assess the medium term outcomes of Acrysof® toric intraocular lens implantation in 54 patients (54 eyes).

Methods: Uncorrected visual acuity (UCVA), best corrected visual acuity (BCVA), preoperative astigmatism, residual postoperative astigmatism, and global average and model-specific intraocular lens (IOL) rotation grade were analyzed.

Results: At 2-months of follow-up, the mean UCVA was 0.83 (SD: 0.14) Snellen scale, with 73.9% of the patients ≥ 0.8 , and 32.6% with 1.0. Mean BCVA achieved was 0.94 (SD: 0.10). Mean preoperative astigmatism was -2.25 diopters (D) (SD: 0.78), and mean postoperative astigmatism was -0.32 D (SD: 0.56), with significant differences between both groups ($p < 0.001$). Model-specific mean residual astigmatism was -0.1 D for T3, -0.27 D for T4 and -0.43 D for T5, without significant differences between the three models ($p = 0.483$). Mean IOL-axis rotation grade was 3.87 ± 3.25 degrees, with 91.6% of implanted lens within 10° of predicted axis.

Discussion: T3, T4 and T5 Acrysof® Toric intraocular lenses can correct preoperative astigmatism with a high success rate in terms of UCVA, and residual postoperative astigmatism, with minimum IOL-rotation grade at 2 months follow-up period.

© 2010 Sociedad Española de Oftalmología. Published by Elsevier España, S.L.
All rights reserved.

Implante de lentes intraoculares tóricas Acrysof® en cirugía de la catarata

R E S U M E N

Propósito: Valorar los resultados a medio plazo del implante de lentes intraoculares tóricas Acrysof en 54 pacientes (54 ojos).

Método: Los parámetros analizados fueron mejor agudeza visual sin corrección (AVSC) y agudeza visual mejor corregida (AVMC), astigmatismo preoperatorio y residual postoperatorio, y rotación de la lente globalmente y en cada modelo de lente intraocular empleado.

Resultados: A los 2 meses del seguimiento, la AVSC media total fue de 0,83 (DS: 0,14) Snellen, estando el 73,9% de ellos con AVSC $\geq 0,8$ y el 32,6% en 1,0. La AVMC fue de 0,94 (DS: 0,10).

Palabras clave:

Acrysof

Tórica

Lente intraocular

Cirugía de catarata

Astigmatismo

Facoemulsificación

*Corresponding author.

E-mail: jzarranz@unav.es (J. Zarranz-Ventura).

El astigmatismo medio preoperatorio fue de $-2,25$ dioptrías (D) (DS: 0,78), siendo el astigmatismo medio postoperatorio total de $-0,32$ D (DS: 0,56), con diferencia estadísticamente significativa entre ambos grupos ($p < 0,001$). Desglosado por tipo de lente el astigmatismo fue $-0,1$ para las lentes T3, $-0,27$ D para las T4, y $-0,43$ para las T5, sin diferencias significativas entre los grupos estudiados ($p = 0,483$). La rotación media del eje de la LIO respecto al eje previsto fue de $3,87 \pm 3,25$ grados, con rotación menor a 10° en el 91,6% de las LIO implantadas.

Discusión: Las lentes tóricas modelo Acrysof T3, T4 y T5 permiten corregir el astigmatismo preoperatorio con un porcentaje elevado de éxito en lo que a AVSC y astigmatismo residual postoperatorio se refiere, con un mínimo grado de rotación de la lente a los 2 meses.

© 2010 Sociedad Española de Oftalmología. Publicado por Elsevier España, S.L.
Todos los derechos reservados.

Introduction

Cataract surgery has evolved in the past decades to become a safe and comfortable surgery with excellent visual quality results for patients. Phacoemulsification and the development of new devices have shortened the surgical procedure down to a few minutes with minimum aggression for the patient eye and a comfortable post-surgery period. However, the continuous development of innovations and technical improvements is accompanied by higher demand for better results by patients as well as surgeons in an ongoing search for excellence for the final visual quality of cataract patients. The objective is not only to improve the patient's vision but to achieve emmetropia without added optical correction as far as possible. To this end, presurgery diagnostic devices have been developed to perform an exact calculation of the most adequate intra-ocular lens for each patient as well as new lens and device designs for adapting their use according to the criteria of each surgeon.

Along this line, astigmatism has represented a problem for the traditional spherical lens implant, with several solutions being proposed. The use of arcuate corneal incisions and excimer laser refractive keratectomy have become the best options for resolving these cases for a number of years until the recent appearance of toric IOLs. These lenses have demonstrated excellent results in multicentre clinical trials since being presented in 1998, and their use has become mainstream in recent years.¹ This study analyses the results obtained in 54 patients intervened in our centre with implant of Acrysof[®] toric lenses (Alcon Laboratories, Inc., Fort Worth, Texas).

Method

Fifty-four patients (54 eyes) intervened in our centre between July 2008 and March 2009 were included in the study. The main inclusion criterion was pre-surgery keratometric astigmatism as per IOL-Master[®] (Carl Zeiss Meditec Inc., Dublin, CA, USA) ≥ 1.00 . The spherical power of the lens was calculated with IOL-Master[®] with constant A optimised for this biometer (118.72), and keratometric values K1 and K2 what input to the Acrysof Toric Calculator[®] software (www.acrysoftoriccalculator.com, Alcon Laboratories Inc,

Fort Worth, TX, USA) to determine the cylinder power (IOL model) and the exact pre-surgery IOL. The three lens models implanted were SN60T3, SN60T4 and SN60T5 for IOL plane cylinder correction of -1.50 , -2.25 and -3.00 D, equivalent to -1.03 , -1.55 and -2.06 D in corneal plane, respectively. Following the software IOL selection algorithm, the adequate IOL was determined for each patient and requested from the manufacturer. In the immediate presurgery, minutes before the intervention, the 0° - 180° axis was marked with the patient at 90° from the floor to avoid torsion phenomena and, with the surgical fields in place, we marked the axis for the IOL calculated by the software using the 0° - 180° axis as reference. All the surgical procedures, carried out by the same surgeon (JMM) with the Phaco-Chop technique went smoothly. The IOL implant was performed in the conventional manner with the Monarch II injector through a 2.4mm incision (fig. 1) and the IOL was centred placing its axis as calculated by the software. The irrigation-aspiration was performed softly to avoid lens rotation. The post-op was conventional, with topical administration of prednisolone-neomycin-polymixin B (Poly-pred[®], Allergan Inc., Irvine, CA, USA) in descending pattern, without events in any of the 54 eyes. Two months after the intervention the NCVA and BCVA were determined, together with the post-op residual astigmatism and the final

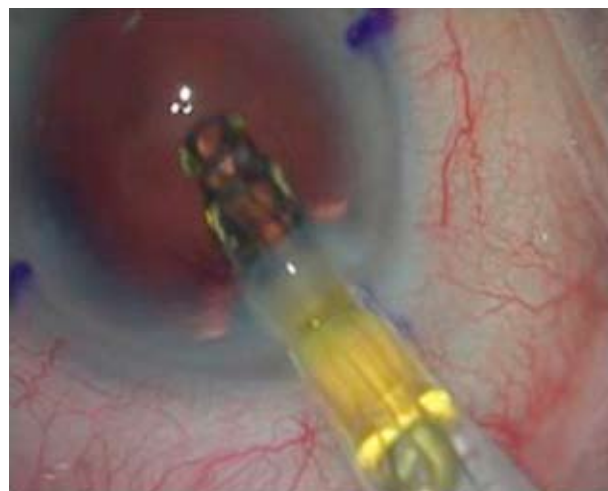

Figure 1 – Lens injection with Monarch II cassette.

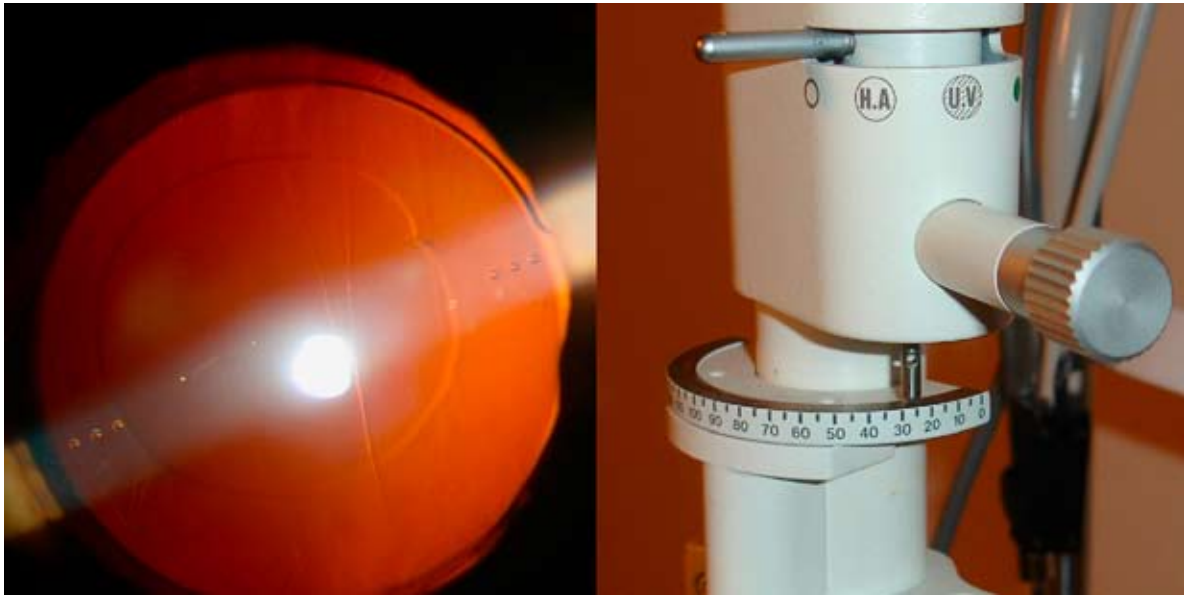

Figure 2 – Annotation of the post surgery lens axis, showing the points at both sides of the lens indicating its axis. Detail of slit lamp to measure final axis (25 degrees).

IOL axis after midriasis (fig. 2) with phenylephrine eyedrops 10% - tropicamide 1% (Alcon Cusí, El Masnou, Barcelona, Spain). The data were analysed with the SPSS 15.0 software (SPSS Inc, Chicago, IL, USA).

Results

Fifty-four eyes of 54 patients (n=54) were included in this study. The mean age was of 69.48 years (SD: 9.78), in a range of 51-78 years. The distribution by sex was of 24 males (44.4%) and 30 females (55.5%), and in what concerns the laterality of the intervened eyes, 23 were right eyes (42.59%) and 31 were left eyes (57.40%). All the included eyes completed the post surgery period without events. Eight patients were excluded due to baseline pathologies involving significant visual limitation: three had diabetic macular edema, two had advanced ARMD, 2 had amblyopia and 1 venous branch thrombosis. As regards the remaining 46 eyes, the results were as follows (table 1): the mean total NCVA was of 0.83 (SD: 0.14) Snellen, in 73.9% of cases, it remained equal to or above 0.8, with 32.6% of the sample reaching the unit (1.0) (fig. 3). With optical correction,

Table 1 – Visual equity and astigmatism 2 months post surgery

	Unc VA	Corr VA	Preop Astig.	Postop Astig.
No. of eyes	46	46	46	46
Mean	0.835	0.941	-2.2545	-0.3259
Typ. Dev.	0.1494	0.0977	0.78044	0.52097

Mean post surgery visual acuity (with and without optical correction) and mean astigmatism pre-surgery and two months post-surgery (n:46. Mean, Typical Deviation).

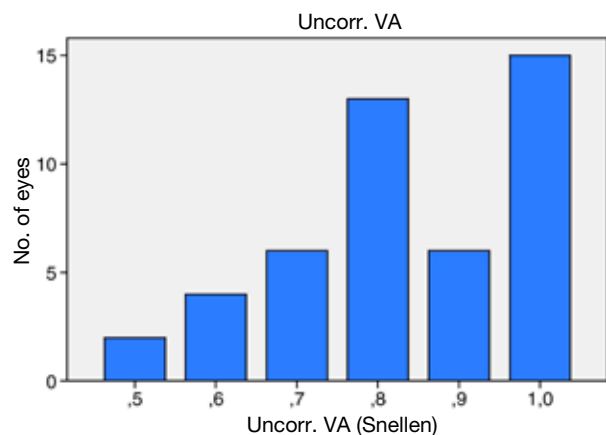


Figure 3 – Post surgery uncorrected visual acuity.

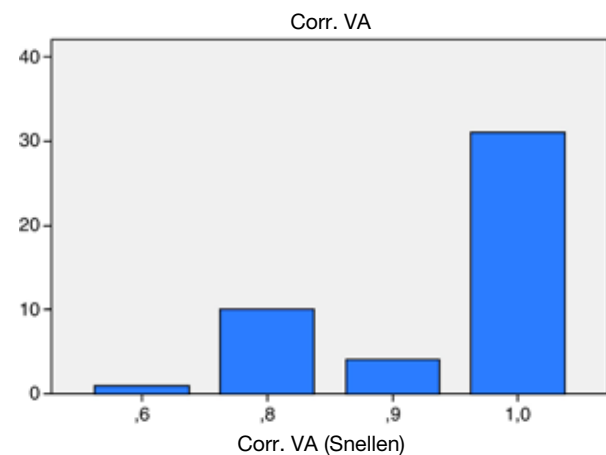


Figure 4 – Visual acuity with post surgery correction.

the mean corrected visual acuity was of 0.94 (SD: 0.10) (fig. 4). The presurgery astigmatism correction was significant, with the mean value prior to surgery being of -2.25 (CI 95%: $-2.48/-2.02$) while the post surgery mean total astigmatism was of -0.32 (CI 95%: $-0.48/-0.15$) ($p < 0.001$).

After analysing the results per lens model, residual astigmatism for IOL model SN60T3 ($n=11$) was of -0.10 D, for SN60T4 ($n=14$) was of -0.27 D and for SN60T5 ($n=21$) was of -0.43 D, without statistical significance between any of the groups ($p=0.483$). The mean rotation against the calculated axis was of 3.87 ± 3.25 degrees, without differences against the implanted IOL model, and 91.6% of the IOL exhibited a rotation of $< 10\%$ from the calculated axis.

Discussion

The results obtained in our study match those of previously published series. The clinical trial carried out by the US Food & Drug Administration (FDA) in 2005, prior to the marketing of Acrysof® lenses, obtained 66% of patients with toric IOL with $NCVA \geq 0.8$ at month six, similar to our 73.9%.¹ The different sample size could explain the difference ($n=250$; $n=46$) between both results. The lens implantation did not depart from the standard injection procedure of common lenses, with the main differences between the published studies being in the determination of the pre-op K values and the 0° - 180° axis marking system. Several authors have utilized IOL Master in their studies, although others have utilized systems such as Orbscan II (Bausch & Lomb, Rochester, NY, USA) or conventional keratometres to obtain the K values.²⁻⁴ In what concerns the determination of the 0° - 180° axis, the system utilized by the FDA and the authors was dermatographic marking with slit lamp while in this study the Elies marker was utilized (E. Janach, Como, Italy). The results of these studies in what concerns the lens rotation degree are slightly

lower than our 3.87 ± 3.25 values, varying in a range of 2.2° to 3.75° , which is quite consistent with our data. The percentage of patients with IOL rotation $< 10^\circ$ on two similar to our 91.6%, varying between 96.7 and 100%.¹⁻⁵

In conclusion, Acrysof® T3, T4 and T5 toric lens implants allow the correction of presurgery astigmatism with a high percentage of success in what concerns NCVA and residual postsurgery astigmatism, with a minimum degree of lens axis rotation after 2-6 months according to the published series.¹⁻⁶ The minor of modification of the surgical procedure and a broad dissemination of the necessary presurgery diagnostic devices, many of which are mainstream, lead us to consider a higher degree of utilization of this type of lenses in the mid term for patients with significant presurgery astigmatism intervened for cataracts.

REFERENCES

1. Horn JD. Status of toric intraocular lenses. *Curr Opin Ophthalmol.* 2007;18:58-61.
2. Bauer NJ, de Vries NE, Webers CA, Hendrikse F, Nuijts RM. Astigmatism management in cataract surgery with the AcrySof toric intraocular lens. *J Cataract Refract Surg.* 2008;34:1483-8.
3. Mendicute J, Irigoyen C, Aramberri J, Ondarra A, Montés-Micó R. Foldable toric intraocular lens for astigmatism correction in cataract patients. *J Cataract Refract Surg.* 2008;34:601-7.
4. Zuberbuhler B, Signer T, Gale R, Haefliger E. Rotational stability of the AcrySof SA60TT toric intraocular lenses: a cohort study. *BMC Ophthalmol.* 2008;8:8.
5. Chang DF. Comparative rotational stability of single-piece open-loop acrylic and plate-haptic silicone toric intraocular lenses. *J Cataract Refract Surg.* 2008;34:1842-7.
6. Ruiz-Mesa R, Carrasco-Sánchez D, Díaz-Álvarez SB, Ruiz-Mateos MA, Ferrer-Blasco T, Montés-Micó R. Refractive lens exchange with foldable toric intraocular lens. *Am J Ophthalmol.* 2009;147:990-6.