

284 Correspondence

It is our current practice to advise patients with aplastic anaemia against having influenza vaccination and only to give other vaccinations if medically indicated.

¹Department of Haematology,
St George's Hospital Medical
School, London, and

²Department of Haematology,
Peterborough District Hospital,
Peterborough, UK.

E-mail: jmarsh@sglms.ac.uk

C. L. HENDRY¹

M. SIVAKUMARAN²

J. C. W. MARSH¹

E. C. GORDON-SMITH¹

REFERENCES

- Frickhofen, N. & Rosenfield, S.J. (2000) Immunosuppressive therapy of aplastic anaemia with anti lymphocyte globulin and cyclosporine. *Seminars in Haematology*, **37**, 56–68.
- Meletis, J., Samarkos, M., Mesogitis, S., Melitis, C., Mougou, A., Terpos, E., Tsimberidou, A., Andreopoulos, A., Konstantopoulos,

K. & Loukopoulos, D. (1998) Severe aplastic anaemia relapsing during a pregnancy; spontaneous remission following a termination. *Haematologica*, **29**, 147–151.

Schrezenmeier, H., Marin, P., Raghavachar, A., McCann, S., Hows, Gluckmann, E., Nissen, C., van't Veer-Korthof, E.T., Ljungman, P. & Hinterberger (1993) Relapse of aplastic anaemia after immunosuppressive treatment, a report from the European Bone Marrow Transplantation Group SAA Working Party. *British Journal of Haematology*, **85**, 371–377.

Viallard, J.-F., Boiron, J.-M., Parrens, M., Moreau, J.-F., Ranchin, V., Reiffers, J., Leng, B. & Pellegrin, J.-L. (2000) Severe pancytopenia triggered by recombinant hepatitis B vaccine. *British Journal of Haematology*, **110**, 230–233.

Young, N.S. & Alter, B.P. (eds) (1994) *Aplastic Anaemia, Acquired and Inherited*. pp. 133–158. W.B. Saunders.

Keywords: aplastic anaemia, influenza vaccine, immunisation, pancytopenia, relapse.

ACQUIRED INHIBITOR OF THE INTRINSIC PATHWAY IN A NON-HAEMOPHILIC PATIENT. CONTROL OF BLEEDING BY RECOMBINANT FACTOR VIIa

The incidence of acquired inhibitors against clotting factors is rare in previously healthy subjects. Most of them are related to underlying autoimmune diseases or postpartum state. We report a case of acquired postpartum bleeding disorder in a non-haemophilic patient caused by an inhibitor of the intrinsic pathway that affected factor IX and the response to treatment with recombinant factor VIIa (rFVIIa; NovoSeven, Novo Nordisk, Denmark) and prednisone.

A 39-year-old woman without previous history of bleeding disorders was admitted as a result of the recent appearance of skin haematomas in upper and lower extremities. The patient had delivered her third child 1 month before without significant bleeding, requiring analgesic treatment with Diclofenac and Aspirin for 10 d. Initial laboratory data showed normal blood counts and biochemistry. A plasma coagulation study disclosed a prolonged activated partial thromboplastin time (aPTT) of 76.8 s (ratio 2.7) and normal prothrombin time, thrombin time, fibrinogen level and platelet aggregation. While other coagulation tests were being carried out, the patient developed an haemarthrosis at her right elbow with signs of compartment syndrome.

Clotting factors assay revealed a decreased factor IX (40 µ/dl), factor XI to be on the lower limit of normal range (61 µ/dl), and normal factors II, VIII, X, XII, XIII and von Willebrand factor. No alterations in D-dimer levels were observed (173 ng/ml), and functional tissue type plasminogen activator (t-PA) and α2-anti-plasmin were barely increased. Screening and confirmation tests for lupus anticoagulant were negative. The aPTT and factor IX levels

were hardly corrected after mixing with control plasma, indicating the presence of an inhibitor that showed no time dependence. New mixtures with normal pooled plasma showed the presence of an inhibitor against factor IX (2.5 Bethesda units).

Treatment with rFVIIa 90 µg/kg/4 h and prednisone 1.5 mg/kg/24 h was started, resulting in rapid recovery of factor IX levels. However, the prolongation of aPTT persisted, requiring 15 infusions of rFVIIa to achieve the complete disappearance of the clinical picture. Table I shows the patient's coagulation data at admission and during the treatment period.

A prospective study of 100 consecutive cases with prolonged aPTT of unknown aetiology identified the presence of lupus anticoagulant as the most common cause (Kitchens, 1988). Alterations of clotting factors in the intrinsic pathway may also be responsible for the prolongation of the aPTT. In the present report, a postpartum-acquired inhibitor of the intrinsic pathway affecting factor IX was detected. The presence of an acquired factor IX inhibitor is infrequent in haemophilia B patients and is extremely rare in non-haemophilic patients (Feinstein, 1995). A literature search identified reports of acquired factor IX inhibitors in a patient with autoimmune disease, two children and a patient with adenocarcinoma of the colon.

Bleeding in patients with acquired haemophilia is often severe, even with low titres of inhibitor, especially during the first weeks after presentation. However, the presence of a functional factor IX of 40 µ/dl seems insufficient to cause such prolongation of the aPTT. This suggests that other

Table 1. aPTT, functional factors IX and VII, and D-dimer performed at admission, 1 h after every rFVIIa infusion, at discharge and 1 week after discharge.

	Admission	1st	2nd	3rd	4th	5th	6th	7th	8th	9th	10th	11th	12th	13th	14th	15th Discharge	1 week later	
aPTT (s)	76.8	60	60.4	57.9	57.5	53.9	61.7	57.9	56.4	57.9	56.4	51.3	55.1	55.7	55.1	50.7	53.1	34.7
ratio	2.7	2.1	2.2	2	2	1.9	2.2	2	2	2	2	1.8	1.9	1.9	1.9	1.8	1.9	1.2
F. IX (u/dl)	40	141	151	195	172	213	130	134	136	148	152	184	143	166	143	160	188	97
F. VII (u/dl)	77	1969	1915	2206	1969	2083	2025	2143	2206	2143	2271	2555	2143	2206	2123	2480	100	100
D-dimer (ng/ml)	173	180	161	292	213	197	263	235	194	281	201	175	239	155	229	158	429	250

components of the intrinsic pathway may be affected, although the determination of other clotting factors showed no significant alterations.

The aims in the treatment of acquired haemophilia are control of the haemorrhage and elimination of the autoantibody. rFVIIa has proven effective in patients with alloantibodies and autoantibodies against factor VIII or IX (Lusher, 1996; Negrier & Hay, 2000). In a NovoSeven compassionate-use programme in 38 patients with acquired autoimmune depletion of factor VIII (Hay *et al.*, 1997), a median of 28 doses were administered per episode. In this case, 15 infusions were required to achieve a complete clinical response. Remarkably, D-dimer did not increase significantly during the treatment with rFVIIa. Persistence of the prolongation of the aPTT, despite recovery of normal factor IX levels during treatment with rFVIIa, supports the hypothesis of an inhibitory action against other factors involved in the intrinsic pathway. Another explanation could be interference between the presence of large amounts of factor VIIa and the determination of factor IX.

Spontaneous disappearance of postpartum-acquired inhibitors has been reported. However, owing to the severity of the bleeding, our patient started treatment with prednisone, which was maintained with tapered doses for 4 months. After discontinuation of immunosuppressive therapy, factor IX levels and aPTT remain between normal ranges.

*Servicio de Hematología y
Hemoterapia, Clínica
Universitaria de Navarra,
Universidad de Navarra,
Pamplona, Spain.
E-mail: erocha@unav.es*

RAMÓN LECUMBERRI
CARLOS PANIZO
JOSÉ ANTONIO PÁRAMO
MARTA PÉREZ SALAZAR
EDUARDO ROCHA

REFERENCES

- Einstein, D.I. (1995) Inhibitors of blood coagulation. In: *Hematology, Basic Principles and Practice*, pp. 1742–1758. 2nd edn. Churchill Livingstone.
- Hay, C.R.M., Negrier, C. & Ludlam, C.A. (1997) The treatment of bleeding in acquired haemophilia with recombinant factor VIIa: a multicentre study. *Thrombosis and Hemostasis*, **78**, 1463–1467.
- Kitchens, C. (1988) Prolonged activated partial thromboplastin time of unknown etiology: a prospective study of 100 consecutive cases referred for consultation. *American Journal of Hematology*, **27**, 38–45.
- Lusher, J.M. (1996) Recombinant factor VIIa (NovoSeven) in the treatment of internal bleeding in patients with factor VIII and IX inhibitors. *Haemostasis*, **26**, 124–130.
- Negrier, C. & Hay, C. (2000) The treatment of bleeding in hemophilic patients with inhibitors with recombinant factor VIIa. *Seminars in Thrombosis and Hemostasis*, **26**, 407–412.

Keywords: acquired inhibitor, intrinsic pathway, factor IX, recombinant factor VIIa, prednisone.

THE USE OF RECOMBINANT FACTOR VIIA IN A JEHOVAH'S WITNESS WITH AUTO-IMMUNE THROMBOCYTOPENIA AND POST-SPLENECTOMY HAEMORRHAGE

We report a 68-year-old female Jehovah's Witness who presented with a widespread purpuric rash, blood blisters in the mouth and a platelet count of $3 \times 10^9/l$. The blood

count was otherwise normal and bone marrow examination was consistent with idiopathic auto-immune thrombocytopenia.

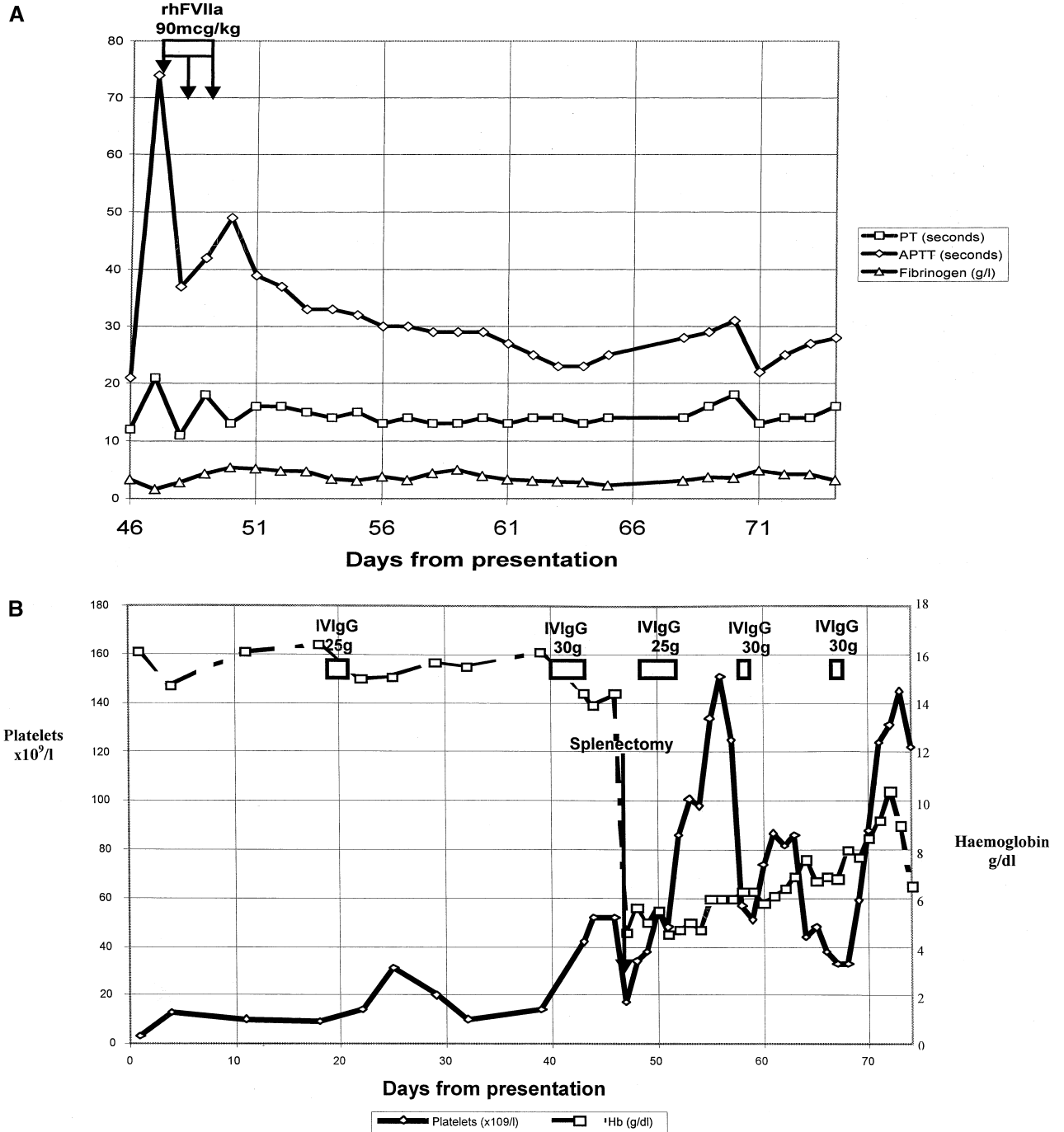


Fig 1. (A and B) Serial coagulation tests, haemoglobin and platelet counts.

She was commenced on prednisolone 60 mg/d. On d 11 after presentation, the platelet count was only $10 \times 10^9/l$. It was confirmed that immunoglobulins were an acceptable treatment and the patient received a 3 d course of intravenous immunoglobulin (IVIgG) 25 g/d. The maximum platelet count achieved was $31 \times 10^9/l$. She therefore received methyl prednisolone 500 mg i.v. for 3 d, but the platelet count remained at $14 \times 10^9/l$. On d 40, the patient was again given IVIgG, 30 g (0.4 g/kg) daily for 4 d. On d 44, the platelet count had risen to $52 \times 10^9/l$ with Hb 14.4 g/dl; this platelet count was considered sufficient to allow splenectomy safely to be performed and surgery was carried out on d 47. The preoperative coagulation screen was prothrombin time (PT) 12 s (normal range, 11–16 s), activated partial thromboplastin time (APTT) 21 s (22–35 s), fibrinogen 3.3 g/l (1.5–4.5 g/l).

Several hours after splenectomy, her abdomen was found to be tense and distended; the haemoglobin (Hb) was 8.0 g/dl with platelets $46 \times 10^9/l$. Gelatin solution (1500 ml) was given as a non-blood-derived volume expander and packing inserted to try to contain the bleeding; aprotinin and tranexamic acid were commenced. The patient was transferred to the intensive therapy unit (ITU) with Hb 4.5 g/dl, platelet count $17 \times 10^9/l$, PT 21 s, APTT 74 s and fibrinogen 1.6 g/l. Cryoprecipitate was acceptable to the patient and she received 8 units on two occasions.

Despite continuing life-threatening haemorrhage and in the face of significant thrombocytopenia and coagulopathy, the patient continued to refuse most plasma products. Recombinant factor VIIa (Novosen, Novo Nordisk) was then administered at a dose of 90 µg/kg. Haemostasis was achieved, following a single dose, and after two doses coagulation was normal (PT 11 s, APTT 28 s, fibrinogen 4.4 g/l). A third dose was given after the patient returned to theatre for removal of packs, when the coagulation tests deteriorated (see Fig 1A). Factor VIIa has been reported to promote haemostasis in intractable haemorrhage, e.g. following severe trauma (Kenet *et al.*, 1999; Martinowitz *et al.*, 2001). As it is not derived from blood, the product is acceptable to Jehovah's Witnesses (Majumdar & Savidge, 1993; Papatheodoridis *et al.*, 1999). Her thrombocytopenia was managed by continuing steroid therapy and IVIgG.

Erythropoietin (10 000 units three times per week) was commenced on the second day in the ITU (Koestner *et al.*, 1990); vitamin B₁₂, folate and intravenous iron sucrose were also administered. Further blood loss was minimized by use of paediatric microsampling. Human or bovine haemoglobin solutions (natural or recombinant) or perfluorocarbons (Marelli, 1994; Doyle, 2001) were found not to be available outside the context of clinical trials in the USA and Canada. Hyperbaric O₂ was also considered, but it was thought that the risk of transferring the patient would outweigh the benefit.

On d 51, the patient suffered an episode of fast atrial fibrillation and the following day she developed *Candida albicans* pneumonia. On d 62, there was evidence of auto-

immune haemolytic anaemia (Hb 6.4 g/dl, positive direct antiglobulin test, reticulocytes 9.1%, lactate dehydrogenase 1488 iu/l) and further IVIgG was given. By d 72, the Hb had risen to 10.4 g/dl, with a platelet count of $131 \times 10^9/l$ (Fig 1B). Coagulation was normal as follows: PT 14 s, APTT 25 s, fibrinogen 4.2 g/l. Erythropoietin was reduced to 3000 units three times per week. Inspired oxygen had been reduced to 40% and it was hoped to wean her off the ventilator. However, on d 73, the patient suffered two rectal bleeds, despite a platelet count of $145 \times 10^9/l$ and normal coagulation. She continued to bleed and her Hb fell to 6.5 g/dl. It was thought that the patient would not survive total colectomy and she died on d 75. At post mortem, there was evidence of ischaemic colitis, a relatively common complication of long-term treatment on the ITU, as well as adult respiratory distress syndrome and multiorgan failure.

The treatment of this patient using non-blood methods resulted in a significantly higher cost. The major drug costs and an estimate of the costs of keeping the patient on ITU totalled almost £44 000. The cost of recombinant FVIIa was £10 250 but, although the final outcome in this patient was unsuccessful, recombinant factor VIIa clearly arrested bleeding in the face of life-threatening haemorrhage and coagulopathy and would be of value again in similar circumstances.

¹University of Newcastle DOMINIC P. WADDINGTON¹
upon Tyne, Newcastle upon Tyne, ²Queen Elizabeth
Hospital, Gateshead, and FRANK T. MCAULEY²
JOHN P. HANLEY³
GEOFFREY P. SUMMERFIELD²
³Haemophilia Centre,
Royal Victoria Infirmary,
Newcastle upon Tyne, UK.
E-mail: geoffrey.summerfield@
ghnt.nhs.uk

REFERENCES

- Doyle, D.J. (2001) Hemoglobin-based blood substitutes for Jehovah's Witnesses. *Journal of Clinical Anesthesiology*, **13**, 472.
- Kenet, G., Walden, R., Eldad, A. & Martinowitz, U. (1999) Treatment of traumatic bleeding with recombinant factor VIIa. *Lancet*, **354**, 1879.
- Koestner, J.A., Nelson, L.D., Morris, Jr, J.A. & Safcsak, K. (1990) Use of recombinant human erythropoietin (R-HuEPO) in a Jehovah's Witness patient refusing transfusion of blood products: case report. *Journal of Trauma-Injury Infection and Critical Care*, **30**, 1406–1408.
- Majumdar, G. & Savidge, G.F. (1993) Recombinant factor VIIa for intracranial haemorrhage in a Jehovah's Witness with severe haemophilia A and factor VIII inhibitors. *Blood Coagulation and Fibrinolysis*, **4**, 1031–1033.
- Marelli, T.R. (1994) Use of a hemoglobin substitute in the anemic Jehovah's Witness patient. *Critical Care Nurse*, **14**, 31–38.
- Martinowitz, U., Kenet, G., Segal, E., Luboshitz, J., Lubetsky, A., Ingerslev, J. & Lynn, M. (2001) Recombinant activated factor VII for adjunctive hemorrhage control in trauma. *Journal of Trauma-Injury Infection and Critical Care*, **51**, 431–438.

Papatheodoridis, G.V., Chung, S., Keshav, S., Pasi, J. & Burroughs, A.K. (1999) Correction of both prothrombin time and primary haemostasis by recombinant factor VII during therapeutic alcohol injection of hepatocellular carcinoma in liver cirrhosis. *Journal of Hepatology*, **31**, 747–750.

Keywords: Jehovah's Witness, recombinant FVIIa, auto-immune thrombocytopenia, post splenectomy, haemorrhage.