

Cartas al Director

Foreign body tumor simulating a gastrointestinal stromal tumor

Key words: Gastrointestinal stromal tumor. GIST. Foreign body.

Dear Editor,

We report the case of a 31 years old female who came to our center for a second opinion, regarding a previous diagnosis of a gastrointestinal stromal tumor (GIST) or a retroperitoneal sarcoma.

She had been in her usual health until 1 year ago, when she felt an indolent mass in right lower quadrant, without alteration in bowel movement neither anorexia or weight loss. The patient previously consulted with a gastroenterologist and a gynecologist. Due to the increase of the abdominal mass, a computed tomography (CT) without contrast revealed and 8.5 cm diameter intraabdominal tumor.

She referred to be operated of left herniorrhaphy in her infancy and of hiperparathyroidism and uterine myoma and ovarian cyst six years before, with no other gynecologic history. The family history was irrelevant. On examination, the vital signs were normal. A solid mass was palpated in the lower right abdominal quadrant. It was mobile and not attached to overlying skin or deep plane and no hepatosplenomegaly.

With a normal routine hematological and serum chemical test, a thoraco-abdominal CT-scan with and without intravenous contrast was carried out. The CT-scan showed a solid mass of 8 x 5 x 10 cm of diameter in right lower quadrant (RLQ), heterogeneous with scattered calcifications. The mass displaced the ileal loops and was in close contact with the right epigastric artery, without involvement of any vascular structure. The radiological findings were compatible with GIST.

She underwent a laparotomy and “en block” resection of the

tumor with involved ileal loops was performed. The postoperative course was uneventful and she was discharged on the third postoperative day.

The pathologic report described an “ovoid” tumor weighing 500 grams which included 11 cm of ileum. The tumor was consisting with a cystic lesion formed by 1 cm thick well defined capsule and a surgical sponge in its interior. Histology revealed a chronic inflammatory infiltrate. The small bowel was normal, and sinusal hystiocitosis was present in the regional lymph nodes.

The patient history as well as the radiological findings were consistent with a peritoneum or mesentery originated tumor –desmoid tumor, malignant fibrous histiocytoma, neuronal tumor– or an intramural neoplasm of the gastrointestinal tract: autonomic nerve tumors, neuronal tumors, lipomatous tumors (1).

The suspected diagnosis of GIST was based on the size and the presence of heterogeneous areas in the lesion, due to endogenous necrosis of its central position. Although other signs as the age of the patient, the absence of digestive symptoms –pain, nausea, weight loss, bleeding, etc.– as well as the absence of contrast uptake by the lesion could role out the GIST diagnosis. In figure 1 the correlation between the CT image and macroscopic view are depicted.

In spite of the precautions and monitoring held during surgical interventions as the double count of sponges and the exploration of the abdominal cavity before closure of the abdomen, the missing of foreign bodies –sponges, needles– represent a medical problem (2).

The reported incidence of retain foreign body was estimated to be 0.3 to 1 each 1,000 abdominal surgeries, would probably be underestimated and when occurring generates serious consequences for the patient, including infection, bleeding and perforation (3,4).

Although the origin of the surgical errors are not well systematized, the majority of the authors agree with the risk factors for this adverse event: the high number of interventions, the lack of vigilance during the double-check counting of surgical devices, obesity, changes on the surgical technique and emergency cases (5). It is recommended the systematic review,

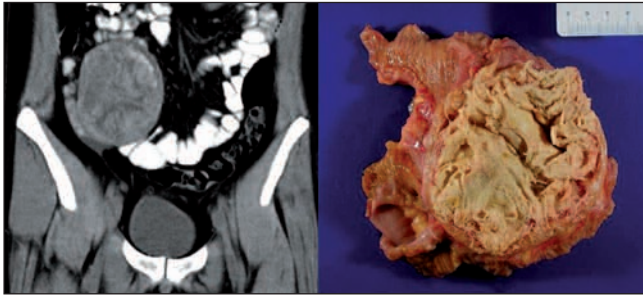


Fig. 1. Correlación entre imagen de corte coronal de TC y pieza macroscópica.

team briefings and communication skills between the providers involved in the operating room as the most effective measure. There are on-going studies regarding the counting with radiofrequency devices still in the experimental field.

J. Arredondo¹, P. Martí¹, J. M. Bondía², G. Zozaya¹
and J. A. Cienfuegos¹

¹Department of General Surgery. ²Service of Radiodiagnosis.
Clínica Universidad de Navarra. Pamplona, Spain

References

1. Levy A, Remotti HE, Thompson WM, Sobin LH, Miettinen M. Gastrointestinal stromal tumors: radiologic features with pathologic correlation. *Radiographics* 2003; 23: 283-304.
2. Pascual Regueiro D, Mallén Mateo E, Allué López M, García de Jalón Martínez A, Roncalés Badal A, Rioja Sanz LA. Cuerpo extraño simulando tumor renal. *Actas Urol Esp* 2004; 28: 390-2.
3. Stawicki SP, Evans DC, Cipolla J, Seamon MJ, Lukaszczyk JJ, Prosciak MP, et al. Retained surgical foreign bodies: a comprehensive review of risks and preventive strategies. *Scand J Surg* 2009; 98: 8-17.
4. González Ojeda A, Rodríguez Alcántara DA, Arenas Márquez H, Sánchez Pérez-Verdía E, Chávez Pérez R, Álvarez R, et al. Retained foreign bodies following intra-abdominal surgery. *Hepatogastroenterology* 1999; 46: 808-12.
5. Gawande A, Studdert DM, Orav EJ, Brennan TA, Zinner MJ. Risk factors for retained instruments and sponges after surgery. *N Engl J Med* 2003; 348: 229-35.
6. Greenberg C, Gawande A. Retained foreign bodies. *Adv Surg* 2008; 42: 183-91.