

Acta Alimentaria, Vol. 43 (3), pp. 452–458 (2014)

DOI: 10.1556/Alim.43.2014.3.12

EFFECTS OF VITAMIN A OVERDOSE ON RAT'S ORGANS INVOLVED IN IMMUNITY AND VITAMIN A STORAGE

S. MAHASSNI* and N. AL-SHAIKH

Department of Biochemistry, King Abdulaziz University, Jeddah, Saudi Arabia

(Received: 21 February 2013; accepted: 15 April 2013)

Vitamin A overdose is a common occurrence due to food fortification and ingestion of vitamin A supplements. Vitamin A is a nutrient that possesses known and potential effects on general health and the immune response. This research work is an *in vivo* investigation of the effects of administration of vitamin A above dietary requirements on some organs involved in immunity, vitamin A storage, and metabolism in healthy male rats. A total of 60 young adult male Wistar rats were equally divided into three groups. Rats in the two test groups were orally administered with vitamin A at different concentrations (8000 and 15 000 IU kg⁻¹ body weight) for 21 days, while the control rats did not receive any supplementation. Weekly body weights and weights of the liver, kidney, spleen, and thymus were measured. Histological evaluations were carried out on the liver, kidney, thymus, and Peyer's patches. Findings show that vitamin A did not significantly affect body and organs' weights, except for a significant decrease of spleen weights for both experimental groups. Vitamin A was found to lead to some changes in the histology of the tested organs. This is the first study of its kind and sets a base for future studies.

Keywords: immune system, vitamin A, hypervitaminosis A, vitamin A overdose, histology, rat

Vitamin A deficiency is one of the most common nutritional deficiencies in many countries (WEDNER & ROSS, 2008). Many people take vitamin A supplements in doses surpassing the required or recommended amounts in the hope that, according to the findings of many research studies (CUNNINGHAM-RUNDLES et al., 2005; VILLAMOR & FAWZI, 2005; PENNISTON & TANUMIHARDJO, 2006), they lead to better health, to enhance the immune response, and decrease the number of infections and the incidence of certain diseases. Additionally, overdosing of vitamin A may occur inadvertently when taking supplements, in light of the many vitamin A fortified foods in many countries. The consequences of taking high doses of vitamin A on the immune system and general health in adults are not fully understood and studies are limited.

Vitamin A, a fat-soluble vitamin, is absorbed in the intestine and stored mainly in the liver, kidney, and adipose tissues. The ease of its accumulation in the body and the difficulty of disposing excess amounts, leads to a high likelihood of hypervitaminosis (vitamin toxicity). The symptoms of both acute and chronic hypervitaminosis A, with symptoms for chronic being more severe, may be nausea, jaundice, irritability, anorexia, vomiting, blurry vision, headaches, hair loss, muscle and abdominal pain, weakness, drowsiness, an altered mental state (RAMANATHAN et al., 2009), and increased susceptibility to infections, which is due to a weakened immune system (CHANDRA, 1993).

A weakened immune system may be caused by effects on the organs of the immune system. Lymphoid tissue and its cellular components are known to be responsible for body

* To whom correspondence should be addressed.

Phone (9665)05686027; e-mail: sawsanmahassni@hotmail.com

defence mechanisms that are markedly sensitive to chemical or bacterial toxins (MIURA et al., 1998). The organs that are involved in acquired immunity and where lymphocytes are produced and mature are the primary lymphoid organs (e.g., thymus), while the secondary lymphoid organs (e. g., spleen and Peyer's patches) are where lymphocytes acquire specificity for antigen. Thus, any effector that leads to the inhibition of the immune system may affect any of these organs. Also the liver, kidney, and adipose tissues are the organs where vitamin A is stored (PENNISTON & TANUMIHARDJO, 2006). Therefore, vitamin A toxicities may affect the liver and kidney and may increase with increasing body weight, since more vitamin can be stored.

The main aim of this study is to investigate the effects of very large doses of vitamin A on rat organs involved in immunity (spleen, thymus, and Peyer's patches) and vitamin A storage (liver and kidney). Also changes in body weight and weights of the thymus, spleen, liver, and kidney were assessed.

An extensive search in the literature was carried out to find histological studies on tissues of rats that have been administered with high doses of vitamin A, but none were found. Therefore, this work is the first to study the histological effects of very high doses of vitamin A and this is an area where more research is needed.

1. Materials and methods

1.1. Animals

Sixty young adult male Wistar rats aged 9 weeks, with an initial body weight range of 170–250 g, were used. Rats were supplied by and housed at King Fahd Medical Research Center, Jeddah, Saudi Arabia. The rats were housed at room temperature (25 °C), with a fixed 12 h light-dark cycle, and had free access to food. Rats received a diet that contained 8.44% moisture, 6% ash, 20% proteins, 4% fats, 59.55% soluble carbohydrates, 3.50% fibres, 1% calcium, 0.60% phosphorus, 20 IU g⁻¹ vitamin A, 2.20 IU g⁻¹ vitamin D, and 70 IU kg⁻¹ vitamin E (Grain Silos and Flour Mills Organization, Jeddah, Saudi Arabia).

The rats were randomly divided into three equal groups. The two experimental groups received vitamin A daily by oral gavage for 21 days. Powdered vitamin A (retinol, 99% pure) (Lanospharma Laboratories Company, China) was dissolved in cold pressed virgin olive oil. Rats in the low dose group received vitamin A at 8000 IU kg⁻¹ body weight, while the high dose group received 15 000 IU kg⁻¹ body weight. The control rats received olive oil only in the same manner as for the experimental groups. Body weight of all rats was measured four times. The first weight was taken the day before beginning vitamin A administration and the subsequent weights were taken at the end of each week. At the end of the experimental period, rats were anesthetized by ether, and the liver, kidney, spleen, and thymus gland were excised and weighed.

1.2. Histological examination

Harvested liver, kidney, thymus gland, and Peyer's patches were fixed and stored in 10% formalin for one or two days. Subsequently, each organ was dehydrated by transferring it to successively higher percentages of alcohol solutions ending with 100% alcohol. After clearing the organ in xylene, it was impregnated in wax, and then sliced at 4 microns using a microtome. The slices were then placed in xylene, then passaged through decreasing concentrations of alcohol down to 70%, and finally stained by haematoxylin and eosin. Slides

were examined and photographed using a digital camera, attached to an Olympus CX21 light microscope connected to a computer.

2. Results and discussion

2.1. Organs and body weights

The vitamin A doses used in this study did not significantly affect the body weights of rats (Table 1). This result is not in agreement with the findings of previous studies on rats (JEYAKUMAR et al., 2005) and lambs (RAOOFI et al., 2010), where they found that feeding of high but non-toxic doses of vitamin A significantly reduces body weight.

The data (Table 1) show that there is no association between oral administration of vitamin A and liver, kidney, and thymus weights of the vitamin A fed rats when compared to the control rats. Limited previous studies in rats (BEN-AMOTZ et al., 2005; JEYAKUMAR et al., 2005) are in agreement with these findings. As for the spleen, the data show (Tables 1 and 2) that the mean spleen weights for the test groups are significantly lower than those of the control, which is contradictory to the findings of researchers (BEN-AMOTZ et al., 2005) who found no changes in spleen weights of supplemented rats. No difference was found in the mean weights between the low and high dose groups.

Table 1. Descriptive statistics and test of significance for organ weights using the ANOVA one way test

	Group	Organ weight (g)			SD	P
		Max	Min	Mean		
Body	Control	320	180	254.25	31.84	0.66 ^{NS}
	Low	280	185	247.06	24.37	
	High	300	220	248.25	21.10	
Spleen	Control	0.90	0.40	0.60	0.15	0.03 ^S
	Low	0.77	0.46	0.52	0.07	
	High	0.70	0.45	0.52	0.06	
Liver	Control	15.10	7.40	11.17	1.91	0.69 ^{NS}
	Low	14.23	9.12	11.16	1.59	
	High	12.35	8.76	10.80	1.02	
Thymus	Control	0.58	0.23	0.43	0.09	0.40 ^{NS}
	Low	0.76	0.23	0.45	0.12	
	High	0.88	0.32	0.49	0.14	
Kidney	Control	3.03	1.40	2.08	0.40	0.93 ^{NS}
	Low	2.40	1.71	2.09	0.18	
	High	2.40	1.65	2.06	0.16	

S: Significant ($P < 0.05$); NS: non-significant ($P > 0.05$); Max: maximum; Min: minimum; SD: standard deviation

Table 2. Multiple comparisons LSD test between the mean spleen weights for the control group and other groups

Group X	Group Y	Mean Difference (X-Y)	SE	P	95% CI
Control	Low	0.082*	0.04	0.03 ^S	0.009, 0.154
	High	0.083*	0.03	0.02 ^S	0.015, 0.152
Low dose	Control	-0.082*	0.04	0.03 ^S	-0.154, -0.009
	High	0.002	0.04	0.96 ^{NS}	-0.069, 0.073
High dose	Control	-0.083*	0.03	0.02 ^S	-0.152, -0.015
	Low	-0.002	0.04	0.96 ^{NS}	-0.073, 0.069

* The mean difference is significant at the 0.05 level. SE: Standard error; CI: confidence interval; S: significant ($P < 0.05$); NS: non-significant ($P > 0.05$)

2.2. Histological observations

Histology of the organs from the experimental groups was compared to their respective controls. Liver sections of experimental rats (Fig. 1) had different morphology from those of untreated rats. The changes were present in both experimental groups, but they were more pronounced in the high dose group. Changes are shown in Fig. 1 in addition to focal apoptosis near the central veins and portal areas, peri-portal inflammatory cell infiltrate, and vacuolation of hepatocytes in the form of rounded vacuoles of various sizes in some hepatocytes. Cell necrosis was also observed but less evident compared to apoptosis.




Fig. 1. Sections from the liver of the high dose group. **A.** Dilated central veins (CV) and congestion of the portal vein (black arrow) ($\times 40$). **B.** Magnified hepatocytes from the same slide showing rounded cytoplasmic (lipid) vacuoles (thin black arrow). Many cells show dark acidophilic cytoplasm (white arrow) indicating early apoptosis. **C.** Portal area showing congested portal vein (PV), proliferating bile ducts (BD) with mononuclear cell infiltrate (thick black arrow) ($\times 100$)

Sinusoidal dilatation and peri-portal inflammatory reaction were reported by COLAKOGLU and KÜKNER (2003) in rats with hypervitaminosis A. Sinusoidal dilatation was attributed by SHINTAKU and co-workers (1998) to be related to increased size and number of Ito cells, which contradicts the findings here of normal size and number of Ito cells. FUCHS (1999) observed apoptosis of hepatocytes in rats with hypervitaminosis A.

SHINTAKU and co-workers (1998) reported that excessive intake of vitamin A leads to focal necrosis in the peripheral zone hepatocytes of the hepatic lobules, which is in agreement

with the present data. COLAKOGLU and KÜKNER (2003) also described, similar to the current findings, vacuolated hepatocytes and lipid droplets accumulation in the livers of high retinoic acid-fed rats. However, the researchers also described accumulation of fat droplets in the peri-sinusoidal Ito cells, which were not observed in the current study results.

The thymus of supplemented rats (Figs 2–4) had different morphology from control rats. The treated group thymus showed, in addition to the changes in the figures, cells with active vesicular nuclei, which may be related either to active thymocytes or stromal reticular cells, and in the high dose group, dark small bodies (may be fragmented nuclei of apoptotic thymocytes) surrounded by large unstained areas were observed in the cortical regions of the thymi.

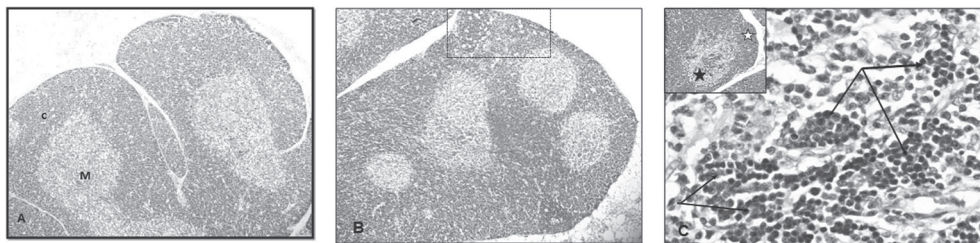


Fig. 2. A. Section from thymus of the control group showing the cortex (C) and the medulla (M) ($\times 40$).
B. Thymus section of the high dose group. Note the increase in thickness of cortical regions (dotted square) ($\times 40$).
C. The medulla (black star) shows thymocytes aggregation (thin black arrow) ($\times 100$)

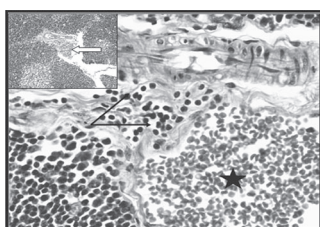


Fig. 3. Part of interlobular tissue of the thymus (insert) shows marked dilation and venous congestion (white arrow). Mononuclear cell infiltration (thin black arrows) is seen near the congested vein (black star) ($\times 100$)

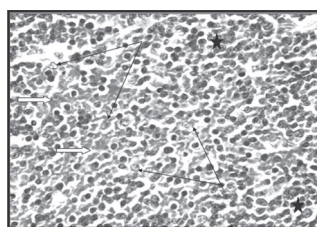


Fig. 4. Magnified segment of thymic lobule medulla. Cortical thymocytes (black stars) at the periphery, the increase in thymocytes having rounded large vesicular nuclei (black thin arrows) and the infiltration with erythrocytes (white arrows) ($\times 100$)

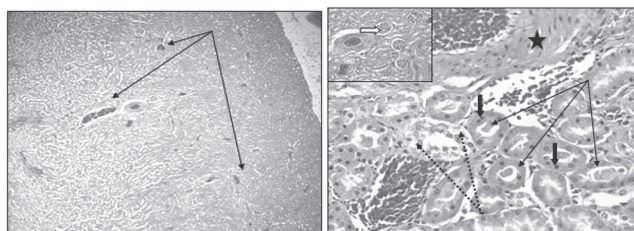


Fig. 5. Kidney segment from the high dose group (left panel) showing congested blood vessels (arrows) and dilated tubules ($\times 40$). Right panel shows the marked thickening and congestion of arterial wall (black star). Some proximal tubules show slight dilation and the presence of casts (thin black arrows), small dark nuclei (thick black arrows) of the tubular cells (pyknosis) and distal tubules show degenerated unstained cytoplasmic regions (dotted arrow). The insert shows normal renal corpuscles ($\times 400$)

The administration of vitamin A resulted in changes (Fig. 5) in the kidney of the high dose group. The changes were focal and showed individual variations. Contradictory data were reported in the literature (LI et al., 2009) regarding the effect of vitamin A on kidney tissue. Vitamin A was reported (LI et al., 2009) to modulate ureteric bud branching and morphogenesis.

The Peyer's patch tissues of the high dose group (Fig. 6) compared to the control tissue show an increase in the size of the germinal centres in the lymphoid follicles. Spaces containing pyknotic small dark nuclei and cells with large vesicular nuclei (could be macrophages or active lymphocytes) were also observed.

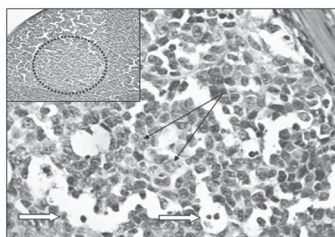


Fig. 6. Peyer's patch from the high dose group, showing germinal centres (dotted circle). The lymphocytes show active light stain nuclei (black arrow). Large spaces with dark small nuclei are seen (white arrows)

3. Conclusions

The chosen concentrations of vitamin A are very high doses since, as established by the National Research Council (NRC, United States), the approximate daily requirement of vitamin A for a rat is 0.37–4 IU, although there is no consensus on this level (MCDOWELL, 2000). In addition, different organs may reach toxicity at different levels of vitamin A and this depends on adiposity of the rat since the vitamin is fat-soluble.

The oral gavage route was used to administer vitamin A since it introduces the vitamin directly into the gastrointestinal tract of rats, which is closest to the natural route of food, and supplement ingestion and ensures the ingestion of the entire dose. This route may affect immunity in general, while the intraperitoneal route reaches the blood stream directly and may induce humoral immunity only. Most vitamin A toxicity studies (PENNISTON & TANUMIHARDJO, 2006) administer the vitamin by using intramuscular or venous injections, thus, their findings are not useful for studying the effect on the immune system or extrapolation to later studies in humans.

Nutrient overdose may have some effects on organ structure, function and size. Also, a reduction in weight is a symptom of vitamin A toxicity (acute and chronic). In this study no change in weight was observed for the experimental group. This, along with the lack of other symptoms of hypervitaminosis, may indicate that the used levels of vitamin A did not cause any toxicity. This reduction in the weight of the spleen may have an inhibitory effect on the immune system, which is much like the size reduction of the spleen that occurs with aging that also affects the immune response.

In view of the data, a suggestion may be made that daily administration of vitamin A results in hyperplasia of thymic cortex presented in the form of increased thymic lobule thickness. In addition, vitamin A was reported (BELLOVINO et al., 2003) to play a crucial role in the mechanisms that govern proliferation and differentiation of many cell types throughout

life. This may provide a reason for the findings of increasing thickness of the thymic lobular cortices and enlargement of the Peyer's patches follicles via a local effect exerted on lymphocyte proliferation.

In conclusion, the high doses vitamin A used here lead to minimal changes in either liver or kidney parenchyma resulting in an increase in the number of apoptotic cells in the liver and among tubular epithelium. Regarding lymphatic tissues, vitamin A seemed to act locally, enhancing lymphocyte proliferation or activation. Thus, it may be concluded that the used doses are not toxic for the length of the experimental period.

The differences in the results in this study and previous studies may be due to using different doses and forms of vitamin A, different lengths of experimental period, and also using different routes of administration or supplementation. It is recommended that further study is to be carried out using larger sample sizes and higher doses of vitamin A in healthy and infected or sick rats. These results set a base for more extensive research into the effects of vitamin A overdose with the hope of extrapolation to humans.

*

The authors thank Dr. Soad Shaker Ali for her help with the histology.

Funding: This research was partially funded by a King Abdulaziz City of Science and Technology grant.

References

- BELLOVINO, D., APREDA, M., GRAGNOLI, S., MASSIMI, M. & GAETANI S. (2003): Vitamin A transport: in vitro models for the study of RBP secretion. *Mol. Aspects Med.*, *24*, 411–420.
- BEN-AMOTZ, A., VOLKIS, B. & MOKADY, S. (2005): Selective distribution of b-carotene stereoisomers in rat tissues. *Nutr. Res.*, *25*, 1005–1012.
- CHANDRA, R.K. (1993): Nutrition and the immune system. *Proc. Nutr. Soc.*, *52*, 77–84.
- COLAKOGLU, N. & KÜKNER, A. (2003): Effects of high dose retinoic acid on adult rat liver: electron microscopic and immunohistochemical study. *Nutr. Res.*, *23*, 509–517.
- CUNNINGHAM-RUNDLES, S., MCNEELEY, D.F. & MOON, A. (2005): Mechanisms of nutrient modulation of the immune response. *J. Allergy Clin. Immunol.*, *115*, 1119–1125.
- FUCHS, J. (1999): Alcoholism, malnutrition, vitamin deficiencies, and the skin. *Nutr. Res.*, *17*, 457–462.
- JEYAKUMAR, S.M., VAJRESWARI, A. & GIRIDHARAN, N.V. (2005): Chronic dietary vitamin A supplementation regulates obesity in an obese rat model. *Obesity*, *14*, 52–59.
- LI, K., ZENG, S., GAO, J., CHEN, L. & WANG, Y. (2009): The effect of vitamin A deficiency in maternal rats on tumor formation in filial rats. *J. Pediatr. Surg.*, *44*, 565–570.
- MCDOWELL, L.R. (2000): *Vitamins in animal and human nutrition*, 2nd edition, Iowa State University Press, USA, pp. 15–82.
- MIURA, K., NAKAJIMA, Y., YAMANAKA, N., TERAOKA, K., SHIBATO, T. & ISHINO, S. (1998): Induction of apoptosis with fusarenon-X in mouse thymocytes. *Toxicology*, *127*, 195–206.
- PENNISTON, K.L. & TANUMIHARDJO, S.A. (2006): The acute and chronic toxic effects of vitamin A. *Am. J. Clin. Nutr.*, *83*, 191–201.
- RAMANATHAN, V.S., HENSLEY, G., FRENCH, S., EYSSELEIN, V., CHUNG, D., REICHER, S. & PHAM, B. (2009): Hypervitaminosis A inducing intra-hepatic cholestasis – a rare case report. *Exp. Mol. Pathol.*, *88*, 324–325.
- RAOOFI, A., ASADI, F., MARDJANMEHR, S.H. & KAZEMPOOR, R. (2010): The effects of hypervitaminosis A in sheep following intramuscular administrations of vitamin A. *Fd Chem. Toxicol.*, *48*, 193–195.
- SHINTAKU, T., MURATA, T., YAMAGUCHI, K. & MAKITA, T. (1998): Hepatic histopathology of vitamin A overdose in mouse liver. *J. Electron Microsc.*, *47*, 263–267.
- VILLAMOR, E. & FAWZI, W.W. (2005): Effects of vitamin A supplementation on immune responses and correlation with clinical outcomes. *Clin. Microbiol.*, *18*, 446–464.
- WEDNER, S.H. & ROSS, D.A. (2008): Vitamin A deficiency and its prevention. -in: KRIS H. (ed.) *International encyclopedia of public health*. Academic Press, Oxford, UK, pp. 526–532.