

Acta Veterinaria Hungarica 62 (1), pp. 33–41 (2014)

DOI: 10.1556/AVet.2013.058

First published online 11 December 2013

DATA ON THE PARASITOLOGICAL STATUS OF GOLDEN JACKAL (*CANIS AUREUS* L., 1758) IN HUNGARY

András TAKÁCS¹, László SZABÓ², Lajos JUHÁSZ¹, András Attila TAKÁCS³,
József LANSZKI⁴, Péter Tamás TAKÁCS⁵ and Miklós HELTAI^{2*}

¹Centre for Agricultural and Applied Economic Sciences, University of Debrecen, Debrecen, Hungary; ²Institute for Wildlife Conservation, Szent István University, Péter K. u. 1, H-2100 Gödöllő, Hungary; ³Faculty of Geoinformatics, University of West Hungary, Székesfehérvár, Hungary; ⁴Department of Nature Conservation, University of Kaposvár, Kaposvár, Hungary; ⁵Sárospatak, Hungary

(Received 24 October 2012; accepted 2 April 2013)

In Hungary, twenty *Canis aureus* individuals were submitted to parasitological examinations in 2010–2012. Two Coccidia: *Cystoisospora canis* (15%) and *Toxoplasma*-type oocysts (5%), one Trematoda: *Alaria alata* (10%), six Cestoda: *Mesocestoides lineatus* (20%), *Echinococcus granulosus* (10%), *Dipylidium caninum* (5%), *Taenia hydatigena* (15%), *Taenia pisiformis* (20%), *Taenia crassiceps* (40%), and nine Nematoda: *Angiostrongylus vasorum* (10%), *Crenosoma vulpis* (30%), *Capillaria aerophila* (5%), *Toxocara canis* (20%), *Toxascaris leonina* (15%), *Trichuris vulpis* (10%), *Ancylostoma caninum* (45%), *Uncinaria stenocephala* (40%), *Capillaria plica* (45%) have been identified. *Angiostrongylus vasorum* has been reported from carnivores in Europe, Africa, South America and North America. The helminth *A. vasorum* or French heartworm is a metastrongylid nematode, widely distributed in Western Europe, that infects the pulmonary arterial tree of dogs, various species of foxes, wolves, Eurasian badgers, coyotes and stoats. To our knowledge, this is the first report of natural *A. vasorum* infection in golden jackal.

Key words: Parasites, *Angiostrongylus vasorum*, golden jackal, Hungary

The golden jackal (*Canis aureus*), a species that had become extinct in the territory of Hungary earlier, started to recolonise the areas near the southern borders of the country more than two decades ago (Szabó et al., 2009). The species has a high population density (2.5–4 family groups/km², 2–4 individuals/group) in the southern part of Hungary, especially in Baranya county (Lanszki et al., 2007). The golden jackal is a species characterised by extremely high adaptability. Its food acquisition habits are based on solitary hunting in addition to hunting

*Corresponding author; E-mail: heltai.miklos@gmail.com; Phone: 0036 (28) 522-086; Fax: 0036 (28) 522-989; Mobile: 0036 (30) 474-6732

in pairs as well as together with family members in the period of teaching the young to hunt. The golden jackal is a potential competitor of the red fox (*Vulpes vulpes*). It uses the food sources available in the area inhabited by it, and its main food source is constituted by small mammals present in some areas in a large biomass, as well as animal cadavers. Besides the above food sources, the golden jackal eats birds, plants (fruits, maize kernels, other plant seeds) as well as insects. In addition, occasionally the young or injured (e.g. wounded) individuals of large game species and domestic animals also serve as its food sources (Lanszki et al., 2006). Its reproduction takes place in a manner typical of gregarious species of the Canidae family (Macdonald, 1979), and it bears the greatest resemblance to the reproduction of wolves (Lapini et al., 2009). Very little information is available on the parasite fauna of the golden jackal, with only two studies being known from Europe. During a study involving 13 individuals in Bulgaria (Trifonov et al., 1970), 1 Trematoda, 2 Nematoda and 5 Cestoda species were detected, while a study conducted in Greece on a total of five golden jackals (Papadopoulos et al., 1997) revealed the presence of as few as five parasite species (1 Trematoda, 1 Cestoda and 3 Nematoda species). The parasite fauna of jackals in Iran was found to be much more diverse (Sadigham, 1969; Dalimi and Mobedi, 1992; Dalimi et al., 2006; Meshgi et al., 2009), as the studies conducted there demonstrated the presence of 24 parasite species including 3 Trematoda, 8 Nematoda, 11 Cestoda and 2 Acanthocephala species.

The objective of this study was to obtain data on endoparasite infections of the golden jackal, for the first time in Hungary.

Materials and methods

In the period between 1 October 2010 and 21 June 2012, 17 golden jackals brought down during individual hunts and 3 golden jackals hit by vehicles were examined by parasitological dissection. The animals originated from the geographic areas shown in Fig. 1. According to age estimation based on appearance, body measurements and dentition, the animals belonged to the following age categories: 3 juvenile females (less than 1 year old), 2 juvenile males, 4 subadult males, 4 subadult females, 3 adult females and 4 adult males.

All internal organs removed during evisceration were stored and transported in closed, drip-proof, double-insulated bags. The animals' head and internal organs were placed in a freezer box and, after defrosting them one by one at the appropriate time, subjected to parasitological examination. The oesophagus and the trachea were opened, and impression smears were taken from the mucous membranes with a microscope slide. The heart and the lung halves were taken out of the thoracic cavity in their entirety. From the removed heart, a blood sample was taken into a citrated blood collection tube and later subjected to Knott's

test for the presence of microfilariae. The large veins and arteries were cut through at the remotest possible point from the heart, the heart was cut open and its exposed chambers, together with the large blood vessels, were flushed with physiological saline. The lung was placed into a separate dish, cut open up to the bifurcation of the large bronchi, and then its sharp margins were cut off with a pair of scissors at a width of 1 cm. The chambers of the heart and the small and large bronchi of the lung halves were flushed with physiological saline solution using a large syringe. Subsequently, the lung was cut into pieces the size of sugar cubes and, after soaking for a few hours, the content of the pieces was squeezed out and the fluid was decanted. The sediment was placed in a Petri dish and examined under a stereomicroscope. Muscle samples taken from the crura of the diaphragm and the coccygeal muscle were examined for the presence of *Trichinella* larvae by trichinostomy (using the so-called compressorium technique). A total of 7 muscle samples the size of a rice grain from each crus of the diaphragm and 28 samples from the coccygeal muscle were examined. Six- to eight-centimetre-long sections of the duodenum were cut open, their content was collected in a Petri dish and examined by stereomicroscopy. The remaining parts of the small intestine were cut into 20- to 30-cm pieces, and helminths were collected from the intestinal content after clarification. The helminths and helminth chains were placed into 7% formalin and then stored in 70% ethanol. For flotation of the individual faecal samples magnesium sulphate solution with a density of 1.28–1.32 was used.

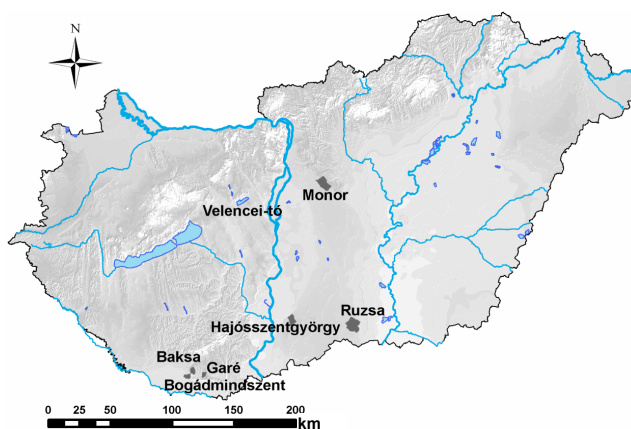


Fig. 1. Spatial distribution of the golden jackals involved in the study

The oocysts of *Cystoisospora canis* and *Toxoplasma* species were detected by faecal examination and the helminth species were identified on the basis of their morphological characteristics and egg size. Species identification of the parasites was done according to the works of Kotlán (1961), Verster (1969), Edwards and Herbert (1981), Khalil et al. (1994) and Rommel et al. (2000).

Results

Cystoisospora canis oocysts occurred in low numbers in 2 adult male golden jackals and in 1 subadult female, while *Toxoplasma*-type oocysts were found in 1 adult male. The fluke *Alaria alata* was found in 2 adult males, while infection with the nematode *Trichuris vulpis* was detected in 1 adult female and 1 adult male golden jackal. *Ancylostoma caninum* occurred in 2 juvenile male, 3 juvenile female, 1 adult male and 3 adult female jackals. *Uncinaria stenocephala* was found in 3 juvenile females, 2 juvenile males and 3 adult females. *Capillaria plica* was present in 1 adult female, 4 subadult males and 4 adult males. *Toxocara canis* was recovered from 4 adult males, while *Toxascaris leonina* from 1 adult female and 2 adult males.

In this study, 2 male (Fig. 2) and 6 female specimens (Fig. 3) of *Angiostrongylus vasorum* were recovered from the left ventricle of the heart and the pulmonary artery of a juvenile female and an adult male golden jackal.



Fig. 2. The tail end of a male *Angiostrongylus vasorum* identified from golden jackal

The lungworm *Crenosoma vulpis* was detected in 4 adult male and 2 subadult female jackals, while *Capillaria aerophila* occurred in a single adult male. Four adult male jackals were found to be infected with a low number of *Mesocostoides lineatus* specimens. *Echinococcus granulosus* was found in 1 juvenile female and 1 adult female jackal. *Dipylidium caninum* occurred in 1 adult male. The cestode *Taenia hydatigena* was identified in the small intestine of 3 adult male jackals, while *T. crassiceps* was present in a total of 8 golden jackals (2 adult and 2 juvenile females and 4 adult males). *Taenia pisiformis* was found in 3 adult male jackals and in 1 adult female.

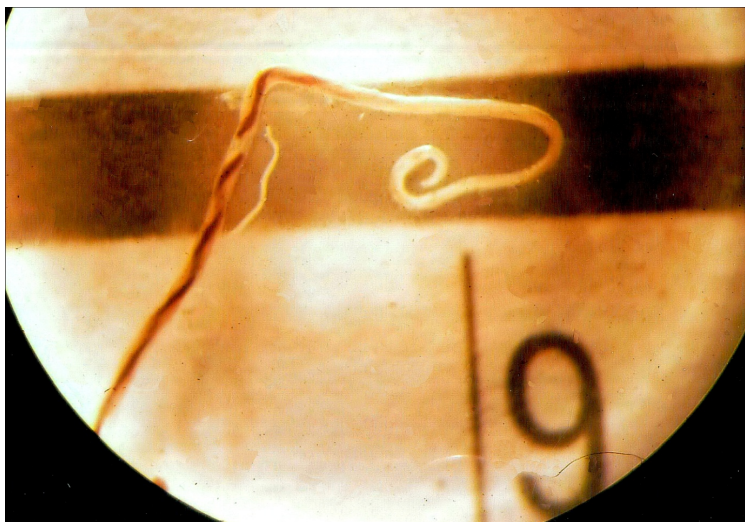

Fig. 3. A female *Angiostrongylus vasorum* identified from golden jackal

The results of Knott's test for detecting microfilariae in the blood were negative.

The overall data of parasite recoveries are presented in Table 1.

Table 1

Helminth infection of the golden jackals examined (n = 20)

Parasite species	No. of infected hosts	Extensity, %	No. of worms found
<i>Cystoisospora canis</i>	3	15	
<i>Toxoplasma</i> -type oocysts	1	5	
<i>Alaria alata</i>	2	10	40
<i>Mesocestoides lineatus</i>	4	20	24
<i>Echinococcus granulosus</i>	2	10	41
<i>Dipylidium caninum</i>	1	5	4
<i>Taenia hydatigena</i>	3	15	7
<i>Taenia crassiceps</i>	8	40	40
<i>Taenia pisiformis</i>	4	20	18
<i>Trichuris vulpis</i>	2	10	19
<i>Ancylostoma caninum</i>	8	40	166
<i>Uncinaria stenocephala</i>	8	40	78
<i>Angiostrongylus vasorum</i>	2	10	8
<i>Crenosoma vulpis</i>	6	30	29
<i>Capillaria aerophila</i>	1	5	5
<i>Capillaria plica</i>	9	45	65
<i>Toxocara canis</i>	4	20	26
<i>Toxascaris leonina</i>	3	15	9

Discussion

All animals harboured parasites. Parasite species specific for Canidae occurred in large numbers in our study material (Table 1). Of the helminth species detected in red foxes during our previous study conducted in Kétújfalu, Baranya county (Takács, 2001), the species *A. alata*, *T. leonina*, *A. caninum* and *C. plica* were found in the golden jackal as well. Data on the occurrence of the lungworm species *A. vasorum* in red foxes and dogs in Hungary were reported by Sréter et al. (2003) and Fukár et al. (2007), respectively.

So far the parasite fauna of the golden jackal has not been studied in Hungary. By examining 13 golden jackals in Bulgaria, Trifonov et al. (1970) found the following helminth species: *U. stenocephala* (64%), *T. hydatigena* (55%), *Trichinella spiralis* larvae (45% – these did not occur in the present study), *T. leonina* (36%), *M. lineatus* (27%), *E. granulosus* (23%), *T. pisiformis* (18%), *M. multiceps* (9% – not found in the present study) and *A. alata* (9%). The further 10 helminth species detected by us had not occurred in the Bulgarian study. The examination of 5 golden jackals in Greece revealed the presence of *A. alata* (20%), *T. canis* (40%), *U. stenocephala* (80%), *A. caninum* (20%) and *T. pisiformis* (20%) (Papadopoulos et al., 1997). Dalimi et al. (2006) reported data on the helminth infection of 10 jackals examined in Iran, demonstrating the presence of *T. canis* (10%), *T. leonina* (30%), *T. hydatigena* (10%), *D. caninum* (20%) and *M. lineatus* (70%). However, *E. granulosus*, *A. caninum* and *U. stenocephala* did not occur in their study material. The helminth *A. vasorum* was not detected in any of the above-cited studies. To the best of our knowledge, there are no data in the international literature on the detection of *A. vasorum* in naturally infected golden jackals, although experimental infection of both jackals and cats with this nematode has been successful, and the host range of *A. vasorum* includes several fox species and also the dog (Bolt et al., 1994; Conboy, 2000).

The fact that the low-pathogenicity fluke species *A. alata*, known to occur also in the small intestine of foxes in Hungary, is a member of the helminth fauna of jackals is indicative of the presence of water snail intermediate hosts that can be taken up by the host in the aquatic habitats (Takács, 2001). In Germany, 30% of a total of 101 foxes examined were found to be infected by that fluke (Steinbach et al., 1994). In the aquatic habitats located in several places near our sample collection sites, not only the dog and the fox but also the jackal can be the definitive host of the cestode *M. lineatus*. Of the taeniid tapeworms, the cysticercus tenuicollis larval form of *T. hydatigena* develops in the abdominal cavity and liver of farm animals that have died or been predated on, including sheep and pigs, as well as wild boar (*Sus scrofa*) and roe-deer (*Capreolus capreolus*), and golden jackals may have access to these infected intermediate hosts. Cysticercus longicollis, the larval form of *T. crassiceps*, develops in the abdominal cavity of small mammal intermediate hosts. In certain periods, common voles (*Microtus*

arvalis), wood mice (*Apodemus* spp.) and bank voles (*Myodes glareolus*) constitute the main food source of jackals (Lanszki et al., 2006), and thus jackals may easily become infected by the tapeworm *T. crassiceps*. The intermediate host of *cysticercus pisiformis*, the larval form of *T. pisiformis* is the brown hare (*Lepus europaeus*). The presence of this tapeworm in jackals is suggestive of predation on the brown hare (Boch and Schneidawind, 1988), which has been proved by the study of feeding habits (Lanszki et al., 2006).

The most important hosts of *E. granulosus* are the dog and, of the free-living Canidae, the wolf (*Canis lupus*) and the jackal, but this tapeworm occurs in the dingo (*Canis lupus dingo*) and the hyena (*Hyaena hyaena*) as well (Kotlán, 1961). *Echinococcus hydatidosus*, the infective larva of *E. granulosus* develops in the liver and lungs of farm animals, wild boar, free-living ruminants (and rarely humans) acting as intermediate hosts (Kassai, 2003). According to an improper hunting practice, the viscera of game bagged during hunts are left at the place of bagging and, thus, they may be consumed by birds, foxes, stray dogs and, in areas where jackals occur, mainly by jackals.

It is striking that, according to the data obtained during the present study, the jackal is often infected by hookworms (*A. caninum*, *U. stenocephala*). When present in populations comprising more than two hundred specimens, *A. caninum* may cause severe disease and death in puppies (Kassai, 2003). Humans may also become infected by *A. caninum* (Prociv and Croese, 1996; Shamir et al., 2001).

Trichinella larvae were not found in the muscle samples taken from the crura of the diaphragm and the coccygeal muscle. In contrast to this, golden jackals infected by trichinellae (*T. britovi*) have already been found in Bulgaria (Trifonov et al., 1970) as well as in Romania, a country neighbouring Hungary (Blaga et al., 2008).

In summary, it can be stated that the intensity and extensity of helminth infection in golden jackals originating from Baranya, Pest, Fejér and Bács-Kiskun counties were low; thus, this infection is unlikely to play a notable epidemiological role in the infection of domestic animals and humans. More importantly, the present study provided the first record on the occurrence of the nematode *A. vasorum* in golden jackal.

Acknowledgements

We would like to thank Game Management Engineers Zsolt Dani and István Takács, Game Management Engineer Imre Víg, a graduate of the University of Debrecen and our colleagues at the Institute for Wildlife Conservation, Szent István University for their great help in the collection, submission and storage of the study materials. We are grateful to Professor István Hajtós for his useful advice given during the preparation of this manuscript. The publication was supported by the 'Research Faculty Grant' of the Hungarian Ministry of Human Resources' (registration no.: 17586-4/2013/TUDPOL).

References

- Boch, J. and Schneidawind, H. (1988): Krankheiten des Jagdbaren Wildes. Verlag Parey, Berlin. pp. 398.
- Blaga, R., Gherman, C., Seucom, D., Cozma, V. and Boireau, P. (2008): First identification of *Trichinella* sp. in golden jackal (*Canis aureus*) in Romania. J. Wildl. Dis. **44**, 457–459.
- Bolt, G., Monrad, J., Koch, J. and Jensen, A. L. (1994): Canine angiostrongylosis: a review. Vet. Rec. **135**, 447–452.
- Conboy, G. A. (2000): Canine angiostrongylosis (French heartworm) (30-May-2000). http://www.ivis.org/advances/parasit_bowman/conboy_angiostrongylosis/ivis.pdf. In: Bowman, D. D. (ed.) Companion and Exotic Animal Parasitology. International Veterinary Information Service (www.ivis.org).
- Dalimi, A. and Mobedi, I. (1992): Helminth parasites of carnivores in northern Iran. Ann. Trop. Med. Parasit. **86**, 395–397.
- Dalimi, A., Sattari, A. and Motamedi, G. (2006): A study on intestinal helminths of dogs, foxes and jackals in the western part of Iran. Vet. Parasitol. **142**, 129–133.
- Edwards, G. T. and Herbert, I. V. (1981): Some quantitative characters used in the identification of *Taenia hydatigena*, *T. ovis*, *T. pisiformis* and *T. multiceps* adult worms and *T. multiceps* metacestodes. J. Helminthol. **55**, 1–7.
- Fukár, O., Majoros, G., Fok, É. and Farkas, R. (2007): Occurrence of *Angiostrongylus vasorum* in dogs from Hungary [abstract only, in Hungarian]. Magyar Állatorvosok Lapja **129**, 505.
- Kassai, T. (2003): Helminthology [in Hungarian]. Medicina Könyvkiadó, Budapest. 369 pp.
- Khalil, L. F., Jones, A. and Bray, R. A. (eds) (1994): Keys to the Cestode Parasites of Vertebrates. CAB International, Wallingford, United Kingdom. 751 pp.
- Kotlán, S. (1961): Parasitology [in Hungarian]. Mezőgazdasági Kiadó, Budapest. 455 pp.
- Lanszki, J., Heltai, M. and Szabó, L. (2006): Feeding habits and trophic niche overlap between sympatric golden jackal (*Canis aureus*) and red fox (*Vulpes vulpes*) in the Pannonian eco-region (Hungary). Can. J. Zool. **84**, 1647–1656.
- Lanszki, J., Heltai, M., Szabó, L. and Frankhauzer, N. (2007): Study of the population density of golden jackal in Southern Transdanubia [in Hungarian]. Natura Somogyensis **10**, 373–388.
- Lapini, L., Molinar, I., Dorigo, L., Are, G. and Beraldo, P. (2009): Reproduction of the golden jackal (Mammalia, Carnivora, Canidae). Boll. Mus. civ. St. nat. Venezia **60**, 169–186.
- Macdonald, D. W. (1979): The flexible social system of the golden jackal, *Canis aureus*. Behav. Ecol. Sociobiol. **5**, 17–38.
- Meshgi, B., Eslami, A., Bahonar, A. R., Kharrazian-Moghadam, M. and Gerami-Sadeghian, A. (2009): Prevalence of parasitic infection in the red fox (*Vulpes vulpes*) and golden jackal (*Canis aureus*) in Iran. Iran. J. Vet. Res. **10**, 387–391.
- Papadopoulou, H., Himonas, C., Papazahariadou, M. and Antoniadou-Sotoriadou, K. (1997): Helminths of foxes and other wild carnivores from rural areas in Greece. J. Helminthol. **71**, 227–232.
- Prociv, P. and Croese, J. (1996): Human enteric infection with *Ancylostoma caninum*: hookworms reappraised in the light of a new zoonosis. Acta Trop. **62**, 23–44.
- Rommel, M., Eckert, J., Kutzer, E., Körting, W. and Schnieder, T. (eds) (2000): Veterinärmedizinische Parasitologie. 5th edition. Parey Buchverlag, Berlin. 915 pp.
- Sadigham, A. (1969): Helminth parasites of stray dogs and jackals in Shahsavar area, Caspian region, Iran. J. Parasitol. **55**, 372–374.
- Shamir, M., Yakobson, B., Baneth, G., King, R., Dar-Verker, S., Markovics, A. and Aroch, I. (2001): Antibodies to selected canine pathogens and infestation with intestinal helminths in golden jackals (*Canis aureus*) in Israel. Vet. J. **162**, 66–72.
- Sréter, T., Széll, Z., Marucci, G., Pozio, E. and Varga, I. (2003): Extraintestinal nematode infections of red foxes (*Vulpes vulpes*) in Hungary. Vet. Parasitol. **115**, 329–334.

- Steinbach, G., Welzel, A., Von Keyserlinck, M. and Stoye, M. (1994): Zur Helminthenfauna des Rotfuchses (*Vulpes vulpes*) in Südniedersachsen. Teil 1, Nematoden und Trematoden. Z. Jagdwiss. **40**, 30–39.
- Szabó, L., Heltai, M., Szűcs, E., Lanszki, J. and Lehoczki, R. (2009): Expansion range of the golden jackal in Hungary between 1997 and 2006. Mammalia **73**, 307–311.
- Takács, A. (2001): Data on the parasitological status of the red fox in Hungary [in Hungarian, with English abstract]. Magyar Állatorvosok Lapja **123**, 100–107.
- Trifonov, T., Meskov, S. and Stoimenov, K. (1970): Helminth fauna of the jackal (*Canis aureus*) in the Strandzha Mountains. Veterinarno Meditsinski Nauki **7**, 51–54.
- Verster, A. (1969): A taxonomic revision of the genus *Taenia* Linnaeus, 1758 s. str. Onderstepoort J. Vet. Res. **36**, 3–58.