

# **Evaluation of a Combination Allograft Material Compared to DFDBA in Alveolar Ridge Preservation**

by

**Sanju P. Jose**

B.S., University of Maryland Baltimore County, 2008

D.D.S., University of Maryland School of Dental Medicine, 2013

Submitted to the Graduate Faculty of  
University of Pittsburgh School of Dental Medicine in partial fulfillment  
of the requirements for the degree of  
Master of Dental Science

University of Pittsburgh

2017

UNIVERSITY OF PITTSBURGH

School of Dental Medicine

This thesis was presented

by

Sanju P. Jose

It was defended on

June 09, 2017

and approved by

Anitha Potluri, BDS, DMD, MDcs, Department of Oral and Maxillofacial Radiology

Andrejs Baumhammers, DDS, MS, Department of Periodontics

Thesis Director: Pouran Famili, DDS, DMD, MDS, MPH, PhD, Department of Periodontics

Copyright © by Sanju P. Jose

2017

**Evaluation of a Combination Allograft Material Compared to DFDBA in Alveolar Ridge Preservation**  
Sanju P. Jose, D.D.S.

University of Pittsburgh, 2017

*Purpose:* The aim of this split-mouth clinical study was to compare DFDBA to a combination allograft that is 70% FDBA and 30% DFDBA, in alveolar ridge preservation. Changes in ridge dimension were evaluated, as was graft consolidation, ability to place implants, and additional grafting needs.

*Materials and methods:* 20 extraction sockets in 6 patients (3 males, 3 females) who presented to the School of Dental Medicine were selected to be part of the study. These patients required 20 extractions with ridge preservation, with the eventual goal of being restored with dental implants. Extraction sockets were randomly assigned to either the control group (DFDBA) or the test group (combination allograft). Immediately after extraction, a limited CBCT was taken to evaluate the socket. Following the scan, the extraction sockets received the assigned graft material, was covered with fast absorbing collagen dressing, and sutured with polyglactin. After 6 months, a second scan was taken. 3-D rendering software was used to compare the two scans and measure horizontal dimensional changes to the ridge. CBCT sections were also used to evaluate graft integration. Ability to place implants and additional grafting needs at the time of implant placement was also noted.

*Results:* Despite our best efforts to preserve the ridge, some dimensional change is bound to occur. This change was found as a loss of 0.67 mm for the test group and 0.74 mm for the control group. Graft integration was excellent for both the control and test groups. Implant

placement was possible without any additional augmentation in these sites that underwent alveolar ridge preservation.

*Conclusion:* Extraction followed by alveolar ridge preservation using either demineralized freeze-dried bone allograft or a 70:30 combination allograft resulted in minimal and clinically negligible changes in alveolar ridge dimensions. It can also be concluded that there were minimal and clinically negligible differences between the two grafting materials when measuring changes in alveolar ridge dimensions. CBCT scans showed excellent graft integration for both materials, and implants were placed in sites grafted with both materials without any need for additional augmentation. These findings need to be confirmed with a larger sample.

## TABLE OF CONTENTS

<b>PREFACE.....</b>	<b>IX</b>
<b>BACKGROUND.....</b>	<b>1</b>
<b>MATERIALS/METHODS.....</b>	<b>11</b>
<b>RESULTS .....</b>	<b>13</b>
<b>DISCUSSION .....</b>	<b>21</b>
<b>CONCLUSION .....</b>	<b>24</b>
<b>BIBLIOGRAPHY.....</b>	<b>25</b>

## LIST OF TABLES

Table 1. Changes in ridge dimension.....	13
--	----

## LIST OF IMAGES

Image 1. DFDBA Pre.....	14
Image 2. DFDBA Post .....	15
Image 3. FDBA Pre.....	16
Image 4. FDBA Post.....	16
Image 5. Loss of buccal plate pre-grafting .....	17
Image 6. Regeneration post-grafting.....	18
Image 7. Implant surgery A .....	19
Image 8. Implant surgery B .....	20



## **PREFACE**

**Acknowledgments:** The author would like to thank Dr. Poursan Famili for all her mentorship, guidance, and help with this study, including securing a grant from Nobel Biocare to offset any costs to patients. The author would also like to thank both Dr. Anita Potluri and Dr. Andrejs Baumhammers for their guidance and for their willingness to be part of the thesis committee.

## **Background**

Following tooth extraction, the bony socket will fill in with a blood clot, which over several months, will be replaced with osseous tissue. However, the bone fill that occurs during this process will typically result in an overall loss of bone, both in a vertical as well as a horizontal direction (13,14). Various studies have shown up to 56% resorption of the buccal bone in a horizontal direction, and up to 30% of the lingual bone in a horizontal direction. Overall, up to 50% of the ridge width (horizontal dimension) has been shown to be lost following extraction (16-19). With this pattern of resorption, the remaining bone volume tends to be in a palatal/lingual position, and this can have a negative outcome in terms of implant placement in an ideal position with the final prosthesis in mind (15,16). Most of this bone loss occurs in the first month following extraction, and by the end of 6 months, an average of 3 to 5 mm of horizontal bone width can be lost (1). A systematic review found that 29% to 63% of horizontal bone width and 11% to 22% of vertical bone height can be lost following a period of 6 months post-extraction (1). Depending on the specific situation, bone loss may be even greater. For example, if there is an ill-fitting prosthesis that is fabricated for the patient to replace the lost tooth putting excessive pressure on the ridge, bone loss may be accelerated. In patients that are interested in having the extraction site restored with an implant in the future, this loss of vertical and horizontal bone can be damaging. These patients may then need a guided bone regeneration procedure to augment their jaw ridge prior to the placement of a dental implant. These procedures can be extensive, especially if the augmentation requires vertical gain. Gaining horizontal bone is predictable, as patients can undergo a gingival flap procedure with placement of bone or bone substitute along with a resorbable or non-resorbable membrane. However, gaining vertical bone is not as predictable, and patients may have to undergo more invasive

autogenous grafting procedure, which involves a second surgical site to remove patient's own bone to serve as a donor tissue to the recipient site (20). Moreover, with these augmentation procedures, there can be healing periods approaching 6 to 9 months, further delaying the placement of the implant having the missing site replaced. If these augmentation procedures can be avoided, patients will benefit from avoiding additional surgeries and having the missing site replaced sooner. Literature has not shown a specific grafting material to be superior in terms of preserving height and width of the ridge following extraction.

A recent clinical study compared hard and soft tissue changes after extraction and ridge preservation versus extraction sockets allowed to heal naturally (2). The control group had the blood clot following extraction stabilized with silk sutures. Meanwhile, the test group had extraction sockets grafted with porcine bone and collagen membrane, left to heal with secondary intention. The control group had vertical bone loss of 2.1 mm on the buccal aspect and 2 mm on the lingual aspect. The control group also had 3.6 mm of average resorption in the horizontal dimension. In comparison, the test sites had vertical bone loss of 1.1 mm on the buccal aspect and 0.9 on the lingual aspect. The test group also had 1.6 mm of average resorption in the horizontal dimension. In terms of the final outcome of being able to place a dental implant in these sites, 42% of the control sites needed further augmentation at the time of implant surgery. Only 7% of the test sites needed further augmentation at implant placement (2). This study showed that ridge preservation with grafting material in combination with resorbable collagen membrane that is left exposed following tooth extraction minimized the loss of ridge contours from remodeling, when compared to extraction sockets left to heal spontaneously. This study demonstrated and agreed with previous results that complete ridge preservation is not achievable with ridge preservation (2). This study also showed that in the non-grafted sockets, buccal bone

that were considered the thinnest, were more likely to have higher bone resorption. However, in grafted sites, this association was not seen. The ridge preservation, therefore, minimized the resorption seen in thin, buccal bone of non-grafted sites.

A systematic review on alveolar ridge preservation evaluated the effect of alveolar ridge preservation in comparison to non-grafted socket healing (3). In addition to looking at the changes in ridge dimension after extraction with ridge preservation or extraction without grafting, this group also looked to evaluate histological characteristics in both groups. 11 studies included histological analysis via biopsies of trephine cores taken out at implant placement. In these 11 studies, 149 sockets healed without any grafting, while 181 sockets were grafted at the time of extraction. 2 studies reported significantly higher trabecular bone with ridge preservation when compared to unassisted socket healing. Significantly higher connective tissue in the non-grafted sites were reported by 2 studies (3). Significantly more vital bone in the non-grafted sites were reported by one study (3). Other histomorphometric parameters evaluated in these studies were not statistically significant. As is evident here, no particular advantage histologically, in terms of more vital bone, less connective tissue, or denser bone, has been demonstrated in various studies comparing grafted extraction sockets with non-grafted sites (3).

Another recent study also looked at both histologic differences and dimensional changes in the alveolar ridge between grafted and non-grafted extraction sockets. Primary outcomes were horizontal and vertical dimension changes, and percent of vital bone in the trephine core. Additional outcomes evaluated were changes in the buccal plate width and amount of connective tissue in the trephine core (4). The meta-analysis included 18 articles, 3 of which were controlled clinical trials, 14 of which were randomized clinical trials, and one cohort study (4). The horizontal dimension change ranged from -6.10 to 3.27 mm in the test groups and -4.56 to 1.30

mm in the control groups (non-grafted sockets). The vertical change ranged from -2.00 to 1.30 mm in the test groups, and -3.60 to 1.20 mm in control groups. Percentage of vital bone ranged from 28 to 66% in the test groups, and 25.70 to 54% in the control groups. This study further analyzed results based on the type of bone grafting material. With autografts, there was significantly less horizontal bone loss in the test group compared to the control group (-1.14 to -2.46 mm). There was also more vertical bone loss the control group (-1.17 compared to -0.62 mm). More vital bone was found in the autograft group compared to the unassisted group. With allografts, there were only limited studies that reported on outcomes, and these showered contrary results. With xenografts, all included studies showed outcomes favoring the grafted group when compared to unassisted socket healing. When evaluating secondary outcomes, specifically thickness of buccal plate, grafted sites showed less reduction or even gains, when compared to unassisted sockets (4). Connective tissue infiltration into the sockets were found to be 35.3 to 51.6% in the grafted sockets, compared to 59.1% in the non-grafted sites. 9.9% of grafted sockets needed further grafting at the time of implant surgery, whereas 20.8% of non-grafted sites needed additional augmentation. This, more recent meta-analysis seems to agree with previous studies in terms of alveolar ridge contour changes with grafting and unassisted sockets. This study also supports ridge preservation in terms of having more vital bone, less connective tissue infiltration, and less likelihood of needing additional grafting at the time of implant surgery, when compared to unassisted socket healing (4).

Histological characteristics of ridge preservation using collagen membrane and xenograft bone were evaluated in a clinical study, comparing a flapless approach to a flapped approach (5). It has been previously demonstrated by the same author that implants in augmented sites had similar survival rates compared to implants placed in native bone (5). The author has also shown

that ridge preservation allowed implant placement with less likelihood of additional need for augmentation. A full-thickness flap reflection during tooth extraction leads to increased loss of alveolar ridge dimension, most likely due to the severance of blood supply to the buccal bone (5). The specific objective of this study was to evaluate the outcome of full thickness flap and primary closure on histological healing of extraction sites augmented with a bone substitute material and collagen membrane, compared to a flapless technique where the grafted extraction socket and collagen membrane were left exposed to heal with secondary intent (5). Following 3 months post-extraction, re-entry was made, biopsies taken, and implants placed. Percentages of new bone formation (22.5 to 22.5%), soft tissues (59.3 and 59.4%) and residual graft materials (18.6 to 18.2%) were similar in both the flap and flapless groups. The authors concluded that due to the lack of difference between the flap and flapless approach, healing via secondary intent and leaving collagen membrane exposed did not negatively affect the quality of regenerated bone in the extraction socket (5). Therefore, it seems that although alveolar ridge dimensions may be negatively affected by a flapped approach, there are no histological differences in grafted extraction sockets when comparing a flapped approach to a flapless approach.

Following extraction, in addition to hard tissue changes, there can also be soft tissue changes. Combined, these hard and soft tissue changes will comprise the overall dimensional change of the alveolar ridge. Even though there may be adequate width of bone (hard tissue) for implant placement, loss of soft tissue following extraction can still compromise the esthetic outcome. A recent article from 2016 evaluated both soft and hard tissue remodeling of the alveolar ridge post extraction and ridge preservation. This study only included high-risk patients in the study, and attempted to identify specific predictors of remodeling (6). Patients were considered high risk when they presented with a thin-scalloped gingival biotype or incomplete

buccal bone wall. In these high-risk patients, teeth were extracted atraumatically without a flap elevation. Deproteinized bovine bone mineral collagen blocks were prepared for the individual sockets and placed, condensed, and wound sutured with monofilament sutures. At baseline (prior to extraction) and 4 months post-extraction, occlusal slides were captured by the same clinician. The horizontal dimension in the center of the tooth was captured both at baseline and 4 months post-extraction. The change in this dimension was expressed as a percentage of the overall value at baseline. Loss of dimension corresponded with a positive value, and gain of dimension corresponded with a negative value. In all patients, the initial dimension at baseline could not be maintained with extraction and ridge preservation. On average, the loss of horizontal dimension was 14%. All patients were able to have an implant placed without any further bone grafting procedure. The authors also evaluated tooth location (comparing central incisors, lateral incisors, cuspids and premolars), abscess, buccal bone loss and thickness of gingiva as determinants of alveolar ridge changes. The authors concluded that central incisors and cuspids were more likely to be affected by remodeling, as were sites with an abscess or buccal bone loss (6). This study agrees with previous studies in that dimensional changes in the ridge cannot be completely prevented even with ridge preservation techniques. However, as was shown in the study, even in patients considered to be high-risk, the dimensional changes post-extraction and ridge preservation did not prevent the placement of implants.

Various bone or bone substitute grafting materials have been used in ridge preservation techniques, and literature does not show one type to be superior to others. In addition to these materials, platelet-rich fibrin (PRF) has also been used in alveolar ridge preservation (7). PRF is a good source of cytokines and growth factors. It contains platelets, cytokines, and leukocytes, incorporated in a polymerized fibrin matrix. The growth factors contained may have positive

effects on angiogenesis, wound healing, and may promote osseous and soft tissue regeneration that can prove useful in alveolar ridge preservation (7). A clinical study from 2013 evaluated the effectiveness of PRF in maintaining the alveolar ridge following extraction, compared to extraction and unassisted healing. Socket orifices were evaluated in mesial-distal and buccal-lingual dimensions clinically. Alveolar ridge contours were evaluated using study models. Proximal bone changes were measured using standardized periapical radiographs (7). When evaluating the socket, the PRF group had quicker healing of the soft tissues at 4 weeks, compared to the unassisted socket. However, when marginal bone levels were evaluated via periapical radiographs, PRF group was comparable to unassisted socket healing group. Likewise, when evaluating alveolar ridge dimension changes, no difference was noted between the two groups. The authors concluded that although PRF can accelerate soft tissue healing at 4 weeks, it has not shown to be more effective than unassisted socket healing in terms of enhanced bone formation or alveolar ridge preservation (7). Based on this study, the use of PRF alone as a technique of alveolar ridge preservation is questionable, and other methods using bone or bone-substitute materials have shown to be more effective.

Following extraction, alveolar ridge preservation varies among sites. As previously discussed, changes in ridge width tend to be greater on the buccal, and changes in ridge height tend to be more significant in mandibular sockets compared to maxillary sockets (8). A study published in 2013 evaluated alveolar ridge changes following extraction and ridge preservation, comparing anatomic locations, specifically posterior maxilla to posterior mandible. Measurements were made immediately post-extraction and again at the time of implant placement. Immediately after extraction, ridge height and ridge width were similar for both jaws. Thickness of the buccal bone wall was 1.5 mm in the maxilla and 1.5 in the mandible. Palatal



bone wall thickness was 1.3 mm and lingual bone wall thickness was 2 mm. Differences did not reach statistical significance. At the time of re-entry for implant placement, mandibular sites gained on average 1 mm, while maxillary sites lost 0.2 mm. However, these changes were not statistically significant between the two groups. Horizontal width loss was 2-2.5 mm, statistically significant change from baseline. However, there was no significant difference between posterior maxilla and mandible (8). The study by this group shows that both posterior maxilla and posterior mandible behave similarly in terms of initial width and height, as well as in healing after extraction and ridge preservation. While some have maintained that ridge preservation is not necessary in the posterior mandible, this study proves otherwise, showing that it undergoes dimensional changes similar to that of posterior maxilla.

A very recent article from the Journal of Esthetic and Restorative Dentistry evaluated the effectiveness of alveolar ridge preservation in the anterior maxilla (9). The primary aim of the study was to determine if ridge preservation will result in preservation of at least 6 mm of horizontal width. This group evaluated 60 patients, with the eventual goal of extraction and single implant placement in the anterior maxilla. 20 patients were in the control group, and had extractions without simultaneous ridge preservation. 40 patients were in the test group and had ridge preservation at the time of extraction. At the time of implant placement, measurements were taken to evaluate ridge width. In the test group of extraction and ridge preservation, 82.5% of sites had an alveolar ridge width of at least 6 mm. However, in the control group of extraction without ridge preservation, only 35% of the sites had at least 6 mm of bone width. The odds of needing additional augmentation in this anterior maxillary esthetic zone was less in the group that was grafted at the time of ridge preservation (9). The authors concluded that ridge preservation was effective in providing for a minimal width of 6 mm that is required for implant

placement. The difference noted in this study suggests that ridge preservation is especially effective in the maxilla in avoiding a need for secondary augmentation. Without ridge preservation, there seems to be a high likelihood of additional augmentation.

It is clear that alveolar ridge preservation techniques minimize the amount of bone loss in both horizontal and vertical dimensions. It is also evident that ridge preservation reduces the need for additional augmentation, compared to unassisted socket healing (9). A systematic review further evaluated implant related treatment outcomes following alveolar ridge preservation (10). They concluded that implant placement was feasible without any significant difference in both groups. Bone levels, as well as the rates of survival and success of implants, were similar in both groups. However, the need for additional augmentation was decreased in the group where ridge preservation was done at the time of extraction (10). The literature seems to be consistent in that regardless of grafting or unassisted socket healing, there will be some degree of bone loss, especially in the horizontal dimension. However, with ridge preservation, this bone loss that occurs is less significant. Further, there is less likelihood that the patient will need additional bone augmentation in that particular site following ridge preservation, compared to unassisted socket healing. Histological studies show that there is less connective tissue infiltration in grafted sockets, and more mineralized bone, favoring ridge preservation. Marginal bone levels following implant placement, and survival/success rates seem to be similar in grafted and non-grafted sites. Therefore, it seems prudent to follow techniques of ridge preservation following extractions in sites where implants are to be placed in the future.

The market is currently flooded with various materials that can be used for this procedure, including allografts, which come from human bone, xenografts, which come from other species such as bovine, and alloplast, which are synthetic materials. Allograft is the most

frequently used material, and is typically used as freeze-dried bone allograft (FDBA) and demineralized freeze-dried bone allograft (DFDBA). FDBA acts as an osteoconductive scaffold and DFDBA has the added benefit of providing osteoinductive factors into the graft. FDBA has better physical characteristics, and this can be attributed to the fact that it remains mineralized at the time of grafting. However, due to this same fact, it does not have any osteoinductive characteristics. Therefore, both types have their benefits. FDBA, with its better physical characteristics, is more effective at maintaining space during the healing process. Maintaining space is very important during any grafting procedure, since this space maintenance allows the body to naturally resorb the graft material and replace with the body's own osseous tissue. If space is not maintained, ridge width and height can be lost during the healing process. Likewise, FDBA also remains in the grafted site longer, due to the fact that it is mineralized, and this can be advantageous as well. DFDBA, due to being demineralized, will resorb faster, and is less effective at maintaining space. However, its osteoinductive factors will encourage increased cell migration and osteogenesis in the grafted site, leading to more vital bone. There are limited studies that look at the longevity of implants in terms of grafted and native bone, and most studies instead refer to the amount of bone height and width instead. In line with this, studies that look at the quality of bone in grafted versus native bone are also limited. Long term implant success certainly depends not only on the amount of bone around the implant, but also on the quality and composition of bone. The potential of using a combination allograft for socket preservation may allow the clinician to reap the benefits of both DFDBA and FDBA, leading to both volume stability and increased quality/composition of bone. No reported study has compared combination allograft to DFDBA in terms of ridge dimension and graft integrity. This

pilot study will compare DFDBA to a novel combination allograft of FDBA/DFDBA in alveolar ridge preservation.

## **Materials/Methods**

In this randomized clinical study, we recruited, treated and followed patients presenting to the University of Pittsburgh School of Dental Medicine for extractions and implant placement. This study was conducted by the principal investigator at the University of Pittsburgh. The clinical study protocol and materials have been approved by the IRB (REN16100237/PRO14110066) of the institution. Informed consent was obtained.

*Patients:* In this pilot study with a split-mouth design, we recruited enough patients to have 10 control sites and 10 test sites. Patients that are under the medical care of a physician for any health condition which would contraindicate successful simple extraction will be excluded, including uncontrolled metabolic conditions, bleeding disorders, and smoking. All other subjects may be included. These patients were selected such that each patient would need at least two such extractions. Other inclusion criteria were: extraction socket was aligned with future implant placement, adequate occlusal space was available for future restoration, and bone loss was less than 50%. Extraction sites were randomly assigned in each patient to either combination allograft or DFDBA immediately prior to the surgical procedure.

*Surgical procedure:* Patients were anesthetized with 2% lidocaine with 1:100,000 epinephrine for the mandible and 4% septocaine with 1:100,000 epinephrine for the maxilla. Extractions were done in a minimally invasive manner, using luxators and elevators, without raising a mucoperiosteal flap in most situations. In cases where buccal dehiscence exists, mucoperiosteal flap was tunneled to place fast absorbing collagen dressing along this dehiscence

aspect to contain graft material. Sockets were curetted and irrigated adequately. Site-specific limited volume cone beam volumetric tomography scans were taken immediately after the extractions. The fresh extraction sockets received the assigned graft material, and were covered with fast absorbing collagen dressing. The oral tissues overlying the sites were closed and sutured with resorbable polyglactin sutures for secondary closure in a similar fashion. All patients were instructed in standard post-operative procedures.

*Graft materials:* A combination allograft was used in the test sites. This is a newly developed blend of 70% mineralized freeze-dried and 30% demineralized freeze-dried cortical bone. The particulate size range was 0.25 – 1 mm. Demineralized freeze-dried cortical bone allograft was used in the control sites. The particulate size range was 0.25 – 1 mm.

*Follow-up examinations:* Subject recall appointments for site evaluation were at one week, one month and six months after extraction. Sutures were removed after one week, and post-operative instructions given again. A second site-specific limited volume cone beam volumetric tomography scan was taken after six months of healing period.

*CBCT evaluation and clinical examination:* Baseline CBCT taken immediately after extraction were compared to the CBCT taken 6 months post-extraction, to assess changes in alveolar ridge dimensions, in terms of ridge width. The CBCT taken at 6 months post-extraction was also used to evaluate graft integration into the extraction sockets. Clinical exam was done at the time of implant placement to evaluate ridge integrity and quality of bone. The need for additional augmentation during implant surgery was also be evaluated.

## Results

Total of 10 sets of extraction sockets in 6 patients were used in this split mouth study. Immediately following extractions, a site-specific limited volume cone beam volumetric tomography scan was taken for all 20 extraction sockets. These scans were then analyzed using 3-D rendering software, and measurements were made for width. In case of thin buccal plate or missing buccal plate, measurement was made from the most coronal aspect of the existing cortical buccal plate, appearing as a dense, thick radiolucent outline on the software rendering. All extraction sockets received the randomly assigned graft material. In the case of missing buccal plate, the flap was undermined, and fast absorbing collagen dressing was placed on the buccal aspect as well, to contain the defect. All patients healed uneventful without any infections or other issues. Patients were recalled at the appropriate intervals, and a second site-specific limited volume cone beam volumetric tomography scan was taken for all 20 extraction sockets. These scans were also analyzed using 3-D rendering software. Using identifiable locations on the rendered images, attempt was made to approximate the same location for measurement in both scans. These measurements are shown in table 1, with ‘Pre’ being measurements taken from the first scan, and ‘Post’ being measurements taken following 6 months of healing post extraction and ridge preservation.

Site	Combination Allograft		DFDBA	
	Pre (in mm)	Post (in mm)	Pre (in mm)	Post (in mm)
1	7.8	6.8	6.1	6.9
2	7.5	7.7	6.2	6.5
3	8.7	8.6	6.5	5.6

4	13.4	12.2	8.6	7.6
5	7.5	8.2	8.1	6.5
6	9.1	8.8	8.6	8.3
7	8.7	7.2	8.3	7.4
8	7.3	6.2	9.4	8.2
9	8.1	6.9	6.2	5.4
10	7.2	6.0	6.1	5.3
Mean	8.53	7.86	7.41	6.67
Net Change	-0.67		-0.74	

As is evident in table 1, extraction followed by ridge preservation still led to some loss of alveolar ridge width as a general trend, although certain sites gained some width. With the test material, net loss in width was 0.67 mm, and with the control group using demineralized freeze-dried bone allograft, net loss in width was 0.74 mm.

Image 1

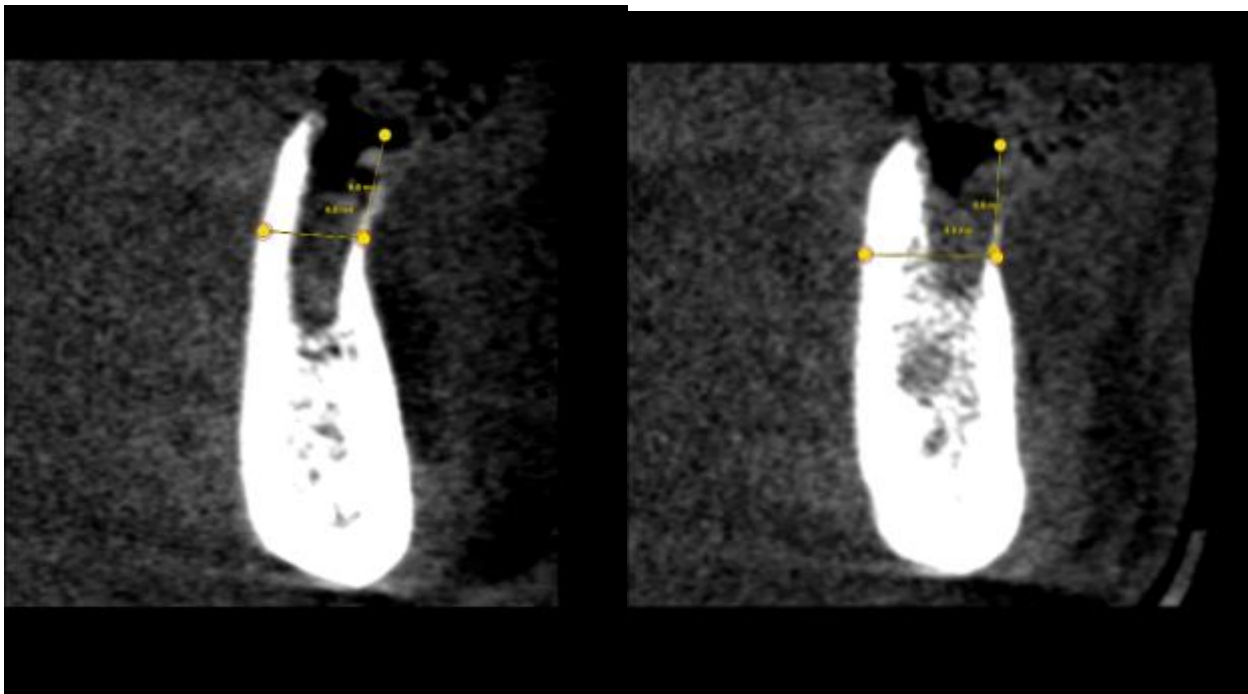


Image 2

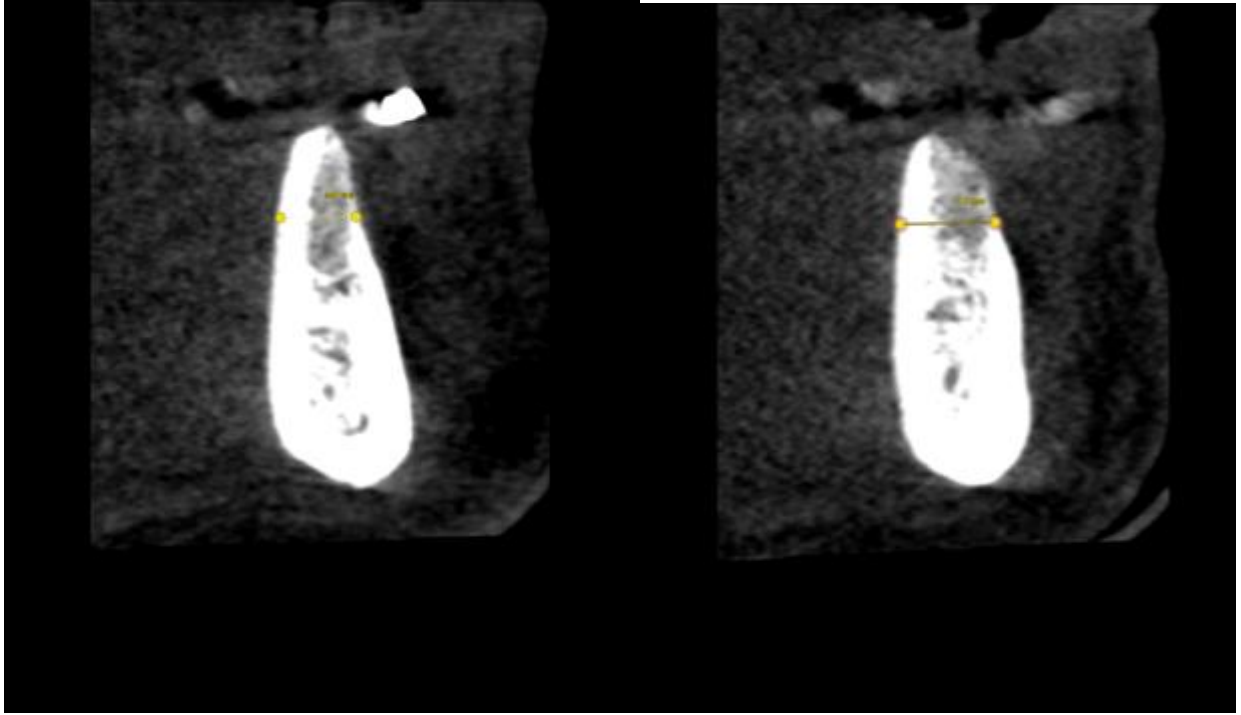


Image 1 shows cross-sectional images from a CBCT rendering immediately following extractions. Extraction outline can be seen clearly. This demonstrates how the measurements were made starting from the point where a thick, dense, radiolucent buccal plate was seen. Both these sites were grafted with DFDBA. Image 2 shows cross-sectional images from a CBCT rendering following 6 months of healing for those same extraction sockets from image 1. It can be seen that with DFDBA, graft integration is excellent.



Image 3

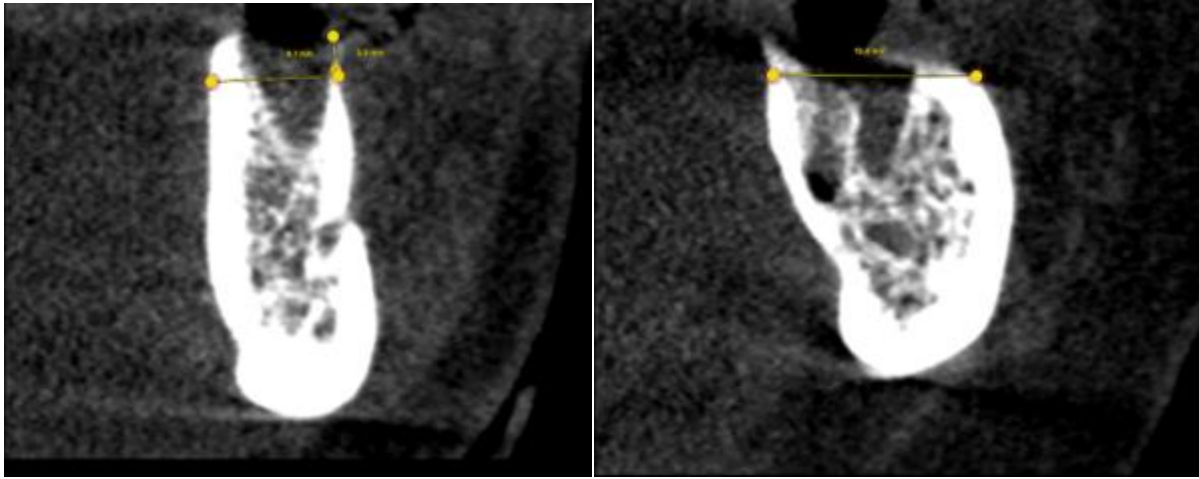


Image 4

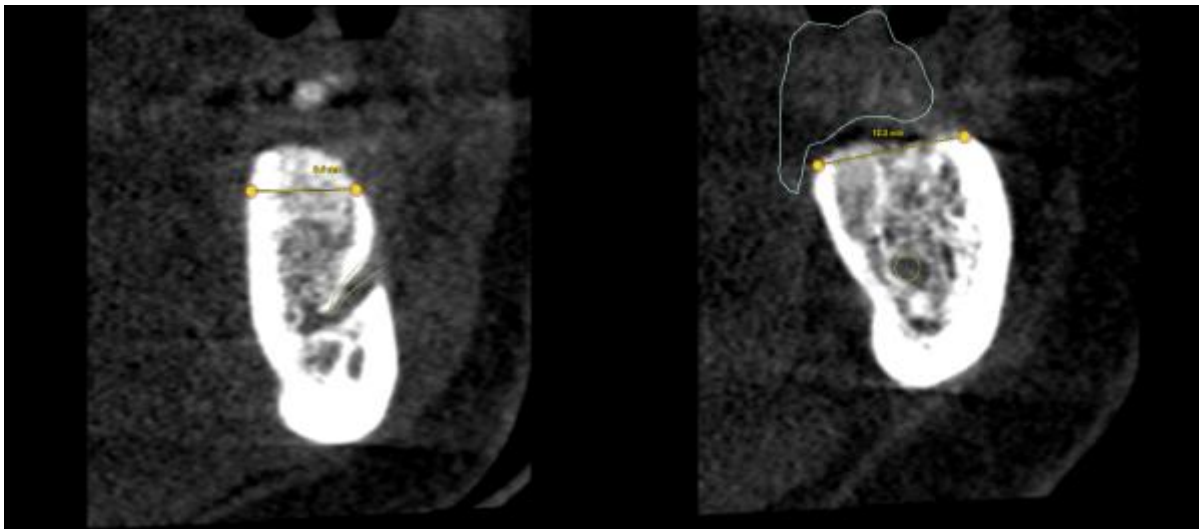


Image 3 shows cross-sectional images from a CBCT rendering immediately following extractions. Again, extraction outline can be seen clearly. Both these sites were grafted with the combination allograft. Image 4 shows cross-sectional images from a CBCT rendering following 6 months of healing for those same extraction sockets from image 3. Similar to DFDBA, it is evident that graft consolidation and integration into the sites are unremarkable with the combination allograft.

Image 5

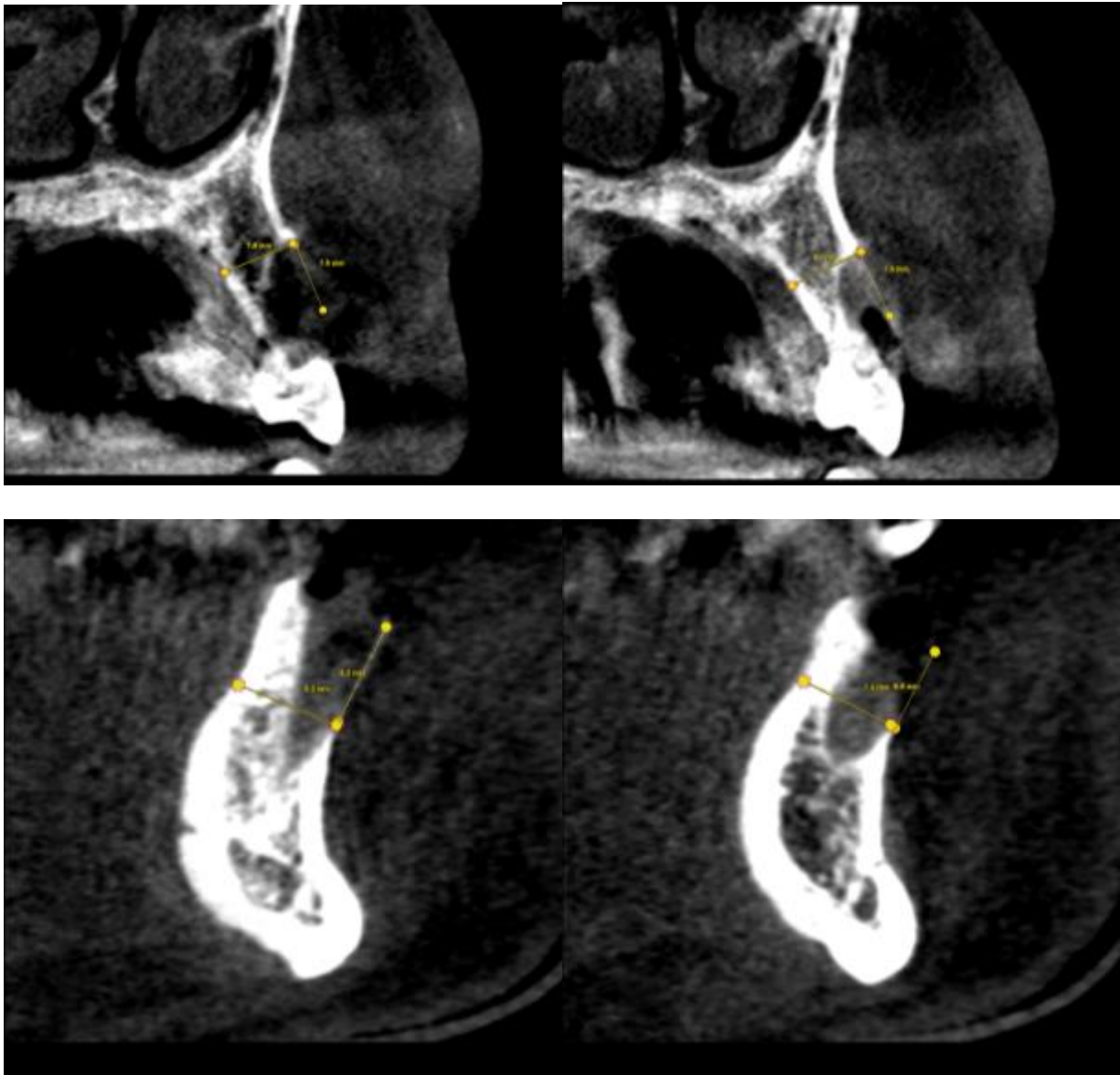
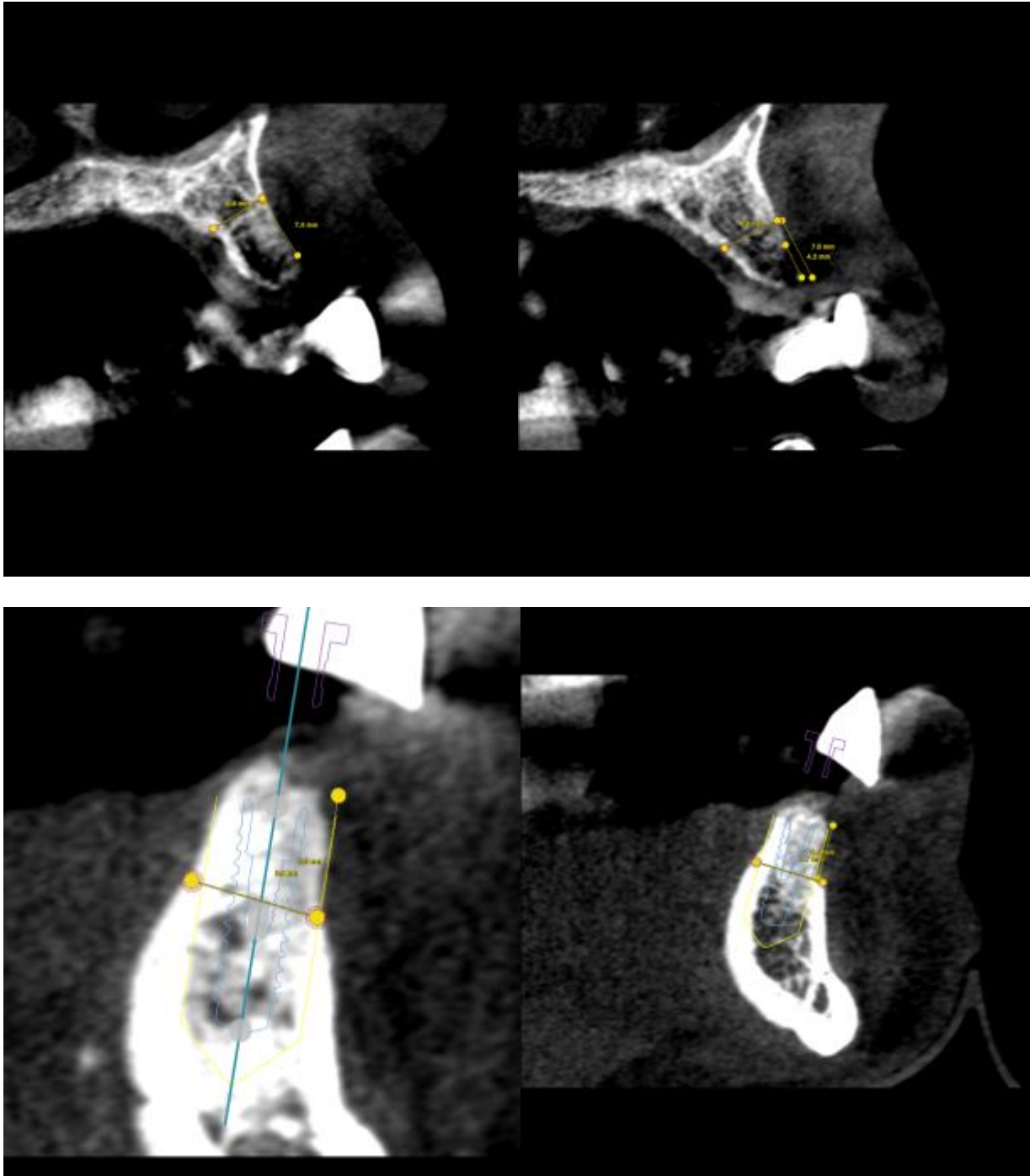


Image 6

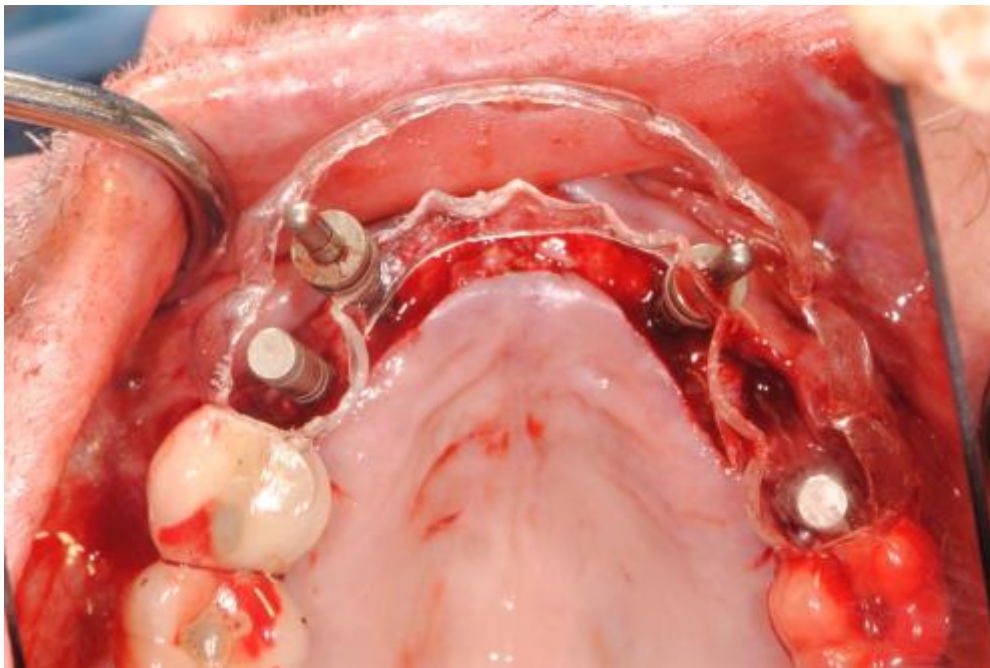


Images 5 and 6 are from the same patient who had two sets of extractions done for this study. On the maxilla, sites #6 and #11 were extracted, and ridge preservation completed with

both DFDBA and combination allograft. Similarly, sites #22 and #27 were also extracted and included as part of the study for ridge preservation with both DFDBA and combination allograft. In all sites, this patient had a significant portion of his buccal plate missing, as can be seen in image 5. These sites were undermined, and fast absorbing collagen dressing was placed on the buccal aspect to contain the graft material. Primary closure was not achieved. Image 6 shows the 6-month post extraction and ridge preservation images. It is evident that graft consolidation is excellent. It is also remarkable the amount of bone that has been regenerated in this patient that presented with a significant portion of the buccal plates missing, using just graft material and a fast absorbing collagen dressing.

Following 6 months of healing, most sites underwent implant placement. Certain sites did not have implant placement due to either prosthetic plan changing, necessitating changes in implant positions, or due to patient's decision stemming from financial difficulties.

Image 7





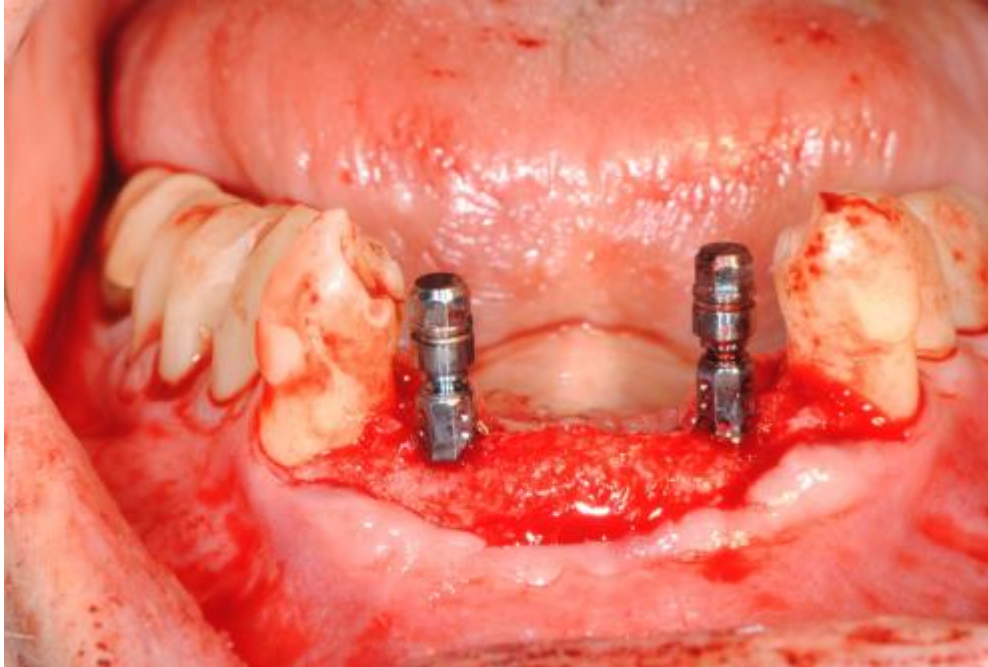
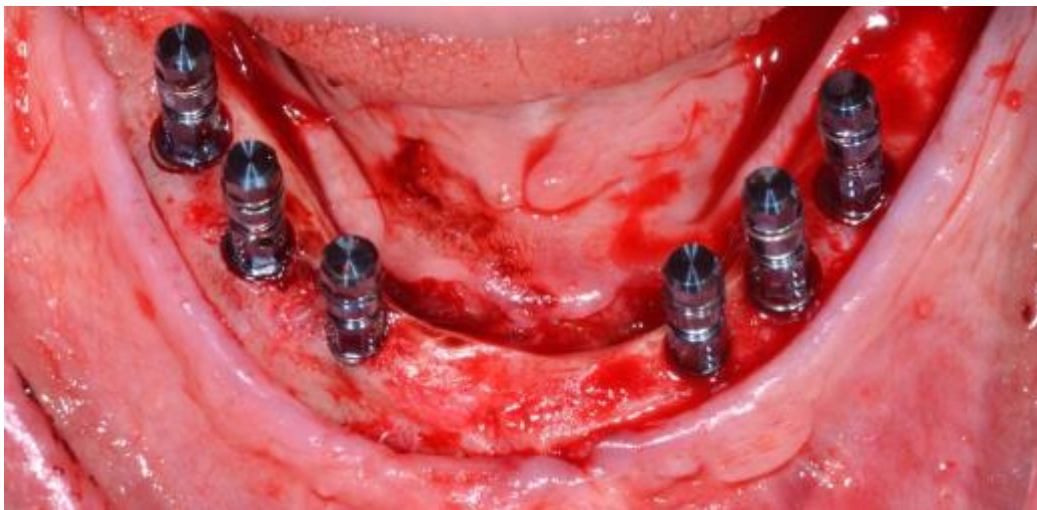

Image 7 shows implant placement in the same patient whose CBCT sectional images are shown in images 5 and 6. It is evident that all sites had ample bone volume for ideal implant placement based on the final prosthesis. There was no need for a second augmentation during implant placement.

Image 8



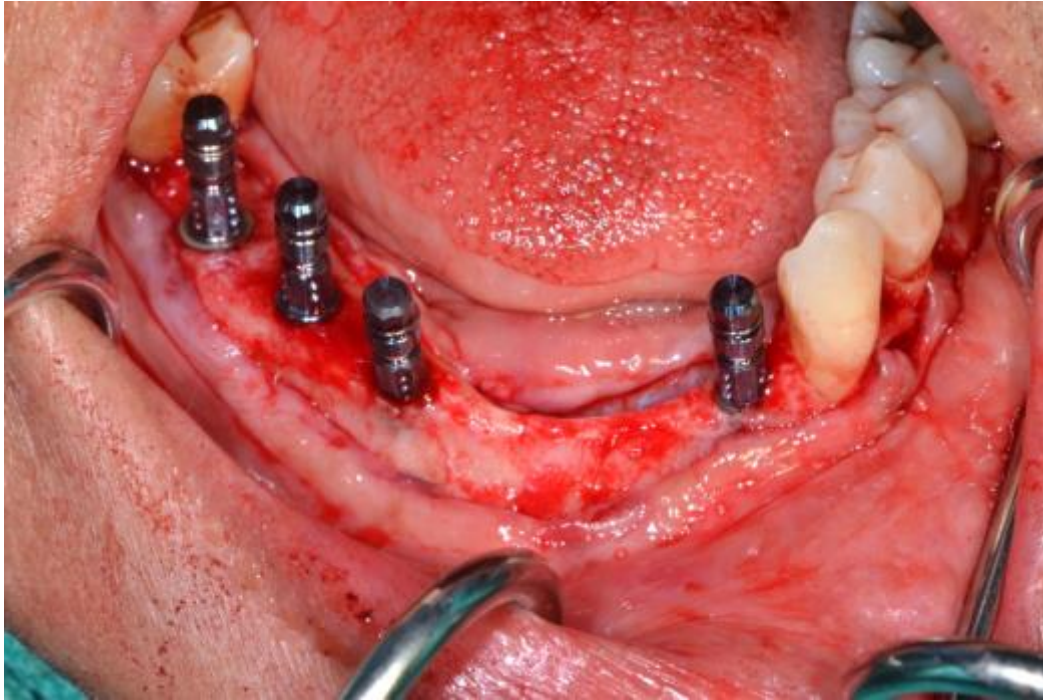


Image 8 shows two patients who were in this study. Both patients were able to undergo implant placement for fixed prosthesis without any additional need of augmentation. As can be seen in these images, the grafted sites for both materials healed very well. The sites for implant placement were vital, mineralized, and dense enough to achieve primary stability. There were no discernible clinical differences between the sites grafted with the combination allograft and with DFDBA. Both control and test sites underwent implant placement successfully without any further grafting.

## **Discussion**

The present study compared alveolar ridge preservation following extraction using two different bone substitute materials. The control was demineralized freeze-dried bone allograft. Particular size for this graft material ranged from 0.25 to 1 mm. The test sites received a fairly new combination allograft. This combination graft is a blend of 70% mineralized freeze-dried

and 30% demineralized freeze-dried cortical bone allograft. The particular size ranged from 0.25 to 1 mm.

During ridge preservation procedures, practitioners, with their ingenuity, often combine FDBA and DFDBA, hoping to obtain the positive aspects of each type of graft. This practice is not based on a specific clinical study, but rather, is based on their own clinical judgement. No other study has compared combination allograft to DFDBA in alveolar ridge preservation studies utilizing site-specific limited volume cone beam volumetric tomography scans. Based on the results, it can be noted that despite our best efforts to preserve the ridge, some dimensional change is bound to occur. This change was found as a loss of 0.67 mm for the test group and 0.74 mm for the control group. The fact that there was a dimensional loss in the alveolar ridge despite ridge preservation techniques coincides with existing literature (1,2,4). The amount of horizontal loss seen in this study seems to be less than what has been presented in other studies involving ridge preservation (4). This could be due to measurement errors in the software rendered images. It could also be due to the small sample size in this study. More accuracy could have been gained by fabricating a radiographic stent to be worn by the patient in both CBCT imaging sessions. This stent could then be scanned separately, and then combined with both scans of the patient at baseline and 6 months following extraction and ridge preservation. Using this method, exactly identical positions could be selected based on the radiographic stent to make measurements. Despite not having such a stent, the measurement positions on the CBCT sectional images were fairly similar in both baseline and 6-month post-op scans. More accuracy could also have been gained by making clinical measurements immediately following extraction, and again at the time of implant placement. The change measured clinically could also have been compared to the changes measured via CBCT. This would have not only provided a second

measure of alveolar ridge dimension change, it would have also served to measure the accuracy of CBCT measurements. Nonetheless, based on the results of this study, changes in alveolar ridge dimension are minimal when alveolar ridge preservation is done. Also, there are negligible differences in changes to alveolar ridge dimensions, when comparing DFDBA to combination allograft. Further, implant placement was possible without any additional augmentation in these sites that underwent alveolar ridge preservation.

A recent study from 2015 compared combination allograft to freeze-dried bone allograft (FDBA), and this group concluded that there are no significant differences between both groups when evaluating changes in ridge dimension (11). However, there was more vital bone in the combination allograft group compared to FDBA. FDBA also had significantly higher percentage of residual graft particles (11). This is clinically significant because it showed that the use of combination allograft led to more vital bone, at the same time, preserving similar alveolar ridge dimensions as FDBA. Another study compared FDBA to DFDBA in alveolar ridge preservation techniques (12). Again, the conclusion was that there were no significant differences in the two materials when evaluating changes in alveolar ridge width and height. However, similar to Borg's study, this group did find significantly higher percentage of vital bone in the DFDBA group compared to the FDBA group (11,12). The FDBA group also had significantly higher residual graft particles. Borg's study is favoring the use of combination allograft over FDBA, since the combination allograft group had more vital bone, and had similar alveolar ridge dimensional changes as FDBA (11). Wood's study is favoring DFDBA over FDBA for those same reasons (12). The present study is the first to evaluate combination allograft to DFDBA. However, this evaluation only included dimensional changes measured via CBCT and graft incorporation via CBCT and clinical examination, and did not include any histological



evaluations. Future studies should include histological evidence to better support the use of one material over the other.

## **Conclusion**

It can be concluded that extraction followed by alveolar ridge preservation using either demineralized freeze-dried bone allograft or a 70:30 combination allograft resulted in minimal and clinically negligible changes in alveolar ridge dimensions. It can also be concluded that there were minimal and clinically negligible differences between the two grafting materials when measuring changes in alveolar ridge dimensions. CBCT scans showed excellent graft integration for both materials, and implants were placed in sites grafted with both materials without any need for additional augmentation. Larger sample size and histomorphometric analysis should be done in future studies to confirm these findings.

## **BIBLIOGRAPHY**

1. Horowitz, R. et al., A Review on Alveolar Ridge Preservation Following Tooth Extraction. *Journal of Evidence-Based Dental Practice Special Issue* 2012(S1):149-160.
2. Barone, A. et al., Tissue changes of extraction sockets in humans: a comparison of spontaneous healing vs. ridge preservation with secondary soft tissue healing. *Clinical Oral Implants Research* 2013;24:1231-1237.
3. Horvath, A. et al., Alveolar ridge preservation. A systematic review. *Clinical Oral Investigations* 2013;17:341-363.
4. Willenbacher, M. et al., The Effects of Alveolar Ridge Preservation: A Meta-Analysis. *Clinical Implant Dentistry and Related Research* 2016;18(6):1248-1268.
5. Barone, A. et al., Flap versus flapless procedure for ridge preservation in alveolar extraction sockets: a histological evaluation in a randomized clinical trial. *Clinical Oral Implants Research* 2015;26:806-813.
6. Cosyn, J. et al., Predictors of Alveolar Process Remodeling Following Ridge Preservation in High-Risk Patients. *Clinical Implant Dentistry and Related Research* 2016;18(2):226-233.
7. Suttapreyasri, S. et al., Influence of Platelet-Rich Fibrin on Alveolar Ridge Preservation. *The Journal of Craniofacial Surgery* 2013;24(4):1088-1094.
8. Leblebicioglu, B. et al., Determinants of alveolar ridge preservation differ by anatomic location. *Journal of Clinical Periodontology* 2013;40:387-395.

9. Lee, A. et al., The Clinical Effectiveness of Alveolar Ridge Preservation in the Maxillary Anterior Esthetic Zone-A Retrospective Study. *Journal of Esthetic and Restorative Dentistry* 2017;29(2):137-145.
10. Mardas, N. et al., Does ridge preservation following tooth extraction improve implant treatment outcomes: a systematic review. Group 4: Therapeutic concepts & methods. *Clinical Oral Implants Research* 2015;26(11):180-201.
11. Borg, TD. et al., Histologic healing following tooth extraction with ridge preservation using mineralized versus combined mineralized-demineralized freeze-dried bone allograft: a randomized controlled clinical trial. *Journal of Periodontology* 2015;86(3):348-355.
12. Wood, RA. et al., Histologic comparison of healing after tooth extraction with ridge preservation using mineralized versus demineralized freeze-dried bone allograft. *Journal of Periodontology* 2012;83(3):329-336.
13. Atwood DA. Reduction of residual ridges: A major oral disease entity. *Journal of Prosthetic Dentistry* 1971;26(3):266-279.
14. Tallgren A. The continuing reduction of the residual alveolar ridges in complete denture wearers: A mixed-longitudinal study covering 25 years. *Journal of Prosthetic Dentistry* 1972;27(2):120-132.
15. Araujo MG. Lindhe J. Dimensional ridge alterations following tooth extraction. An experimental study in the dog. *Journal of Clinical Periodontology* 2005;32(2):212-218.
16. van der Weijden F. Dell'Acqua F. Slot DE. Alveolar bone dimensional changes of post-extraction sockets in humans : A systematic review. *Journal of Clinical Periodontology* 2009;36(12):1048-1058.

17. Pinho MN. Roriz VL. Novaes AB Jr et al. Titanium membranes in prevention of alveolar collapse after tooth extraction. *Implant Dentistry* 2006;15(1):53-61.
18. Schropp L. Wenzel A. Kostopoulos L. Karring T. Bone healing and soft tissue contour changes following single-tooth extraction: A clinical and radiographic 12-month prospective study. *International Journal of Periodontics and Restorative Dentistry* 2003;23(4):313-323.
19. Araujo MG. Linder E. Wennström J. Lindhe J. The influence of Bio-Oss collagen on healing of an extraction socket: An experimental study in the dog. *International Journal of Periodontics and Restorative Dentistry* 2008;28(4):123-135.
20. Milinkovic, I. et al., Are there specific indications for the different alveolar bone augmentation procedures for implant placement? A systematic review. *International Journal of Oral & Maxillofacial Surgery* 2014;43:606-625.