

Case Report

Management of a mandibular first molar with three separate root canals in the distal root

Kesavan Mohan, Sarra Abdulhamid Abdalla Ben Hmida, Saaid Ayesh Alshehadat, Mohamad Syahrizal Halim, Hany Mohamed Aly Ahmed

Department of Conservative Dentistry, School of Dental Sciences, Universiti Sains Malaysia, Kubang Kerian, Kelantan, Malaysia

Address for correspondence: Dr. Hany Mohamed Aly Ahmed, Department of Conservative Dentistry, School of Dental Sciences, Universiti Sains Malaysia, Kubang Kerian - 16150, Kelantan, Malaysia. E-mail: hany_endodontist@hotmail.com

ABSTRACT

Adequate knowledge on the root canal morphology is essential for successful root canal treatment. Mandibular molar teeth show considerable variations in their external and internal radicular morphology that require special attention from dental practitioners to provide the best clinical outcomes for the patients. The occurrence of three separate root canals in the distal root of a mandibular molar is uncommon. This article aims to present the endodontic management of a mandibular first molar that has five separate root canals (two root canals in the mesial roots and three root canals in the distal roots).

Keywords: Distal, endodontic treatment, mandibular molar, root canal, root canal morphology, root canal treatment, three

INTRODUCTION

Sufficient knowledge on the root and root canal morphology, good anticipation, and absolute clinical thoroughness are fundamental prerequisites for a successful root canal treatment.^[1,2] This includes preoperative awareness of, and intraoperative care to identify, the landmarks of normal morphology as well as any unusual anatomy of the root canal system.^[3] A meticulous understanding of the anatomical variations will help to reduce the number of missed root canals during treatment, thus increasing the rate of clinical success.^[3]

Studies have demonstrated wide anatomical variations in the mesial and distal roots of mandibular molar teeth

that are mainly influenced by ethnicity and age.^[1,4,5] Canal systems commonly seen within these roots are two or three canals in the mesial root and one or two canals in the distal root.^[6,7] Nevertheless, the occurrence of three root canals in the distal root has been reported, and this can reach up to 3% depending on the population studied.^[5] Rarely will all canals have a separate foramen when exiting the tooth structure.^[5,7]

Here, we present endodontic management of a mandibular left first molar with five separate canals, two canals in the mesial root and three canals in the distal root (type VIII root canal pattern - Vertucci's classification).^[1]

CASE REPORT

A 19-year-old male patient was referred to the polyclinics of the School of Dental Sciences, Universiti Sains Malaysia, with the chief complaint of a dull pain on the mandibular left side while chewing. The medical history was noncontributory. The clinical examination revealed a restored mandibular left first molar with slight pain on percussion. There was no evidence of current swelling or tooth mobility. Radiographically, the tooth showed a periapical radiolucency around the mesial root

Access this article online

Quick Response Code:



Website:
www.jresdent.org

DOI:
10.4103/2321-4619.176021

[Figure 1a]. The tooth was provisionally diagnosed as necrotic with chronic apical periodontitis. After removal of the restoration, the pulp was confirmed to be necrotic and the endodontic treatment was commenced.

After rubber dam isolation, the access cavity preparation was completed. Four root canals {two in the mesial root [mesiobuccal (MB), mesiolingual (ML)], and two in the distal root [distobuccal (DB), distolingual (DL)]} were identified. The working length was determined radiographically [Figure 1b], and with the aid of an electronic apex locator (Root ZX, J Morita, USA). After that, the canals were initially instrumented using SX hand NiTi ProTaper file (*Dentsply-Maillefer, Ballaigues, Switzerland*). For irrigation and lubrication, 2.5% NaOCl and ethylenediaminetetraacetic acid (EDTA)-based root canal conditioner (Glyde File Prep, *Dentsply-Maillefer, Ballaigues, Switzerland*) were used. Subsequently, the canals were filled with a nonsetting calcium hydroxide paste (Henry Schein, New York, USA), and the tooth was restored with a double seal composed of Cavition (GC Corporation, Tokyo, Japan) capped with glass ionomer cement (Fuji IV, Tokyo, Japan).

In the following visit and upon further exploration between the distal canals using K-file size 10, a “separate” third middle distal (MD) canal was identified [Figure 1c and d]. The mechanical instrumentation was continued for MB, ML, DB, and DL canals using hand ProTaper files up to size F3 and the MD canal was instrumented using K-files up to size 30. The canals were then obturated using lateral compaction technique [Figure 1e]. After that, the occlusal and proximal cavities were restored using a posterior resin composite restoration [Figure 1f].

DISCUSSION

The root canal anatomy shows considerable variations and complexities that require special attention while performing root canal therapy.^[1,8] A comprehensive understanding of common root canal configurations and its variations is essential to achieve long-term success of the root canal treatment.^[8,9] Researchers^[10] reported 42% incidence of missed root/root canals in teeth scheduled for retreatment. Therefore, complete debridement followed by three-dimensional obturation of the root canal system is an utmost important procedure in endodontic practice.

The presentation of this case is to contribute to our knowledge of the anatomical variability in mandibular molars. This case demonstrates a rare anatomical configuration, and supports previous reports of the existence of root canal aberrations in the distal root of mandibular molars. The distal root has three distinct root canals with three portals of exit, which could be described

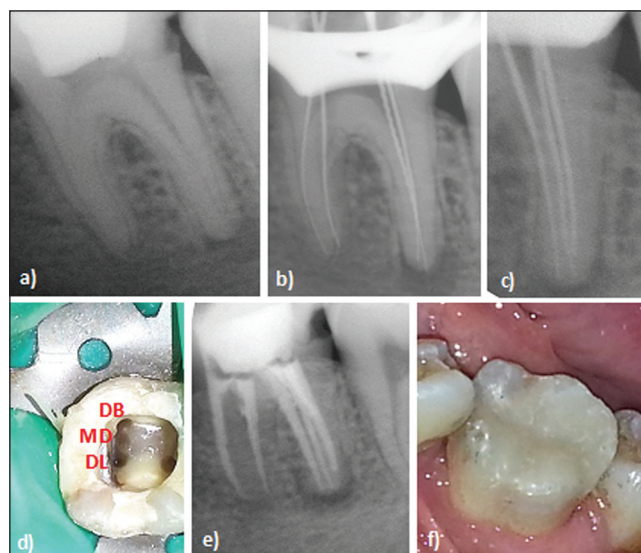


Figure 1: (a) Preoperative radiograph, (b) Working length determination using periapical radiography, (c and d) Four canals were identified (Mb, ML, DB, and DL) during initial exploration and upon further exploration, a separate third MD canal was identified, (e) Obturation using lateral compaction technique, and (f) Coronal restoration was done using a posterior resin composite

as Type VIII canal configuration according to Vertucci's classification.^[11] Previous reports demonstrated other root canal configurations such as Type XVIII according to Sert and Bayirli supplemental configurations.^[5,11,12] The occasion of four canals in the distal root has also been reported.^[9,13]

Based on the discussion above, it appears that ignoring the absolute confidence for the preestimated number of roots/root canals is essential for practicing endodontics.^[14] Diagnostic measures are important aids in locating root canals including the use of some sort of magnification (operating microscope or loupes), pretreatment radiographs with different horizontal angulations, examination of the pulp chamber floor with a sharp explorer, troughing the grooves with ultrasonic tips, staining of chamber floor, visualizing canal bleeding points, and tactile examination of the root canal walls.^[3,9,14-16] In some clinical situations, the use of cone beam computed tomography (CBCT) is helpful as an adjunctive diagnostic aid to conventional radiography.^[12]

CONCLUSION

The root canal anatomy in the distal root of mandibular molar may show considerable variations. Therefore, it is indispensable that dentists undertaking root canal treatment in mandibular molars thoroughly assess the root canal system in both the mesial and distal roots in order to provide the best possible outcome of treatment for the patient.

REFERENCES

1. Vertucci FJ. Root canal morphology and its relationship to endodontic procedures. *Endod Top* 2005;10:3-29.
2. Ahmed HM. Anatomical challenges, electronic working length determination and current developments in root canal preparation of primary molar teeth. *Int Endod J* 2013;46:1011-22.
3. Ahmed HM, Abbott PV. Accessory roots in maxillary molar teeth: Review and endodontic considerations. *Aust Dent J* 2012;57:123-31; quiz 248.
4. Ahmed HM, Luddin N. Accessory mesial roots and root canals in mandibular molar teeth: Case reports, SEM analysis and literature review. *Endod Pract Today* 2012;6:195-205.
5. Kottoor J, Sudha R, Velmurugan N. Middle distal canal of the mandibular first molar: A case report and literature review. *Int Endod J* 2010;43:714-22.
6. Azim AA, Deutsch AS, Solomon CS. Prevalence of middle mesial canals in mandibular molars after guided troughing under high magnification: An *in vivo* investigation. *J Endod* 2015;41:164-8.
7. Ryan JL, Bowles WR, Baisden MK, McClanahan SB. Mandibular first molar with six separate canals. *J Endod* 2011;37:878-80.
8. Ahmed HM. A paradigm evolution shift in the endodontic map. *Eur J Gen Dent* 2015;4:98.
9. Baziar H, Daneshvar F, Mohammadi A, Jafarzadeh H. Endodontic management of a mandibular first molar with four canals in a distal root by using cone-beam computed tomography: A case report. *J Oral Maxillofac Res* 2014;5:e5.
10. Hoen MM, Pink FE. Contemporary endodontic retreatments: An analysis based on clinical treatment findings. *J Endod* 2002;28:834-6.
11. Jain S. Mandibular first molar with three distal canals. *J Conserv Dent* 2011;14:438-9.
12. Kaushik A, Talwar S, Yadav S, Chaudhary S, Nawal RR. The role of cone beam computed tomography in the endodontic management of a mandibular first molar with three distal canals. *Dent Res J (Isfahan)* 2014;11:700-4.
13. Arora A, Acharya SR, Sharma P. Endodontic treatment of a mandibular first molar with 8 canals: A case report. *Restor Dent Endod* 2015;40:75-8.
14. Ahmed HM. The foremost challenge in endodontics and pediatric dentistry. *Aperito J Oral Health Dent* 2015;1:103.
15. Ahmed HM. Management of third molar teeth from an endodontic perspective. *Eur J Gen Dent* 2012;1:148-60.
16. Ahmed HM, Cheung GS. Accessory roots and root canals in maxillary premolar teeth: A review of a critical endodontic challenge. *ENDO — Endod Pract Today* 2012;6:7-18.

How to cite this article: Mohan K, Ben Hmida SA, Alshehadat SA, Halim MS, Ahmed HM. Management of a mandibular first molar with three separate root canals in the distal root. *J Res Dent* 2016;4:22-4.

Source of Support: Nil, **Conflicts of Interest:** The authors deny any conflict of interest.

