



Sveriges lantbruksuniversitet  
Swedish University of Agricultural Sciences

**Faculty of Veterinary Medicine  
and Animal Science**  
Department of Clinical Sciences

# **The Use of Thermography in Evaluation of Surgical Wounds in Small Animal Practice**

*Erica Gumpert Herlofson*

*Uppsala  
2017*

*Degree Project 30 credits within the Veterinary Medicine Programme*

*ISSN 1652-8697  
Examensarbete 2017:16*



# The Use of Thermography in Evaluation of Surgical Wounds in Small Animal Practice

*Termografi vid utvärdering av kirurgiska sår på hund och katt*

**Supervisor:** Annika Bergström, Department of Clinical Sciences, SLU

**Examiner:** Odd Höglund, Department of Clinical Sciences, SLU

*Degree Project in Veterinary Medicine*

**Credits:** 30

**Level:** Second cycle, A2E

**Course code:** EX0736

**Place of publication:** Uppsala

**Year of publication:** 2017

**Number of part of series:** Examensarbete 2017:16

**ISSN:** 1652-8697

**Online publication:** <http://stud.epsilon.slu.se>

**Key words:** thermography, thermal imaging, wound healing, small animal, dog and cat

**Nyckelord:** termografi, värmekamera, sårläggning, smådjur, hund och katt

Sveriges lantbruksuniversitet  
Swedish University of Agricultural Sciences

Faculty of Veterinary Medicine and Animal Science  
Department of Clinical Sciences



## **SUMMARY**

The aim of this study was to test the usefulness of thermal imaging in a clinical setting as a part of wound healing evaluation after surgical procedures. Forty-one client owned dogs and cats (thirty nine dogs and two cats) were included in the study which was a part of another study investigating the effects of local anaesthetics on wound healing. Thermal imaging and clinical assessment of the wound area was performed approximately fourteen days after surgical intervention. Clinical assessment was focused on evaluating wounds for signs of inflammation and thermal interpretation investigated if there was a significant difference in temperature between wound area and control area. The skin temperature in the wound area had a significantly lower temperature than control areas. Comparison of results from thermal image interpretation for correlation with clinical assessment of wound area had no statistical significance. The controversial finding of a malignant tumour being depicted as colder than surrounding tissue instead of warmer, which is described in the literature, illustrates the need for further research to improve thermal imaging diagnostic outcome in the oncology field. A potentially useful area for thermal imaging in every day clinical practice may lie in monitoring the healing of bone fractures but further studies are needed. The conclusion from this study was that subjective clinical evaluations of surgical wounds two weeks post surgery provides enough information for clinical decision making and thermal imaging is superfluous in this context. The method should be evaluated within the timeframe of the inflammatory phase to further explore its potentials in wound healing evaluation.

## **SAMMANFATTNING**

Målet med denna studie var att utvärdera den kliniska användbarheten av termografi som metod för att utvärdera sårhäkning av kirurgiska sår i senare delen av sårhelingsfasen. Fyrtioen privatägda hundar och katter (39 hundar och 2 katter) inkluderades i studien som var en del av en annan studie där effekten av lokalbedövningsmedel på sårhelningen studerades. Cirka fjorton dagar efter kirurgiskt ingrepp avbildades sårområdet med värmekamera och en klinisk bedömning utfördes i samband med detta. Den kliniska bedömningen utvärderade närvaro- eller frånvaro av inflammationstecken och sårområdet jämfördes mot kontrollområden för eventuell temperaturskillnad i de termografiska bilderna. En skillnad i hudtemperatur mellan sår och kontrollområden sågs, där såret hade en signifikant lägre temperatur än kontrollområden. Jämförelse mellan resultat från värmekamerabilderna och klinisk bedömning av sårområdet visade inte på någon statistiskt signifikant korrelation. Det kontroversiella fyndet av en tumör som istället för att avbildas som varmare än omgivande vävnad, i enlighet med vad tidigare studier har visat, var kallare än omgivande vävnad visar på behovet av vidare forskning för att förbättra de diagnostiska möjligheterna inom onkologi. Ett potentiellt användningsområde för värmekameran i den kliniska vardagen skulle kunna vara att övervaka frakturläkning men vidare forskning krävs. Sammanfattningsvis bedömdes användningen av värmekamera för att utvärdera kirurgiska sår som överflödigt vid den tidpunkt som studerades då en subjektiv klinisk utvärdering bedömdes tillräckligt för att fatta kliniska beslut. Metoden bör utvärderas inom tidsramen för den inflammatoriska fasen för att vidare utforska termografins användbarhet vid bedömning av sårhäkning.

**CONTENT**

INTRODUCTION..... 1

Litterature review ..... 1

    Infrared radiation..... 1

        Electromagnetic spectra..... 1

        Light and heat..... 2

        Emissivity..... 2

    Thermography ..... 2

        Basic theory..... 2

        Technology ..... 3

        Thermographic imaging ..... 4

    Clinical use..... 4

        Human ..... 4

        Veterinarian..... 5

    Inflammation and wound healing..... 6

        Normal wound healing..... 6

        Wound healing complications..... 7

Materials and Methods ..... 10

Results ..... 12

Discussion ..... 20

Conclusion..... 24

Acknowledgements ..... 24

References ..... 24

Appendix a ..... 32

Appendix b ..... 33

## **INTRODUCTION**

Inflammation is the body's natural response to injury and has a crucial role in the healing process (Eming *et al.*, 2007). When performing surgical procedures a wound is intentionally created when incising the skin and therefore the inflammatory process is triggered. The normal healing process of a wound goes through three phases; inflammatory-, proliferative- and maturity phase where the first two should roughly be finished approximately 14 days post surgery and the last can proceed up to 18 months post surgery (Tobias & Johnston, 2012).

Suture removal is commonly scheduled approximately 14 days post surgery (Kladakis, 2014) when the inflammatory response should already essentially have played its part and epithelium covers the wound. A persistent high degree of inflammatory activity at this time suggests a prolonged wound healing (Eming *et al.*, 2007).

Signs of inflammation are heat, pain, redness, swelling and loss of function (Harari, 1993). One of the challenges when evaluating inflammation is that there are few methods for objective measurement. Pain can be difficult to assess and the perception of pain varies a lot between individuals, which further complicates evaluation. For this reason protocols have been developed to help create a basis for standardization in pain evaluation (Hellyer *et al.*, 2007). Redness and swelling would appear to be good candidates for objective measurement but can sometimes present challenges by having diffuse outlining. Loss of function in terms of healing of skin would be wound dehiscence, which can be measured using a simple measuring tape. Heat might seem like the most difficult to evaluate but it has shown a great potential when depicted with thermal imaging (Vainionpää & others, 2014).

Thermal imaging, also called thermography, depicts the infrared light emitted by all things with a temperature above absolute zero (0 K, -273,15 C) and presents the different temperatures in an image with a colour scale representing different temperatures (Carosena, 2012). With adapted software *regions of interest* (ROI) can be analysed giving the interpreter information about maximum, minimum and average temperature within a defined area (Meditherm Inc.).

This study aimed to evaluate the usefulness of thermography in a clinical setting as an objective measurement for inflammation and delayed healing. The study was a part of another study looking at the use of local anaesthetics in relation to complications in wound healing.

## **LITTERATURE REVIEW**

### **Infrared radiation**

#### ***Electromagnetic spectra***

Heat, light and radiation are usually described using wavelength and frequency in a scale called the electromagnetic spectra. Low frequencies have a greater wavelength and high frequencies a shorter wavelength. In the low frequencies radiowaves are found and in the high frequencies gamma radiation is found. Somewhere in the middle of the scale is the narrow window of light that is visible to the naked human eye, 400-800 THz (Bergström *et al.*, 2005),



and below this the infrared light-spectra, 300 GHz -400 THz and 0,75-1000  $\mu\text{m}$  (Mehta, 2011).

### **Light and heat**

Light has both the properties of a wave but also the properties of a stream of particles, which are called photons. Photons are charged with energy and are not dependent of matter to travel through space, and can therefore travel through vacuum as well as air (Eddy *et al.*, 2001). The stream of energy-charged photons called infrared light or infrared radiation has a lower frequency and bigger wavelength than the human eye can see and is therefore only perceived as heat by humans (Vainionpää & others, 2014). Heat can be transmitted through conduction, convection and radiation (Eddy *et al.*, 2001).

### **Emissivity**

An object can both absorb and emit energy via light in different spectrums. The balance between emissivity and absorption is adapted depending on the level of energy in the object's surroundings and aims to create radiation balance (Bergström *et al.*, 2005). An illustrative example of this establishment of radiation balance would be to look at what happens when an object is placed in direct sunlight on a warm day and thereafter taken inside and placed in a windowless room at ambient room temperature. The object absorbs energy outside while it is exposed to the higher energy that comes from the sun and inside it will emit energy until it has cooled to room temperature (Bergström *et al.*, 2005). All objects with a temperature above absolute zero (0 K, -273,15 C) emits infrared radiation (Carosena, 2012). Different objects have different emissivity potentials and can therefore interact to a variable degree with its surroundings when creating balance. A black body is a theoretical concept of an object that is considered to have 100% absorption/emissivity potential and the opposite would be a body that has no absorption/emissivity potential. The scale of emissivity ranges from 0-1 where 1 equals a black body and the unit is  $\text{W}/\text{m}^2$  (Bergström *et al.*, 2005). The emissivity of human skin is considered to be between 0,97-0,99 (Steketee, 1973). The emissivity of animals has not been scientifically established and has in certain studies been assumed to be somewhat lower (0,95) than that of humans due to insulating properties of fur but in others it has been set to 1 (Vainionpää & others, 2014).

## **Thermography**

### **Basic theory**

Infrared radiation can, when it is significant, be identified through palpation but cannot be seen with the naked human eye. When the heat is subtle it becomes substantially more difficult to identify merely by palpation and more sensitive and refined tools are required (Turner, 2001). Thermography uses emitted heat from a given source to make a visual image where different temperatures are depicted in colours visible to the human eye. The visual heat pattern can then help the practitioner identify asymmetries in heat emission that can serve as an indication of an ongoing and potentially pathological process in the area (Levet *et al.*, 2009). The theoretical background to thermography stems from two essential laws of physics: Planck's radiation law and Stefan-Boltzmann's law explaining emittance (Vainionpää & others, 2014).

Planck's radiation law:

$$S\lambda = \frac{8\pi hc}{\lambda^5} \frac{1}{e^{hc/\lambda kT} - 1}$$

$S\lambda$  = energy per unit, volume per wavelength

$\pi$  = 3,14159265

$c$  = speed of light  $(299792458 \frac{m}{s})$

$h$  = Planck constant  $(6,626 \times 10^{-34} Js)$

$T$  = temperature in Kelvin

$\lambda$  = wavelength

$k$  = Boltzmann constant  $(1,38 \times \frac{10^{-23} J}{K})$

Stefan-Boltzmann's law:

$$P = \sigma \epsilon A (T^4 - T_{env}^4)$$

$P$  = Energy emitted (radiated)

$\sigma$  = Stefan – Boltzmann's constant  $(5,6703 \times 10^{-8} \frac{Watt}{m^2 K^4})$

$\epsilon$  = emissivity (ranges from 0 – 1 depending on object)

$A$  = area

$T$  = temperature of the radiator

$T_{env}$  = temperature of surroundings

### **Technology**

There are many different thermography cameras available on the market and although the basic technology is much the same there are some variations to be aware of when choosing the model best suited for intended use. Thermography cameras are available with cooled or uncooled systems and in different resolutions. The cooled cameras are useful when establishing absolute temperatures but needs time to cool between imaging and are therefore more time consuming to use than the uncooled cameras. The uncooled models calibrate in relation to ambient temperature constantly and has been developed to the point where the result is close to the fixed calibration of the cooled cameras therefore making it useful in most situations not requiring an absolute temperature (Pedreros et al. 2012; Vainionpää & others, 2014). Cameras with different resolution were compared in a recent study (Vainionpää *et al.*, 2012) and the result was that to have the best repeatability, both concerning quality of images and the interpretation of these, a minimum of 180 x 180 pixel resolution was recommended by the authors.

## **Thermographic imaging**

### **Examination area**

To ensure good quality images and reliable results the examination area, preparation of patient and the angle between camera and object must be controlled and standardized. The room where the thermography exam takes place should be draught free, have an ambient temperature and be windowless to avoid sunlight artefacts (Ringer *et al.*, 2005). The animal should be given at least 10 min to acclimatize to the room temperature in the room where the thermography exam will take place. Depending on temperature difference between the examination area and the external environment different amounts of time is required for the animal to acclimatize, the greater the difference the more time is needed (Tunley & Henson, 2004). All clothes, bandages, dirt and moist should be removed from the anatomic region which is to be examined (Celeste *et al.*, 2013). To minimize optical effects a 90 degree angle between object and thermographer is recommended but up to 20 degrees deviations from this can be tolerated and still give reliable results (Westermann *et al.*, 2013).

### **Strengths and limitations**

The strengths in the thermal imaging technique are that it is a very sensitive instrument, the imaging process presents no risk to patient or examiner through dangerous radiation and it is a no contact examination technique (Eddy *et al.*, 2001) also there is no need to sedate the animal which is required for i.e. CT scan imaging (Grossbard *et al.*, 2014). The greatest limitation is that although it is very sensitive, thermography is not very specific (Grossbard *et al.*, 2014) and therefore is best used together with other diagnostic tools. Also, in the thermal image infrared radiation originates not only from the object itself but from the atmosphere in its surrounding and through reflection from the surrounding via the object of interest (Carosena, 2012). Because of the external factors that can affect the thermal image one has to be cautious to provide a controlled examination area (Turner, 2001).

## **Clinical use**

### **Human**

Thermography used for objective measurement within the medical field was first studied in 1956 by Lawson R.. He concluded and predicted a potential use for thermography in early detection of malignant breast cancer. Lawson hypothesized that increased cellular activity, metabolism and angiogenesis particularly associated with malignant neoplasms should leave a recognizably changed thermal pattern locally that could be identified using thermal imaging (Lawson, 1956). More recent studies have confirmed Lawson's theory and it has been found that angiogenesis, local elevation in nitric oxide, local inflammation and elevated estrogen levels, all physiological features associated with tumour growth, causes increased thermal radiation from the tumour site that can be detected using thermography (Kennedy *et al.*, 2009). Since Lawson's first attempt at using thermal imaging as a diagnostic tool studies have been made within various medical fields e.g. orthopaedics (Varju, 2004), ophthalmology (Tan *et al.*, 2009), odontology (Ventä *et al.*, 2001) and more. The method has been validated and implemented in different clinical situations within these fields. Today thermography is most extensively researched as a substitute or supplement to mammography in early breast cancer detection, as predicted by Lawson. In a study conducted by Keyserlingk *et al.*, 2000 the

sensitivity for thermography used for breast cancer detection using only thermography was established at 83% while in conjunction with mammography it was 95%. The sensitivity of mammography alone and mammography together with clinical breast exam (CBE) was investigated by Oestreicher *et al.*, 2004 and determined at 78% for mammography and 82% for mammography combined with CBE.

### **Veterinarian**

In veterinary medicine the potentials of thermography has been explored in many of the same medical fields as in human medicine and tested on numerous species; horses (Soroko *et al.*, 2013; Redaelli *et al.*, 2014) cattle (Stewart *et al.*, 2007; Rainwater-Lovett *et al.*, 2009), wild animals (Cilulko *et al.*, 2013) and dogs and cats (Vainionpää & others, 2014). The technology early attracted interest within horse medicine (Smith, 1964) and is so far most extensively researched and clinically implemented within this species. Since horses are expected to perform athletically in different disciplines the health and normal function of the locomotor apparatus is essential, thus making it a popular focus in research. The potentials of thermography in early detection and diagnosis of orthopaedic injuries and lameness in horses has therefore been one of the major focuses in studies on thermal imaging in horse medicine (Turner, 2001). Although the potentials of thermography in orthopaedic evaluations has attracted most attention studies have been performed in a wide range of other fields of equine medicine testing its use in detection of illegal performance enhancing techniques (Van Hoogmoed & Snyder, 2002), early detection of distal limb cast sores (Levet *et al.*, 2009), back pain diagnosis (Fonseca *et al.*, 2006), saddle assessment (Arruda *et al.*, 2011) and stress (Dai *et al.*, 2015) amongst others. Its potential use in small animal practice has until more recent years been less examined. The last decade a modest but growing number of studies in small animal medicine have been published with encouraging results. Attempts have been made to validate thermography data from specific regions of interest (ROI) such as the thoracolumbar area (Grossbard *et al.*, 2014), ocular surface (Biondi *et al.*, 2015) and mammary glands (Pavelski *et al.*, 2015) with the intention of facilitating identification and diagnosis of pathological processes such as disc hernia, keratoconjunctivitis sicca and mammary tumours. Grossbard *et al.*, 2014 studied the potentials of thermography used as a screening tool to identify thoracolumbar disc hernia, Vainionpää *et al.*, 2012 investigated its use in early identification of muscle injury and proceeded to look at the possible use of thermography to identify painful conditions in cats in a following study (Vainionpää *et al.*, 2013). Its usefulness as a diagnostic tool (Infernuso *et al.*, 2010; Pavelski *et al.*, 2015), its potential use in treatment evaluation (Grossbard *et al.*, 2014) and as a tool when studying stress responses (Travain *et al.*, 2015) have also been studied in dogs and cats.

Studies have been performed in both human (Ventä *et al.*, 2001; Christensen *et al.*, 2012) and veterinary (Mamedov *et al.*, 1999; Celeste *et al.*, 2013; Całkosiński *et al.*, 2015) medicine using thermal imaging to successfully evaluate postoperative inflammation in wound area. Since inflammation and the resolve of inflammation are both part of normal wound healing thermography is potentially a very useful tool to identify deviations from normal progression through healing phases suggestive of wound healing complications (Eming *et al.*, 2007; Franz *et al.*, 2008; Guo & DiPietro, 2010).

## Inflammation and wound healing

### *Normal wound healing*

The wound healing process is traditionally divided into three phases based on cellular- and cell mediator activity in the affected area; the inflammatory phase, proliferative phase and maturity phase. The subdivision into separate phases is mainly done to facilitate understanding of the more complex reality where these responses to injury overlap and coexist within the same timeframe (Guo & DiPietro, 2010; Tobias & Johnston, 2012). A schematic overview of the activity during each phase is presented in Figure 1.

| Inflammation phase  | Proliferation phase  | Maturity phase   |
|---|--|--|
| <ul style="list-style-type: none"> <li>• Haemostasis through:               <ul style="list-style-type: none"> <li>-coagulation-cascade</li> <li>-vasoconstriction</li> <li>-vasodilatation</li> </ul> </li> <li>• Debridement of:               <ul style="list-style-type: none"> <li>-contamination</li> <li>-damaged/dead tissue</li> </ul> </li> </ul> | <ul style="list-style-type: none"> <li>• Blood supply through:               <ul style="list-style-type: none"> <li>-vascularisation</li> <li>-angiogenesis</li> </ul> </li> <li>• Repair of extracellular matrix</li> <li>• Repair of epithelium</li> <li>• Formation of granulation tissue components:               <ul style="list-style-type: none"> <li>-capillaries</li> <li>-fibroblasts</li> <li>-macrophages</li> <li>-collagen</li> <li>-fibronectin</li> <li>-hyaluronic acid</li> </ul> </li> </ul> | <ul style="list-style-type: none"> <li>• Restoration of tissue strength by:               <ul style="list-style-type: none"> <li>-collagen remodelling</li> <li>-replacement of collagen typ III to collagen type I</li> </ul> </li> </ul> |

Figure 1. *Wound healing phases.*

### *Inflammatory phase*

The moment injury is inflicted on tissue marks the start of the inflammatory phase which then continues for approximately 96 h (Teller & White, 2009). The cellular activity is dominated by sentinel cells; such as monocytes, macrophages, mast cells, dendritic cells and neutrophils (Tobias & Johnston, 2012). Neutrophils dominate early leukocyte population and arrives in situ within 24-48h (Dovi *et al.*, 2004; Eming *et al.*, 2007). During this phase haemostasis is acquired through the coagulation cascade and initially vasoconstriction. Later the vasoconstriction instead turns into vasodilatation as the cell population and the signalling substances that dominates the wound bed changes. Apart from haemostasis this phase is also characterised by neutrophil and macrophage debridement of wound contaminants and damaged and dead tissue (Hosgood, 2006).

### *Proliferative phase*

Whilst the inflammatory phase mainly deals with short-term actions to stabilize the wound area the proliferative phase marks the beginning of tissue reconstruction. The proliferative phase starts when the inflammatory phase ends, about 3-4 days post-wounding and continues for about 5-8 days (Hosgood, 2006; Teller & White, 2009). By the end of the inflammatory phase and the beginning of the proliferative phase the leukocyte cell population has become

dominated by macrophages (Tobias & Johnston, 2012). The shift from the acute handling of tissue trauma to focus on re-growing and reconstructing tissue is reflected in a growing number of epithelial cells, endothelial cells and fibroblast recruited to the wound bed to help form granulation tissue that covers and protects the wound (Hosgood, 2006). In response to Platelet-derived growth factor (PDGF) cytokine there is initially a fibroblast production of collagen type III together with fibronectin and glucosaminoglycan. Later the collagen production shifts from collagen type III to collagen type I under the influence of Transforming growth factor- $\beta$  (TGF- $\beta$ ), which reaches its highest levels approximately 7-14 days after injury (Goldman, 2004; Hosgood, 2006). TGF- $\beta$  also plays an important role in inducing wound contraction by locally transforming fibroblast into myofibroblasts (Hinz, 2007).

### *Maturity phase*

Once the wound is covered with epithelium the final phase of healing begins where the objective is to re-establish tissue strength. This phase usually begins around day 12 post wounding and continues for up to 18 months (Tobias & Johnston, 2012). The replacement of the relatively weak extracellular matrix (ECM) with a high ratio of collagen type III to a mature and mechanically, as well as functionally, resistant ECM with a high ratio of collagen type I is the main change during this phase (Tobias & Johnston, 2012). Depending on the amount of mechanical load on the wound area the stimulation of temporary ECM formation and thereafter its maturity and collagen replacement stretches over different amounts of time before final wound healing is established (Broughton *et al.*, 2006).

### **Wound healing complications**

The healing wound can encounter different challenges in different phases of the healing process. Part of the challenge in comparing results from scientific studies is the fact that “negative effects on wound healing” or “wound healing complications” are rarely specified and when they are the definition somewhat varies between studies (Lazarus *et al.*, 1997). The widest definition of wound healing complications would be that the wound does not meet the expectations concerning microbial activity, structural quality and mechanical integrity in relation to time and healing-phase (Lazarus *et al.*, 1997). The underlying reasons and risk factors can be many and a brief overview will be presented in this work. A set of guidelines were summarized and presented by Franz *et al* 2008 targeting these risk factors aiming to minimize wound healing impairment in soft tissue wounds on humans. The guidelines are subdivided in two main categories, systemic and local, and eleven subcategories that fall under these. Systemic factors described were immunology, oncology, miscellaneous systemic conditions, thermal injuries, external agents and excessive scarring. Local factors taken into consideration were wound perfusion, tissue viability, hematoma and/or seroma, infection and mechanical factors, the latter being described as the success or lack thereof in achieving a first intention healing. The following headlines are based on the guidelines published by Franz *et al* 2008 and adapted and described according to relevance in veterinary medicine.

### *Concomitant systemic disease*

There are various systemic diseases of genetic- and infectious background as well as endocrinopathies (where the aetiology is not yet completely understood) that can interfere

with normal wound healing. In a retrospective study on two hundred and thirty-nine dogs and cats that had clean-contaminated surgical procedures Nicholson *et al.* (2002) found that patients with a concurrent endocrine disorder were 8.2 times more likely to develop postoperative surgical site infections. Endocrinopathies represented in the group of animals that developed infections in the study were hyperadrenocorticism (Cushing's) and hypothyroidism. Diabetes Mellitus is an endocrine disorder associated with chronic wounds in human health care and murine models in research have shown the same tendencies of impaired wound healing in animals (Gibran *et al.*, 2002). In cats the feline immunodeficiency virus has been implicated in delayed wound healing (Tobias & Johnston, 2012) and in dogs canine leukocyte adhesion deficiency (CLAD) (Bauer *et al.*, 2004), haemophilia and von Willebrand's disease (Hoffman, 2008) are associated with impaired wound healing.

### *Medical treatment*

Human patients receiving immunosuppressant therapy, especially in higher doses, can be expected to have a prolonged wound healing (Busti *et al.*, 2005) and studies on rat show similar results (Wicke *et al.*, 2000). Human oncology patients receiving chemotherapy or radiation therapy have impaired wound healing and the same should be expected to be true for animals receiving corresponding treatment. Cancer treatment aims to target fast replicating cells and therefore affects cell regeneration in wound area through the same mechanisms (Franz *et al.*, 2008).

### *Thermal injuries*

Thermal wounds can present many challenges regarding their healing process but will not be discussed in this work.

### *Excessive scarring*

The aetiology of why certain wounds experience excessive scar formation or even keloid formation is unknown and therefore there is no standard treatment or means to prevent it from occurring (Franz *et al.*, 2008).

### *Wound perfusion*

A reduced perfusion to wound area can be caused for instance by chock, hypotension, hypovolemia, hypothermia, arterial- or venous impairment, pain, reduced cardiac output or Diabetes Mellitus (Worthley, 2000). Insufficient debridement of necrotic tissue also interferes with perfusion and should be addressed before attempting wound closure (Knighton *et al.*, 1981; Ayello & Cuddigan, 2004). With a decreased wound perfusion the inflammatory response is delayed, the proliferative phase is impaired and the maintenance of oxygen pressure in tissue is complicated. Neutrophils are highly dependent on a high oxygen pressure to effectively kill bacteria and are therefore sensitive to wound ischemia causing a higher risk of failure to control bacterial colonization in ischemic tissue (Tobias & Johnston, 2012). Ischemia also has a negative effect on angiogenesis and collagen production (Knighton *et al.*, 1981; Ueno *et al.*, 2006).

### *Surgical site infection (SSI)*

The incisional infection is subtyped into superficial (skin and subcutis) and deep (skin, subcutis, fascia and muscle) and differed from organ- or space infection, which occurs in body cavities, specific organs or joints (Tobias & Johnston, 2012; Turk *et al.*, 2014). Estimated prevalence of SSI in clean-contaminated surgeries is just below 6% (Nicholson *et al.*, 2002). Several factors increase the risk of surgical site infections such as contaminated surgeries (i.e. GI tract or traumatic wounds), animals scoring ASA III or higher at time of surgery (Mangram *et al.*, 1999; Nelson, 2011), when failing to maintain normothermia (Melling *et al.*, 2001), euglycemia (Dronge *et al.*, 2006) and wound oxygen pressure (Qadan *et al.*, 2009). The risk for SSI can be as much as 30% higher if there is a lot of staff coming and going in the operating room during surgical intervention (Eugster *et al.*, 2004). A prolonged anaesthesia, for instance when a CT or MR is needed, also increases the risk for SSI and for every hour the risk increases with approximately 30% according to a retrospective clinical study by Beal *et al.* 2000 on seven hundred seventy-seven dogs and cats undergoing clean surgical procedures. Animals with more than three diagnoses at time of discharge are also at higher risk than the general population. Intact male dogs and cats have a higher risk for SSI due to androgenous effect (Nicholson *et al.*, 2002). Common bacteria found in SSI include *Staphylococcus* spp, *E.coli*, *Pasteurella* spp and *Bacteroides* spp (Sveriges Veterinärförbund, 2009). Standard reportings of SSI for clean wounds in Swedish veterinary practice is usually about 5% (Sveriges Veterinärförbund, 2009). Taking the above mentioned risks into consideration when planning surgical procedures is crucial to actively prevent surgical site infection. In some cases, where there is an expected significant increase in risk for SSI, perioperative antibiotics can be administered to ensure a low bacterial load and bacteria-host defense equilibrium in favour of host at time of surgery. It is generally sufficient with well-timed peri- and intraoperative doses of antibiotics when given with prophylactic indication (Nazarali *et al.*, 2014).

### *Mechanical stress*

The formation of hematoma and seroma in the post-operative period is recognized as an important factor impairing wound healing (Bullocks *et al.*, 2006). The formation of hematoma is caused by leakage of blood to the area for various reasons such as insufficient intraoperative haemostasis, uncared tissue handling during surgery, patient suffering from coagulopathy or patient being treated with anticoagulant medication (Bullocks *et al.*, 2006). The aetiology of seroma formation is less clear but Bonnema *et al.* 1999 concluded in their study that the composition of fluid content was very close to that of peripheral lymph fluid suggesting leaking lymphatic vessels as a possible origin. Surgical dead space is thought to enable accumulation of fluids and seroma formation is common after mastectomy since this is associated with both disruption of lymphatic vessels and surgical deadspace (van Bommel *et al.*, 2011). Risks associated with fluid accumulation are increased rate of wound infections and skin flap necrosis (Bullocks *et al.*, 2006).

Tension on tissue in wound site area is both a necessity for wound closure but can also be detrimental when excessive (Pickett *et al.*, 1996; Macpherson & Lee, 2010). When skin is incised wound edges pull apart creating a tension with a direction away from the incision line. Elliptical incisions, used for instance when removing skin defects, creates more tension than



straight incisions (Macpherson & Lee, 2010). When closing wounds by means of suturing a tension is created to approximate wound edges and help the wound healing process by minimizing the area that needs to be covered with epithelium. Choice of suture technique and amount of tension on incision should be optimized since these factors can either be an advantage or a disadvantage for the healing wound. The suture technique dictates the direction of tension on the healing wound and therefore plays an important role both in facilitating healing and ensuring that the end result is cosmetically satisfying (Macpherson & Lee, 2010). Wounds sutured with excessive tension experience less cutaneous blood flow (Sagi *et al.*, 2008) and may result in skin edge necrosis and distortion (Burkhardt *et al.*, 2008).

### *Nutritional status*

The nutritional status of the surgical patient is much relevant and should be considered, and if possible, corrected before surgery when surgery is elective. Malnourished as well as obese humans are at higher risk for wound healing complications (Guo & DiPietro, 2010) and it is considered that these effects are also true for animals although studies are sparse especially concerning obesity and its effects on wound healing in animals (Tobias & Johnston, 2012). The nutritional status of an individual can also be affected by concomitant disease such as cancer (cancer cachexia) (Esper & Harb, 2005; Lohsiriwat, 2008), hyperthyroidism, hypothyroidism (Nicholson *et al.*, 2002), protein losing enteropathy (PLE) (Goodwin *et al.*, 2011) and diabetes (Dronge *et al.*, 2006) and for these patients it is important that the disease is under treatment and stabilized before elective surgery.

## **MATERIALS AND METHODS**

The study was performed using client owned dogs and cats. Patients were selected after assessing available information from booked appointments and patient records at University Animal Hospital, Swedish Agricultural University, regarding type of surgery and patient's history of illness. Patients were recruited from April 2016 to October 2016. Clients were given oral and written information and were asked to sign a consent form. Clinical experimentation was approved by the Uppsala animal ethics committee. This study was a part of a larger study evaluating effects of local anaesthetics on wound healing.

Material used in this study was a Meditherm camera, IRIS 2000 for thermal imaging with a 25 deg FOV lens with a focus range from 5 cm to infinity. A Casio Exilim HS, EX-ZR 1000 was used to take pictures of wound area to ensure a standardized interpretation of each wound. Two distances intended to standardize optical effects when using the Casio camera, 10 cm distance and 15 cm distance, were attached to the camera when photographs were taken and printed adhesive etiquettes for journal reference were attached to these and visible in photographs. Adhesive non-transparent tape was used to create intentional artefacts in thermal images marking beginning and end of incision line and strategic reference points when incision was not straight. Thermal images were processed using customized software developed by Meditherm Inc. from the original version of the WinTes3 program.

The animals included in the study were scheduled for various types of surgery and chosen based on the following criteria: Patients scheduled for clean or clean-contaminated surgery with an ASA score of I or II, a body mass of minimum 5 kg and planned incision estimated to

exceed 4 cm were included. Patients with higher ASA scores, systemic illnesses (Diabetes, HIV, Cushing), receiving immunosuppressive treatment, having contaminated skin or skin disease or with history of prolonged wound healing were excluded. Given the increased risk for complications during healing of carpus and tarsus arthrodesis, major tumour resections, advanced reconstructive surgery and wounds in need of drainage these patients were also excluded.

Patients participating in the study were given a randomly selected envelope containing information to place them in treatment group A or B, this part being related to another study. The envelopes were drawn by staff not committed to the study and followed the patient to the preoperative preparation room before they were opened. The nurse assigned to assist during operation was left in charge of opening and administering selected substance before moving the patient to the operating table and both study manager and surgeon were blinded to the content of the envelope. Patients drawn to group A were administered 0.25 ml xylocain without adrenaline 10 mg/ml per centimetre whereas patients drawn to group B were given corresponding volumes of NaCl. Injections were given superficially in subcutaneous tissue. Maximum dose of xylocain was 5 mg/kg.

Five to seven days after performed surgery clients were asked to fill out a simple form with mainly yes or no questions assessing the status of the patient's wound (see Appendix A).

Fourteen days (+/- 2 days) after surgery clients were asked to return to the clinic and bring the patient for wound assessment, photographic documentation of wound site and thermal imaging. Wound was assessed according to protocol (see Appendix B). Images were taken with a Casio Exilim camera using the distances mentioned above. In cases with very long incisions a generalized photo of the entire area was taken at convenient distance. In cases with protocol scoring above 0 close ups of were taken of the areas of interest as a control to verify consistent assessment between patients. The thermal imaging was performed after 10 minutes of acclimatization in the draught free and ambient, 21°C +/- 2.1°C (with the exception of one patient when the room temperature was 29°C) examination room. Imaging was performed with patients standing or lying down (depending on anatomical site of wound) on examination table, ground or in owner lap with a distance of 30-45 cm between object and camera. Start and end of wound was marked in all wounds with non-transparent adhesive tape preventing heat emission from these areas to create an intentional artefact in the thermal image. Several captures were made of each wound to ensure the entire wound was included and the focus and quality of the image was satisfactory. Surgical wounds were divided into the following groups for processing and comparison: linea alba incisions, mastectomies, orthopaedic surgeries and mixed group.

When processing the thermal images two-three regions of interest (ROI) were created, each contributing with the lowest, highest and mean temperature of that area. The mean of the value of ROI 2 and ROI 3 was subtracted from the value of ROI 1 to obtain the temperature difference between wound and control areas. The results were tested for normal distribution and depending on the result either tested for significant temperature difference between ROI 1 and ROI 2 (when only one control area could be made) or mean of ROI 2 and ROI 3 using the

Wilcoxon test or Paired t-test. “Mean” values from thermal image processing were used for comparison with clinical protocol. These values were then compared with each individual parameter from the clinical evaluation form (see Appendix B) and tested for significance. For those values in the evaluation form that had categorical values a Paired, two way, t-test was performed. In the cases of “Redness” and “Swelling” which had numerical values creating three different groups ANOVA testing was chosen. A total inflammation score was calculated based on scores from the “Clinical wound healing evaluation” form giving the patients between 0 p to a maximum of 20 p. A part from basic scoring, consisting of sum of points from protocol, additional points (0-2p) were given, depending on percentage of wound affected, in each of the following groups: wound dehiscence, redness and swelling. Wounds where 0-33% of total incision line was affected were given 0 p, when 34-66% of the total incision line was affected an additional 1 p was given and when 67-100% of incision was effected additional 2 p were given. The total inflammation score was tested against the thermal images using a Spearman correlation. Since 41% of the wounds evaluated had sutures at the time of thermal imaging this was tested for significance using a Paired t-test. To test if certain types of surgeries were more or less difficult to correlate with the thermal imaging results the surgeries were grouped in linea alba incisions, mastectomies, orthopaedic surgery and mixed and tested using the Kruskal-Wallis test.

## RESULTS

This study included thirty-nine dogs and two cats undergoing thirteen different surgeries (see Table 1).

Table 1. *Different surgeries included in the study*

| Surgery   | Number of animals | Distribution |
|---|-------------------|--------------|
| OHE, pyometra   | 8                 | 19,5 %       |
| OHE*  | 5                 | 12,2 %       |
| Mastectomy  | 11                | 26,8 %       |
| TPLO**  | 1                 | 2,4 %        |
| Extracapsular repair of cranial crucial ligament                        | 2                 | 4,9 %        |
| Castration  | 2                 | 4,9 %        |
| Castration, cryptorchid (inguinal)                                      | 4                 | 9,8 %        |
| Mastocytoma removal   | 2                 | 4,9 %        |
| Stabilization of medial shoulderjoint instability                       | 1                 | 2,4 %        |
| Vesicotomi and urolith removal  | 2                 | 4,9 %        |
| Splenectomy   | 1                 | 2,4 %        |
| Removal of cartilage fragments from tarsocrural joint (Osteochondrosis) | 1                 | 2,4 %        |
| Femoral head resection  | 1                 | 2,4 %        |

\*OHE= ovariohysterectomy, \*\*TPLO= tibial plateau levelling osteotomy

Processing of data from clinical evaluation protocol showed that the highest total inflammation score seen in one patient was 11 p. out of a possible maximum of 20 p. and this score was seen in an Irish Wolfhound having a one sided complete mastectomy. Table 2 shows mean values and standard deviations for each value derived from clinical protocol. Table 3 shows statistical testing of comparison between values from thermal image processing of ROI 1 compared with ROI 2+3 mean (reference areas). A comparison of data from the clinical evaluation protocol and data from thermal imaging (temperature difference between wound area and control areas using the “Mean”-group) is shown in Table 4.

Table 2 Mean points and standard deviation derived from clinical protocol

| Protocol parameter       | Min/max values | Possible min/max values | Mean values | Standard Deviation |
|--------------------------|----------------|-------------------------|-------------|--------------------|
| Infection                | 0/2            | 0/2                     | 0,19p       | 0,60               |
| Pain                     | 0/2            | 0/2                     | 0,10p       | 0,44               |
| Tissue separation        | 0/2            | 0/4                     | 0,24p       | 0,66               |
| Redness                  | 0/4            | 0/4                     | 0,88p       | 0,56               |
| Swelling                 | 0/4            | 0/4                     | 0,27p       | 0,59               |
| Seroma                   | 0/2            | 0/2                     | 0,05p       | 0,31               |
| Suppuration              | 0/1            | 0/2                     | 0,05p       | 0,22               |
| Total inflammation score | 0/11           | 0/20                    | 2,83p       | 2,39               |

Table 3. Temperature difference between wound and control area (ROI) based on thermographic evaluation

| Pairing* | Region of interest | Normal distribution | Test for significance | P-value (ROI 1 vs. ROI 2+3 mean) |
|----------|--------------------|---------------------|-----------------------|----------------------------------|
| 1        | ROI** 1 Max        | No                  | Wilcoxon              | <0.0001                          |
| 1        | ROI 2+3 mean Max   | No                  | Wilcoxon              |                                  |
| 2        | ROI 1 Min          | Yes                 | Paired t-test         | <0.0001                          |
| 2        | ROI 2+3 mean Min   | Yes                 | Paired t-test         |                                  |
| 3        | ROI 1 Mean         | Yes                 | Paired t-test         | 0.0060                           |
| 3        | ROI 2+3 mean Mean  | Yes                 | Paired t-test         |                                  |

\*ROI's with corresponding numbers were compared for significance of temperature difference

\*\*ROI= region of interest

In the linea alba group the incision line was generally very straight and therefore only needed to be marked at the beginning and end of incision at thermal imaging to enable thermal image interpretation (see Figure 2). Positioning of the animal was given extra consideration when the patient had significantly pending mammary glands, in which case the animal was

completely on its back during imaging. In cases with male animals and patients with modest amounts of mammary gland tissue it was generally sufficient if the animal was placed on its side with the top leg properly lifted to avoid skin folds in the area of interest. In the linea alba group the thermal images generally showed a higher temperature in the most caudal area. Teats showed a lower temperature than the rest of the body and therefore were not included in ROI's.

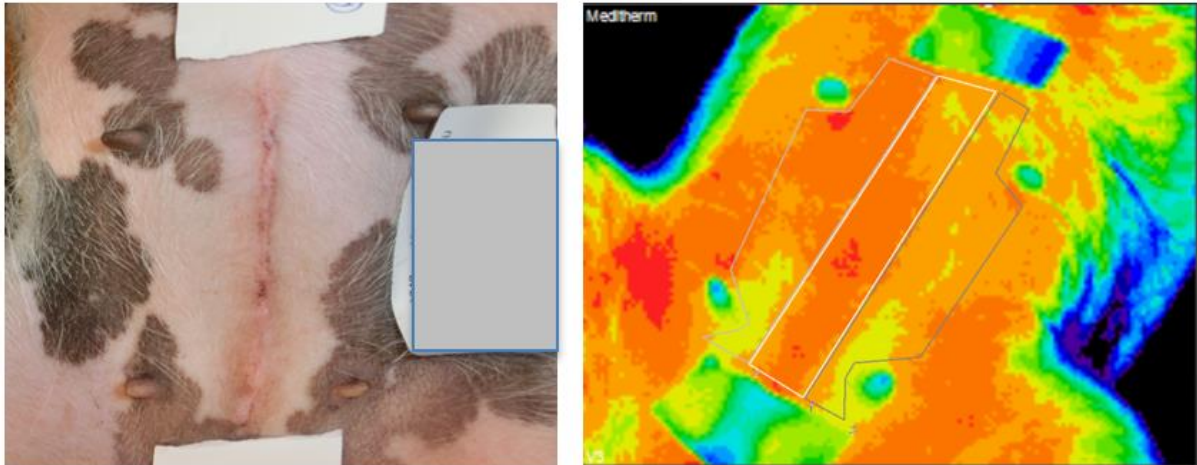


Figure 2. Images of linea alba incision on a dog after ovariohysterectomy. Left image showing normal photograph of the area of interest, white tape marking start and end of wound and identity of patient to the right (covered due to patient secrecy). Right image shows thermal image of the same patient. In the thermal image the white tape and teats are depicted in green-blue colours. Three ROIs are outlined, ROI 1(wound area) in the middle.

The mastectomy was in many aspects similar to the linea alba group. This group had more variations within the group than the linea alba group given that depending on tumour site (all animals in this group had surgery to remove tumours) different parts of the mammary glands were removed and to various extents. When surgical site was in the caudal part of the abdomen this group showed the same pattern of increased temperature as the linea alba group. In the study two of the patients in the mastectomy group were of giant dog breeds (Leonberger and Irish Wolfhound). These patients had onesided complete, radical mastectomies, and therefore had incision lines too long to be fully included in thermal images of good focus and quality. In these cases a series of overlapping images were taken and the data was processed to give a mean value representative of the wound. Since the beginning and end of the incision line could not be included in the same image additional markers were placed strategically to indicate wound area to facilitate interpretation (Figure 3).

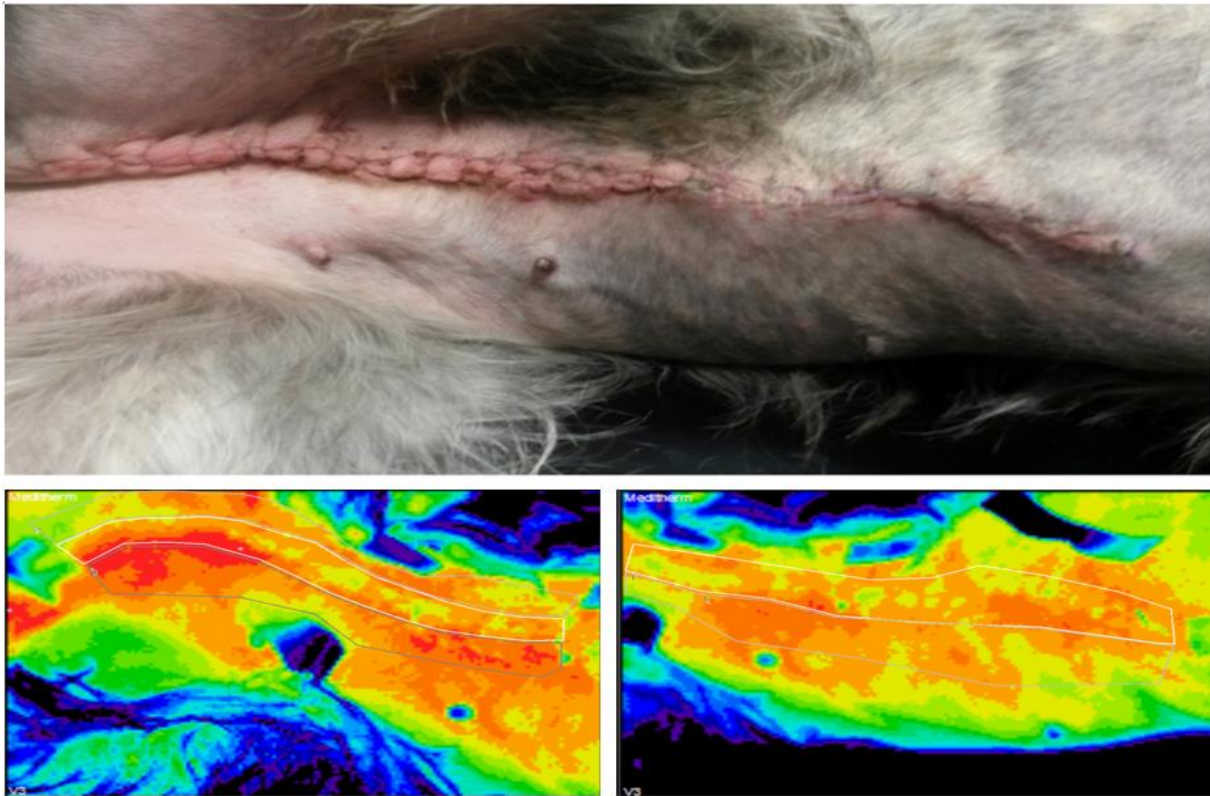


Figure 3 *Onesided radical mastectomy on an Irish wolfhound. Above image was taken without standardized distances to give an overview of wound area. Below left image is the thermal image of the caudal part of the same patient and below right is the cranial aspect of the wound. The thermal images overlap and was calculated for a mean during image processing.*

Included in the mastectomy group there was also a case with a female dog where two very large tumours, one on each side of the fifth mammary glands were removed. The patient was included twice in the local anaesthesia study (of which one surgery could be included in this study) since both tumours could not be removed at the same time. At the first revisit the tumour on the left side had been removed and the remaining tumour (Figure 4) was sent for pathological analysis after removal at second surgery. Pathological examination of tissue samples from the tumour in Figure 4 showed both atypical lobular mammary gland hyperplasia and tubulopapillary carcinoma. The tumour was depicted as colder than surrounding tissue. This case needed special consideration concerning multiple special features. The first time the patient still had one tumour left approximately 10 x 6 x 3 cm, which had forced the surgeon to make a rounded incision to avoid cutting in the tumour. Additional markers were placed to facilitate image processing but the placement of these was not entirely simple since there was an area on the patient's left side (opposite of the tumour), which was undesirable to block with markers, therefore multiple photographs were taken for comparison with thermal images.

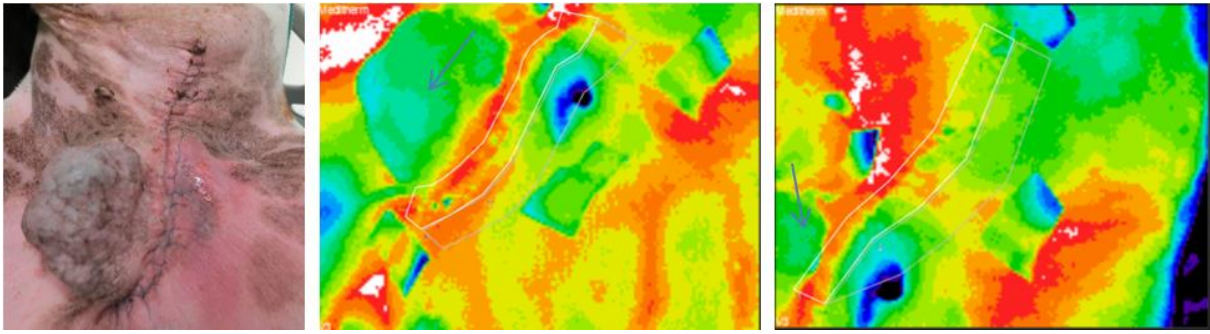


Figure 4 *Left image is an overview of wound area. In this image five challenging features of the patient's wound area are illustrated; the curved incision line, Ethilon sutures, the remaining tumour, the red area on the opposite side of the incision from the tumour and a small amount of clear liquid in the cranial aspect of the red area. Thermal images (middle and right) are overlapping, the middle image representing the most caudal part of the wound and the right image the most cranial aspect. The arrows identifies the mammary tumour on the right side.*

Discoloured area opposite of tumour was classified as diffuse swelling at clinical examination and represented as colder than surrounding tissue in the thermal images. The small amount of seroanguinous fluid found in the cranial part of the dark skin discoloration was depicted as colder than the swelling and is shown in dark blue colour in thermal images. The second time the patient came was after this part of the study was finished hence the results are not included in the data of this work. It can be mentioned that the second time the patient presented with persistent red/blue discoloration of the skin from the first surgery, which was a challenge for correct clinical assessment. At the second visit the patient also had an accumulation of fluid on the medial part of the thigh adjacent to the incision line that was colder than surrounding tissue in thermal images.

The third group consisted of patients that had undergone different orthopaedic surgeries, the most common being anterior cruciate ligament rupture repair. Due to the anatomical site of surgical intervention this group presented completely different challenges than other groups included in the study. With these patients it was more challenging to gain good access to a clear view of the wound area since the incision line was generally very close to the thin and most cranial aspect of the hind leg making patient positioning more important. Patients were standing or lying down on the side with one leg lifted to obtain a complete view of the narrow area of interest. The incision was also not straight which, in combination with the very slim area of interest, presented challenges to the interpreter (Figure 5). In other surgical sites additional markers could easily be placed to outline a curved incision line, but since the area of interest was very slim over the stifle, additional markers would inhibit the possibility to create reference areas of interest. To facilitate image interpretation multiple photographs were taken of these patients for comparison with thermal images to avoid disturbing image interpretation with markers.

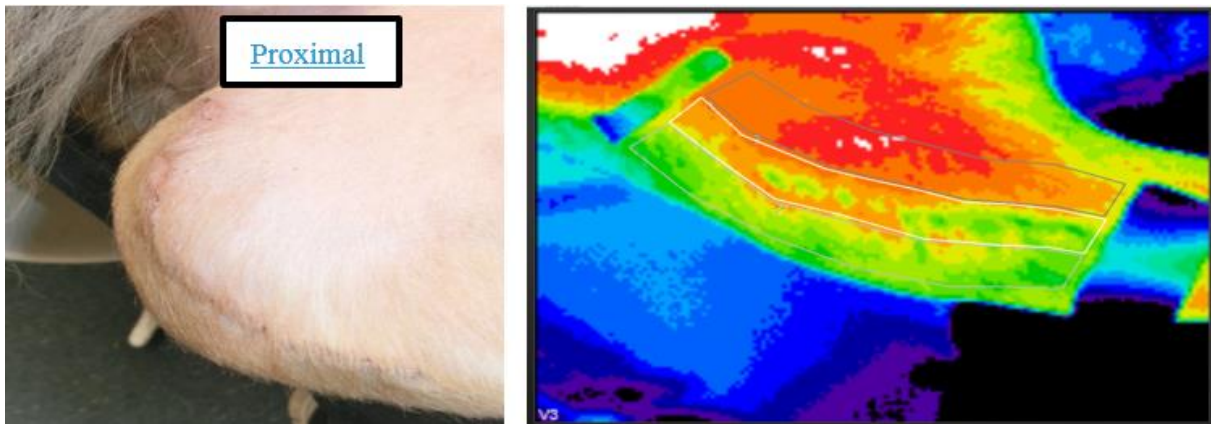


Figure 5 Left image shows patellar area on the right hind leg of a dog and corresponding thermal image is shown to the right. Interpretation of images of these surgeries is somewhat easier if the hind leg is kept straight when depicted (see thermal image on the right side) although some animals was reluctant to cooperate due to post surgical discomfort from joint area.

All orthopaedic surgeries where external fixations are used cannot be assessed with the same thermal imaging interpretation method that was used for this study since the fixation creates artefacts that blocks the entire incision line (Figure 6).




Figure 6 External fixation after surgical repair of a femur fracture in a cat. Left image showing the placement of the external fixation on cat's right hind leg and right image showing thermal image. The external fixation is dark blue in the thermal image and completely blocks the incision line. In the upper half of the image a warmer field is depicted.



Included in the “other” group were two routine pre-scrotal castrations that deserve a special mention since they have a very specific thermal presentation. Due to the protruding nature of male genitals these are generally cooler than surrounding tissue. This specific feature, found only in male dogs, is also present in other surgeries where the incision is placed in that area (Figure 7 and 8).

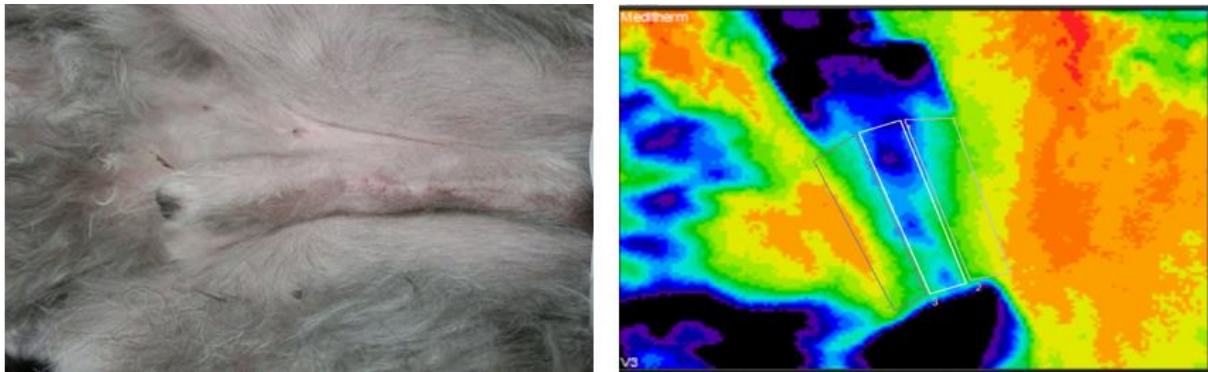


Figure 7 Left is normal photograph and right is corresponding thermal image of a dog after pre-scrotal castration. Thermal image shows the same area but the image is turned approximately 80 degrees clockwise. In the thermal image two markers are visible and represented as dark blue, almost black, colour and at the top of the image the preputial area can be seen in the same colours. Between the wound markers the penis is depicted as a cold ridge with wound area being the coldest.

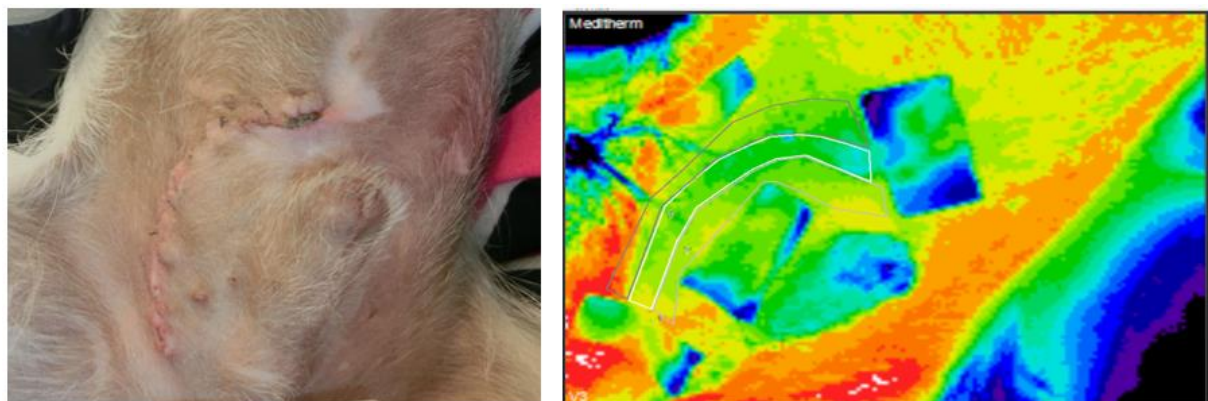


Figure 8 Left image shows the curved incision on the patient's right side of the penis on a dog recovering from surgical urolith removal. Right image shows the thermal image of the same area with the patient positioned in a way corresponding (although slightly tilted) to that of the left photograph. The thermal image illustrates in a very typical way the thermal representation of dogs' male genitals.

Also in the “mixed” group were two dogs having had mastocytomas removed from various sites. On one of the dogs the tumour was removed from area of biceps femoris musculature (Figure 9) and the wound had a curvy outline. In this case normal photograph and knowledge of anatomy was of good help to trace incision line since it was very difficult making the markers stick to the skin due to extensive movement over the well-developed muscles in the area every time the dog shifted position. This dog had clinical signs of inflammation in the distal third of the wound and an area with higher temperature in the distal, caudal part of the wound is visible in the thermal image.

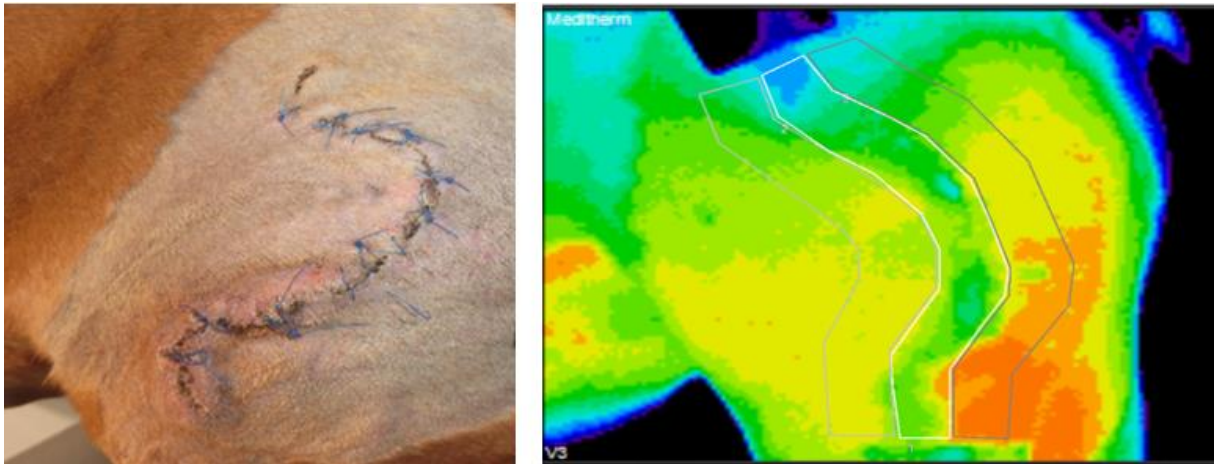


Figure 9 *Left image showing the dog in a sitting position where the curved appearance of incision line is very well demonstrated. Right image is the thermal image of the area with the dog in a standing position. Incision line is colder than surrounding tissue and there is a dark orange field at the distal, lateral part of the wound.*

Results from thermal image processing showed that all values had a normal distribution apart from the maximum values in the ROI's. In 68% of the subtractions made in the "Mean" group results had a negative value, indicating that ROI 1's in most cases were colder than control areas.

None of the statistical tests performed showed any statistical significance between thermal image evaluation and clinical evaluation of wound areas.

Table 4. Statistical testing for correlation between temperature difference between wound area and control area using the “Mean”-group from thermal image analysis and clinical evaluation of surgical wound

| Analysis                   | Test           | p-value |
|----------------------------|----------------|---------|
| Infection                  | t-test         | 0.65    |
| Antibiotic treatment       | t-test         | 0.64    |
| Pain                       | t-test         | 0.31    |
| Tissue separation          | t-test         | 0.47    |
| Redness                    | ANOVA          | 0.58    |
| Swelling                   | ANOVA          | 0.75    |
| Seroma                     | t-test         | 0.76    |
| Suppuration                | t-test         | 0.11    |
| Inflammation score         | Spearman       | 0.43    |
| Ethilon sutures at imaging | t-test         | 0.77    |
| Ethilon sutures            | t-test         | 0.88    |
| Surgery group              | Kruskal-Wallis | 0.39    |

A total of seven patients included in the study received postoperative antibiotic treatments of which four had a confirmed infection.

## DISCUSSION

Wound healing has an essential role in postoperative recovery and return to normal activity. There are many factors that can potentially affect the wound healing in a negative way, persistent inflammation or infection being two of them (Guo & DiPietro, 2010). Early detection and diagnosis of compromised wound healing enables use of countermeasures to prevent the occurrence of more serious complications (Nelson, 2011). Based on results from previous studies using thermal imaging both on humans and animals (Parisky *et al.*; Levet *et al.*, 2009; 2003Vainionpää & others, 2014) we hypothesised that this method would be sensitive enough to detect signs of wound healing complications that otherwise would go undetected through merely clinical examination. Our aim was to validate the method both concerning accuracy in detection of wound healing complications and also its usability in a clinical setting rather than a strict research setting. The advantages of thermal imaging in a

clinical situation is that it is non invasive, the animal does not need to be sedated, and should not be sedated since this effects blood circulation, and since it is a no contact technique it only requires minimal restraint of the animal (Eddy *et al.* 2001; Grossbard *et al.*, 2014). Also the technique is safe for practitioners, owners and animals in that it produces no harmful radiation (Eddy *et al.* 2001; Grossbard *et al.*, 2014).

An interesting feature, compared to what Całkosiński et al 2015 found when studying rat models, our study revealed a significantly lower temperature in the incision area compared to control areas. This was an unexpected finding and speculations can be made about the reason for this. One possible reason could be that the rats in Całkosiński's study were examined at times from 10 minutes to 120 hours after injection of irritant when the inflammatory activity can be expected to be high. Animals in this study were examined at approximately 14 days post surgery when the expectation on the wound healing is that it is at the end of the proliferative phase and moving more towards the maturity phase (Hosgood, 2006; Teller & White, 2009; Tobias & Johnston, 2012). At this point there is a higher degree of collagen in the wound than at early to late inflammatory phase which was when the rats were examined (Teller & White, 2009; Tobias & Johnston, 2012) possibly accounting for the lower temperature in wound area. If, in contrast, the wound healing would have been delayed we expected the inflammatory phase to be delayed causing a thermal pattern with higher temperature in wound area. The fact that we did not have any patients with severely delayed healing accounts for lack of inflammatory heat pattern in thermal images. If imaging would have taken place within the timeframe of the inflammatory phase our results might have been different.

Basic criteria for a successful session of thermal imaging are: a controlled environment (draught free, windowless, ambient temperature) and an animal that is clean, dry and has had a minimum of 10 minutes to adjust to room temperature (Tunley & Henson, 2004). In small animal practice it is customary that the owners bring their animals to the clinic and that the examination takes place indoors contrary to e.g. horses and cattle where examination areas are much different and more variable. The general setting for small animal patient visits makes the controlled environment criteria fairly easy to meet and most clinics have at least one windowless room and the rooms are generally draught free and have an ambient temperature. During this clinical trial it was confirmed that the greatest challenges are mainly associated with the animal not the examination area.

In clinical practice time is a key factor, first time visits are held short and follow up visits even shorter. In previous studies the time for an animal to acclimatize to the examination area has ranged between 10 minutes to 3 hours (Eddy *et al.*,2001; Holmes *et al* 2003; Ringer *et al.*, 2005; Pavelski *et al.*, 2015). In this study we gave the patients 10 minutes to acclimatize to best test the usefulness of thermography in everyday clinical practice. One issue related to time and owner compliance was that almost half of the patients included in the study had non-absorbable sutures that needed removal. In the chosen study design the choice was between removing the sutures before thermal imaging or leaving them to be removed after the images were taken. If sutures are to be removed before imaging the 10-minute acclimatization time might not be sufficient since suture removal is associated with various degrees of

manipulation of the wound area. There are no studies known to the author that specifically compares time needed to adjust between wound areas that have been manipulated and those who have not. In studies on horses time elapsed between grooming, that might be compared to manipulation of surgical wound area, and thermal imaging has varied from 10 minutes (Soroko *et al.*, 2013) to 2 hours (Eddy *et al.*, 2001) without making reference to scientific reports supporting the chosen time indicating that little is known about this factor. If sutures are not removed before imaging they will be visible in the thermal image as cold artefacts and will lower the average temperature in the wound area. Assuming that a significant inflammation would raise the average temperature enough to present a significant difference between wound area and control area/-s even though sutures were not removed the choice was made to leave these. When tested for significance the suture material did not have any significant effect on temperature in wound area compared with the wounds evaluated without suture material. One advantage when using thermal imaging to study wound areas is that these are shaved in preparation for surgery, hence there are generally no problems with excessive dirt or water sticking to the fur in the area of interest hence eliminating the issue with grooming mentioned above.

In this study a variety of surgical wounds were included and these were divided in 4 subgroups depending on surgical site. Each subgroup had different characteristics and features that needed to be taken into consideration, the main ones being; heat/cold artefacts, long incision lines, irregularly shaped incision lines and incisions made in anatomical sites not wide enough to create three areas of interest.

In the linea alba group and the mastectomy group the thermal heat pattern showed consistent higher temperatures in the caudal part of the abdomen most likely caused by a higher degree of skin-to-skin contact in this area. These heat artefacts have to be taken into account when designing studies involving thermal imaging of this area. In this study we were not interested in absolute temperatures and the amount of heat artefacts are hypothetically the same in all three regions of interest, hence it will not create a false difference in temperature between the incision area and the reference areas, which is why these patients could be included in this study. Incisions in the linea alba group were the most standardized concerning anatomical placement and length compared with the other groups.

The mastectomy group had variations concerning both anatomical location and extent of surgery ranging from removal of one mammary gland to one side complete mastectomy. In cases with long wounds these had to be depicted in overlapping sequence to include the entire incision. Data from these images were then calculated for mean values. In the case with the patient presenting with a large tumour of both benign and malignant character at imaging the tumour was depicted as blue in the thermal images meaning that it emitted significantly less thermal radiation than surrounding tissue. This thermal representation of the tumour was quite interesting given that previous studies have described mammary tumours, especially malignant tumours, in both dogs and humans as areas of increased thermal radiation (Kennedy *et al.*, 2009; Pavelski *et al.*, 2015). The swelling on the opposite side of the tumour was firm and the skin was markedly red over this area. The expectation was that this area would be depicted as significantly warmer than surrounding tissue in the thermal images but it

turned out to be the opposite. A possible confounding factor here would be that in fact the clinical assessment was not correct and the area should not have been classified as a swelling but rather a seroma or hematoma and that perhaps these are more likely to emit less thermal radiation. The author has found no studies comparing thermal representation of seroma, hematoma and tissue swelling thus thoughts about this can only be speculative. The liquid seen in the photograph of this patient (Figure 4) had a lower temperature than surrounding tissue adding to the speculation that perhaps thermal patterns of liquids and liquid accumulations are colder than surrounding tissue.

The cat seen in Figure 6 with an external fixation could not be included in this study due to interpretation issues, but raised questions about the possibilities of monitoring of bone fracture healing using thermography. Visible in the thermal image of this cat is an area of increased thermal radiation possibly corresponding to fracture site raising the question if thermal imaging can be used to evaluate bone fracture healing. Thermal imaging has been shown to successfully identify stress fractures on tibia in horses according to review article by Eddy *et al.*, 2001 looking at a total number of 64 horses presenting with lameness of different aetiology. The increased thermal pattern might be due to soft tissue trauma associated with the trauma causing the bone to fracture but is suggestive of a scientific base for further research in this field.

The experience from this study is that thermal representation of male genitals in dogs needs to be taken into consideration if study goal is to acquire absolute temperatures from this area and/or compare results between patients especially if they are of different genders. When the patient serves as its own internal reference and the absolute temperatures are of minor interest it is only the somewhat narrow area of interest that might cause problems.

The patient from the “other” group shown in Figure 9 had clinical signs of inflammation in the distal third of the wound. Interestingly the incision line itself was colder than surrounding tissue, possibly an artefact from sutures, but with a distal, lateral field with higher temperature. There are a few possible explanations to this representation, one would be that the suture material is in fact creating a significant artefact disguising a potentially abnormal heat pattern. Another explanation could be that this is an area where a fold is created every time the dog sits down creating skin-to-skin contact artefacts, and since this patient was very restless on the table, shifting from a standing to a sitting position numerous times this might create thermal artefacts. There is also the possibility that for some reason the distal inflammation was more active in this particular area at the time of imaging.

The overall response from pet owners remained positive throughout the study since thermal imaging enables more flexibility than other imaging techniques concerning where the animal is placed during the imaging procedure. Since the equipment is portable and relatively easy to move to enable imaging with the animal on the examination table, on the floor and sometimes in the owners lap the response from the animals were also generally positive.

Since many of the wounds presented with one or several small areas of considerably lower or higher temperature than the average ROI temperature the “Mean” values were picked out as the most reliable for further comparison with clinical examination protocol. When compared

with clinical protocol no statistically significant correlation was found indicating that thermal imaging is perhaps not best used this way. From a practical standpoint the clinical evaluation provided enough information for clinically relevant decision-making rendering thermal imaging superfluous in this context. Patients included in the study, experiencing signs of infection were identified at an earlier stage than scheduled thermography appointments. Included in this study there were seven patients with suspected infections of which four were confirmed with a positive bacterial culture. When these patients were evaluated for the study they had already received antibiotic treatment and infection and inflammation was under control explaining the lack of abnormal thermal images. The conclusion from this was that to be able to identify early stage infections by means of thermography the screening should advantageously be performed at an earlier point. To further evaluate the potentials of thermal imaging in wound healing evaluation, a different approach should be adopted where wounds are repeatedly examined during the inflammatory phase at short intervals. A possible future clinical application that needs further research could be as help in monitoring bone fracture healing providing information to help with rehabilitation.

## **CONCLUSION**

The conclusion from this study was that timeframe chosen for this study's follow-up showed no clinical advantage in using thermal imaging to evaluate surgical wounds. This might in part be explained by the fact that no wounds with markedly delayed wound healing was included in this study. The technology remains highly interesting for research but more studies are needed before it can be implemented in clinical small animal practice.

## **ACKNOWLEDGEMENTS**

Special thanks to my supervisor Annika Bergström, Dipl ECVS, VMD for great support and inspiration and Ian Allen at Meditherm Inc for all the help customizing software to fit our needs.

## **REFERENCES**

- Arruda, T. Z., Brass, K. E. & De La Corte, F. D. (2011). Thermographic Assessment of Saddles Used on Jumping Horses. *Journal of Equine Veterinary Science*, 31(11), pp 625–629.
- Ayello, E. & Cuddigan, J. (2004). Debridement: controlling the necrotic/cellular burden. *Adv Skin Wound Care*, (17), p 66.
- Bauer, T. R., Gu, Y.-C., Creevy, K. E., Tuschong, L. M., Embree, L., Holland, S. M., Sokolic, R. A. & Hickstein, D. D. (2004). Leukocyte Adhesion Deficiency in Children and Irish Setter Dogs. *Pediatric Research*, 55(3), pp 363–367.
- van Bommel, A. J. M., van de Velde, C. J. H., Schmitz, R. F. & Liefers, G. J. (2011). Prevention of seroma formation after axillary dissection in breast cancer: A systematic

review. *European Journal of Surgical Oncology (EJSO)*, 37(10), pp 829–835.

Bergström, L., Johansson, E., Nilsson, R., Alphonse, R. & Gunnvald, P. (2005) *HEUREKA! Fysik kurs B Gymnasieskolan*. Första utgåva. Natur & Kultur. ISBN 978-91-27-56722-1.

Biondi, F., Dornbusch, P. T., Sampaio, M. & Montiani-Ferreira, F. (2015). Infrared ocular thermography in dogs with and without keratoconjunctivitis sicca. *Veterinary Ophthalmology*, 18(1), pp 28–34.

Bonnema J., Ligtenstein D.A., Wiggers T., van Geel A.N. (1999). The composition of serous fluid after axillary dissection. *European Journal of Surgery*, 165(1), pp 9-13.

Broughton, G., Janis, J. & Attinger, C. The basic science of wound healing. *Plast Reconstr Surg*, 2006(117), p 12S.

Bullocks, J., Basu, C., Hsu, P. & Singer, R. (2006). Prevention of Hematomas and Seromas. *Seminars in Plastic Surgery*, 20(4), pp 233–240.

Burkhardt, R., Preiss, A., Joss, A. & Lang, N. P. (2008). Influence of suture tension to the tearing characteristics of the soft tissues: an in vitro experiment. *Clinical Oral Implants Research*, 19(3), pp 314–319.

Busti, A. J., Hooper, J. S., Amaya, C. J. & Kazi, S. (2005). Effects of perioperative antiinflammatory and immunomodulating therapy on surgical wound healing. *Pharmacotherapy: The Journal of Human Pharmacology and Drug Therapy*, 25(11), pp 1566–1591.

Całkosiński, I., Dobrzyński, M., Rosińczuk, J., Dudek, K., Chrószcz, A., Fita, K. & Dymarek, R. (2015). The Use of Infrared Thermography as a Rapid, Quantitative, and Noninvasive Method for Evaluation of Inflammation Response in Different Anatomical Regions of Rats. *BioMed Research International*, 2015, pp 1–9.

Carosena, M. (2012). *Infrared Thermography, Recent Advances and Future Trends*. Bentham e Books.

Celeste, C. J., Deschesne, K., Riley, C. B. & Theoret, C. L. (2013). Skin Temperature during Cutaneous Wound Healing in an Equine Model of Cutaneous Fibroproliferative Disorder: Kinetics and Anatomic-Site Differences: Skin Temperature during Cutaneous Wound Healing. *Veterinary Surgery*, 42(2), pp 147–153.

Christensen, J., Matzen, L., Vaeth, M., Schou, S. & Wenzel, A. (2012). Thermography as a quantitative imaging method for assessing postoperative inflammation. *Dentomaxillofacial Radiology*, 41(6), pp 494–499.

Cilulko, J., Janiszewski, P., Bogdaszewski, M. & Szczygielska, E. (2013). Infrared thermal imaging in studies of wild animals. *European Journal of Wildlife Research*, 59(1), pp 17–23.

Dai, F., Cogi, N. H., Heinzl, E. U. L., Dalla Costa, E., Canali, E. & Minero, M. (2015).



Validation of a fear test in sport horses using infrared thermography. *Journal of Veterinary Behavior: Clinical Applications and Research*, 10(2), pp 128–136.

Dovi, J. V., Szpaderska, A. M. & DiPietro, L. A. (2004). Neutrophil function in the healing wound: adding insult to injury? *Thrombosis and Haemostasis* [online]. Available from: [http://www.schattauer.de/index.php?id=1214&doi=10.1160/TH03-11-0720&no\\_cache=1](http://www.schattauer.de/index.php?id=1214&doi=10.1160/TH03-11-0720&no_cache=1). [Accessed 2016-11-15].

Dronge, A. S., Perkal, M. F., Kancir, S., Concato, J., Aslan, M. & Rosenthal, R. A. (2006). Long-term glycemic control and postoperative infectious complications. *Archives of Surgery*, 141(4), pp 375–380.

Eddy, A. L., van Hoogmoed, L. M. & Snyder, J. R. (2001) The Role of Thermography in the Management of Equine Lameness. *The Veterinary Journal*, 2001(162), pp 172–181.

Eming, S. A., Krieg, T. & Davidson, J. M. (2007). Inflammation in Wound Repair: Molecular and Cellular Mechanisms. *Journal of Investigative Dermatology*, 127(3), pp 514–525.

Esper, D. H. & Harb, W. A. (2005). The cancer cachexia syndrome: a review of metabolic and clinical manifestations. *Nutrition in Clinical Practice*, 20(4), pp 369–376.

Eugster, S., Schawalder, P., Gaschen, F. & Boerlin, P. (2004). A Prospective Study of Postoperative Surgical Site Infections in Dogs and Cats. *Veterinary Surgery*, 33(5), pp 542–550.

Fonseca, B. P. A., Alves, A. L. G., Nicoletti, J. L. M., Thomassian, A., Hussni, C. A. & Mikail, S. (2006). Thermography and ultrasonography in back pain diagnosis of equine athletes. *Journal of Equine Veterinary Science*, 26(11), pp 507–516.

Franz, M. G., Robson, M. C., Steed, D. L., Barbul, A., Brem, H., Cooper, D. M., Leaper, D., Milner, S. M., Payne, W. G., Wachtel, T. L. & others (2008). Guidelines to aid healing of acute wounds by decreasing impediments of healing. *Wound repair and regeneration*, 16(6), pp 723–748.

Gibran, N. S., Jang, Y.-C., Isik, F. F., Greenhalgh, D. G., Muffley, L. A., Underwood, R. A., Usui, M. L., Larsen, J., Smith, D. G., Bunnett, N., Ansel, J. C. & Olerud, J. E. Diminished Neuropeptide Levels Contribute to the Impaired Cutaneous Healing Response Associated with Diabetes Mellitus. *Journal of Surgical Research*, 2002(108), pp 122–128.

Goldman, R. Growth factors and chronic wound healing: past, present, and future. *Adv Skin Wound Care*, 2004(17), p 24.

Goodwin, L. V., Goggs, R., Chan, D. L. & Allenspach, K. (2011). Hypercoagulability in Dogs with Protein-Losing Enteropathy: Hypercoagulability in Protein-Losing Enteropathy. *Journal of Veterinary Internal Medicine*, 25(2), pp 273–277.

Grossbard, B. P., Loughin, C. A., Marino, D. J., Marino, L. J., Sackman, J., Umbaugh, S. E., Solt, P. S., Afruz, J., Leando, P., Lesser, M. L. & Akerman, M. (2014). Medical Infrared

Imaging (Thermography) of Type I Thoracolumbar Disk Disease in Chondrodystrophic Dogs: Thermography of Thoracolumbar Disk Disease. *Veterinary Surgery*, 43(7), pp 869–876.

Guo, S. & DiPietro, L. A. (2010). Factors Affecting Wound Healing. *Journal of Dental Research*, 89(3), pp 219–229.

Harari, J. (1993). *Surgical Complications and Wound Healing in the Small Animal Practice*. Saunders. ISBN 978-0721639844.

Hellyer, P., Rodan, I., Brunt, J., Downing, R., Hagedorn, J. E. & Robertson, S. A. (2007) AAHA/AAFP pain management guidelines for dogs and cats. *Journal of Feline Medicine and Surgery*, 2007(9), pp 466–480.

Hinz, B. (2007). Formation and Function of the Myofibroblast during Tissue Repair. *Journal of Investigative Dermatology*, 127(3), pp 526–537.

Hoffman, M. (2008). Animal models of bleeding and tissue repair. *Haemophilia*, 14(s3), pp 62–67.

Holmes, L. C., Gaughan, E. M., Gorondy, D. A., Hogge, S. & Spire, M. F. The effect of perineural anesthesia on infrared thermographic images of the forelimb digits of normal horses. *Can Vet J*, 2003(44), pp 392–396.

Hosgood, G. (2006). Stages of Wound Healing and Their Clinical Relevance. *Veterinary Clinics of North America: Small Animal Practice*, 36(4), pp 667–685.

Infernuso, T., Loughin, C. A., Marino, D. J., Umbaugh, S. E. & Solt, P. S. (2010). Thermal Imaging of Normal and Cranial Cruciate Ligament-Deficient Stifles in Dogs: Thermal Imaging of Canine Stifles. *Veterinary Surgery*, 39(4), pp 410–417.

Kennedy, D. A., Lee, T. & Seely, D. (2009). A Comparative Review of Thermography as a Breast Cancer Screening Technique. *Integrative Cancer Therapies*, 8(1), pp 9–16.

Keyserlingk J.R., Ahlgren P.D., Yu E., Belliveau N., Yassa M. (2002). Functional Infrared Imaging of the Breast. *IEEE Engineering in Medicine and Biology Magazine*, 19 (13), pp 30–41.

Kladakis, S. (2014). Choosing Sutures in Small Animal Surgery. *J Dairy Vet Anim Res*, 1(3), p 15.

Knighton, D., Silver, I. & Hunt, T. (1981). Regulation of wound-healing angiogenesis-effect of oxygen gradients and inspired oxygen concentration. *Surgery*, (90), p 262.

Lawson, R. (1956). Implications of surface temperatures in the diagnosis of breast cancer. *Canadian Medical Association Journal*, 75(4), p 309.

Lazarus, G., Cooper, D., Knighton, D., Margolis, D., Pecoraro, R., Rodeheaver, G. & Robson, M. Definitions and guidelines for the assessment of wounds and evaluation of healing. *Arch*

*Dermatol*, 1997(130), pp 489–93.

Levet, T., Martens, A., Devisscher, L., Duchateau, L., Bogaert, L. & Vlaminck, L. (2009). Distal limb cast sores in horses: Risk factors and early detection using thermography. *Equine Veterinary Journal*, 41(1), pp 18–23.

Lohsiriwat, V. (2008). Pre-operative hypoalbuminemia is a major risk factor for postoperative complications following rectal cancer surgery. *World Journal of Gastroenterology*, 14(8), p 1248.

Macpherson, N. & Lee, S. (2010). Effect of different suture techniques on tension dispersion in cutaneous wounds: A pilot study: Suture types and wound tension. *Australasian Journal of Dermatology*, 51(4), pp 263–267.

Mehta A. (2011). *Introduction to the Electromagnetic Spectrum and Spectroscopy*. Available: <http://pharmaxchange.info/press/2011/08/introduction-to-the-electromagnetic-spectrum-and-spectroscopy/> [2017-01-05]

Melling, A. C., Ali, B., Scott, E. M. & Leaper, D. J. (2001). Effects of preoperative warming on the incidence of wound infection after clean surgery: a randomised controlled trial. *The Lancet*, 358(9285), pp 876–880.

Mamedov, L. A., Dzhafarov, C. M., Kuliev, E. A. & Guseinov, L. M. (1999). Methods for diagnosis and prevention of pyoinflammatory complications of postoperative wounds. *Bulletin of Experimental Biology and Medicine*, 127(4), pp 433–435.

Mangram AJ., Horan TC., Pearson ML (1999). Guideline for prevention of surgical site infection. *American Journal of Infection Control*, 27, pp. 97.

Nazarali, A., Singh, A. & Weese, J. S. (2014). Perioperative Administration of Antimicrobials During Tibial Plateau Leveling Osteotomy: Perioperative Administration of Antimicrobials During TPLO. *Veterinary Surgery*, 43(8), pp 966–971.

Nelson, L. L. (2011). Surgical Site Infections in Small Animal Surgery. *Veterinary Clinics of North America: Small Animal Practice*, 41(5), pp 1041–1056.

Nicholson, M., Beal, M., Shofer, F. & Brown, D. C. (2002). Epidemiologic Evaluation of Postoperative Wound Infection in Clean-Contaminated Wounds: A Retrospective Study of 239 Dogs and Cats. *Veterinary Surgery*, 31(6), pp 577–581.

Oestreicher N., Lehman C. D., Seger D. J., Buist D. SM, White E., (2005) The incremental contribution of clinical breast examination to invasive cancer detection a mammography screening program. *American Journal of Roentgenology*, 184(2), pp 428-432.

Parisky, Y. R., Sardi, A., Hamm, R., Hughes, K., Esserman, L., Rust, S. & Callahan, K. (2003). Efficacy of computerized infrared imaging analysis to evaluate mammographically suspicious lesions. *American Journal of Roentgenology*, 180(1), pp 263–269.

Pavelski, M., Silva, D. M., Leite, N. C., Junior, D. A., de Sousa, R. ., Guérios, S. D. & Dornbusch, P. T. (2015). Infrared Thermography in Dogs with Mammary Tumors and Healthy Dogs. *Journal of Veterinary Internal Medicine*, 29(6), pp 1578–1583.

Pedrerros F, Pezoa JE, Torres SN. (2012) Compensating internal temperature effects in uncooled microbolometer-based infrared cameras. *SPIE Digital Library, SPIE Proceedings*. 2012; 8355.

Pickett B.P., Burgess L.P.A., Livermore G.H., Tzikas T.L., Vossoughi J. (1996). Wound healing: tensile strength vs healing time for wounds closed under tension. *Otolaryngology-Head & Neck Surgery*, 122, pp. 565-8.

Qadan, M., Akça, O., Mahid, S. S., Hornung, C. A. & Polk, H. C. (2009). Perioperative supplemental oxygen therapy and surgical site infection: a meta-analysis of randomized controlled trials. *Archives of Surgery*, 144(4), pp 359–366.

Rainwater-Lovett, K., Pacheco, J. M., Packer, C. & Rodriguez, L. L. (2009). Detection of foot-and-mouth disease virus infected cattle using infrared thermography. *The Veterinary Journal*, 180(3), pp 317–324.

Redaelli V., Bergero D., Zucca E., Ferrucci F., Costa L. N., Crosta L., Luzi F. (2014). Use of Thermography Techniques in Equines: Principles and Applications. *Journal of Equine Veterinary Science*, 34 (3), pp. 345-350.

Ringer, S. K., Lischer, C. J. & Ueltschi, G. (2005). Assessment of scintigraphic and thermographic changes after focused extracorporeal shock wave therapy on the origin of the suspensory ligament and the fourth metatarsal bone in horses without lameness. *American journal of veterinary research*, 66(10), pp 1836–1842.

Sagi, H., Papp, S. & DiPasquale, T. (2008). The effect of suture pattern and tension on cutaneous blood flow as assessed by laser Doppler flowmetry in a pig model. *Journal of Orthopaedic Trauma*, (22), pp 171–5.

Smith, W. M. (1964). Applications of thermography in veterinary medicine. *Annals of the New York Academy of Sciences*, 121(1), pp 248–254.

Soroko, M., Henklewski, R., Filipowski, H. & Jodkowska, E. (2013). The Effectiveness of Thermographic Analysis in Equine Orthopedics. *Journal of Equine Veterinary Science*, 33(9), pp 760–762.

Steketee J. (1973) Spectral emissivity of skin and pericardium. *Physics in Medicine and Biology*. 1973; 18: 686-694.

Stewart M., Webster J.R., Verkerk G.A., Scafer A.L, Colyn J.J, Stafford K.J., (2007). Non-invasive measurement of stress in dairy cows using infrared thermography. *Physiology & Behaviour*, 92(3), pp. 520-525.

Sveriges Veterinärförbund (2009). *Antibiotikapolicy för hund- och kattsjukvård*. [http://www.sva.se/globalassets/redesign2011/pdf/antibiotika/antibiotikapolicy\\_2009.pdf](http://www.sva.se/globalassets/redesign2011/pdf/antibiotika/antibiotikapolicy_2009.pdf)

- Tan, J.-H., Ng, E. Y. K., Rajendra Acharya, U. & Chee, C. (2009). Infrared thermography on ocular surface temperature: A review. *Infrared Physics & Technology*, 52(4), pp 97–108.
- Teller, P. & White, T. The physiology of wound healing: injury through maturation. *Surg Clin North Am*, 2009(89), p 599.
- Tobias, K. M. & Johnston, S. A. (2012) *Veterinary Surgery Small Animal*. Elsevier Saunders. ISBN 978-1-4377-0746-5.
- Travain, T., Colombo, E. S., Heinzl, E., Bellucci, D., Prato Previde, E. & Valsecchi, P. (2015). Hot dogs: Thermography in the assessment of stress in dogs (*Canis familiaris*)—A pilot study. *Journal of Veterinary Behavior: Clinical Applications and Research*, 10(1), pp 17–23.
- Tunley, B. V. & Henson, F. M. D. (2004). Reliability and repeatability of thermographic examination and the normal thermographic image of the thoracolumbar region in the horse. *Equine veterinary journal*, 36(4), pp 306–312.
- Turk R., Singh A., Weese J.S (2014). Prospective Surgical Site Infection Surveillance in Dogs: Prospective Surgical Site Infection Surveillance. *Veterinary Surgery*, 44(1), pp 2-8.
- Turner, T. (2001). Diagnostic thermography. *The Veterinary Clinics of North America. Equine practice*, 2001(17), pp 95–113.
- Ueno, C., Hunt, T. & Hopf, H. (2006). Using physiology to improve surgical wound outcomes. (117), p 59S.
- Vainionpää, M. H., Raekallio, M. R., Junnila, J. J., Hielm-Björkman, A. K., Snellman, M. P. & Vainio, O. M. (2013). A comparison of thermographic imaging, physical examination and modified questionnaire as an instrument to assess painful conditions in cats. *Journal of feline medicine and surgery*, 15(2), pp 124–131.
- Vainionpää, M. & others (2014). Thermographic imaging in cats and dogs: Usability as a clinical method. [online],. Available from: <https://helda.helsinki.fi/handle/10138/45311>. [Accessed 2016-10-27].
- Vainionpää, M., Raekallio, M., Tuhkalainen, E., Hänninen, H., Alhopuro, N., Savolainen, M., Junnila, J., Hielm-Björkman, A., Snellman, M. & Vainio, O. (2012). Comparison of three thermal cameras with canine hip area thermographic images. *Journal of Veterinary Medical Science*, 74(12), pp 1539–1544.
- Vainionpää, M., Tienhaara, E.-P., Raekallio, M., Junnila, J., Snellman, M. & Vainio, O. (2012). Thermographic Imaging of the Superficial Temperature in Racing Greyhounds before and after the Race. *The Scientific World Journal*, 2012, pp 1–6.
- Van Hoogmoed, L. M. & Snyder, J. R. (2002). Use of Infrared Thermography to Detect Injections and Palmar Digital Neurectomy in Horses. *The Veterinary Journal*, 164(2), pp 129–141.

Varju, G. (2004). Assessment of hand osteoarthritis: correlation between thermographic and radiographic methods. *Rheumatology*, 43(7), pp 915–919.

Ventä, I., Hyrkäs, T., Paakkari, I. & Ylipaavalniemi, P. (2001). Thermographic imaging of postoperative inflammation modified by anti-inflammatory pretreatment. *Journal of Oral and Maxillofacial Surgery*, 59(2), pp 145–148.

Westermann, S., Stanek, C., Schramel, J. P., Ion, A. & Buchner, H. H. F. (2013). The effect of airflow on thermographically determined temperature of the distal forelimb of the horse: Effect of airflow on thermographically determined temperature. *Equine Veterinary Journal*, 45(5), pp 637–641.

Wicke, C., Halliday, B., Allen, D., Roche, N. S., Scheuenstuhl, H., Spencer, M. M., Roberts, A. B. & Hunt, T. K. (2000). Effects of steroids and retinoids on wound healing. *Archives of Surgery*, 135(11), pp 1265–1270.

Worthley, L. (2000). Shock: a review of pathophysiology and management. Part I. *Crit Care Resusc*, (2), p 55.

## APPENDIX A

### DJURÄGARBEDÖMNING DAG 5-7

#### *Temp*

För att få ett så rättvisande resultat som möjligt ska temperaturen mätas rektalt och i samband med en längre stunds vila, allra helst på morgonen när djuret precis har vaknat.

Är temperatur tagen? JA/NEJ

Om JA, hur många grader visade termometern? \_\_\_\_\_

#### *Smärta*

JA/NEJ

Om djuret är tydligt ovilligt/blir arg/visar smärta/låter om man tar i området runt såret (undvik att ta på själva såret) på ett sätt som det tidigare inte har varit när man tar på samma område.

#### *Rodnad*

JA/NEJ

Om huden vid såret är röd/rödare än resten av huden.

#### *Svullnad*

JA/NEJ

#### *Om JA*

MJUK/HÅRD

#### *Vätska från såret*

JA/NEJ

#### *Glipande sår*

JA/NEJ

#### *Om JA, hur långt?*

\_\_\_\_\_ cm

#### *Övriga kommentarer:*

---

---

---

---

---

Ni får även mer än gärna ta kort och maila till: [eagu0001@stud.slu.se](mailto:eagu0001@stud.slu.se)

Tack för ert deltagande!

## APPENDIX B

### Clinical wound healing evaluation

**Room temperature:**

**Total length of wound:**

**Infection** (after bacteriological culture) 0/2

**Pain** 0/2

(Yes= pain reaction that can clearly be related to palpation of the area, No=no reaction/reaction that cannot be directly associated with palpation of the area)

**Wound dehiscence** 0/2

**If "2"** \_\_\_\_\_%

(Measure the length of the gap and the total length of the wound and calculate percentage of total wound length)

**Redness** 1 2 3

**If "1 or 2"** \_\_\_\_\_%

(0=no redness, 1=slight redness but only directly associated to incision line and around sutureholes, 2=diffusely around incision line and sutures and possibly outside of area directly adjacent to incision)

**Swelling** 1 2 3

**If "1 or 2"** \_\_\_\_\_%

(0=no swelling, 1=Slight swelling at each side of incision line and adjacent to sutureholes with a firm consistency, 2=distinct swelling that reaches beyond the incision line and has a firm consistency)

**Seroma** 1 2 3

(0=no seroma, 1=minor seroma directly adjacent to wound edges and sutureholes with a soft/fluctuating consistency, 2=distinct seroma that reaches beyond the incision line with a fluctuating consistency)

**Suppuration** 1 2 3

(0=old dry wound liquid, 1=mostly dry wound liquid but also some fresh liquid, 2=significant amount of fresh wound liquid)

**Assessment of wound liquid** (When unclear → fine needle aspirate)

No liquid 0/1

Serous liquid 0/1

Seroanginous 0/1

Sanguinous 0/1

Purulent 0/1