

Western  Graduate&PostdoctoralStudies

Western University
Scholarship@Western

Electronic Thesis and Dissertation Repository

4-10-2017 12:00 AM

Comparing Mid Lumbar Interbody Fusion (MIDLF) with Traditional Posterior Lumbar Interbody Fusion (PLIF)

Joel T. Phillips
The University of Western Ontario

Supervisor
Dr. Chris Bailey
The University of Western Ontario Joint Supervisor
Dr. Parham Rasoulinejad
The University of Western Ontario

Graduate Program in Surgery
A thesis submitted in partial fulfillment of the requirements for the degree in Master of Science
© Joel T. Phillips 2017

Follow this and additional works at: <https://ir.lib.uwo.ca/etd>



Part of the [Orthopedics Commons](#), and the [Surgery Commons](#)

Recommended Citation

Phillips, Joel T., "Comparing Mid Lumbar Interbody Fusion (MIDLF) with Traditional Posterior Lumbar Interbody Fusion (PLIF)" (2017). *Electronic Thesis and Dissertation Repository*. 4541.
<https://ir.lib.uwo.ca/etd/4541>

This Dissertation/Thesis is brought to you for free and open access by Scholarship@Western. It has been accepted for inclusion in Electronic Thesis and Dissertation Repository by an authorized administrator of Scholarship@Western. For more information, please contact wlsadmin@uwo.ca.

Abstract

Mid-lumbar interbody fusion (MIDLF) uses a novel cortical bone trajectory (CBT) screw that provides robust cortical fixation that is less dependent on cancellous bone quality than a traditional pedicle screw. MIDLF also allows for decompression and instrumentation through a smaller central surgical window. The aim of this study is to compare MIDLF with posterior lumbar interbody fusion (PLIF) with regards to perioperative complications, operative time, blood loss, length in hospital, radiographic outcomes and post-operative patient functional status. A retrospective review of our institutional database was performed of patients undergoing MIDLF. Matched PLIF controls were then selected from the same database for comparison. 20 MIDLF patients were identified as were 20 matched PLIF controls. Primary outcomes included perioperative clinical and radiographic measures as well as postoperative patient self-reported function. Results demonstrated no significant differences between the two groups with respect to all clinical, radiographic and patient self-reported measures.

Keywords: MIDLF, CBT, PLIF, blood loss, operative time, complications, radiographic outcomes, function.

Co-Authorship Statement

Chapter 1. Joel Phillips –sole author

Chapter 2. Joel Phillips,

Chapter 3. Joel Phillips. Jennifer Urquhart

Acknowledgments

I am incredibly grateful to my supervisor Dr. Chris Bailey. Working with you on this Masters thesis was incredibly fulfilling. You were an invaluable advisor and teacher to me both on this masters thesis as well as during my surgical training as a resident and clinical fellow. You played a huge role in my surgical training as an orthopaedic surgeon as well as in stimulating my interest in becoming an orthopaedic spine surgeon. I also count myself fortunate to have gotten to know you as an individual and to count you both as friends and colleagues. Chris, your infectious enthusiasm for your work and kindness made coming to work everyday a joy. I also had the privilege of training under Dr Parham Rasoulinejad as well as Dr. Kevin Gurr and Dr. Fawaz Siddiqi. Parham, your humility, kindness and humor while training alongside you as a resident and under you as a fellow left many lasting memories. Fawaz your sense of humor as well as your approach to spine surgery made each day enjoyable and taught me a lot. Kevin, you have such a wealth of knowledge and skill both inside and outside the OR. You became not only an important surgical mentor but also a role model for me.. I have appreciated the mentorship and friendship each of you has provided. I share the same sentiments for all of you. I couldn't be prouder to call each of you mentors and friends. It has been a rarity in my life to find individuals who I equally respect as both professionals and as individuals. I mean this with the utmost sincerity. I hope I represent all of you well in my future endeavors.

Table of Contents

Abstract	ii
Co-Authorship Statement	iii
Acknowledgments (if any).....	iv
Table of Contents	v-vi
List of Tables (where applicable)	vi-xiii
List of Figures	xiv
Chapter 1	1
1 Introduction to the Spine	1
1.1 The Spine	1-4
1.2 Spinal Stenosis	4-8
1.2a Pathophysiology	4-5
1.2 b Epidemiology	5
1.2c Presentation	6-7
1.2d Natural Course	7-8
1.3 Spine Biomechanics	8-9
1.4 Spine Stabilization	9-12
1.4a General Principles	9-12
1.4b Cortical Bone Trajectory Screw	12
1.4c Spine Fusion Techniques	12
1.4d Posterior Lumbar Interbody Fusion	13-15
1.4e Open Transforaminal Interbody Fusion	16

1.4f Minimally Invasive Spine Surgery / Minimally Invasive Transforaminal	
Interbody Fusion	17-18
1.4g MIDLF Technique	18-22
1.5 MIDLF Trials	23-24
1.6 Thesis Rationale	24
1.7 Objectives and Hypothesis	24
Chapter 2.....	54
2Materials and Methods	54
Chapter 3.....	27-5429
3Results	54
54Chapter 4	5429-30
4Discussion	54
Chapter 5.....	30-31
5Conclusions	54
5.1 « First level subheading uses style Heading 2 »	54
References or Bibliography (if any)	54
Appendices (if any).....	54
Curriculum Vitae	54

List of Tables

Table 1: Demographic Data and Functional Score

Parameter	Case (n=15)	Control (n=15)	P-value
Age, mean \pm SD, years	62.6 \pm 12.2	60.8 \pm 12.3	0.147
BMI, mean \pm SD, kg/m ²	30.4 \pm 5.9	32.2 \pm 6.7	0.035
Gender, Male, n (%)	3 (20.0)	3 (20.0)	1.00
Anatomic Level, n (%)			
L3-4	1 (6.7)	1 (6.7)	1.00
L4-5	14 (93.3)	11 (73.3)	0.371
L5-S1	0 (0)	3 (20.0)	0.248
‡Anatomic Diagnosis, n (%)			
Lateral recess stenosis	14 (93.3)	12 (80.0)	0.617
Spondylolisthesis	11 (73.3)	13 (86.7)	0.683
Foraminal stenosis	8 (53.3)	10 (66.7)	0.724
Degenerative scoliosis	0 (0)	1 (6.7)	1.00
Disc Hernation	5 (33.3)	8 (53.3)	0.450
‡Clinical Diagnosis, n (%)			
Back pain	11 (73.3)	14 (93.3)	0.371
Claudication	9 (60.0)	12 (80.0)	0.371
Radiculopathy	5 (33.3)	7 (46.7)	0.724

Cauda equina syndrome	1 (6.7)	1 (6.7)	1.00
Weakness	1 (6.7)	0 (0)	1.00
Previous Lumbar Surgery, n (%)	3 (20.0)	1 (6.7)	0.617
Oswestry Disability Index, mean \pm SD	49.7 \pm 12.8	43.9 \pm 9.6	0.077
Intensity of leg pain, mean \pm SD	8.5 \pm 1.3	7.9 \pm 1.2	0.279
Intensity of back pain, mean \pm SD	8.31 \pm 1.2	7.8 \pm 1.4	0.275
SF12 PCS, mean \pm SD	28 \pm 7.1	32.1 \pm 6.9	0.080
SF12 MCS, mean \pm SD	47.7 \pm 7.3	50.1 \pm 6.8	0.402

A patient could have more than one anatomic diagnosis or clinical diagnosis

Table 2: Operative characteristics

Parameter	Case (n=15)	Control (n=15)	P-value
Surgical Duration, mean \pm SD, min	197.1 \pm 33.9	208.2 \pm 42.4	0.389
Change in hemoglobin, mean \pm SD,	-34.5 \pm 9.0	-28.5 \pm 9.3	0.075
Length of stay, mean (range), days	3.87 (2 – 9)	3.67 (3 – 9)	0.731
Reduction of listhesis, n (%)			0.607
None	9 (40.0)	3 (25.0)	

Less than a grade	4 (26.7)	5 (41.7)	
One grade	2 (13.3)	3 (25.0)	
Two cages per level, n (%)	10 (66.7)	11 (73.3)	1.00
Screw Loosening, n (%)	0 (0)	1 (6.7)	1.00
Revision surgery, n (%)	1 (6.7)	3 (20.0)	0.480
Intraoperative complication			
Dural tear, n (%)	2 (13.3)	0 (0)	0.480
‡Indication for revision surgery, n (%)			
Adjacent level stenosis	1 (6.7)	1 (6.7)	1.00
Non-adjacent disease	0 (0)	1 (6.7)	1.00
Hardware failure/malposition	1 (6.7)	1 (6.7)	1.00
Infection	0 (0)	1 (6.7)	1.00
Post-operative complaints, n (%)			0.699
None	4 (26.7)	7 (46.7)	
Radiculopathy	4 (26.7)	3 (20.0)	
Back pain	5 (33.3)	3 (20.0)	
Motor weakness	1 (6.7)	1 (6.7)	

‡, A patient could have more than one indication for revision surgery

Length of follow-up P=0.344 case 363.3 (2-779) days, control 461 (53 – 1121) days

No cases or controls had PRBC

Preoperative hemoglobin, mean \pm SD, case 137.2 \pm 10.0, control 137.1 \pm 10.3, 0.966;

Postoperative hemoglobin, mean \pm SD, 101.8 \pm 14.0, 108.2 \pm 11.6, 0.082

Table 3: Radiographic measures

Parameter	Cases (n=15)	Control (n=15)	P-value
Cage subsidence, mean \pm SD, mm	2.9 \pm 4.6	2.7 \pm 1.6	0.917
Preoperative segmental lordosis (across diseased levels), mean \pm SD, $^{\circ}$	35.6 \pm 8.8	30.0 \pm 10.5	0.136
Postoperative segmental lordosis (across diseased levels), mean \pm SD, $^{\circ}$	37.5 \pm 6.5	32.6 \pm 9.2	0.083
Change in segmental lordosis, mean \pm SD, $^{\circ}$	3.08 \pm 4.01	2.67 \pm 7.38	0.858
Preoperative lumbar lordosis, mean \pm SD, $^{\circ}$	52.6 \pm 13.3	53.2 \pm 12.0	0.926
Postoperative lumbar lordosis, mean \pm SD, $^{\circ}$	57.4 \pm 12.6	56.9 \pm 9.2	0.913
Change in lumbar lordosis, mean \pm SD, $^{\circ}$	5.08 \pm 8.28	5.25 \pm 7.12	0.953

Table 4: Outcome measures

Parameter	Case	Control	P-value
3 months after surgery n=11 per cohort			
Oswestry Disability Index, mean \pm SD	29.4 \pm 17.1	26.4 \pm 15.3	0.548
Intensity of leg pain, mean \pm SD	2.3 \pm 3.1	2.3 \pm 3.0	1.00
Intensity of back pain, mean \pm SD	2.2 \pm 2.2	3.1 \pm 2.5	0.407
SF12 PCS, mean \pm SD	41.9 \pm 9.9	43.0 \pm 6.9	0.780
SF12 MCS, mean \pm SD	52.8 \pm 5.4	54.0 \pm 6.4	0.700
Change in scores from baseline to 3 months n=11			
Oswestry Disability Index, mean \pm SD	-18.5 \pm 15.0	-17.7 \pm 11.2	0.257
Intensity of leg pain, mean \pm SD	-7.0 \pm 3.3	-5.9 \pm 3.3	0.464
Intensity of back pain, mean \pm SD	-6.4 \pm 2.7	-5.2 \pm 2.3	0.833
SF12 PCS, mean \pm SD	15.8 \pm 9.8	9.6 \pm 6.1	0.173
SF12 MCS, mean \pm SD	7.8 \pm 8.9	6.1 \pm 7.7	0.711

Table 5: Presence of a good improvement in pain and disability as measured by a $\geq 30\%$ improvement in ODI score at 3 months after surgery

	$\geq 30\%$ improvement in ODI score at 3 months in Control Subjects	
	Yes	No
$\geq 30\%$ improvement in ODI score at 3 months in Case Subjects		
Yes	2	2
No	2	7

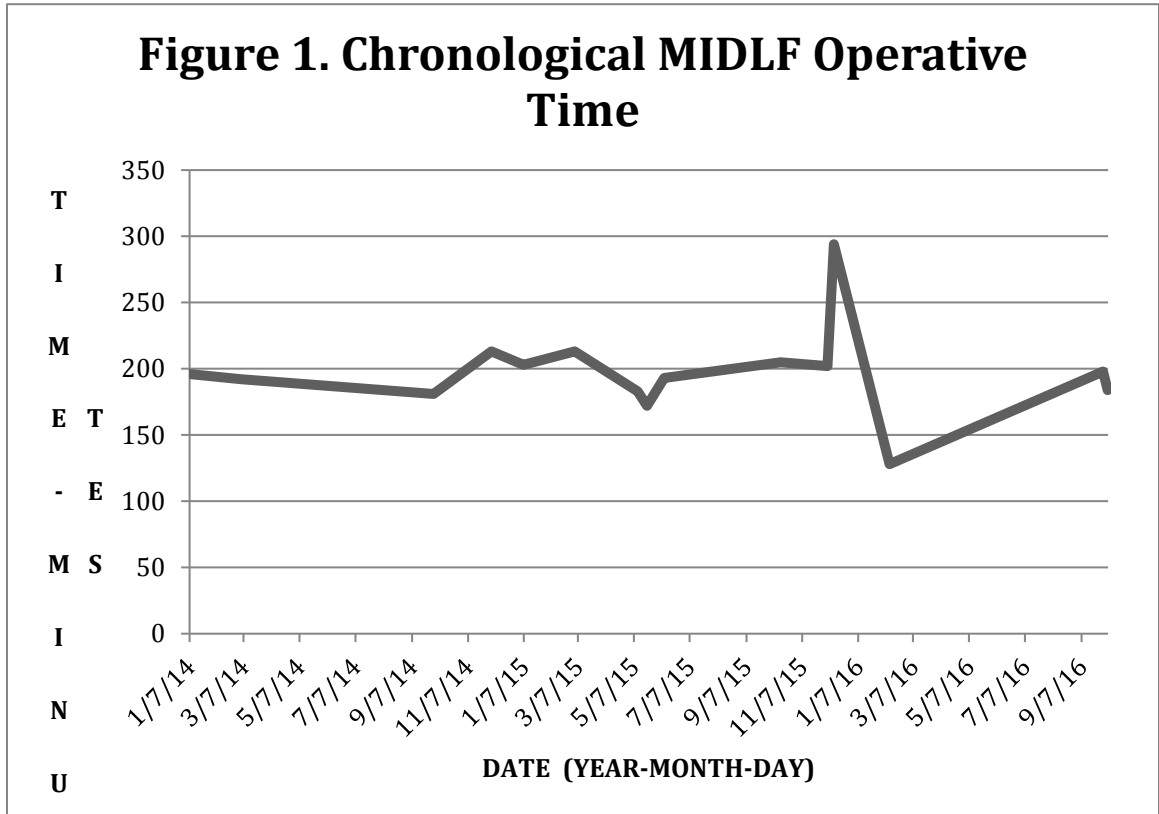
OR = 1.00; 95% CI (0.141, 7.099), P=1.00 by conditional logistic regression analysis.

If a conditional logistic regression model is run with BMI, surgical duration, and previous surgery as covariates improvement in ODI is still not significant P=0.543, OR 2.224, 95% CI (0.166, 29.856).

Table 6: Conditional logistic regression for change in outcome measures from baseline to 3 months

Parameter	β	OR	95% CI	P-value
ODI	-0.10 \pm 0.045	0.990	0.906, 1.081	0.823
IBP	-0.208 \pm 0.188	0.812	0.561, 1.175	0.269
ILP	-0.097 \pm 0.129	0.907	0.704, 1.169	0.452
PCS	0.101 \pm 0.081	1.106	0.903, 1.061	0.604
MCS	0.026 \pm 0.063	1.026	0.906, 1.162	0.685
Adjusted analysis for BMI, surgical duration, previous surgery, and any AE				
ODI	0.002 \pm 0.069	1.002	0.875, 1.147	0.979
IBP	-0.083 \pm 0.189	0.921	0.635, 1.334	0.662
ILP	-0.110 \pm 0.2	0.896	0.606, 1.325	0.583
PCS	0.089 \pm 0.183	1.039	0.764, 2.433	0.628
MCS	-0.413 \pm 0.478	0.662	0.259, 1.564	0.388

List of Figures



Chapter 1: Introduction to the Spine

OVERVIEW: This chapter outlines basic spine anatomy and rudimentary knowledge related to spine surgery and surgical implant use particularly regarding interbody fusion. Relevant anatomy, surgical techniques and use of spinal instrumentation is reviewed.

1.1 The Spine

The human spine is a complex osseoligamentous structure that serves as an attachment point for the cranium and limbs, provides support to the thorax allowing for upright posture, allows for rotational and bending movements to place the body in space, and protection of the neural elements. It is typically composed of 33 or 34 vertebrae: 7 cervical, 12 thoracic, 5 lumbar, 5 sacral and 4 or 5 coccygeal. Connecting these individual elements are 97 synovial joints (diarthroses) that allow for the aforementioned complex motions of the human spine. Amphiarthroses (fibrocartilagenous joints) are even more abundant; albeit their role in motion is less significant.

Each vertebrae with the exception of the atlas is comprised of three essential elements: a cylindrical vertebral body, a posterior vertebral arch and two horizontal pillars of bone (pedicles) linking the anterior vertebral body and posterior vertebral arch. The former and latter can be further broken down into subcomponents. The vertebral body can be divided into an anterior and posterior component comprising the anterior and middle column in Denis' 3 column model (Denis) that was originally designed for the lumbar spine. The posterior vertebral arch makes up the posterior column and consists of the paired superior facets and inferior facets, laminae and transverse processes. The singular spinous process serves as a central anchor point for these paired posterior structures via the laminae. Each superior articular facet projects dorsally and articulates with its corresponding ventrally oriented inferior articular facet. Together, these paired elements form the two facet joints (zygapophyseal joints) at each level of the spine and plays a role in the movement and

stability of the spine. Connecting the superior and inferior articular facets is an anatomic structure known as the pars interarticularis. It arises from the junction of the spinous process and the lamina. This column of bone is crucial to the translational and rotational osseous stability of the spine as it serves as a link between the facets at adjacent levels of the spine. Disruption of the one or both pars (spondylolysis) is a well-documented phenomenon that leads to uncoupling of the posterior elements of two adjacent levels and creates a scenario that can lead to rotation and translation or pure translation of the cranial vertebrae relative to the caudal vertebrae respectively (spondylolisthesis). Certainly, more detailed anatomical structures and regional landmarks exist at both the cervical and thoracic regions of the spine; this is not the focus of the current study as it deals with the lumbar region only.

The lumbar spine has several unique osseous anatomical features that are worth mentioning for the current study. As previously stated it typically consists of 5 vertebrae. The sagittal profile of a normal lumbar human adult spine is lordosis of 20-60 degrees. Lumbar vertebrae are large compared to their cervical and thoracic counterparts. Spatially they have a greater width than anteroposterior (AP) diameter. Their large pedicles are located on the superoposterolateral aspect of the vertebral body. The intervertebral foramen are large and trefoil shaped with the paired nerve roots exiting below the pedicle of their corresponding vertebrae. Transverse processes are broad flat structures emanating from the vertebral body at the level of the inferior aspect of the superior articular facet. The mammillary processes are ridges of bone on the posteroinferior aspect of the superior facet that is analogous to the true transverse process of the thoracic spine as it serves as an attachment point of the deep paraspinal musculature. Along with the central aspect of the transverse process and the lateral margin of the corresponding superior articular facet, the mammillary process is a critical landmark for traditional lumbar pedicle screw insertion. The start-point for these screws is formed by the intersection of the three lines formed by these structures. Lumbar facet joints are relatively sagittally oriented; allowing for a flexion-extension moment.

Equally important as the bony elements of the spine is the discoligamentous complex. As with the description of the bony elements, the following description will remain a general overview with further details being elaborated in the surgical techniques section. Coursing along the anterior aspect of the vertebral bodies is the anterior longitudinal ligament (ALL). It provides tensile strength to the spinal column and acts as a tether against hyperextension. It consists of superficial, intermediate and deep components. The deep layer spans only a single level while the intermediate and superficial layers span 2-3 or 4-5 levels respectively. The ALL's most robust attachment point lies at the most cranial and caudal ends of the vertebrae anteriorly, with weaker attachments centrally. The posterior longitudinal ligament (PLL) courses along the posterior aspect of the vertebral bodies and serves as a tether against hyperflexion. It consists of a deep and superficial layer. In the lower thoracic and lumbar spine, this thick structure is under considerable tension, attaching only to the cranial and caudal aspects of the vertebrae. In the coronal plane the PLL is most firmly attached to the posterolateral aspect of each vertebrae. This is especially pertinent in understanding disc herniation and is why paracentral herniations are far more common than central herniations. The ligamentum flavum attaches on the ventral surface of the caudal two-thirds of the cranial lamina and the dorsal surface of the cranial one-third of the caudal lamina. It runs from the second cervical vertebrae to the first sacral vertebrae. In the coronal plane it runs from the medial aspect of one facet joint to near-midline on each side with a small deficiency centrally. It is another important stabilizer resisting hyperflexion. It is also a critical anatomical component in the development and surgical treatment of spinal stenosis. The intertransverse ligament is a fibrous connection between the transverse processes of adjacent levels that provides little mechanical support. Joining the spinous processes of adjacent levels are two sets of ligaments; the interspinous and supraspinous ligaments. The interspinous ligaments are paired with a common confluence medially and join the caudal aspect of one spinous process with the cranial aspect of the next most caudal spinous process. The supraspinous ligament runs as a continuous structure from C7 to the

central sacral crest. In addition to these ligamentous structures, the facet joint capsules provide significant stability with their disruption leading to potential instability.

With the exception of the atlantoaxial articulation; intervertebral discs lie between the individual vertebrae of the cervical, thoracic and lumbar spine. These discs and their corresponding vertebral bodies form articulations that are unique to any other joint in the body. The intervertebral disc consists of a softer inner portion, the nucleus pulposus and a more fibrous structural outer layer, the annulus fibrosis. The inner nucleus consists largely of water and hydrophilic proteoglycans. It is a viscoelastic structure that aids in dissipation of forces in the spine: especially compressive forces. The outer annulus combines circumferential and radial fibres that act as a containment structure for the nucleus and strongly links adjacent vertebrae as well as dissipate torsional and tensile forces in the spine. Rather than discrete anatomical structures separated by a clear margin, the nucleus and the annulus rather gradually transition into each other. Discs in the lumbar spine have a wedge profile with an increased anterior height that contributes to normal lordotic posture. Disc abnormalities contribute to a variety of pathology including acute neural element compromise from an acute disc herniation to spinal stenosis and the accompanying neurogenic claudication.

1.2 Spinal Stenosis

1.2a Pathophysiology

Pathology in the spine consists of congenital or acquired causes that encompass oncological, metabolic, infectious, traumatic, degenerative and deformity. For the purposes of this thesis we will focus on degenerative pathology with or without accompanying deformity. The pathway of degenerative changes in the spine has been well described even if the exact mechanism is unclear. It involves a complex interplay of genetic, biochemical, and biomechanical factors. The initiating event involves changes

within the disc in the form of an acute annular tear or more commonly changes in disc composition that lead to structural alterations of the disc and subsequently the entire spinal unit. These alterations involve decreased proteoglycan concentrations and subsequently water content that is vital for normal disc function. Approximately 80% of the healthy young adult nucleus pulposus and 65% of the annulus are composed of water [1].

As one ages proteoglycan and water content decrease leading to changes in disc composition, disc height and disc biomechanics. As the disc loses height more stress is transferred to the surrounding osseoligamentous structures. These include the facets and ligamentum flavum. In response to increased loads these structures may hypertrophy and facet joints may form cysts. This is the pathoanatomy leading to lumbar spinal stenosis that can cause symptomatic neurogenic claudication. Also as disc desiccation occurs one can develop instability and deformity of the spinal unit in the form of degenerative scoliosis and degenerative spondylolisthesis. These processes also cause stenosis or narrowing of the spinal canal leading to narrowing of the canal at the lateral recess or at the neuroforamen. This narrowing may be further exacerbated by an accompanying disc herniation that further decreases the available space for the neural elements. If severe enough, this stenosis can result in symptomatic disease.

1.2b Epidemiology

Relative and absolute spinal stenosis has a prevalence of 4.71% and 2.62% in the general population [2]. In individuals age 60-69 this number increases to 47.2% and 19.4% respectively. Spinal stenosis is a leading cause of disability in the elderly [2]. It has been demonstrated to impart functional limitations greater or equal to that seen in congestive heart failure (CHF), chronic obstructive pulmonary disease (COPD), renal failure, rheumatoid arthritis, lupus as well as hip and knee osteoarthritis. Spinal stenosis is the most common reason for spinal surgery in patients 65 years of age and older [3].

Operative treatment of lumbar spinal stenosis has been shown to provide similar improvement in health-related quality of life when compared to total knee arthroplasty [4]. Thus surgical treatment of spinal stenosis should be of great interest to both patient and surgeon as it confers significant ability to restore function.

1.2c Presentation

Patients with lumbar spinal stenosis and/or spondylolisthesis typically present with any number of a constellation of typical symptoms. These symptoms can be broadly divided into mechanical back pain and neurological symptoms. Patients often describe back pain that worsens with sitting, standing and extension of the lumbar spine. Typical neurological complaints include burning, cramping, numbness or fatiguing of the thighs, legs and feet with standing or walking. These symptoms may be improved with sitting or with forward flexion of the lumbar spine (pushing a shopping cart or walker). These symptoms need to be differentiated from vascular claudication via history, physical or if necessary Doppler flow studies of the lower extremities. On history neurogenic claudication is more likely if the patient describes lower extremity numbness, leg symptoms with standing alone that does not subside until they are seated and location in the buttock and thigh regions [5]. Less reliable differentiating historical features include leg pain with walking uphill compared to downhill and a longer rest period before cessation of leg symptoms compared to vascular claudication. On exam peripheral pulses and skin examination may help rule out peripheral vascular disease. If still unsure Doppler flow studies of the lower extremities can rule out vascular claudication. Other potential differential diagnoses that must be ruled out are cervical/thoracic stenosis/myelopathy, peripheral neuropathy, hip pathology and lumbar disc herniation. Patients with myelopathy will often have a history of gait imbalance or fine motor incoordination as well as upper motor neuron findings on exam. Patients with peripheral neuropathy may have a history of risk factors for developing a peripheral neuropathy (Diabetes, alcoholism, B12/ folate deficiency) as well as altered sensation in a non-dermatomal

distribution. Electromyography (EMG) may be used to diagnose suspected peripheral neuropathy. A thorough history and examination of the hip are essential as well. Patients with lumbar disc herniation are typically younger, have worsening pain with flexion, and often will have a positive straight-leg-raise (SLR) in addition to disc herniation on MRI.

In addition to neurogenic claudication spinal stenosis patients may also have radiculopathy. Symptoms of cauda equina syndrome while rare should always be ruled out on history. Differentiation and quantification of back versus leg dominant symptoms is crucial in effective treatment of spinal stenosis. Leg symptoms are known to respond far more reliably to surgical intervention when compared with back symptoms. Thus patients with back-dominant pain are typically managed via non-operative modalities focusing on smoking cessation, weight loss, physiotherapy and NSAIDS as well as potential facet injections. Patients with leg dominant symptoms are typically tried on a similar course of non-operative treatment. Additional non-operative medications include anticonvulsants and antidepressants that target pain secondary to neural compression. Epidurals and/or root blocks also take the place of facet injections. If leg dominant patients (with documented stenosis on MRI) fail to improve with a trial of non-operative treatment then surgical intervention may be indicated. Surgical intervention can be broadly divided into isolated decompression and decompression and fusion.

1.2d Natural course/ Management

While spinal stenosis is a degenerative condition, this does not mean that symptomatic disease will continue to worsen. The North American spine society (NASS) indicate that one third of patients with mild to moderate stenosis will improve with time [6]. Other studies have demonstrated that a rule of thirds at 8 year follow-up: that is one third improve, one third remains unchanged and the last third worsens [7][8][9]. Treatment options were outlined in the preceding section.

Surgical treatment via lumbar decompression and fusion will be expanded upon in the coming sections and will be the focus of this thesis. Surgery is indicated in a medically fit patient with documented stenosis and significant neural element compression on CT or MRI who has undergone an adequate trial of non-operative treatment and whose claudicant and/or radicular leg symptoms continue to interfere significantly with their quality of life. Considerations in differentiating between surgical decompression alone or surgical decompression with a fusion include: structural integrity of each level, sagittal and coronal alignment/ deformity and alterations of structural integrity with completion of the decompression [10]. In their landmark study examining surgical versus nonoperative treatment of lumbar spinal stenosis; Lurie et al demonstrated that surgically treated patients experienced significantly greater improvement in pain, function, satisfaction and self-rated progress at 8 years post-surgery when compared to their nonoperatively managed controls [11]. Success rates for significant improvement of neurological complaints is 75%-90% [12]–[17]. Thus understanding and differentiating between the various surgical treatment options is of the utmost importance given the potential benefits they afford to the patient with symptomatic lumbar spinal stenosis.

1.3 Spine Biomechanics

In addition to the spine providing protection of the neural elements, it also enables transmission of complex forces as well as facilitates complex multi-directional movement. Understanding these complex roles requires a basic knowledge of the biomechanical building blocks of the spine. As previously discussed the spine is typically composed of 33 vertebrae with 5 lumbar vertebrae. Similarly, from a biomechanical perspective, the spine is composed of repeating single motion segments that together allow for complex load dissipation and movement. These single biomechanical/ motion segments are referred to as a functional spine unit (FSU). This is comprised of two adjacent vertebrae, their intervening disc, the paired facet joints as well as the associated musculo-ligamentous structures.

In the lumbar spine, flexion-extension and its corresponding compressive and distractive forces are of utmost importance as these movements and forces are regularly encountered to reposition the trunk in space for regular locomotion. Thus in the setting of an instrumented spine; these are the motions and loads that the instrumentation is resisting and could potentially be the cause of failure. During extension of the native spine, 60-70% of the load is borne by the neural arch [18], [19]. Damage occurs when the extension of the FSU reaches 5-9 degrees in the upper lumbar spine and 10-16 degrees in the lower lumbar spine [18], [19]. The disc can fail at 18 degrees of flexion with a load of 15-50 N-m [20].

Spine biomechanics encompasses 4 specific areas: injury mechanism characterization, loading of the spine, displacement of the spine, and evaluation of various spinal instrumentation [21]. Displacement of the spine is comprised of 6 components as are the corresponding forces. This can be represented via a coordinate system. Most motions are coupled; consisting of a combination of displacement and rotation. Punjabi et al were able to separate sagittal motion from lateral bend, simplifying the study of the spine [22]. Flexion and extension are the primary motions of the lumbar spine that allow placing of the trunk in space for activities of daily living. This motion is comprised of three movements: sagittal rotation, axial translation and anterior-posterior translation. Lateral bending of the lumbar spine is comprised of lateral bending, lateral translation and axial rotation. The other primary modes of motion of the lumbar spine as outlined by Punjabi et al include axial translation and axial torsion [22]. The corresponding loads include compressive, distractive, rotational and translational (shear) forces along the six coordinates.

In the instrumented spine; the hardware must resist the motion and forces that are seen in the native spine in order to provide an environment that facilitates fusion of the FSU. Commonly this involves placement of one or two interbody devices in concert with pedicle screw-rod fixation. Various techniques have been adopted for placement of the interbody devices and segmental fixation under the umbrella of minimally invasive

surgery (MIS). Mid-lumbar interbody fusion (MIDLF) is one such technique. It employs the use of interbody devices in concert with the novel cortical bone trajectory (CBT) screw segmental fixation.

1.4 Spine Stabilization

1.4a. General Principles

Broadly speaking, spine surgery can be divided into 4 broad goals: decompression, realignment, stabilization, and fusion. While different modes of fixation exist; the pedicle screw is by far the most utilized method of fixation in the spine surgeons armamentarium [23]. The logic in selecting the pedicle as a point of fixation in the spine includes anatomic and biomechanical factors [24]. In addition to being large enough to accommodate a screw, the pedicle provides secure fixation within the body of the vertebrae giving the surgeon control in all planes of motion through a traditional posterior approach [25][26]. Numerous biomechanical studies have demonstrated the secure biomechanical fixation of the pedicle screw [24][27][28][29][30][22]. The screws are placed in the pedicles in a dorsal to ventral fashion both above and below the level of interest. These screws are then joined via a titanium, cobalt chrome or stainless steel rod to provide a rigid construct that will provide a favourable environment for fusion to occur. Pedicle Screw fixation was first conceptualized by Boucher [31][32] as an evolution of King's facet screw fixation. While Boucher is cited as the father of pedicle screw fixation: modern pedicle screw fixation was first described by Harrington and Tullose in 1969 as a solution to childhood isthmic spondylolisthesis [33]. This was then popularized by Roy-Camille, who in 1970 described the use of posterior plates combined with sagittally-placed screws through the pedicle as a means of lumbar spine fixation [26][25][34][25][35]. This formed the basis for modern pedicle screw constructs. His idea was further developed by Steffee, whose modification allowed for variable screw placement that could accommodate variations in patient anatomy [36]. Pedicle screw

fixation has been a boon for the spine surgeon allowing for short, rigid segmental immobilization of the spine in the absence of posterior elements that was not possible with previous techniques [24].

Pedicle screw design and material properties have continued to develop with the advent of ‘tulip-rod-cap’ constructs, poly-axial screws, high-fidelity manufacturing techniques, the use of titanium alloys, and specialized instrumentation and screws. A modern pedicle screw consists of an outer threaded shaft with an inner core as well as a head or ‘tulip’ and a screw tip. The outer threaded shaft or ‘major diameter’ is vital in achieving interdigitation with the host bone and resisting screw pullout. Two key elements of the outer shaft are thread pitch and thread depth. Thread pitch refers to the distance between adjacent threads on the screw shaft. Coarser thread designs achieve fixation within less-dense cancellous bone whereas finer thread pitch designs provide fixation within dense cortical bone. The inner diameter or ‘minor diameter’ is directly related to thread depth as a larger core leads to a decreased thread depth at the advantage of increased screw stiffness whereas a smaller minor diameter leads to increased thread depth allowing potentially increased pullout strength at the expense of decreased screw stiffness. The screw lead is the distance the screw travels with one rotation. A dual-lead screw will travel twice the distance as a single-lead screw of the equivalent pitch. The screw head or ‘tulip’ has undergone significant evolution from its earliest iterations and is available in several variations depending on the desired application. The tulip serves several key purposes in posterior pedicle-screw rod constructs. It acts as an interface between the screw and the rod, linking two adjacent levels together and providing immobilization across that level, typically with the goal of achieving fusion. Tulip designs offer motion or rigidity in different planes of motion. Uniaxial or monoaxial screws, while more difficult to dock the rod given their single plane of motion, allow for correction of rotation through the shaft of the screw and hence the spine itself. This is especially useful in the setting of rotational deformity correction seen in scoliosis. Polyaxial screws allow the tulip to rotate independently of the shaft through multiple planes of motion which

allows for much easier placement of the rod within the tulips but poorer spinal realignment ability.

Indications for lumbar pedicle screw fixation are broad and include spondylolisthesis reduction, fusion of degenerative spondylolisthesis, lumbar scoliosis decompression and stabilization, posterolateral fusion, multi-level wide posterior decompressions, posterior stabilization of painful degenerative discs, instability in the setting of lumbosacral trauma or tumor and stabilization after osteotomy [37]. Contraindications include inadequate pedicle size, severe osteopenia, pedicle fracture and metal allergy [37]. Lumbar pedicle screw fixation involves identification of the start-point. This can be done via either a midline posterior approach, a Wiltse approach (paramedian) or via a percutaneous technique. Key landmarks for pedicle insertion include a line along the central longitudinal axis of the transverse process (TP), the mammillary process and the lateral aspect of the superior articular facet. The junction of these three landmarks marks the insertion point for the lumbar pedicle screw. Lumbar pedicles increase in diameter from approximately 7mm in the thoracic spine to 15mm at L5. Medialization of the pedicle screw trajectory increases from around 0 degrees at L1 to 30 degrees at L5.

Cephalocaudal orientation must consider individual patients lordosis. It changes from slight cephalad orientation at L1 to relatively neutral at L3, to increasingly caudal distal to L3. An awl or 4.0 mm burr is often used to create a startpoint. Traditionally, a pedicle finder is then slowly oscillated back and forth via manual-power to a depth of approximately 45-50 mm. A ball-tipped probe is the used to feel the floor, medial wall, lateral wall, cranial wall and caudal wall to ensure that the anterior vertebral body cortex/ pedicle walls have not been violated; preventing injury to the cauda equina, nerve roots as well as vascular and visceral structures.

1.4b. Cortical Bone Trajectory Screw

While pedicle screw (PS) fixation has been a crucial development in spinal fixation; it is not without its inherent limitations. These limitations include significant soft tissue dissection/ retraction, significant exposure time, technically challenging in the obese patient, increased deadspace creation, altered startpoint anatomy in degenerative disease, and potentially compromised fixation in osteoporotic bone. The cortical bone trajectory screw potentially alleviates these shortcomings. In their retrospective study, Kasukawa examined patients undergoing TLIF for Myerding grade 1 or 2 spondylolisthesis or intraforaminal to lateral disc herniation (A13) [38]. TLIF/CBT, TLIF with minimally invasive pedicle screw insertion (M-TLIF) and TLIF with percutaneous pedicle screw insertion were compared with respect to duration of surgery, estimated blood loss (EBL), intraoperative complications, level of fusion and postoperative radiographic evaluation. TLIF/CBT displayed decreased blood loss and shorter operative duration when compared with the other two groups. Other measured variables were similar between the groups. Thus if instrumented fusion using a CBT screw demonstrates biomechanical non-inferiority when compared to traditional pedicle screw fixation it provides an attractive option to the modern spine surgeon.

1.4c. Spine Fusion techniques

The first description of interbody fusion was the insertion of autograft spinous process within the disc space performed by Cloward in 1940 [39]. The goal of this procedure combined with pedicle screw insertion is to achieve a solid circumferential fusion mass connecting the cranial and caudal vertebrae all through a standard midline posterior incision. With the passage of time, a host of various interbody graft/implant options have been attempted. These include autologous iliac crest, autologous fibula, allograft bone, calcium carbonate/phosphate, cancellous bone chips, metallic implants, carbon fiber implants, polyetheretherketone (PEEK) and threaded cages. Advantages compared with traditional posterolateral fusion (PLF) include a larger surface area of bone to bone contact, improved vascularity to the graft from the cancellous vertebral body and

increased load-sharing of the graft [40]. Fusion rates have been demonstrated to be significantly higher with interbody fusion compared with posterolateral fusion .

With time there also have been numerous modifications to the approach utilized for insertion of the interbody device. The most longstanding approach is the PLIF that still serves as a reliable workhorse approach for many surgeons. Over the years there have been the development of various approaches including anterior lumbar interbody fusion (ALIF), transforaminal interbody fusion (TLIF), direct lumbar interbody fusion (DLIF), extreme lateral interbody fusion (XLIF), oblique lumbar interbody fusion (OLIF) and mid-lumbar interbody fusion (MIDLIF). Given that DLIF, XLIF, OLIF and ALIF are more commonly indicated to address deformity rather than symptomatic spinal stenosis; they will not be a focus of discussion. Rather the focus of this study will be to compare and contrast the various methods of interbody fusion via a posterior approach, using either traditional open techniques or minimally invasive surgical (MIS) techniques.

1.4d PLIF

PLIF is the classically described method for achieving an interbody fusion in the lumbar spine. Indications for PLIF include disc herniation, degenerative disc disease, pseudoarthroses, spondylolistheses and symptomatic spinal stenosis [41]. Cited contraindications include extensive epidural scarring, arachnoiditis, active infection, conjoined or low-lying nerve roots as well as pathologic bone unable to support an interbody device[41]. PLIF involves a midline dorsal incision in a prone patient with a standard bilateral posterior approach. First described by Cloward in 1953, it involved placement of an interlaminar spreader in the interspinous space after removal of the supraspinous ligament and interspinous ligament [39]. Removal of the caudal third of the inferior articular facet and the medial two-thirds of the superior articular facet combined with undercutting of the lamina, affords the surgeon access to the disc space. The traversing nerve root and the dura are then retracted medially and epidural vessels and fat

are coagulated. A posterior annulotomy is made in the disc and the disc and cartilaginous endplate is removed. A small amount of cortical bone was then removed from each endplate and a full-thickness appropriately-sized cancellous iliac crest graft was placed in the disc space.

Alterations in the technique for present-day treatment of lumbar spinal stenosis include abandoning the placing an interlaminar spreader in the interspinous space. Instead access is gained through removal of at least the caudal two thirds of the lamina with or without the spinous process. If bilateral cages are to be placed, most surgeons will sacrifice the spinous process along with performing bilateral laminectomies/ laminotomies. Inferior articular facets are then osteotomized using osteotomes, leksell and kerrison rongeurs, a high-speed drill or a combination of the above. All of the hypertrophied ligamentum flavum is removed along with a portion of the superior articular facet. Once again the surgeon retracts the thecal sac medially and then gains access to the disc space.

Preparation of the disc space has evolved using various modern preparatory instruments of the surgeons choosing. Endplate cartilage and disc are removed however the surgeon avoids violating the cortical bone of the endplate to avoid cage subsidence. One or two interbody devices are then placed within the disc space. Interbody devices include bone graft alone as well as interbody cages. Cages are typically composed of titanium or polyetheretherketone (PEEK) with or without hydroxyapatite and are typically filled with a graft material to facilitate interbody fusion (autograft, allograft, Calcium triphosphate, bone-morphogenic protein (BMP), etc). Fluoroscopic or three-dimensional imaging is then used to verify cage position within the disc space ventral to the posterior vertebral body line and dorsal to the anterior vertebral body line. Prior to or after this decompression and interbody device placement pedicle screws are placed using a variety of free-hand or image-guided techniques and the screws are linked together with rods that span the disc space where the fusion is to occur. Caps secure the rods to the screws, forming a semi-rigid construct that provides a favourable environment for fusion to occur.

Fusion rates amongst open PLIF and TLIF have been reported to be between 88.4% and 95.7% [42]–[46]. Placement of a single versus dual interbody devices remains a topic of debate. In a finite PLIF biomechanical model, cage remodeling, cage stress, cage subsidence and cage dislodgement prior to any simulated fusion were higher amongst single cage constructs versus dual cage constructs [47]. However, after simulated boney remodeling the differences between single and dual cage constructs was diminished. Both randomized prospective clinical trials and retrospective studies comparing single versus dual cage have found similar fusion rates, complication rates and clinical outcomes in patients undergoing PLIF [48], [49].

While PLIF has been shown to be a reliable technique in achieving an interbody fusion of the lumbar spine; it is not without its limitations. Potential complications can be broadly divided into general perioperative complications and complications specific to PLIF. General perioperative complications include blood loss, wound infection, general infections (pneumonia, urinary tract infections), perioperative cardiorespiratory events, airway compromise, ileus and general medical complications related to anesthesia [50]–[52]. Complications related specifically to the PLIF procedure include significant bleeding requiring transfusion, durotomy, cauda equina injury causing paralysis, nerve root injury (specifically the traversing root in PLIF) causing weakness, epidural fibrosis pseudoarthrosis, cage subsidence, hardware malposition/ failure, ongoing back pain, adjacent level disease, neuropathic pain, peripheral neuropraxia secondary to prone positioning, blindness secondary to positioning [48], [51]–[53][41]. Complication rates are increased with older age, increased blood loss, increased operative time and increased number of levels fused [50].

1.4e Open TLIF (O-TLIF)

Open TLIF was an attempt to address the major concerns with PLIF, namely the extent of

neural element retraction required and the subsequent concerns of potential nerve root injury (particularly the traversing root), dural tears and epidural fibrosis [41]. The TLIF offers direct unilateral access to the intervertebral foramen while decreasing surgical injury to the paraspinals and decreasing structural damage. Unilateral foraminal exposure theoretically may decrease probability of injury to dura and nerve root. Indications for TLIF and PLIF are the same.

Traditional TLIF was first described by Harms and Rolinger in 1982 [54]. As in PLIF, the spine is accessed posteriorly in a prone patient. Incision is either made in the midline or paramedian. Access to the spinal canal is achieved through a unilateral laminectomy and inferior facetectomy. Similarly to PLIF, TLIF involves excision of the ligamentum flavum and cauterization of epidural bleeding. The thecal sac is retracted medially to gain access to the disc space albeit to a lesser extent than with traditional PLIF. Cited advantages of TLIF include relatively easier access to posterior structures, improved preservation of posterior osseoligamentous structures (that are theoretically important for biomechanical stability), less retraction of the thecal sac and decreased risk of traversing nerve root injury. Disadvantages of this technique similarly to PLIF include the presence of still posterior muscle dissection/ injury (albeit to a lesser degree) as well as the theoretical disadvantages of open surgery. Whereas the traversing nerve root has a theoretical risk of injury in PLIF, the exiting nerve root theoretically is at higher risk in TLIF given the exiting root lies within the foramen. In a recent meta-analysis comparing PLIF to open TLIF, PLIF was found to have a significant increase in overall complication rate and durotomy rate [55]. No significant difference was found between the two with respect to patient satisfaction or radiographic fusion rate. Despite their limitations both PLIF and TLIF are incredibly effective and account for a significant number of interbody fusions performed worldwide.

1.4f MIS spine surgery/ MIS-TLIF

Minimally invasive spine surgery seeks to address the issue of significant muscle dissection and muscle retraction and the potential corresponding complications of increased scarring, blood loss, operative time, post-operative pain, post-operative infection and time in hospital. Important principles in achieving this include small skin incisions followed by serial dilatation, tubular retraction as well as percutaneous screw, rod and cap insertion. Potential advantages with this approach include decreased blood loss, decreased narcotic requirement, shorter hospital stays and faster return to work while providing equivalent clinical and radiographic outcomes.

MIS TLIF was first introduced as a modification to Harms and Rolinger's original technique by Foley et al in 2002 [54], [56]. While TLIF is a safe and reliable procedure for achieving decompression and fusion of the lumbar spine [45], [57]–[60], it still requires significant paravertebral muscle dissection, stripping and retraction that can lead to soft tissue injury and its associated complications [53]. Using the aforementioned principles MIS-TLIF sought to reduce operative dissection and its associated complications. MIS-TLIF can be done as a “mini-open” technique or via serial dilation and tubular retraction followed by percutaneous pedicle screw instrumentation. The remainder or the goals and principles of the technique are very similar to open-TLIF.

The claimed advantages of MIS spine surgery and MIS-TLIF in particular are controversial as the literature is conflicting on the validity of these claims. A recent meta-analysis did indicate significantly lower blood loss, lower overall complication rates, shorter hospital stay, equivalent surgical time but higher duration of fluoroscopy in those undergoing MIS TLIF versus O-TLIF. Admittedly the studies included in the meta-analysis were of low quality and one of the authors does receive industry support. Other meta-analyses have shown no significant advantages for MIS-TLIF compared with open TLIF with a higher rate of neurological complications, a steep learning curve and higher rate of hardware-related complications and higher revision rates [61]–[65]. Expanding on the challenges of MIS spine surgery, one of the reasons for a steep learning curve is the

lack of 3 dimensional anatomical references make orientation more difficult [66]. Also manipulating instruments through a small opening is challenging especially if complications arise and also requires an increase reliance on intraoperative imaging and hence intraoperative radiation exposure. Cost of MIS spine surgery versus open surgery is also a source of debate in the spine community. While studies have been performed examining cost, there is an insufficient number of studies as well as a lack of standardized reporting and cost analysis techniques [67]. Certainly there is a need for high quality prospective studies to answer these questions definitively.

1.4g MIDLF Technique

The MIDLF technique combines the advantages of the CBT screw with minimal access open surgery. It offers the potential advantages of open surgery along with the advantages of decreased dissection and the ability to perform the decompression and fusion through the same surgical window.

The MIDLF technique is composed of a midline posterior approach, microsurgical laminectomy and cortical bone trajectory screw. This technique falls under the umbrella of minimally invasive surgery (MIS) as it permits decompression and fusion within the same field; minimizing approach-related complications. Given the cortical bone trajectory does not rely on cancellous fixation it theoretically improve fixation in the osteoporotic spine. It's medial to lateral trajectory is also theoretically favourable as it angles away from the vital neural elements. This different trajectory also enables the CBT screw to be used a potential rescue screw for a blown pedicle screw (A3)[68]. The origin of the CBT trajectory originated with Steffee's description of the "force nucleus" start point that correlates to the junction of the TP, lamina, and inferior articular facet with the pars interarticularis, superior articular facet and the pedicle (A25)[36]. Roy-Camille further developed the technique in 1986 with his "straight in" posterior lumbar spine plate/screw construct. This trajectory utilized a trajectory that was between a modern CBT and modern pedicle screw trajectory. Su's 2009 study characterized the mid lateral pars as a

key anatomic landmark for the insertion of CBT as well as pedicle screws in the lumbar spine. This landmark represents the centre of the lumbar pedicle. It's utility stems from its preservation even in the setting of severe degenerative changes as well as it protects the cephalad facet from excessive dissection and potential destabilization. It also is advantageous in obese patients as it does not require identification of the transverse processes, which can be quite challenging in this population. Matsukawa's morphometric CT study of 470 lumbar vertebrae has allowed for optimal screw size and trajectory at each level throughout the lumbar spine (A23 11) [69].

Indications for CBT screw/ MIDLF include the majority of indications previously stated for traditional pedicle screws and interbody fusions. These include tumor, infection, trauma, scoliosis and spondylolisthesis of the lumbar spine (A26, A 27)[70][24]. As well as lumbar fixation, lower thoracic (T9-T12) and sacral fixation can utilize a CBT screw.

Absolute contraindications for the use of CBT screws/ MIDLF include a congenital pars defect as well as cortical bone deficiency at the pars secondary to a wide decompression and pars fracture (A23) [71]. Relative contraindications include a narrow or medialized pars and small pedicles. However one could argue that small pedicles in general make any form of pedicle screw fixation difficult whether a traditional or CBT screw technique are used.

While CBT screw fixation provides several distinct advantages to traditional pedicle screw fixation it needs to provide the surgeon with equivalent biomechanical fixation if it is to be a viable technique. Theoretically the CBT screw should provide excellent fixation despite its shorter length and smaller diameter as it obtains 4 point cortical interference fit. Several studies have begun to examine and compare various biomechanical parameters between these two techniques. In their 2009 study, Santoni et al compared yield-pullout and screw-toggle using both a traditional pedicle screw technique and a CBT screw technique in cadaveric lumbar spines. In this study cadaveric lumbar spines

were instrumented with either a Legacy 6.5mm x 50 mm lateral to medial-pedicle-screw and a 4.5mm x 30mm SOLERA medial-to-lateral CBT screw [72]. Yield pullout strength, stiffness and failure moment was statistically equivalent between the two groups. Furthermore post-instrumentation CT demonstrated higher density bone contacting the entire length of the CBT screw that equated to a “100% increase in interface strength per unit screw length relative to the traditionally oriented screw” [72]. This was reinforced by the observation that the CBT group demonstrated a 30% increase in failure load to uniaxial in osteoporotic bone. In their 2015 biomechanical study Matsukawa et al corroborated these findings as CBT screw fixation had a 26.4% greater mean pullout strength and 27.8% increased mean stiffness with cephalocaudal loading and 140.2% increased stiffness during mediolateral loading (A12)[73]. CBT screw fixation did however have inferior resistance to lateral bending and rotational forces.

Perez-Orribo et al. expanded on the concepts of the previous two studies to compare the biomechanical behavior of CBT and traditional pedicle screw fixation combined with tulip-rod and interbody fixation devices. Testing conditions were as follows: intact specimens with either CBT or PS placement, L3-4 bilateral PS-rods, bilateral CS-rods, with DLIF, with DLIF-PS rods, with DLIF-CS rods, with TLIF PS rods, with TLIF CS rods, mean segmental motion of lumbar CBT screws and traditional lumbar pedicle screws (A23:15)[74]. No significant difference in mean segmental motion was observed during flexion, extension or axial rotation. With intact disc the only difference observed was increased axial rotatory stiffness in the PS-rod group. With DLIF no difference was seen between CS and PS. With TLIF, PS-rod fixation was stiffer than CS-rod fixation during lateral bend. Reasons for the decreased lateral bend and rotational stiffness seen in the CBT group may be explained by the smaller screw length and screw diameter rather than the CBT technique itself (A23)[71]. These findings were similar to the previous findings and demonstrated that in the presence of segmental immobilization both with and without interbody devices, CBT screw fixation appeared to provide similar fixation to PS fixation.

Three principle factors determine pedicle screw stability: screw biomechanics screw insertion technique and bone biomechanics (A23; 8,9)[75][76]. Increased screw diameter, decreased screw pitch as well as a tapered screw design aid in improving screw pullout strength (A23:18,19)[77][78] . With respect to bone quality, bone mineral density (BMD) has a significantly positive correlation with pedicle screw stability (A23;17) [79]. Pullout strength has been shown to inversely correlate with screw length and screw diameter (A23:10) [69]. Ratio of the screw diameter to the pilot hole has been shown to be positively correlated with pullout strength (A23;23,24)[80][81]. Under-tapping the pilot hole of self-tapping screws has also been found to increase the pullout strength of self-tapping screws. This is related to the observation that increased insertional torque leads to increased pullout strength (A23 20)[82]. Matsukawa examined insertional torque in both traditional PS and CBT screws and found insertional torque of CBT screws to be 1.7 times higher (A23 10) [69]. With respect to bone biomechanics increased bone density improves screw fixation. Thus, more dense cortical bone provides superior purchase compared to less dense cortical bone. This truth is widely accepted throughout the orthopaedic community. As a continuation of this logic, any pathological process that compromises the material properties of the bone therefore can compromise implant stability. This includes infection, trauma, tumor and metabolic bone diseases (including osteoporosis) as well as skeletal dysplasias.

One final biomechanical study demonstrates yet another advantage of the CBT screw: the ability to salvage a loose or compromised traditional PS. In their 2015 biomechanical study, Calvert et al used 10 fresh-frozen cadaveric lumbar spine specimens to examine the ability to salvage failed traditional PS fixation with a CBT screw [83]. A discoligamentous and facet-capsule-sparing dissection was performed and specimens were potted and placed on a load-cell apparatus. L3 and L4 were instrumented with either 4.5 x 30mm MAST MIDLF CBT screws or 6.5 x 45mm CD Horizon Solera PS. Screw-rod constructs were then completed with 4.75mm CoCr rods. Flexion/extension, lateral

bending and axial rotation was performed and displacement was measured. Load to failure (screw pullout) was then performed. After failure the screws were then salvaged with screws of the opposite trajectory. No significant difference in stiffness in flexion/extension or axial rotation was observed between the initial PS construct and the CBT rescue screw construct. A significant difference was observed in lateral bending with the CBT rescue having a lower resistance. No difference in any motion plane was seen in CBT screws rescued with traditional PS placement. CBT rescue screws maintained a pullout strength of approximately 60-65% compared with the initially placed traditional PS.

The modern pedicle screws consist of several key design elements. The SOLERA (Medtronic Inc.) screw utilized in MIDLF surgery has several key design elements that improve its function as well as potentially limits weaknesses seen with previous instrumentation. One of the major cited disadvantages of pedicle screw fixation is the bulkiness of the screw [84]. In slender patients this can lead to hardware prominence and soft tissue irritation. Also, large screws can impinge upon the unfused superior articular facet contributing to adjacent level degeneration. When patients require cross-sectional imaging post-surgery, the metallic artifact from the hardware can prove to be a significant obstacle in achieving quality imaging and making an accurate diagnosis. Biomechanical studies of pedicle screws demonstrates that 60% of their fixation strength comes from the pedicle itself and the other 40% of their fixation strength comes from fixation within the vertebral body and the anterior vertebral cortex (if there is anterior wall penetration) [23]. Unfortunately, the risks to vital structures with anterior cortical perforation out-weights the advantage of increased fixation and thus the fixation strength is diminished 20% and further biasing fixation strength to the pedicle. The cortical bone trajectory (CBT) screw seeks to exploit the fixation within the dense cortical bone of the pedicle and forgoes fixation in the weaker cancellous bone. The screw selected for this application is the SOLERA pedicle screw (Medtronic Inc). This screw utilizes a 'dual lead OSTEOGRIP thread that consists of a cortical thread pitch near the tulip that is designed to provide

robust fixation within the dense cortical bone of the pedicle as well as a larger cancellous pitch near the tip of the screw that is designed to provide fixation within the less-dense bone of the vertebral body. The screw shaft also utilizes a tapered conical design that has been demonstrated in biomechanical studies to improve pullout strength [72][85].

1.5 MIDLF Trials

In 2014 Mizuno et al performed a retrospective review of 14 patients (mean age 68: 7 males and 5 females) who underwent MIDLF for the treatment of single level lumbar spondylolisthesis (Mizuno MIDLF) [38]. All patients had both low back pain and radicular pain with or without claudication. Indications for interbody fusion included greater than 4mm listhesis and greater than 10 degrees of angulation on flexion-extension views. Secondary inclusion criteria included degenerative spondylolisthesis up to Meyerding grade 2, isthmic spondylolisthesis and advanced facet arthrosis. Exclusion criteria included unilateral foraminal disease, spondylitis, or sacroiliac dysfunction. Average follow-up was 15 months. Outcomes included Japanese Orthopaedic Association (JOA) score that measures patient function. There was one case of intraoperative complication in the form of a cortical bone fracture. CRP, WBC and CK levels were taken pre and post-operatively. All inflammatory markers were found to have normalized within a week post operatively which is in keeping with mini-open PLIF findings in the literature. Post-operative radiographs did not demonstrate any hardware failures. The authors concluded that MIDLF is a valid technique that was safe and yielded clinical improvement similar to traditional techniques with the potential advantages of MIS techniques.

Kasukawa et al's 2015 case-control study compared the clinical and radiological outcomes of TLIF with CBT screw insertion and TLIF PS fixation [38]. 26 patients (mean age 67: 11 males, 15 females) were retrospectively reviewed. Indications for surgery included Meyerding grade 1 or 2 spondylolisthesis or intraforaminal to lateral disc herniation. Screws were inserted in one of three ways: via a minimally invasive

lateral Wiltse approach (M-TLIF, n=10), via a percutaneous system (P-TLIF, n=6), via CBT-TLIF (n=10). Outcomes included operative duration, estimated blood loss (EBL), complications and post-operative radiological parameters. Operative duration was found to be significantly longer in the P-TLIF group. Complications observed in the CBT-TLIF group included one dural tear and two pedicle fractures that were rescued via traditional PS insertion. CBT-TLIF resulted in smaller intraoperative blood loss, and shorter operative duration compared with M-TLIF and P-TLIF. The fusion rate, accuracy of screw insertion and maintenance of lordosis was similar amongst the three groups. Thus CBT-TLIF fixation afforded the biomechanical stability seen with M-TLIF and P-TLIF while minimizing exposure-related morbidity.

1.6 Thesis Rationale

Modern pedicle-rod constructs combined with interbody fusion have revolutionized the treatment of degenerative lumbar spine disorders. Despite the immense success of the traditional pedicle screw design and insertion along with traditional PLIF for achieving interbody fusion they are not without their disadvantages. Pedicle Screw design has evolved in an attempt to address some of these shortcomings seen in previous iterations. From a technique driven-perspective, achieving an interbody fusion with less soft tissue dissection has been a goal of several minimally invasive techniques. The MIDLF technique allows for decompression, fixation and interbody fusion through the same soft tissue window. It does this through utilizing the cortical bone trajectory screw technique. We feel this combination of innovative screw design, CBT screw technique and MIDLF have the potential to improve upon the traditional pedicle-screw PLIF model. Thus, the goal of this thesis is to ascertain whether MIDLF with CBT screw provides equivalent fixation to the traditional pedicle screw PLIF model.

1.7 Objectives and Hypothesis

Specific Objectives to this thesis:

To compare operative time, perioperative blood loss, transfusion rates, radiographic outcomes, perioperative complication rates and patient functional status between patients undergoing traditional PLIF with patients undergoing MIDLF.

The hypotheses for this study were:

Operative time and blood loss will be less in the MIDLF group when compared with their PLIF counterparts. Transfusion rates, radiographic outcomes, perioperative complication rates and patient functional status will not be significantly different between the two groups.

Chapter 2: Materials and Methods

We retrospectively identified 21 patients from our institutional database who had undergone MIDLF. Inclusion criteria included single-level MIDLF using fluoro-navigation that was performed for any combination of the following clinical diagnoses: back pain, neurogenic claudication, radiculopathy, cauda equina syndrome and weakness. MRI demonstrated any combination of the following pathologies: lateral recess stenosis, foraminal stenosis, spondylolisthesis, degenerative scoliosis and lumbar disc herniation. Patients were excluded if they had multi-level surgery. After application of inclusion and exclusion criteria 16 MIDLF patients remained. Our control group consisted of individuals undergoing single-level PLIF with fluoro-navigation who met the same inclusion and exclusion criteria. MIDLF candidates were BMI-matched and age-matched with the closest BMI-matched and age-matched PLIF patients available in our institutional registry.

Outcomes included surgical duration (minutes), pre-operative and post-operative hemoglobin, requirement of transfusion during hospitalization, adverse intraoperative events, duration in hospital, pre-operative and post-operative radiographic segmental

lordosis, pre-operative and post-operative radiographic lumbar lordosis, radiographic reduction of listhesis, radiographic evidence of cage subsidence, screw loosening, number of cages used, post-operative complications, revision surgery and post-operative patient functional status. All data was compiled by a single fellowship-trained spine surgeon.

Data was analyzed using SPSS v. 24. Continuous variables are reported as mean \pm SD or median and range. Matched pairs were compared with the paired t-test for normally distributed data or Wilcoxon signed rank sum test for nonparametric data. Categorical data are reported as percentages and were analyzed by the Mantel-Haenszel test stratified by matched sets or by the McNemar-Bowker test. All p values were considered significant if <0.05 . P values were not adjusted for multiple comparisons. Odds ratios and 95% CI were calculated with conditional logistic regression before and after adjustment for covariates. Covariates were identified as significant on univariate testing or were considered to be clinically relevant.

Results

Demographic data is indicated in Table 1. Average age in both groups was approximately 60 years of age. Average weight and height between the two groups was not significantly different with the MIDLF (case) group possessing a mean weight and height of 78.8 kg and 162.3 cm respectively. The PLIF (control) group had a mean weight and height of 90.9 kg and 158.6 cm respectively. While an effort was made to match BMI between the two groups, there was a small yet significant difference between the mean BMI of the case group (29.8) and the mean BMI of the control group (31.8). We feel it unlikely that this small difference is of significant clinical relevance given both of these values are close to the cutoff between 'overweight' and class 1 obesity. In both groups, the L4-5 level was most commonly involved. The most common stenotic location was the lateral recess. Both of these findings are expected given what we know about the pathoanatomy of spinal stenosis. Clinically most patients in both groups suffered from a

combination of back pain and claudication with radiculopathy, cauda equina syndrome and clinically-measured weakness, making up a smaller percentage of complaints. It is important to note that back pain was never a stand-alone symptom but was always accompanied by a neurologically-based complaint. This is important given we collectively know that there is a significantly increased likelihood patients' radicular or claudicant symptoms will improve with surgical treatment when compared to back pain. A small yet significant increased Oswestry Disability Index (ODI) score was found in the case group (with a higher score indicating greater disability). This result, has to be taken in context however given the absence of a significant difference between the two groups with respect to other self-reported measures as well as the relatively small sample size in the present study.

Operative characteristics are contained in Table 2. Surgical duration was not significantly different between the two groups. While post-operative hemoglobin was different between the two groups, the delta or change in hemoglobin between the pre-operative and post-operative period was not statistically significant between the two groups (Table 4). Length-of-stay as well as perioperative adverse events were not different between the two groups.

Radiographic parameters are displayed in Table 3. While there was a difference in post-operative segmental lordosis between the two groups, the delta or change in segmental lordosis was not significantly different between the two groups (table 4). The remainder of radiographic parameters including lumbar lordosis, reduction of listhesis, number of cages and indications of hardware failure were not significantly different between the two groups. Revision surgery rates were also statistically no different between the two groups.

Functional measures are indicated in Tables 4 and 5. Once again there was no statistically significant difference between the two groups as post-operative complaints and functional scores including both the ODI and SF12 were similar both at 3 months and 12 months post-operatively. Changes in clinical, radiographic and patient functional scores between

the pre-operative and post-operative periods are outlined in table 4. No statistically significant differences were observed between the two groups.

Given the multiple comparisons a logistic regression analysis was performed in Table 6. After this analysis was performed the two groups did not demonstrate statistically significant results with respect to the aforementioned variables.

Discussion

The desire to improve fixation and fusion techniques in the lumbar spine remains an ongoing process for both the surgeon and medical implant designers. The CBT screw as well as the entire MIDLF technique, offer the surgeon several theoretical benefits that have been outlined in this thesis. Santoni's original article on the CBT screw demonstrated equivalent fixation parameters when compared with the traditional pedicle screw with the potential advantages of its resistance to changes in bone quality as well as insertion technique [72]. The MIDLF technique, which employs the use of a CBT screw has been shown in prior studies to provide statistically equivalent clinical, radiological and patient measured outcomes [38], [85]. Kasukawa's study even found a decrease in operative time and perioperative blood loss in MIDLF compared with M-TLIF and P-TLIF[38].

The current study's goal was to compare our institutional clinical, radiographic and patient measured outcomes in patients undergoing single-level MIDLF and PLIF. Our results demonstrated no statistical difference in clinical outcomes such as operative time, blood loss, rate of transfusion, perioperative complication rates or time in hospital. This varies from Kasukawa's finding of decreased blood loss and operative time in the MIDLF group. This could be a result of our small sample size as well as variations between our control group and his. Regarding operative time in our study, we did look at PLIF only done with fluoro-navigation so as to match our MIDLF patients. PLIF is commonly completed in the absence of fluoro-navigation. MIDLF typically uses

navigation although it can be done with fluoroscopy alone. Because of this we may have artificially inflated the operative time of the PLIF group.

Radiographic outcomes including change in listhesis, change in pre-operative versus post-operative segmental and lumbar lordosis as well as cage subsidence and hardware failure did not demonstrate a significant difference when the two groups were compared. This is unsurprising given both procedures provide the necessary fixation and access for placement of interbody cages to allow the surgeon to achieve the desired change in alignment. Also, given the fixation of the CBT screw has demonstrated at minimum non-inferiority to the traditional pedicle screw, there is little reason to expect differences in post-operative alignment changes between the two groups with the passage of time.

Lastly, patient outcome-scores via the Oswestry Disability Index, were statistically no different between the two groups. Again given the previous studies findings as well as given our small numbers it is unsurprising that this was the case.

Conclusions

Based on our study MIDLF provided non-inferiority with respect to all of our measured outcomes including perioperative clinical outcomes, radiographic outcomes as well as patient self-measured functional status. Certainly, this is a pilot study and a larger study is needed to increase our statistical power with p-values adjusted prior to us performing a multi-variable analysis. This study is novel with respect to it being the first known study of it's kind comparing traditional PLIF with MIDLF using a variety of clinical, radiographic and patient functional outcome scores.

Bibliography

- [1] Herkowitz Harry, Garfin Steven, Elsmont Frank, Bell Gordon, Balderson Richard, Rothman Simeone *The Spine*. .
- [2] L. Kalichman *et al.*, “Spinal stenosis prevalence and association with symptoms: the Framingham Study,” *Spine J. Off. J. North Am. Spine Soc.*, vol. 9, no. 7, pp. 545–550, Jul. 2009.
- [3] R. A. Deyo, “Treatment of lumbar spinal stenosis: a balancing act,” *Spine J. Off. J. North Am. Spine Soc.*, vol. 10, no. 7, pp. 625–627, Jul. 2010.

- [4] Y. R. Rampersaud *et al.*, “Assessment of health-related quality of life after surgical treatment of focal symptomatic spinal stenosis compared with osteoarthritis of the hip or knee,” *Spine J. Off. J. North Am. Spine Soc.*, vol. 8, no. 2, pp. 296–304, Apr. 2008.
- [5] M. Nadeau *et al.*, “The reliability of differentiating neurogenic claudication from vascular claudication based on symptomatic presentation,” *Can. J. Surg. J. Can. Chir.*, vol. 56, no. 6, pp. 372–377, Dec. 2013.
- [6] W. C. Watters *et al.*, “Degenerative lumbar spinal stenosis: an evidence-based clinical guideline for the diagnosis and treatment of degenerative lumbar spinal stenosis,” *Spine J. Off. J. North Am. Spine Soc.*, vol. 8, no. 2, pp. 305–310, Apr. 2008.
- [7] H. Hurri *et al.*, “Lumbar spinal stenosis: assessment of long-term outcome 12 years after operative and conservative treatment,” *J. Spinal Disord.*, vol. 11, no. 2, pp. 110–115, Apr. 1998.
- [8] K. E. Johnsson, I. Rosén, and A. Udén, “The natural course of lumbar spinal stenosis,” *Clin. Orthop.*, no. 279, pp. 82–86, Jun. 1992.
- [9] M. Benoist, “The natural history of lumbar degenerative spinal stenosis,” *Jt. Bone Spine Rev. Rhum.*, vol. 69, no. 5, pp. 450–457, Oct. 2002.
- [10] M. A. Knaub, D. S. Won, R. McGuire, and H. N. Herkowitz, “Lumbar spinal stenosis: indications for arthrodesis and spinal instrumentation,” *Instr. Course Lect.*, vol. 54, pp. 313–319, 2005.
- [11] J. D. Lurie *et al.*, “Long-term outcomes of lumbar spinal stenosis: eight-year results of the Spine Patient Outcomes Research Trial (SPORT),” *Spine*, vol. 40, no. 2, pp. 63–76, Jan. 2015.
- [12] S. R. Garfin, M. Glover, R. E. Booth, F. A. Simeone, and R. H. Rothman, “Laminectomy: a review of the Pennsylvania hospital experience,” *J. Spinal Disord.*, vol. 1, no. 2, pp. 116–133, 1988.
- [13] H. N. Herkowitz and L. T. Kurz, “Degenerative lumbar spondylolisthesis with spinal stenosis. A prospective study comparing decompression with decompression and intertransverse process arthrodesis,” *J. Bone Joint Surg. Am.*, vol. 73, no. 6, pp. 802–808, Jul. 1991.
- [14] L. D. Herron and C. Mangelsdorf, “Lumbar spinal stenosis: results of surgical treatment,” *J. Spinal Disord.*, vol. 4, no. 1, pp. 26–33, Mar. 1991.

- [15] J. N. Katz, S. J. Lipson, M. G. Larson, J. M. McInnes, A. H. Fossel, and M. H. Liang, "The outcome of decompressive laminectomy for degenerative lumbar stenosis," *J. Bone Joint Surg. Am.*, vol. 73, no. 6, pp. 809–816, Jul. 1991.
- [16] D. M. Spengler, "Degenerative stenosis of the lumbar spine," *J. Bone Joint Surg. Am.*, vol. 69, no. 2, pp. 305–308, Feb. 1987.
- [17] M. Tile, S. R. McNeil, R. K. Zarins, G. F. Pennal, and S. H. Garside, "Spinal stenosis. Results of treatment," *Clin. Orthop.*, no. 115, pp. 104–108, Apr. 1976.
- [18] D. L. Patrick, R. A. Deyo, S. J. Atlas, D. E. Singer, A. Chapin, and R. B. Keller, "Assessing health-related quality of life in patients with sciatica," *Spine*, vol. 20, no. 17, p. 1899–1908; discussion 1909, Sep. 1995.
- [19] J. C. Fairbank, J. Couper, J. B. Davies, and J. P. O'Brien, "The Oswestry low back pain disability questionnaire," *Physiotherapy*, vol. 66, no. 8, pp. 271–273, Aug. 1980.
- [20] A. Cano, M. T. Leonard, and A. Franz, "The significant other version of the Pain Catastrophizing Scale (PCS-S): preliminary validation," *Pain*, vol. 119, no. 1–3, pp. 26–37, Dec. 2005.
- [21] W. T. Edwards, "Biomechanics of posterior lumbar fixation. Analysis of testing methodologies," *Spine*, vol. 16, no. 10, pp. 1224–1232, Oct. 1991.
- [22] White AA and Punjabi MM, *Clinical Biomechanics of the Spine 2nd Edition*. Philadelphia.
- [23] Benzel, EC, *Biomechanics of spine stabilization : principles and clinical practice*. New York: McGraw-Hill, Health Professions Division, 1995.
- [24] Boos N and Webb JK, "Pedicle Screw Fixation in Spinal Disorders: A European view.," *Eur Spine J*, vol. 6, no. 1, pp. 2–18, 1997.
- [25] Roy-Camille R, Benazet JP, Desauge JP and Kuntz F, "Lumbosacral fusion with pedicle screw plating instrumentation. A 10-year follow-up.," *Acta Orthop Scand*, vol. 251, pp. 100–104, 1993.
- [26] Roy-Camille R, Saillant G, Mazel C, "Internal Fixation of the Lumbar Spine with Pedicle Screw Plating," *Clin Orthop*, vol. 203, pp. 7–17, 1986.
- [27] Krag MH et al, *The Lumbar Spine*. Philadelphia: Saunders.

- [28] Krag MH et al., “An internal fixator for posterior application of short segments of the thoracic, lumbar or lumbosacral spine. Design and testing,” vol. 203, pp. 75–98, 1986.
- [29] Liu YK et al, “Fatigue life improvement of nitrogen-ion-implanted pedicle screws,” *Spine*, vol. 15, pp. 311–317, 1990.
- [30] Moran JM et al, “Transpedicular screw fixation,” *J Orthop Res*, vol. 7, pp. 107–114.
- [31] King D, “Internal Fixation for lumbosacral fusion,” *J Bone Jt. Surg Am*, vol. 30, no. 3, pp. 560–565, 1948.
- [32] Boucher HH, “A method of spinal fusion,” *J Bone Jt. Surg Br*, vol. 41, no. 2, pp. 248–259, 1959.
- [33] Harrington PR and Tullos HS, “Reduction of severe spondylolisthesis in children,” *South Med J*, vol. 62, no. 1, pp. 1–7, 1969.
- [34] Roy-Camille R and Demeulenaere C, “Osteosynthese du rachis dorsal, lombaire et lombosacree par plaque metalliques vissees dans les pedicles vertebraux et les apophyses articulaires,” *Presse Med.*, vol. 78, pp. 1447–1448, 1970.
- [35] Roy-Camille R, Saillant G and Bisserie M et al, “Surgical treatment of spinal metastatic tumors by posterior plating and laminectomy. Proceedings of the 51st annual meeting of the American Academy of Orthopaedic Surgeons.” 1984.
- [36] Steffee AD, Biscup RS and Sitkowski DJ, “Segmental spine plates with pedicle screw fixation. A new internal fixation device for disorders of the lumbar and thoracolumbar spine,” *Clin Orthop Relat Res*, vol. 203, pp. 45–53, 1986.
- [37] Vaccaro A and Albert T, *Spine Surgery: Tricks of the Trade*. New York/ Stuttgart: Thieme, 2008.
- [38] Kasukawa Y, Miyakoshi N, Hongo M et al., “Short-term results of transforaminal lumbar interbody fusion using pedicle screw with cortical bone trajectory compared with conventional trajectory,” *Asian Spine J*, vol. 9, no. 3, pp. 440–448, 2015.
- [39] R. B. Cloward, “The treatment of ruptured lumbar intervertebral discs by vertebral body fusion. I. Indications, operative technique, after care,” *J. Neurosurg.*, vol. 10, no. 2, pp. 154–168, Mar. 1953.
- [40] L. T. Khoo, S. Palmer, D. T. Laich, and R. G. Fessler, “Minimally invasive percutaneous posterior lumbar interbody fusion,” *Neurosurgery*, vol. 51, no. 5 Suppl, pp. S166-181, Nov. 2002.

- [41] R. J. Mobbs, K. Phan, G. Malham, K. Seex, and P. J. Rao, "Lumbar interbody fusion: techniques, indications and comparison of interbody fusion options including PLIF, TLIF, MI-TLIF, OLIF/ATP, LLIF and ALIF," *J. Spine Surg. Hong Kong*, vol. 1, no. 1, pp. 2–18, Dec. 2015.
- [42] F. B. Christensen *et al.*, "Circumferential lumbar spinal fusion with Brantigan cage versus posterolateral fusion with titanium Cotrel-Dubousset instrumentation: a prospective, randomized clinical study of 146 patients," *Spine*, vol. 27, no. 23, pp. 2674–2683, Dec. 2002.
- [43] R. H. Wu, J. F. Fraser, and R. Härtl, "Minimal access versus open transforaminal lumbar interbody fusion: meta-analysis of fusion rates," *Spine*, vol. 35, no. 26, pp. 2273–2281, Dec. 2010.
- [44] L. Hackenberg, H. Halm, V. Bullmann, V. Vieth, M. Schneider, and U. Liljenqvist, "Transforaminal lumbar interbody fusion: a safe technique with satisfactory three to five year results," *Eur. Spine J. Off. Publ. Eur. Spine Soc. Eur. Spinal Deform. Soc. Eur. Sect. Cerv. Spine Res. Soc.*, vol. 14, no. 6, pp. 551–558, Aug. 2005.
- [45] S. A. Salehi, R. Tawk, A. Ganju, F. LaMarca, J. C. Liu, and S. L. Ondra, "Transforaminal lumbar interbody fusion: surgical technique and results in 24 patients," *Neurosurgery*, vol. 54, no. 2, p. 368–374; discussion 374, Feb. 2004.
- [46] S. Lauber, T. L. Schulte, U. Liljenqvist, H. Halm, and L. Hackenberg, "Clinical and radiologic 2–4-year results of transforaminal lumbar interbody fusion in degenerative and isthmic spondylolisthesis grades 1 and 2," *Spine*, vol. 31, no. 15, pp. 1693–1698, Jul. 2006.
- [47] M. Zhang *et al.*, "Long-term effects of placing one or two cages in instrumented posterior lumbar interbody fusion," *Int. Orthop.*, vol. 40, no. 6, pp. 1239–1246, Jun. 2016.
- [48] J. Zhao, X. Wang, T. Hou, and S. He, "One versus two BAK fusion cages in posterior lumbar interbody fusion to L4–L5 degenerative spondylolisthesis: a randomized, controlled prospective study in 25 patients with minimum two-year follow-up," *Spine*, vol. 27, no. 24, pp. 2753–2757, Dec. 2002.
- [49] G. R. Fogel, J. S. Toohey, A. Neidre, and J. W. Brantigan, "Is one cage enough in posterior lumbar interbody fusion: a comparison of unilateral single cage interbody fusion to bilateral cages," *J. Spinal Disord. Tech.*, vol. 20, no. 1, pp. 60–65, Feb. 2007.
- [50] L. Y. Carreon, R. M. Puno, J. R. Dimar, S. D. Glassman, and J. R. Johnson, "Perioperative complications of posterior lumbar decompression and arthrodesis in

- older adults,” *J. Bone Joint Surg. Am.*, vol. 85–A, no. 11, pp. 2089–2092, Nov. 2003.
- [51] N. R. Khan, A. J. Clark, S. L. Lee, G. T. Venable, N. B. Rossi, and K. T. Foley, “Surgical Outcomes for Minimally Invasive vs Open Transforaminal Lumbar Interbody Fusion: An Updated Systematic Review and Meta-analysis,” *Neurosurgery*, vol. 77, no. 6, p. 847–874; discussion 874, Dec. 2015.
- [52] J. R. Joseph, B. W. Smith, F. La Marca, and P. Park, “Comparison of complication rates of minimally invasive transforaminal lumbar interbody fusion and lateral lumbar interbody fusion: a systematic review of the literature,” *Neurosurg. Focus*, vol. 39, no. 4, p. E4, Oct. 2015.
- [53] W. Hu, J. Tang, X. Wu, L. Zhang, and B. Ke, “Minimally invasive versus open transforaminal lumbar fusion: a systematic review of complications,” *Int. Orthop.*, vol. 40, no. 9, pp. 1883–1890, Sep. 2016.
- [54] J. Harms and H. Rolinger, “[A one-stager procedure in operative treatment of spondylolistheses: dorsal traction-reposition and anterior fusion (author’s transl)],” *Z. Orthop. Ihre Grenzgeb.*, vol. 120, no. 3, pp. 343–347, Jun. 1982.
- [55] Q. Zhang, Z. Yuan, M. Zhou, H. Liu, Y. Xu, and Y. Ren, “A comparison of posterior lumbar interbody fusion and transforaminal lumbar interbody fusion: a literature review and meta-analysis,” *BMC Musculoskelet. Disord.*, vol. 15, p. 367, Nov. 2014.
- [56] K. T. Foley, L. T. Holly, and J. D. Schwender, “Minimally invasive lumbar fusion,” *Spine*, vol. 28, no. 15 Suppl, pp. S26–35, Aug. 2003.
- [57] T. G. Lowe, A. D. Tahernia, M. F. O’Brien, and D. A. B. Smith, “Unilateral transforaminal posterior lumbar interbody fusion (TLIF): indications, technique, and 2-year results,” *J. Spinal Disord. Tech.*, vol. 15, no. 1, pp. 31–38, Feb. 2002.
- [58] W. S. Rosenberg and P. V. Mummaneni, “Transforaminal lumbar interbody fusion: technique, complications, and early results,” *Neurosurgery*, vol. 48, no. 3, pp. 569–574–575, Mar. 2001.
- [59] B. K. Potter, B. A. Freedman, E. G. Verwiebe, J. M. Hall, D. W. Polly, and T. R. Kuklo, “Transforaminal lumbar interbody fusion: clinical and radiographic results and complications in 100 consecutive patients,” *J. Spinal Disord. Tech.*, vol. 18, no. 4, pp. 337–346, Aug. 2005.

- [60] S. C. Humphreys, S. D. Hodges, A. G. Patwardhan, J. C. Eck, R. B. Murphy, and L. A. Covington, "Comparison of posterior and transforaminal approaches to lumbar interbody fusion," *Spine*, vol. 26, no. 5, pp. 567–571, Mar. 2001.
- [61] S. S. Dhall, M. Y. Wang, and P. V. Mummaneni, "Clinical and radiographic comparison of mini-open transforaminal lumbar interbody fusion with open transforaminal lumbar interbody fusion in 42 patients with long-term follow-up," *J. Neurosurg. Spine*, vol. 9, no. 6, pp. 560–565, Dec. 2008.
- [62] C. W. B. Peng, W. M. Yue, S. Y. Poh, W. Yeo, and S. B. Tan, "Clinical and radiological outcomes of minimally invasive versus open transforaminal lumbar interbody fusion," *Spine*, vol. 34, no. 13, pp. 1385–1389, Jun. 2009.
- [63] C. Schizas, N. Tzinieris, E. Tsiridis, and V. Kosmopoulos, "Minimally invasive versus open transforaminal lumbar interbody fusion: evaluating initial experience," *Int. Orthop.*, vol. 33, no. 6, pp. 1683–1688, Dec. 2009.
- [64] A. T. Villavicencio, S. Burneikiene, C. M. Roeca, E. L. Nelson, and A. Mason, "Minimally invasive versus open transforaminal lumbar interbody fusion," *Surg. Neurol. Int.*, vol. 1, p. 12, May 2010.
- [65] Q. Jin-Tao *et al.*, "Comparison of MIS vs. open PLIF/TLIF with regard to clinical improvement, fusion rate, and incidence of major complication: a meta-analysis," *Eur. Spine J. Off. Publ. Eur. Spine Soc. Eur. Spinal Deform. Soc. Eur. Sect. Cerv. Spine Res. Soc.*, vol. 24, no. 5, pp. 1058–1065, May 2015.
- [66] M. Payer, "'Minimally invasive' lumbar spine surgery: a critical review," *Acta Neurochir. (Wien)*, vol. 153, no. 7, pp. 1455–1459, Jul. 2011.
- [67] L. T. Al-Khouja, E. M. Baron, J. P. Johnson, T. T. Kim, and D. Drazin, "Cost-effectiveness analysis in minimally invasive spine surgery," *Neurosurg. Focus*, vol. 36, no. 6, p. E4, Jun. 2014.
- [68] Rodriguez A, Neal M, Liu A *et al.*, "Novel placement of cortical bone trajectory screws in previously instrumented pedicles for adjacent-segment lumbar disease using CT image-guided navigation," *Neurosurg Focus*, vol. 36, no. 3, pp. 1–7, 2014.
- [69] Matsukawa K, Yato Y, Nemoto O *et al.*, "In vivo analysis of insertional torque during pedicle screwing using cortical bone trajectory technique.," *J Spine Disord Tech*, vol. 26, pp. E248–E253, 2013.

- [70] Brodke D, Bachus K, Mohr A et al, “Segmental pedicle screw fixation or cross-links in multilevel lumbar constructs: a biomechanical analysis,” *Spine J.*, vol. 1, pp. 373–379, 2001.
- [71] Tengfei S, Hsu W and Tianwen Y., “Lumbar pedicle cortical bone trajectory screw.,” *Chin Med J*, vol. 127, no. 21, pp. 3808–3813, 2014.
- [72] Santoni B, Hynes R, McGilvray K et al., “Cortical bone trajectory for lumbar pedicle screws,” *Spine J.*, vol. 9, pp. 366–373, 2009.
- [73] Matsukawa K, Yato Y, Imabayashi H et al., “Biomechanical evaluation of the fixation strength of lumbar pedicle screws using cortical bone trajectory: a finite element study.,” *J Neurosurg Spine*, pp. 1–8, Jul. 2015.
- [74] Perez-Orribo L, Kalb S, Reyes PM et al., “Biomechanics of lumbar cortical screw-rod fixation with and without interbody support,” *Spine Phila Pa 1976*, vol. 38, pp. 635–641, 2013.
- [75] Cho W, Cho SK and Wu C, “The biomechanics of pedicle screw-based instrumentation.,” *J Bone Jt. Surg Br*, vol. 92B, pp. 1061–1065, 2010.
- [76] Inceoglu S, Montgomery WH, St Clair S et al, “Pedicle screw insertion angle and pullout strength: a comparison of 2 proposed strategies,” *J Neurosurg Spine*, vol. 14, pp. 670–676, 2011.
- [77] Skinner R, Maybee J, Transfeldt E et al, “Experimental pullout testing and comparison of variables in transpedicular screw fixation. A biomechanical study.,” *Spine Phila Pa 1976*, vol. 15, pp. 195–201, 1990.
- [78] Chao CK, Hsu CC, Wang JL et al, “Increasing bending strength and pullout strength in conical pedicle screws: a biomechanical tests and finite element analyses,” *J Spinal Disord Tech*, vol. 21, pp. 130–138, 2008.
- [79] Soshi S, Shiba R, Kondo H et al., “An experimental study on transpedicular screw fixation in relation to osteoporosis of the lumbar spine,” *Spine Phila Pa 1976*, vol. 16, pp. 1335–1341, 1991.
- [80] Chatzistergos PE, Sapkas G and Kourkoulis SK, “The influence of the insertional technique on the pullout force of pedicle screws: an experimental study.,” *Spine Phila Pa 1976*, vol. 35, pp. E332–E337, 2010.
- [81] Steeves M, Stone C, Mogard J et al., “How pilot-hole size affects bone-screw pullout strength in human cadaveric cancellous bone,” vol. 48, pp. 207–212, 2005.

- [82] Zdelblich TA, Kunz DN, Cooke ME et al., “Pedicle screw pullout strength. Correlation with insertional torque.,” *Spine Phila Pa 1976*, vol. 18, pp. 1673–1676, 1993.
- [83] Calvert G, Lawrence B, Abtahi A et al., “Cortical screws used to rescue failed lumbar pedicle screw construct: a biomechanical analysis,” *J Neurosurg Spine*, vol. 22, pp. 166–172, 2015.
- [84] Gaines R, “The use of Pedicle-Screw Internal Fixation for the Operative Treatment of Spinal Disorders,” vol. 82–A, no. 10, pp. 1458–1476, 2000.
- [85] Mizuno M, Kurashi K, Umeda Y et al., “Midline Lumbar Fusion with Cortical Bone Trajectory Screw,” *Neurol Med Chir Tokyo*, vol. 54, pp. 716–721, 2014.

Curriculum Vitae

Dr. Joel Phillips

1.1.1.1.1.1.1 1030 CORONATION DR. UNIT 1113 LONDON, ON. N6G 0G5
 1.1.1.1.1.1.2 PHONE 519 902 4893 • E-MAIL JOEL.PHILLIPS2010@GMAIL.COM

1.1.1.1.1.1.3 QUALIFICATIONS

- **FRCSC Orthopaedic Surgery**
- **Adult Orthopaedic Spine Clinical and Research Fellow**
 - **LHSC Victoria Campus/ Western University**
- Licentiate of the Medical Council of Canada (MCCQE 2): Dec/2011
- MCCQE 1 May 2010
- Doctor of Medicine: Schulich School of Medicine/ Western University May/2010
- Honors Genetics (HBSc): granted at Western University June/2006

1.1.1.1.1.1.4 TRAINING/ EDUCATION

July 2016-Present: Staff physician - Acute Spine Screening Clinic London Ontario

July 2015- Present: Masters of Surgery Program Western University/ Thompson Engineering Biomaterials

July/2015 – July/2016 Adult Spine Fellowship. Western University. LHSC-VH.

- **Division of Orthopaedic Surgery/ London Spine Centre**
- **Full-time Clinical Fellow in Adult Spine Surgery with responsibilities including but not limited to**
 - **Primary Surgeon in a variety of complex and routine Cervical, Thoracic and Lumbar Surgery (>350 cases)**
 - **Degenerative Disease (Cervical, Lumbar): PLIF/MIDLF/TLIF-MIS/TLIF-open microdiscectomy/tubular microdiscectomy/ACDF/ PCDF**
 - **Spine Trauma (Cervical, Thoracic, Lumbar)**
 - **Tumor (Metastatic and Primary): Complex Reconstruction**
 - **Complex Adult Deformity: O-Arm guidance/ Stealth Navigation trained,**

PSO, SPO

- **Patient Management: Clinic, Ward, Emergency Department**
- **Regular On-Call: Weeks/Weekends (>14 days/ month)**

July/2010-June/2015 Orthopaedic Surgery Resident at Western University London Ontario

- I declare that I did not take any breaks in my training as an orthopaedic resident

July/2013

- 1 month Paediatric Orthopaedic elective at BC Children's hospital, Vancouver BC.

Aug/2013

- 1 month Paediatric Orthopaedic elective at Sick Kids hospital, Toronto ON.

Aug/2013-Sept./2013

- 1 month Orthopaedic Oncology core rotation at Mount Sinai hospital, Toronto ON.

2006-2010

Schulich School of Medicine. The University of Western Ontario,

M.D. 2010.

- I declare that I did not take any breaks in my training as a medical student.

2002-2006 University of Western Ontario, Honors Bachelor of Science.

- Major in Genetic

1.1.1.1.1.1.1.5 CLINICAL COURSES/ CONFERENCES

- Canadian Spine Society Meeting
 - Annual adult and pediatric spine symposium
 - Whistler, BC. 2016
- Multidisciplinary Spine Oncology Symposium
 - Comprehensive lecture and case series addressing management of spine oncology
 - Memorial Sloan Kettering Cancer Center. NY, NY. June 2016
- CORF Orthopaedic Review Course
 - Comprehensive Case-based review of all of orthopaedics
 - Calgary AB, April 2015
- Saint-Justine Pediatric Orthopaedic Course

- Didactic/ Case-based review of paediatric orthopaedics
- Montreal QUE, March 2015
- CORR Reconstructive Surgery
 - Didactic/ Case-based review of reconstructive orthopaedics
 - Toronto ON, Jan 2015
- CORR Trauma Review Course
 - Didactic/ Case-based review of orthopaedic trauma
- Canadian Orthopaedic Residents Trauma Course
 - Cadaveric and Didactic resident review of orthopaedic trauma surgery
 - Kingston ON, May 2014
- AO Basic Trauma Course
 - Didactic/ sawbones labs
 - Toronto ON, 2010

1.1.1.1.1.1.6 AWARDS/ RECOGNITION

2015 Canadian Orthopaedic Association Podium Presentation: Are Post-operative Pelvic Parameters and Sagittal Imbalance Predictive of Further Lumbar Surgery in Patients with Spinal Stenosis

2010-2013 Three times recognized by the Department of Surgery as an Outstanding Medical Educator of Medical Clerks

2013 Canadian Orthopaedic Association Poster: Assessing Pre-operative Activity in Total Hip Arthroplasty: A SAFE T Database Study.

2012 Orthopaedic Trauma Association Meeting Podium Presentation: Compartment Syndrome Causes Systemic Inflammatory Response Syndrome (SIRS) and Remote Organ Injury.

2009 International Trauma Association of Canada/ Australasian Trauma Society conference / TAC-ATS (Auckland, New Zealand)

- Co-author for best resident/ fellow scientific paper: Remote Organ Injury Secondary to Compartment Syndrome.

2009 University of Western Ontario Green Award (Quadrangle Beautification Project)

2006-2007 John and Emily Kidd Continuing Scholarship:

- Criteria: undergraduate student entering MD year 1: based on academic achievement.

2006 NSERC Canadian Graduate Scholarship (CGS M)

2002-2008 Queen Elizabeth Aiming for the Top Scholarship

2004-2005 In-Course Scholarship based on competitive average

1.1.1.1.1.1.7 **SPINE CLINICAL EXPERIENCE**

July 2015-July 2016: Adult Spine Fellowship

2014: 3 month senior core rotation at LHSC-VH. Drs. Bailey, Gurr, Rasoulinejad and Siddiqi

2012: 3 Month core rotation LHSC-VH. Drs. Bailey, Gurr, Siddiqi.

-Included exposure to adult deformity correction, adult trauma, as well as oncology/ infection of the spine. Performed a variety of approaches including anterior approach to the cervical spine and standard posterior approach to the thoracic and lumbar spine. Managed high acuity trauma patients as well as inpatient and clinic patients.

2013/07: 1 Month elective BC Children's Hospital: Vancouver, B.C.

-Included exposure to complex neuromuscular/idiopathic/congenital scoliosis. Operative observation included PSIF with SPOs as well as two stage correction with anterior release/fusion + PSIF. Clinic included assessment and brace management of complex deformity

1.1.1.1.1.1.1.8 PAEDIATRIC CLINICAL EXPERIENCE

1.1.1.1.1.1.9 2013/08: 1 Month elective at The Hospital for Sick Children: Toronto, ON.

- Functioned as a Sr. orthopaedic resident: performed numerous orthopaedic procedures as the primary surgeon including guided growth procedures, multiple closed reductions and pinnings of SCFEs, as well as general percutaneous and open treatment of paediatric fractures. Assisted in major oncologic/ reconstruction procedures, complex lower extremity deformity correction.

1.1.1.1.1.1.10 2013/07: 1 Month elective BC Children's Hospital: Vancouver, B.C.

1.1.1.1.1.1.11 -Functioned as a Sr. orthopaedic resident: performed numerous orthopaedic procedures as the primary surgeon including derotational osteotomies, guided growth procedures, soft tissue lengthening/ releases as well as general percutaneous and open treatment of paediatric fractures.

1.1.1.1.1.1.12 2012: 4 Month core rotation LHSC-VH. Drs. Bartley, Carey, Cashin.

1.1.1.1.1.1.13 -Broad paediatric orthopaedic exposure included neuromuscular disorders, paediatric spine and general paediatric orthopaedic practice. Operative exposure included scoliosis, proximal femoral/pelvic osteotomies, hindfoot releases, paediatric trauma and a variety of other general paediatric orthopaedic procedures.

1.1.1.1.1.1.14 **RESEARCH EXPERIENCE**

2015-current Western University, Biomechanics Spine Research. Thompson Engineering/ LHSC-VH. Dr. C. Bailey, Dr K. Gurr, Dr. P Rasoulinejad and Dr. F. Siddiqi.

2014 Western University, Spine Research. Center for critical illness research, LHSC-VH. Dr. C. Bailey, Dr K. Gurr, Dr. P Rasoulinejad and Dr. F. Siddiqi.

2012 Western University, Arthroplasty Research: LHSC-UH/ C-Star at The Dr. Sandy Kirkley Centre for Musculoskeletal Research. Dr. J Howard, Dr. T Vasarhelyi and Julie Todd.

2009 The University of Western Ontario. Spinal Cord Injury Research: Center for critical illness research, LHSC-VH. Dept. of Orthopaedics. Dr. C. Bailey, Dr. H. Hundt, Jennifer Flemming.

2008 The University of Western Ontario. Compartment Syndrome Research: Centre for critical illness research, LHSC-VH. Dept. of Orthopaedics. Dr. D. Sanders, Dr. A. Lawendy.

1.1.1.1.1.1.15 **PUBLICATIONS/PENDING**

- Weeks C, L Somerville, J Phillips, S Ganapathy, J Howard Evaluation of the use of Spinal Epimorph in Total Knee Arthroplasty: a Randomized Control Trial. Publication Pending.
-
- Phillips J, Bailey C, Gurr K, Siddiqi F and Rasoulinejad P. Are Post-operative Pelvic Parameters and Sagittal Imbalance Predictive of Further Lumbar Surgery in Patients with Spinal Stenosis. Publication Pending.
- Ritsma BR, Berger MJ, Charland DA, Khoury MA, Phillips JT, Quon MJ, Strong MJ and Schultz VM. NIPPV: prevalence, approach and barriers to use at Canadian ALS centres. Can J Neurol Sci 2010. 37(1);54-60.

1.1.1.1.1.1.16 **PODIUMS**

2015 Guest lecturer, Schulich School of Medicine: Cervical Spine Trauma

2015 Guest lecturer, Schulich School of Medicine: Thoracic and Lumbar Spine Trauma

2015 Canadian Orthopaedic Association Meeting: Are Post-operative Pelvic Parameters and Sagittal Imbalance Predictive of Further Lumbar Surgery in Patients with Spinal Stenosis?

2014 Western Orthopaedic Resident's Day Presentation: Are Post-operative Pelvic Parameters and Sagittal Imbalance Predictive of Further Lumbar Surgery in Patients with Spinal Stenosis?

2014 Educational Lecture, Division of Orthopaedics, LHSC/SJHC: Value, Outcomes and Cost in Healthcare.

1.1.1.1.1.1.17 2013: Western Resident Research Day Podium: Spinal Epimorph in Total Knee Arthroplasty.

1.1.1.1.1.1.18 2012: Western Resident Research Day Podium: Assessing Pre-operative Mobility in Total Hip Arthroplasty: A SAFE T Database Study.

1.1.1.1.1.1.19 2011: Western Resident Research Day Podium: Compartment Syndrome Causes Systemic Inflammatory Response Syndrome (SIRS) and Remote Organ Injury.

1.1.1.1.1.1.20 **VOLUNTEER EXPERIENCE**

- 2013 Admissions interviewer for 2013 Western CaRMS Orthopaedic match.
- 2009 Admissions interviewer for the class of 2013. Schulich School of Medicine
- 2008 Quadrangle Beautification Project. Landscaping team leader. Schulich School of Medicine
- 2005-2006 Big Brother. Big Brothers of London
- 2005-2006 Alzheimers Outreach Program. McCormick Home of London

1.1.1.1.1.1.21 **AFFILIATIONS**

- College of Physicians and Surgeons of Ontario (CPSO)
- Canadian Medical Protective Association (CMPA)

- American Academy of Orthopaedic Surgeons (AAOS)
- Canadian Medical Association (CMA)
- Ontario Medical Association (OMA)

