

Washington University School of Medicine Digital Commons@Becker

Open Access Publications

2017

Paroxysmal eye–head movements in Glut1 deficiency syndrome

Toni S. Pearson

Washington University School of Medicine in St. Louis

Roser Pons

Columbia University

Kristin Engelstad

Columbia University

Steven A. Kane

Columbia University

Michael E. Goldberg

Columbia University

See next page for additional authors

Follow this and additional works at: https://digitalcommons.wustl.edu/open_access_pubs

Recommended Citation

Pearson, Toni S.; Pons, Roser; Engelstad, Kristin; Kane, Steven A.; Goldberg, Michael E.; and De Vivo, Darryl C., "Paroxysmal eye–head movements in Glut1 deficiency syndrome." *Neurology*.88,17. 1666-1673. (2017).
https://digitalcommons.wustl.edu/open_access_pubs/5871

This Open Access Publication is brought to you for free and open access by Digital Commons@Becker. It has been accepted for inclusion in Open Access Publications by an authorized administrator of Digital Commons@Becker. For more information, please contact engeszer@wustl.edu.

Authors

Toni S. Pearson, Roser Pons, Kristin Engelstad, Steven A. Kane, Michael E. Goldberg, and Darryl C. De Vivo

Paroxysmal eye–head movements in Glut1 deficiency syndrome

OPEN 

Toni S. Pearson, MD*
Roser Pons, MD*
Kristin Engelstad, MS
Steven A. Kane, MD,
PhD
Michael E. Goldberg,
MD
Darryl C. De Vivo, MD

Correspondence to
Dr. Pearson:
tpearson@wustl.edu
or Dr. Pons:
roserpons@med.uoa.gr

ABSTRACT

Objective: To describe a characteristic paroxysmal eye–head movement disorder that occurs in infants with Glut1 deficiency syndrome (Glut1 DS).

Methods: We retrospectively reviewed the medical charts of 101 patients with Glut1 DS to obtain clinical data about episodic abnormal eye movements and analyzed video recordings of 18 eye movement episodes from 10 patients.

Results: A documented history of paroxysmal abnormal eye movements was found in 32/101 patients (32%), and a detailed description was available in 18 patients, presented here. Episodes started before age 6 months in 15/18 patients (83%), and preceded the onset of seizures in 10/16 patients (63%) who experienced both types of episodes. Eye movement episodes resolved, with or without treatment, by 6 years of age in 7/8 patients with documented long-term course. Episodes were brief (usually <5 minutes). Video analysis revealed that the eye movements were rapid, multidirectional, and often accompanied by a head movement in the same direction. Eye movements were separated by clear intervals of fixation, usually ranging from 200 to 800 ms. The movements were consistent with eye–head gaze saccades. These movements can be distinguished from opsoclonus by the presence of a clear intermovement fixation interval and the association of a same-direction head movement.

Conclusions: Paroxysmal eye–head movements, for which we suggest the term aberrant gaze saccades, are an early symptom of Glut1 DS in infancy. Recognition of the episodes will facilitate prompt diagnosis of this treatable neurodevelopmental disorder. **Neurology® 2017;88:1666–1673**

GLOSSARY

Glut1 DS = Glut1 deficiency syndrome; **KD** = ketogenic diet; **VOR** = vestibulo-ocular reflex.

Glut1 deficiency syndrome (Glut1 DS) (OMIM 606777) is a disorder of brain energy metabolism caused by impaired glucose transport into the brain mediated by the glucose transporter Glut1.¹ Classically, patients present in infancy with intractable seizures, acquired microcephaly, developmental delay, intellectual disability, spasticity, ataxia, dystonia, and paroxysmal neurologic events.^{1,2} Patients may present with a benign idiopathic epilepsy-like syndrome.³ They may also present with paroxysmal exertional dyskinesia with or without epilepsy.^{4,5} Despite the phenotypic variability, overlapping features are often present.^{6,7} The disease hallmark is low CSF glucose concentration in association with normoglycemia. The CSF/blood glucose ratio is typically less than 0.4.⁸ The Glut1 defect can be confirmed by a functional in vitro assay that measures glucose uptake in erythrocytes,⁹ and by mutation analysis of the gene encoding the

Supplemental data
at Neurology.org

*These authors contributed equally to this work.

From the Colleen Giblin Research Laboratory (K.E., D.C.D.), Division of Pediatric Neurology, Department of Neurology (T.S.P., R.P.), Department of Ophthalmology, Edward S. Harkness Eye Institute (S.A.K.), Mahoney-Keck Center for Brain and Behavior Research (M.E.G.), Department of Neuroscience (M.E.G.), and the Departments of Neurology, Psychiatry, and Ophthalmology (M.E.G.), Columbia University College of Physicians and Surgeons, New York, NY; Department of Neurology (T.S.P.), Washington University School of Medicine, St. Louis, MO; First Department of Pediatrics (R.P.), National and Kapodistrian University of Athens, Aghia Sofia Hospital, Greece; Kavli Institute for Neuroscience (M.E.G.), Columbia University; and the Division of Neurobiology and Behavior (M.E.G.), New York State Psychiatric Institute, New York.

Go to Neurology.org for full disclosures. Funding information and disclosures deemed relevant by the authors, if any, are provided at the end of the article. The Article Processing Charge was funded by the authors.

This is an open access article distributed under the terms of the Creative Commons Attribution-NonCommercial-NoDerivatives License 4.0 (CC BY-NC-ND), which permits downloading and sharing the work provided it is properly cited. The work cannot be changed in any way or used commercially without permission from the journal.

glucose transporter type 1 (*SLC2A1*).¹⁰ Heterozygous de novo mutations in *SLC2A1* are detected in the majority of patients.^{6,8} Treatment of the nutrient deficiency is based on providing ketone bodies as an alternative brain fuel. Early diagnosis is crucial, since treatment with the ketogenic diet (KD) dramatically improves symptoms and may also improve the long-term outcome.¹¹

Patients with Glut1 DS have paroxysmal abnormal eye movements,^{12–14} and eye movement abnormalities are the first neurologic event in 38% of patients.¹⁵ The eye movements have been tentatively called opsoclonus,¹⁶ but description and characterization of these events is, in fact, lacking. Based on the retrospective analysis of 101 patients with genetically confirmed Glut1 DS and video analysis of the eye movement episodes, we describe the characteristics of the paroxysmal abnormal eye movements in infants with Glut1 DS.

METHODS Video analysis. Home videos from 10 patients were independently reviewed by 2 pediatric neurologists (T.S.P., R.P.) and a pediatric neuro-ophthalmologist (S.A.K.) who generated a consensus description of eye movement findings. We then performed quantitative video analysis on a subset of videos to characterize the time course of eye movements. For this purpose, we selected 30- to 60-second excerpts from 4 episodes from 4 patients, in which the eyes and head were clearly visible in close-up, and used frame-by-frame analysis to manually mark the time of onset of each eye movement (video frame rate: 30 frames per second for 3 videos, 13 frames per second for 1 video).

Retrospective medical record review. Medical records of 101 patients with confirmed Glut1 DS who were evaluated at Columbia University Medical Center between 1989 and 2014 were screened for paroxysmal abnormal eye movements. For all patients who had experienced one or more paroxysmal eye movement events, the following data related to events were analyzed: (1) age at onset, (2) direction and alignment of eye movements, (3) velocity, (4) duration, (5) level of alertness, (6) associated head movements, (7) EEG correlation, (8) frequency, (9) time course, (10) age at resolution, (11) precipitating factors, and (12) relieving factors. Response to the KD or to antiepileptic medication was assessed when applicable.

Abnormal eye movements associated with loss of consciousness, apnea, head drop, or abnormal focal or generalized myoclonic, tonic, or clonic movements were excluded. Episodes described as eye flutter without further characterization were also excluded.

RESULTS Description of 3 representative cases. Patient 1. A 10-year-old boy developed episodes of unusual eye movements, associated with nodding head movements that appeared to follow the direction of the eyes, at age 1 month (video 1 at Neurology.org).

During the episodes, he was awake and at times responded by smiling, and at other times appeared upset. Episodes seemed to be precipitated by excitement and typically lasted 10–20 minutes. Rarely, episodes lasted up to 1 hour. A peak frequency of 10–15 episodes per month occurred at age 4–5 months. Episode frequency decreased towards the end of infancy and ceased by age 8 years.

The patient developed intractable epilepsy at age 3 months. His first seizures were myoclonic and atonic. At age 2 years, he developed absence seizures, and at age 3 years, generalized tonic seizures. He experienced other paroxysmal events including episodic choreoathetosis, limb dystonia associated with crying and drooling, and episodes of lethargy and generalized paralysis.

The patient was started on a KD at age 7 years. His seizures, paroxysmal neurologic events, motor and language skills, attention span, and mood all improved.

Brain MRI was normal and investigations for occult neuroblastoma were negative. Glut1 DS was diagnosed at age 10 years (table 1, patient 1). Examination at age 10 years revealed a head circumference at the 25th percentile, lower limb spasticity, and cerebellar dysfunction with dysarthria, limb dysmetria, and a mixed spastic-ataxic gait.

Patient 2. A 10-year-old-girl had her first episode of unusual eye movements at age 14 weeks. The 3-minute episode began with crossing of the eyes, followed by repeated eye movements with head turns. She then had 14 more episodes before age 15 months, each lasting 1–10 minutes with preserved alertness. Her mother described the episodes as follows: “it’s as if she’s watching something whiz past her. She doesn’t turn her head in a repetitive motion or have a pattern. It seems more like she’s turning her head to try to focus her eyes on something” (video 2). The episodes seemed to improve with feeding.

At age 16 months, the patient had 3 brief generalized tonic-clonic seizures, which responded to carbamazepine. The paroxysmal eye movements also subsided, although she had 7 further episodes, the last at age 23 months.

Due to the abnormal eye movements, at age 27 months the patient was investigated for a possible diagnosis of opsoclonus-myoclonus syndrome. Lumbar puncture demonstrated low CSF glucose. The diagnosis of Glut1 DS was subsequently confirmed by erythrocyte glucose uptake assay and *SLC2A1* analysis (table 1, patient 2).

The KD was initiated at age 29 months. The patient had no further seizures and anticonvulsant therapy was discontinued at age 3.5 years. At age 10 years, she has mild ataxia and difficulties with motor coordination, learning, and attention.

Table 1 Clinical characteristics of 18 patients with paroxysmal eye-head movements

Patient	Sex	First symptom	Onset of eye movements, age, mo	Onset of seizures, age, mo	Age at diagnosis, mo	CSF glucose, mg/dL	CSF:serum glucose ratio	RBC 3-OMG uptake, %	SLC2A1 mutation type	Clinical severity ^a
1	M	Eye movements	1	3	86	24	0.30	70	Missense	Moderate
2	F	Eye movements	3	15	27	28	0.35	66	Missense	Mild
3	M	Eye movements	4	—	78	34	0.39	43	Missense	Mild
4	F	Eye movements	3	7	8	27	0.34	45	Frameshift	Mild
5	F	Eye movements	2	3.5	3.5	27	0.33	43	Missense	Severe
6	F	Eye movements + seizures	3	3	26	32	0.43	59	Insertion	Moderate
7	M	Eye movements	2	—	90	35	0.40	45	Insertion	Moderate
8	M	Eye movements	6	9	45	36	0.49	59	Missense	Mild
9	F	Seizure	1.5	0.5	77	37	—	—	Frameshift	Moderate
10	M	Eye movements	<1	8	120	—	—	52	Missense	Moderate
11	M	Eye movements	6	13	19	—	—	38	Splice site	—
12	M	Eye movements	3	24	96	30	0.37	50	Missense	Severe
13	F	Eye movements	2	18	95	32	—	—	—	—
14	F	Eye movements + seizures	5	5	16	26	0.30	40	Frameshift	Moderate
15	M	Seizure	1.5	1	94	37	0.38	51	Missense	Moderate
16	M	Seizure	8	4	30	31	—	—	Deletion	Moderate
17	F	Eye movements + seizures	<1	<1	30	29	0.36	56	Frameshift	Moderate
18	F	Eye movements	3	18	41	33	0.38	59	Splice site	Severe

Abbreviation: RBC 3-OMG = red blood cell 3-O-methyl-glucose.

^aClinical severity rating based on Columbia Neurologic Score.⁹

Patient 3. A 6-year-old boy experienced, at age 4 months, an episode of abnormal eye movements that his parents likened to “someone following a fly.” He had further episodes approximately once per month during the first year of life. The episodes lasted less than 1 minute and occurred towards the end of the day when he was tired. As he became older, he complained of dizziness during the episodes without associated nausea, vomiting, or headaches. The events’ frequency gradually decreased, and at age 5 years he had his last episode. He never had clinical seizures. EEGs were normal on 2 occasions.

On examination at age 6 years, head circumference was between the 3rd and 10th percentiles. The patient was restless, distractible, and impulsive, but cooperative and able to follow simple instructions. He had lower limb spasticity and hyperreflexia, mild dysarthria, truncal ataxia, intention tremor, poor coordination, and difficulty carrying out complex motor tasks. The diagnosis of Glut1 deficiency was confirmed by the finding of low CSF glucose concentration, reduced erythrocyte glucose uptake, and *SLC2A1* analysis (table 1, patient 3).

Video analysis. We reviewed home video examples of 18 individual episodes from 10 patients.

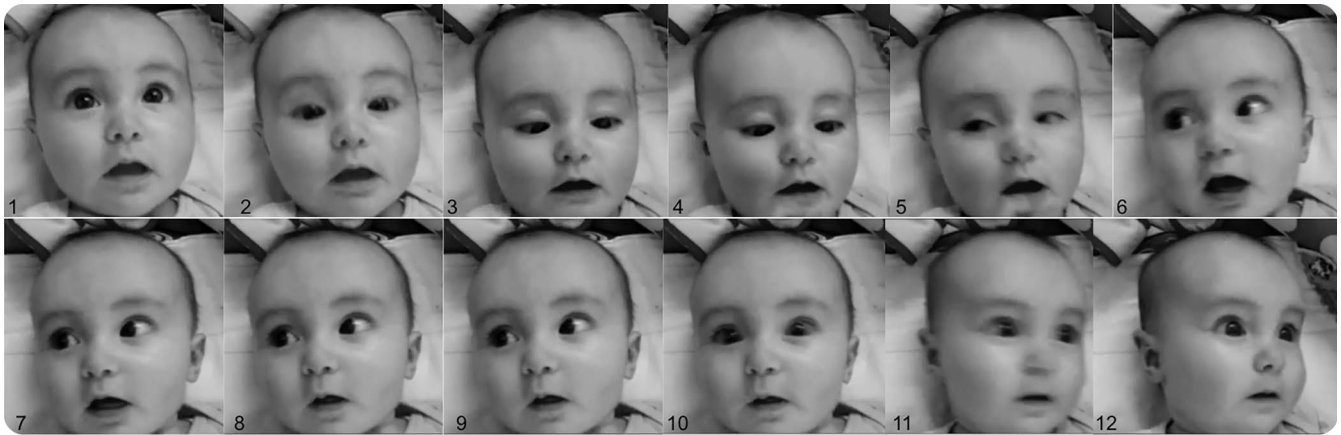The episodes were characterized by frequent movements of the eyes and head. Several features were consistent across all patients. The eye movements were rapid, consistent with saccades, and were followed by epochs of fixation as if they were normal gaze shifts. Movements occurred in multiple directions, were clearly separated in time by intervening periods of fixation, and were often accompanied by a head movement in the same direction (figure 1, videos 1–3). In particular, we never observed 2 eye movements in immediate succession without a brief period of fixation between them.

Eye movements were usually conjugate, but in many episodes the eyes appeared intermittently dysconjugate. Dysconjugate gaze was characterized by convergence of either one or both eyes (video 2, segment 1), giving a temporary cross-eyed appearance.

In some cases, the head movements were large in amplitude and prominent (video 3), while in others, they were subtle. There was only 1 video (10 seconds in duration) in which we did not observe any head movements.

The patients were awake during the episodes in all cases. Responsiveness was difficult to judge in reliably very young infants, but older infants clearly demonstrated preserved consciousness and the ability to respond to their parents during the episode (video 2, segment 3).

Figure 1 Eye-head gaze saccades



In each of these 3 gaze shifts, movement of the eyes is followed by a head movement in the same direction. There is a period of fixation between eye movements (total time: 1.8 seconds, interval between frames: 150 ms).

Frame-by-frame video analysis of 4 individual patient episodes revealed the time course of movements in further detail. The timing of eye movements was irregular and there was a clear interval between saccades (figure 2A). For the vast majority of movements, the interval between saccades ranged from 200 to 800 ms. The pattern of distribution of intersaccadic intervals, with a peak at 400–500 ms, was markedly similar for all 4 patients (figure 2B).

Frame-by-frame analysis also demonstrated that initiation of the eye movements usually occurred first, followed by head turning in the same direction 30–60 ms later (figure 1, panels 5–6, 10–11). Fixation of eye gaze on an apparent target was often maintained during the head movement phase (suggesting active vestibulo-ocular reflex [VOR] during this phase of the movement). During larger amplitude head movements, eye position in the head remained constant during the head movement phase (suggesting VOR suppression) (video 3). These movement features are consistent with shifts of gaze.

Retrospective medical record review. Paroxysmal abnormal eye movements were documented in 32 of 101 patients (32%) with Glut1 DS. Words used by parents or doctors to describe the movements included, in decreasing order of frequency, the following: eye rolling (n = 11); strange, unusual, or funny (n = 5); chaotic (n = 4); opsoclonus (n = 4); searching, “like someone following a fly” or “like following an object visually” (n = 3); darting (n = 3); jerky or jumping (n = 3); uncontrollable (n = 2); oscillating (n = 2); repetitive (n = 2); roving (n = 1); triangular; and up and down eye movements (n = 1).

In 18/32 patients, the abnormal eye movements were described in the medical chart in sufficient detail to suggest the depiction of a consistent type of

episode. Only episodes of these 18 patients are described further below (table 2).

The mean age at onset of eye movement episodes was 3.1 months (range, neonatal period to 8 months). The first episode occurred before age 6 months in 15 of 18 patients.

Eye movement speed was subjectively reported as rapid in 7 patients and slow in 2. Velocity was not reported in the remaining patients. Associated head movements were documented in 7 patients: head nodding in 2, head back and forth in 2, and head turning in 1. The parents of 2 patients specifically described the head turning in the direction of the eyes.

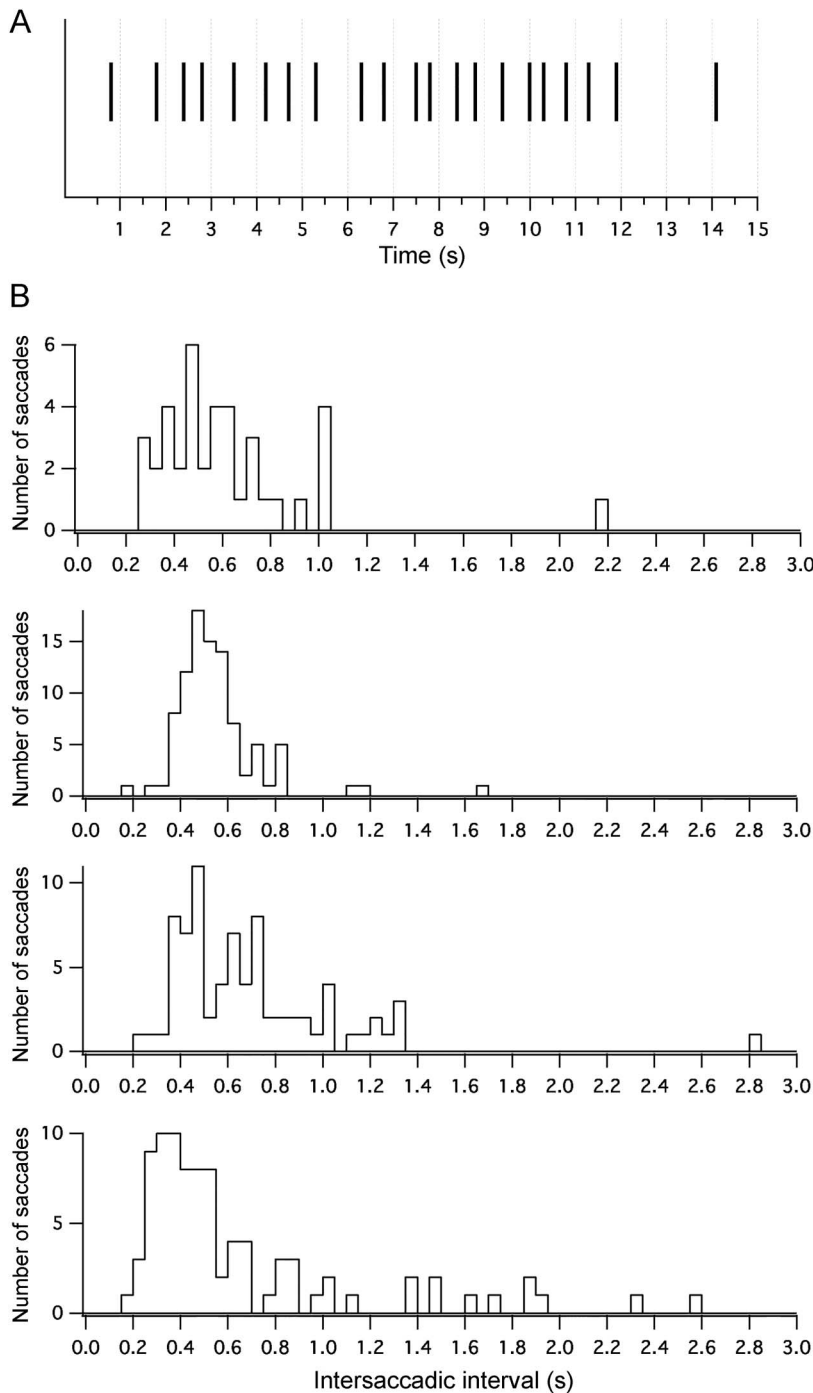
None of the patients lost consciousness during their episodes. In 3 patients there was a questionable alteration of alertness described as “relatively unresponsive,” “zoned out,” or “detached.”

Event duration was typically brief (<5 minutes in 9 patients and <1 minute in 4). One patient experienced rare episodes lasting up to 1 hour. Episode frequency was variable, ranging from 1 or 2 episodes in 2 patients to 10 episodes per day in 1 patient. Among patients for whom the long-term course of eye movement episodes was documented (n = 8), the episodes disappeared between 3 and 6 years of age in 7 patients, and were still present at age 8 years in 1 patient (table 2).

Potential precipitating factors reported by parents included fatigue, hunger, excitement, and being placed on the back. Feeding was reported to be a possible ameliorating factor in 1 patient.

In 5 patients, episodes were captured during continuous EEG monitoring and had no EEG correlate. In 6 further patients, an EEG was performed around the time of the occurrence of the abnormal eye movements. Epileptiform discharges were detected in only 1 patient, with no clinical correlate.

Figure 2 Timing of eye movements



(A) Time of onset of eye saccades in a single patient over a 15-second period (excerpt from video 3). Saccades occur at variable intervals. (B) Distribution of intervals between onset of saccades in 4 individual patients. Bins are 50 ms. Top graph is the same patient as in A (number of eye movements per patient, top to bottom: 40, 94, 78, 90; total = 302).

Improvement in eye movement episodes following initiation of the KD was documented in 2 patients. Episodes had resolved spontaneously prior to initiation of the diet in 3 patients, and in other cases, the response of these episodes to the diet was not specifically documented. Six patients were treated with antiepileptic medications: in 1 patient, the episodes

improved, in 3 the response was unclear, and in 2 there was no benefit.

Sixteen patients in our cohort of 18 had seizures. Of those, 10 of 16 patients experienced eye movement episodes before their first seizure. The latency from onset of eye movements to first seizure ranged from 1 to 21 months (table 1) in those 10 patients.

DISCUSSION In this report, we describe characteristic, brief episodes of eye-head movements that occur in one-third of infants with Glut1 DS. These movements are rapid, multidirectional, and often accompanied by head movements in the same direction. The movements are always clearly separated in time by intervals typically ranging from 200 to 800 ms, corresponding to an average eye movement frequency of approximately 2 per second. These features are most consistent with saccadic eye-head gaze shifts, which are characterized by the presence of intersaccadic intervals, aligned direction of the eye and head movement, and optional presence of the head component. Paroxysmal eye-head gaze saccades of this type may be a specific feature of cerebral glucose insufficiency in infancy.

The eye movements of Glut1DS have been described as opsoclonus. However, unlike the eye movements that we observed, the eye movements of opsoclonus have no intermovement fixation interval, and are not associated with a same-direction head movement. The episodes we observed can also be distinguished from other eye movement disorders that may occur in infancy, including infantile nystagmus, ocular flutter, and spasmus nutans.

The pathophysiologic mechanism underlying paroxysmal eye-head gaze saccades in Glut1 DS is unknown. Gaze shifts normally serve the function of bringing an object of interest, detected in the peripheral visual field, to the fovea, where it can be seen in greater detail. In the mature nervous system, the control of gaze involves both active signals to drive the eyes and active signals to suppress eye movements and therefore facilitate fixation.¹⁷ Gaze shifts often involve both eye saccades and head movements. The signals for head and eye movements originate in the paramedian pontine reticular formation (for horizontal eye movements) and the mesencephalic reticular formation (for vertical eye movements).¹⁸ A network including the superior colliculus,¹⁹ the frontal eye field,²⁰ and the posterior parietal cortex^{21,22} then specifies the target for a possible gaze shift and entrains the brainstem gaze mechanism. Simultaneously a hierarchy of areas suppresses eye movements: the nucleus of the dorsal raphe inhibits the brainstem saccade generators,²³ the substantia nigra pars reticulata suppresses the superior colliculus,²⁴ and neurons in the frontal eye field specify objects

Table 2 Features of eye movement episodes reported in the medical chart

Patient	Onset, mo	Eye movement description	Direction, alignment	Velocity	Head movement	Alert?	Duration, min	Frequency	Precipitant	Resolution/age, y	Response to KD	Response to AED
1	1	Uncontrollable, chaotic, "opsoclonus"	All	Rapid	Nodding, bobbing, following direction of eyes	Yes	5-60	10-15/mo	Excitement	Yes/5	NA	Unclear
2	3	As if watching something whiz past	All	Rapid	Head jerks, head turning	Yes	1-10	1-2/mo	Preprandial, fatigue	Yes/2	NR	Yes
3	4	Like following a fly	All	Rapid	No	Yes	<1	1/2 mo	Fatigue	Yes/6	NA	NA
4	3	Darting, chaotic	Horizontal, dysconjugate	Rapid	Yes	Yes	3-5	3/mo	NR	Yes/3	Yes	NA
5	2	Triangular	All	NR	NR	Yes	NR	1 episode	NR	NR	NA	NA
6	3	Darting	All	Rapid	NR	Yes	1-2	NR	NR	NR	NA	NA
7	2	Rolling	NR	NR	Yes	Yes	1-4	1/d-wk	NR	NR	NA	NA
8	6	Chaotic, rolling	NR	Rapid	NR	Yes	<1	2 episodes	NR	NR	NA	NA
9	1.5	"Opsoclonus"	NR	NR	NR	Yes	NR	1/1-2 mo	NR	Yes/3	NA	NA
10	<1	Chaotic	NR, conjugate	NR	NR	Yes	1-3	NR	NR	NR	NA	NA
11	6	Strange	NR, conjugate	Rapid	Yes	Yes	2	NR	NR	NR	NA	No
12	3	Jumping, "opsoclonus"	Horizontal, NR	Rapid, Slow	Back and forth	Yes	<1-5	NR	Lying on back	NR	NA	Unclear
13	2	Repetitive	NR	NR	Yes	Yes	NR	1/mo	NR	No ^a	NR	NR
14	5	Repetitive	Vertical	NR	NR	Relatively unresponsive	<1	1/mo	Preprandial, fatigue	Yes/2	NA	NA
15	1.5	"Opsoclonus"	All	Slow	Nodding	Yes	2-3	2/wk	Chocolate	NR	Yes	NA
16	8	Rolling, jerky	Horizontal	NR	NR	Yes	Brief	NR	Lying on back	Yes/4	NA	NA
17	<1	Like following a fly	NR, dysconjugate	NR	Back and forth	Zoned out	NR	NR	NR	NR	NR	No
18	3	Rolling, like following an object visually	All	NR	NR	Detached	NR	NR	NR	NR	NR	No

Abbreviations: AED = antiepileptic drug; KD = ketogenic diet; NA = not applicable; NR = not reported.

^aEpisodes still occurring at age 8 years.

in the visual field that are inappropriate targets for saccades.²⁵ Just like the aberrant spontaneous saccades in Glut1 DS, normal saccades are often dysconjugate when they involve shifts in vergence angle.

Our patients' episodes were characterized by apparently involuntary repeated gaze saccades. Symptoms almost always emerged during the first 6 months of life, a time when the visual system is undergoing rapid maturation, and the ability to suppress reflexive saccades to visual stimuli develops.²⁶ Because neurons in the dorsal raphe and the substantia nigra pars reticulata discharge at high rates except during eye movements, it is possible that their activity is compromised by the glucose deficiency of Glut1 DS, allowing the release of inappropriate saccades. Insufficient energy supply to meet demand is one mechanism that has been postulated to underlie other paroxysmal events in Glut1 DS.⁵ Consistent with this hypothesis, eye movement episodes were precipitated by fatigue, excitement, or fasting, and responded favorably to the KD in some patients.

The possibility that these episodes represent a type of focal seizure that is not detectable by scalp EEG cannot be fully excluded, but is unlikely. Preserved alertness, absence of other typical clinical manifestations of seizures, and normal ictal EEG suggest that these events are nonepileptic. The majority of patients had coexisting epilepsy, which manifested at a similar age to the eye movement episodes in 10 patients (table 1). In 6 patients, the first seizure did not occur until 7–21 months after the onset of the eye movement episodes.

Eye movement episodes emerged before age 6 months in 83% of our patients. Among the 8 patients for whom the course of the episodes was known, events decreased in frequency by late infancy, and disappeared in all but one patient by age 8 years. Thus these episodes represent an age-dependent manifestation of the disease that is likely related to a specific stage of brain development. Other features of Glut1 DS also occur in an age-dependent manner: for example, seizures tend to be more prominent in infancy and childhood, and improve or even disappear by adulthood, while dystonia and other paroxysmal movement disorders tend to develop later in childhood or during adolescence.^{11,27}

Verbal description of the eye movement episodes by parents and doctors was highly variable. Some descriptions were strikingly vivid and accurate, but many were imprecise. For example, the movements were often described as eye rolling in the medical chart, but video review clearly demonstrated that the eye movements were rapid. Associated head movements (nodding, bobbing, or back and forth) were documented in only 50% of patients, but head movements were present in all but 1 of the 18 video

episodes that we reviewed. This highlights the diagnostic challenge posed by rare and unusual symptoms for which there is not a recognized medical term.

The retrospective nature of our study has some limitations. For example, our finding of a 32% incidence of eye movement episodes in patients with Glut1 DS may be an underestimate, since patients were not systematically questioned about a history of these specific symptoms. Also, data about the episodes' long-term outcome and response to treatment were not available for all patients, and these details warrant future clarification.

Brief paroxysmal episodes of eye and head movements, for which we propose the term aberrant gaze saccades, are a characteristic and early feature of Glut1 DS during infancy. Failure to meet energy demand is a likely pathophysiologic mechanism, but the precise underlying neuronal basis remains unknown. Since early diagnosis and prompt implementation of the KD is believed to improve the long-term prognosis of patients with Glut1 DS, it is vital that neurologists recognize these episodes as an early diagnostic clue to the disease.

AUTHOR CONTRIBUTIONS

Toni Pearson: study concept and design, acquisition of data, analysis and interpretation of data. Roser Pons: study concept and design, acquisition of data, analysis and interpretation of data. Kristin Engelstad: acquisition of data, critical revision of manuscript. Steven Kane: analysis and interpretation of data. Michael Goldberg: analysis and interpretation of data, critical revision of manuscript for intellectual content. Darryl De Vivo: critical revision of manuscript for intellectual content.

ACKNOWLEDGMENT

The authors thank the Glut1 Deficiency Foundation, Milestones for Children, Hope for Children Research Foundation, Fung family gift, Dr. Pietro Mazzoni for sharing video analysis software, and the families who shared their observations and experiences.

STUDY FUNDING

This work was supported in part by the Crofoot/Walz families.

DISCLOSURE

The authors report no disclosures relevant to the manuscript. Go to Neurology.org for full disclosures.

Received August 23, 2016. Accepted in final form January 27, 2017.

REFERENCES

1. De Vivo DC, Trifiletti RR, Jacobson RI, Ronen GM, Behmand RA, Harik SI. Defective glucose transport across the blood-brain barrier as a cause of persistent hypoglycorrhachia, seizures, and developmental delay. *N Engl J Med* 1991;325:703–709.
2. Pons R, Collins A, Rotstein M, Engelstad K, De Vivo DC. The spectrum of movement disorders in Glut-1 deficiency. *Mov Disord* 2010;25:275–281.
3. Scheffer IE. GLUT1 deficiency: a glut of epilepsy phenotypes. *Neurology* 2012;78:524–525.
4. Suls A, Dedeken P, Goffin K, et al. Paroxysmal exercise-induced dyskinesia and epilepsy is due to mutations in SLC2A1, encoding the glucose transporter GLUT1. *Brain* 2008;131:1831–1844.

5. Weber YG, Storch A, Wuttke TV, et al. GLUT1 mutations are a cause of paroxysmal exertion-induced dyskinesias and induce hemolytic anemia by a cation leak. *J Clin Invest* 2008;118:2157–2168.
6. Leen WG, Klepper J, Verbeek MM, et al. Glucose transporter-1 deficiency syndrome: the expanding clinical and genetic spectrum of a treatable disorder. *Brain* 2010;133:655–670.
7. Pearson TS, Akman C, Hinton VJ, Engelstad K, De Vivo DC. Phenotypic spectrum of glucose transporter type 1 deficiency syndrome (Glut1 DS). *Curr Neurol Neurosci Rep* 2013;13:342.
8. Wang D, Pascual JM, Yang H, et al. Glut-1 deficiency syndrome: clinical, genetic, and therapeutic aspects. *Ann Neurol* 2005;57:111–118.
9. Yang H, Wang D, Engelstad K, et al. Glut1 deficiency syndrome and erythrocyte glucose uptake assay. *Ann Neurol* 2011;70:996–1005.
10. Seidner G, Alvarez MG, Yeh JI, et al. GLUT-1 deficiency syndrome caused by haploinsufficiency of the blood-brain barrier hexose carrier. *Nat Genet* 1998;18:188–191.
11. Alter AS, Engelstad K, Hinton VJ, et al. Long-term clinical course of Glut1 deficiency syndrome. *J Child Neurol* 2015;30:160–169.
12. De Vivo DC, Leary L, Wang D. Glucose transporter 1 deficiency syndrome and other glycolytic defects. *J Child Neurol* 2002;17(suppl 3):3S15–3S23; discussion 13S24–15.
13. Friedman JR, Thiele EA, Wang D, et al. Atypical GLUT1 deficiency with prominent movement disorder responsive to ketogenic diet. *Mov Disord* 2006;21:241–245.
14. Ito Y, Takahashi S, Kagitani-Shimono K, et al. Nationwide survey of glucose transporter-1 deficiency syndrome (GLUT-1DS) in Japan. *Brain Dev* 2015;37:780–789.
15. Akman CI, Yu J, Alter A, Engelstad K, De Vivo DC. Diagnosing glucose transporter 1 deficiency at initial presentation facilitates early treatment. *J Pediatr* 2016;171:220–226.
16. Appavu B, Mangum T, Obeid M. Glucose transporter 1 deficiency: a treatable cause of opsoclonus and Epileptic myoclonus. *Pediatr Neurol* 2015;53:364–366.
17. Goldberg ME, Walker MF. The control of gaze. In: Kandel ER, Schwartz JH, Jessell TM, Siegelbaum SA, Hudspeth AJ, Mack S, eds. *Principles of Neural Science*. New York: McGraw Hill; 2012:894–916.
18. Buttner-Ennever JA, Buttner U. Neuroanatomy of the oculomotor system: the reticular formation. *Rev Oculomot Res* 1988;2:119–176.
19. Gandhi NJ, Katnani HA. Motor functions of the superior colliculus. *Annu Rev Neurosci* 2011;34:205–231.
20. Bruce CJ, Goldberg ME. Primate frontal eye fields: I: single neurons discharging before saccades. *J Neurophysiol* 1985;53:603–635.
21. Bisley JW, Goldberg ME. Attention, intention, and priority in the parietal lobe. *Annu Rev Neurosci* 2010;33:1–21.
22. Bracewell RM, Mazzoni P, Barash S, Andersen RA. Motor intention activity in the macaque's lateral intraparietal area: II: changes of motor plan. *J Neurophysiol* 1996;76:1457–1464.
23. Buttner-Ennever JA, Cohen B, Pause M, Fries W. Raphe nucleus of the pons containing omnipause neurons of the oculomotor system in the monkey, and its homologue in man. *J Comp Neurol* 1988;267:307–321.
24. Hikosaka O, Wurtz RH. Visual and oculomotor functions of monkey substantia nigra pars reticulata: IV: relation of substantia nigra to superior colliculus. *J Neurophysiol* 1983;49:1285–1301.
25. Hasegawa RP, Peterson BW, Goldberg ME. Prefrontal neurons coding suppression of specific saccades. *Neuron* 2004;43:415–425.
26. Johnson MH. The inhibition of automatic saccades in early infancy. *Dev Psychobiol* 1995;28:281–291.
27. Leen WG, Taher M, Verbeek MM, Kamsteeg EJ, van de Warrenburg BP, Willemsen MA. GLUT1 deficiency syndrome into adulthood: a follow-up study. *J Neurol* 2014;261:589–599.

Neurology.org Offers Important Information to Patients and Their Families

The *Neurology*[®] Patient Page provides:

- A critical review of ground-breaking discoveries in neurologic research that are written especially for patients and their families
- Up-to-date patient information about many neurologic diseases
- Links to additional information resources for neurologic patients

All *Neurology* Patient Page articles can be easily downloaded and printed, and may be reproduced to distribute for educational purposes. Click on the 'Patients' link on the home page (Neurology.org) for a complete index of Patient Pages.

Neurology[®]

Paroxysmal eye–head movements in Glut1 deficiency syndrome

Toni S. Pearson, Roser Pons, Kristin Engelstad, et al.

Neurology 2017;88;1666-1673 Published Online before print March 24, 2017

DOI 10.1212/WNL.0000000000003867

This information is current as of March 24, 2017

Updated Information & Services	including high resolution figures, can be found at: http://www.neurology.org/content/88/17/1666.full.html
Supplementary Material	Supplementary material can be found at: http://www.neurology.org/content/suppl/2017/03/24/WNL.0000000000003867.DC1
References	This article cites 26 articles, 6 of which you can access for free at: http://www.neurology.org/content/88/17/1666.full.html##ref-list-1
Subspecialty Collections	This article, along with others on similar topics, appears in the following collection(s): All Epilepsy/Seizures http://www.neurology.org/cgi/collection/all_epilepsy_seizures All Pediatric http://www.neurology.org/cgi/collection/all_pediatric Developmental disorders http://www.neurology.org/cgi/collection/developmental_disorders Metabolic disease (inherited) http://www.neurology.org/cgi/collection/metabolic_disease_inherited Ocular motility http://www.neurology.org/cgi/collection/ocular_motility
Permissions & Licensing	Information about reproducing this article in parts (figures, tables) or in its entirety can be found online at: http://www.neurology.org/misc/about.xhtml#permissions
Reprints	Information about ordering reprints can be found online: http://www.neurology.org/misc/addir.xhtml#reprintsus

Neurology® is the official journal of the American Academy of Neurology. Published continuously since 1951, it is now a weekly with 48 issues per year. Copyright © 2017 The Author(s). Published by Wolters Kluwer Health, Inc. on behalf of the American Academy of Neurology. All rights reserved. Print ISSN: 0028-3878. Online ISSN: 1526-632X.

