



Title	Otologic and Rhinologic Manifestations of Eosinophilic Granulomatosis with Polyangiitis
Author(s)	Nakamaru, Yuji; Takagi, Dai; Suzuki, Masanobu; Homma, Aya; Morita, Shinya; Homma, Akihiro; Fukuda, Satoshi
Citation	Audiology & neuro-otology, 21(1), 45-53 https://doi.org/10.1159/000442040
Issue Date	2016-03
Doc URL	http://hdl.handle.net/2115/64630
Rights	This is the peer-reviewed but unedited manuscript version of the following article: <i>Audiol Neurotol</i> 2016;21:45-53 (DOI:10.1159/000442040). The final, published version is available at http://www.karger.com/?doi=10.1159/000442040
Type	article (author version)
File Information	AudiolNeuro-Otol21_45.pdf



[Instructions for use](#)

Otologic and rhinologic manifestations of Eosinophilic Granulomatosis with Polyangiitis (EGPA)

Yuji Nakamaru, MD, PhD; Dai Takagi, MD, PhD; Masanobu Suzuki, MD; Aya Homma, MD; Shinya Morita, MD; Akihiro Homma, MD, PhD; and Satoshi Fukuda, MD, PhD

Department of Otolaryngology-Head and Neck Surgery, Hokkaido University Graduate School of Medicine, Sapporo, Japan.

CORRESPONDING AUTHOR

Yuji Nakamaru

Department Otolaryngology-Head and Neck Surgery, Hokkaido University Graduate School of Medicine, West 7 North 15 Sapporo 060-8638, Japan

Telephone: +81-11-707-3387, Fax: +81-11-717-7566

E-mail: nmaru@med.hokudai.ac.jp

Key words: Eosinophilic Granulomatosis with Polyangiitis, Churg-Strauss syndrome, vasculitis, EGPA

Short running title: Otologic and rhinologic manifestations of EGPA

Financial Support: None

Conflict of Interest: No conflicts of interest exist for any author

Abstract

Background: Eosinophilic granulomatosis with polyangiitis (EGPA) is a systemic autoimmune disease that manifests as asthma, recurrent sinusitis, and peripheral eosinophilia. In this study, we investigated the clinical features of the ear and nasal manifestations of EGPA in comparison with those of granulomatosis with polyangiitis (GPA).

Materials and Methods: Twenty-one patients diagnosed with EGPA were studied. The frequency of otologic manifestations, degree of hearing loss and frequency of nasal symptoms were assessed. The onset of ear symptoms, sinusitis and asthma in patients with EGPA were also examined.

Results: Eleven patients (52.4%) with EGPA demonstrated otologic symptoms. The EGPA patients commonly presented mild to moderate mixed or sensorineural hearing loss. The pattern of hearing loss was mainly flat and all but one patient achieved complete remission from their hearing impairments. Eighteen patients (85.7%) with EGPA demonstrated nasal symptoms. Patients with EGPA showed a significantly higher incidence of nasal polyps than did those with GPA. The median Lund and Mackey scoring system (LMS) score was 13.7 for patients with EGPA, and the ethmoid sinus shadows were more severe than those of the maxillary sinus. Most ear

symptoms associated with EGPA were observed after definitive diagnosis, although sinusitis and asthma tended to manifest themselves before diagnosis. There were significant differences between the onset of ear symptoms and those of asthma and sinusitis.

Conclusion: As over 80% of patients with EGPA had nasal symptoms and over half had ear symptoms, otolaryngologists should be aware of this disease. Recognition of the characteristic ear and nasal symptoms are thought to be particularly important to the early diagnosis of EGPA.

Introduction

Eosinophilic granulomatosis with polyangiitis (EGPA) is a rare autoimmune small-vessel vasculitis associated with asthma, recurrent sinusitis, and peripheral eosinophilia[Bacciu et al., 2006; Vaglio et al., 2013]. Histologically, EGPA manifests as tissue eosinophilia, necrotizing vasculitis, and eosinophilic granulomatous inflammation. As a proportion of EGPA patients are positive for anti-neutrophil cytoplasmic antibodies (ANCA), this disease has been included in ANCA-associated vasculitis (AAV) together with granulomatosis with polyangiitis (GPA, formerly Wegener's granulomatosis) and microscopic polyangiitis.[Jennette et al., 1994] Churg and Strauss first reported this disease as “allergic angiitis and granulomas” in 1951[Churg and Strauss, 1951]. This disease was thereafter referred to as Churg-Straus syndrome for many years until 2012, when the name was changed to EGPA in the Revised International Chapel Hill Consensus Conference Nomenclature of Vasculitides as part of the phasing out of eponyms[Jennette et al., 2013].

EGPA shows a characteristic onset pattern. Patients with recurrent sinusitis and/or adult onset asthma for many years suddenly develop pronounced eosinophilia and other vasculitis symptoms such as fever, weight loss, peripheral neuropathy, and lung infiltrates. It has also been reported that about three-quarters of EGPA patients

demonstrate ENT involvement[Bacciu et al., 2006]. However, due to its rarity, there have only been a small number of reports on the otolaryngological manifestations of EGPA[Bacciu et al., 2006; Bacciu et al., 2008; Ishiyama and Canalis, 2001; Srouji et al., 2008]. As EGPA commonly affects the ears and nasal region, otolaryngologists should be aware of this disease and make a diagnosis of EGPA in its early stage.

The objective of this study was to report the clinical features of EGPA, focusing on its otologic and rhinologic manifestations, to provide information to assist otolaryngologists in the early diagnosis of this disease.

Patients and methods

Patients

Patients diagnosed with EGPA at the Department of Otolaryngology, Hokkaido University between 2007 and 2014 were studied. Patients with granulomatosis with polyangiitis (GPA, formerly Wegener's granulomatosis) were also studied to clarify the symptoms of EGPA. The diagnosis of EGPA and GPA were made on the basis of the criteria set by the American College of Rheumatology 1990 [Leavitt et al., 1990; Masi et al., 1990].

This study was approved by the Institutional Review Board of the Hokkaido University Hospital for Clinical Research.

Data acquisition and Examinations

In this retrospective study we collected data for all patients from their medical records. All patients underwent multidisciplinary evaluations by specialists in dermatology, nephrology, pulmonary, ophthalmology, neurology, gastroenterology and rheumatology according to their symptoms. The frequency of organ involvement, type of otologic and rhinologic manifestations, degree of hearing loss and frequency of nasal

symptoms, such as crust formation in the nasal cavity, nasal septum perforation and saddle nose, and sinusitis were assessed.

The diagnosis of chronic sinusitis was based on the Clinical Practice Guidelines of the American Academy of Otolaryngology – Head and Neck Surgery [Meltzer et al., 2004; Rosenfeld et al., 2007]. Endoscopy of the nose and ear as well as computed tomography (CT) was used for otorhinologic examinations.

Audiometry was performed by experienced audiologists using a pure tone audiometer (AA-76; RION Co., Japan) in a silent cabin. The pure-tone thresholds for each ear were determined at frequencies of 125, 250, 500, 1000, 2000, 4000 and 8000 hertz (Hz) for air conduction, and at 250, 500, 1000, 2000 and 4000 Hz for bone conduction with masking as appropriate. The air- and bone-conduction pure-tone averages (PTAs) and mean air-bone gaps (ABGs) were calculated based on pure-tone audiograms using the American Academy of Otolaryngology Head and Neck Surgery (AAO-HNS) Committee on Hearing and Equilibrium guidelines [Stachler et al., 2012]. Pure-tone thresholds were obtained at thresholds of 500, 1000, 2000 and 3000 Hz and used to calculate the PTAs. If 3000 Hz was not tested, 4000 Hz was substituted for the calculation of the PTAs. Recovery rate was assessed using the “Clinical Practice Guideline: Sudden Hearing Loss” published by the AAO-HNS in 2012. [Stachler et al.,

2012]

The severity of hearing loss was categorized into 4 grades based on the worst point of air-conduction PTA: mild (an average of hearing threshold of is 20-40 dB HL), moderate (an average of hearing threshold of 41-70 dB HL), severe (an average of hearing threshold of 71-95 dB HL), and profound (an average of hearing threshold of 96 dB HL or more)[Mazzoli et al., 2003].

The pure-tone audiogram patterns were categorized into 4 types using the classification scheme of Mazzoli et al [Mazzoli et al., 2003]. Low frequencies were defined as 500 Hz or less, mid frequencies as greater than 500 and less than 2000 Hz, and high frequencies as greater than 2000 and less than 8000 Hz. The audiogram types were defined as follow: (a) low frequency, a greater than 15 dB HL difference between the poorest low frequency thresholds and those at higher frequencies; (b) mid frequency, a greater than 15 dB HL difference between the poorest thresholds in the mid frequencies and those at higher and lower frequencies; (c) high frequency, a greater than 15 dB HL difference between the mean of the 500 and 1000 Hz thresholds and the mean of the 4000 and 8000 Hz thresholds; and (d) flat, a less than 15 dB HL difference between the mean of the 250 and 500 Hz thresholds, the mean of the 1000 and 2000 Hz thresholds, and the mean of the 4000 and 8000 Hz thresholds.

Hearing impairment was categorized into 3 types as follows. Conductive: normal bone-conduction thresholds (<20 dB HL) and an ABG >15 dB HL averaged over 0.5, 1 and 2 kHz, Sensorineural: an ABG < 15 dB HL averaged over 0.5, 1 and 2 kHz, and Mixed: >20 dB HL in the bone conduction threshold together with >15 dB HL AGB averaged over 0.5, 1 and 2 kHz.

As well as routine blood tests including a full blood count and blood biochemistry, serological and immunological tests were used to screen for AAV diseases. These tests included those for rheumatoid factor (RF), antinuclear antibodies (ANAs), immunoglobulin E, Proteinase 3 (PR3) and Myeloperoxidase (MPO) ANCA.

CT score

CT scans were performed according to our institutional protocol and coronal CT scans of the paranasal sinus were reviewed by an investigator who was blinded to the patients' information. We used the Lund and Mackey scoring system (LMS)[Lund and Mackay, 1993] to evaluate the degree of paranasal sinus shadow. Briefly, CT shadows of

the maxillary, frontal, anterior and posterior ethmoid and sphenoid sinuses as well as those of the olfactory clefts were evaluated as follows. A sinus with no opacification was scored zero, a sinus with partial opacification was scored 1 and a sinus with complete opacification was scored 2. The total score for all sinuses (maximum 24) was taken as the CT score.

Treatment procedure

Patients with EGPA were basically treated with intravenous methylprednisolone pulse therapy (0.5-1g /day) for 3 days followed by high-dose oral prednisolone (1mg/day) for 4 or more weeks, which was then tapered gradually according to the severity of the disease symptoms. Cyclophosphamide (daily orally or pulse) was added for initial therapy. The treatment protocol was adjusted according to the disease severity and patient status, such as age and complications. Treatment for otologic manifestations was chosen on the basis of inflammation, severity of otologic symptoms and other symptoms, and patient status.

Statistical analysis

Statistical analyses were performed using GraphPad Prism software (GraphPad

Software Inc., San Diego, CA, USA) Statistical differences between the incidence rates for each symptom were analyzed using the Fisher's exact test. Analysis of variance for three or more groups was performed using a nonparametric Kruskal-Wallis test followed by Dunn's Multiple Comparison Test. The Mann-Whitney U-test was used to evaluate differences between two groups. A p value of less than 0.05 was considered to be statistically significant.

Results

Patients

Twenty-one consecutive patients fulfilled at least 4 out of the 6 ACR criteria for EGPA. Six patients were male and 15 patients were female, with a mean age at the time of the diagnosis of 53.0 ± 15.5 (range 32-73 years). Twenty-five patients were diagnosed with GPA during the same period.

Otologic manifestations

Characteristics of hearing impairment in patients with EGPA

Eleven patients (52.38%) with EGPA demonstrated otologic manifestations. Ten (90.9%) of the 11 patients presented with unilateral (7 involving the right ear and 3 the left ear) and 1(9.1%) with bilateral hearing loss. The type of hearing loss was mixed hearing loss in 7 ears (58.3%), sensorineural hearing loss in 3 ears (25.0%) and conductive hearing loss in 2 ears (16.7%). The pattern of hearing loss was categorized as flat in 7 ears (58.3%), high in 3 ears (25.0%), and low and mid in 1 ear (8.3%) each. The severity of hearing impairment in patients with EGPA was mild in 7 ears (58.3%) and moderate in 5 ears (41.7%). No patients were categorized with severe or profound hearing impairments (Table 1).

Figure 1A shows the mean pure-tone thresholds for air- and bone-conduction (air-PTA and bone-PTA) in the audiograms of the affected and non-affected ears. We found that air-PTAs in the affected ear were significantly higher than those in the non-affected ears at all frequencies ($p < 0.05$). The bone-PTAs in the affected ear were also significantly higher than those in the non-affected ears at 0.5, 2 and 4 kHz ($p < 0.05$). The air-PTAs of the affected ears were higher than the bone-PTAs at all frequencies and the difference was significant at 4000Hz ($p < 0.05$). There were no differences between the air-PTAs and bone-PTAs in the non-affected ears.

Treatment

Table 1 provides a summary of the initial systemic treatments and treatments for otologic symptoms in EGPA patients. As a systemic treatment, 13 patients (61.9%) received a combination of steroid pulse therapy, high-dose prednisolone and cyclophosphamide. Two patients (9.5%) were treated with high-dose prednisolone and cyclophosphamide, and 4 patients (19.0%) were treated with high-dose prednisolone monotherapy. All patients had achieved complete remission.

For treatment of the otologic symptoms, the PSL dose was increased in 6 patients and 3 patients received additional cyclophosphamide. No changes were made

to the maintenance therapy in 5 patients as these patients had no systemic inflammation or patient status would not allow an increase in immunosuppressive therapy. These patients were treated with carbocisteine and/or vitamin B12. Four patients were underwent myringotomy and one patient had a ventilation tube placed in her tympanic membrane. All but one patient achieved complete remission. One patient, who did not receive any change in maintenance therapy, showed no recovery. At the onset of otologic symptoms, this patient was undergoing treatment for septicemia and it was, therefore, difficult to increase immunosuppressive therapy.

With regard to nasal symptoms, three patients had a history of nasal surgery, 9 patients received topical steroids.

Comparison of hearing thresholds before and after treatment in each group

Figure 1B demonstrates the differences between the pre- and post-treatment air- and bone-PTAs and mean ABGs. The air-PTA was significantly higher than the bone-PTA . The air-PTA was significantly improved from the pre-treatment value of 38.75 ± 17.05 dB HL to the post-treatment value of 20.57 ± 12.16 dB HL ($p < 0.0001$). The bone- PTA value recovered from 24.77 ± 16.25 dB HL pre-treatment to 18.39 ± 13.88 dB HL post-treatment ($p = 0.043$). The mean ABGs were also significantly improved with

treatment from 13.98 ± 13.71 dB HL to 3.21 ± 6.27 dB HL ($p=0.0005$).

Onset of ear symptoms, sinusitis and asthma in patients with EGPA

Figure 1C shows the onset of ear symptoms, sinusitis and asthma in EGPA patients. The mean onset time of sinusitis, asthma, and ear symptoms from the definitive diagnosis of EGPA were -8.9 ± 1.9 years (range, -30 to 0), -4.2 ± 0.9 years (range, -15 to 0) and 1.5 ± 0.7 years (range, -2 to 6), respectively. Although all sinusitis and asthma preceded the definitive diagnosis, 81.8% of ear symptoms (9/11) occurred after definitive diagnosis of EGPA. There were significant differences between the onset of ear symptoms and those of asthma and sinusitis.

Comparison of hearing disturbances between EGPA and GPA

Figure 1D shows the differences in air-PTAs at the worst point between EGPA and GPA. The worst PTAs in the EGPA and GPA groups were 38.75 ± 17.05 dB and 56.18 ± 18.47 dB, respectively, indicating that the PTA of patients with EGPA was significantly milder than that of GPA patients.

Nasal manifestations

Eighteen patients (85.7%) with EGPA demonstrated some nasal symptoms. Rhinorrhea, nasal obstructions, and hyposmia were observed in 16 (76.2%), 16 (76.2%) and 10 (47.6%) patients with EGPA, respectively. Eleven patients (52.4%) had nasal polyps and 9 patients (42.9%) had crust formation in their nasal cavity, whereas no perforation of the nasal septum or saddle nose was observed in patients with EGPA. In the GPA group, all patients had crust formation, and 12 (48%) and 13 (52%) of the patients had nasal septum perforation and saddle nose, respectively. No patients with GPA had nasal polyps in their nasal cavity. Patients with GPA had a significantly higher frequency of crust formation, septal perforation and saddle nose than did patients with EGPA. However, EGPA was associated with a significantly higher incidence of nasal polyps than GPA. Twenty patients (95.2%) with EGPA showed sinus CT scan abnormalities (Fig. 2A).

CT scores for the paranasal sinus

Figure 2B shows the LMS score for patients with EGPA. The median LMS score was 13.7, with the peak LMS score between 17 and 20. A comparison of the degree of CT shadow of the maxillary sinus with that of the ethmoid sinus shows that the

ethmoid sinus shadows were more severe than those of the maxillary sinus (Fig. 2C).

Laboratory data

At the definitive diagnosis of EGPA, all patients suffered hypereosinophilia $>1500/\text{mm}^3$ (mean $9355.8/\text{mm}^3$, range $1525\text{-}24403/\text{mm}^3$). The mean percentage of eosinophils in the whole white blood cells (WBCs) was 45.7% (range, 12.0-72.4%). Nine of 21 patients (42.9 %) were ANCA positive. All ANCA-positive patients suffered MPO-ANCA. No patients were found to be PR3-ANCA positive or double positive for ANCA.

Nineteen of 21 patients (90.5%) had elevated CRP. The mean CRP level was 10.3 ± 9.3 (range, 0.22-18.34). Hyper IgE (> 170 IU/ml) was recognized in 15 of 21 (71.4%) patients. There were no significant relationships between the clinical symptoms and laboratory findings.

Symptoms other than those of the ear and nose

At diagnosis, 17 of 21 (81.0%) patients demonstrated neuropathy of the central and peripheral nerves. The majority of patients with this type of neuropathy (16/17, 94.1%) showed lower-limb sensory loss and drooping foot due to peroneal and/or tibial

nerve involvement. Seven of 17 (41.2%) patients suffered numbness of their hands and fingers due to radial, ulnar or median nerve involvement. Facial nerve palsy, recurrent nerve palsy, cerebral hemorrhage, cerebral infarction were each recognized in one patient.

Skin disorders were observed in 11 of 21 patients (52.3%), with the most common skin disorder (7/11, 63.6%) being purpura of the lower limbs. Six of 21 patients (28.6%) showed chest X-ray abnormalities. Renal, intestinal and heart disorders were also recognized in 5 (23.8%), 4 (19.0%) and 1 of 21 patients (0.048%), respectively.

Pathological diagnosis

Fifteen of 21 patients underwent tissue biopsy from organs such as the nasal cavity, skin, lung, nerve, small intestine and heart. Seven patients (46.7%) were diagnosed with EGPA on the basis of pathological findings. The positive rate for the establishment of an exact diagnosis at the site of biopsy was 25% (1/4 specimens) for the nasal cavity, 80 % (4/5) for skin, 100% (1/1) for nerves, 0% for the small intestine (0/2) and 0% (0/1) for the heart. With regard to specimens from the nasal cavity, no cases were diagnosed on the basis of specimens taken from nasal polyps. On the other hand, a

definitive diagnosis of EGPA could be made on the basis of specimens taken from the granulomatous mucosa in the lateral nasal cavity.

Middle ear effusions were obtained from 3 patients and examined cytologically. Specimens consisted of eosinophils, neutrophils and monocytes, with eosinophils being dominant in all specimens. We could not reach a diagnosis of EGPA from the cytologic examination. The middle ear granulomatous lesions were too small to allow biopsy specimens to be taken.

Discussion

In this study, we reported the characteristic otologic and nasal manifestations in patients with EGPA. Our data showed that more than half of the EGPA patients have otologic manifestations and the characteristics of these manifestations were as following. The severity of hearing loss in these patients was mild to moderate, The pattern of hearing loss varied, although flat type was most common. The most common type of hearing impairment was mixed hearing loss, followed by sensorineural hearing loss. The otologic symptoms showed a good response to treatment in most of EGPA patients.

Reports on the otologic manifestations of EGPA are extremely rare. To date there have only been two studies on multiple patients with otologic symptoms of EGPA[Bacciu et al., 2006; Ishiyama and Canalis, 2001]. These studies reported on only a small number of patients (4 and 5), and did not provide precise audiogram data.

Ishiyama and Canalis reported 5 EGPA patients with otologic manifestations. All of their patients suffered severe to profound mixed or sensorineural hearing loss. Bacciu et al., on the other hand, reported 28 EGPA patients, 4 (19%) of which showed otologic manifestations [Bacciu et al., 2006]. Two patients of their series had mild to

moderate conductive hearing loss and the remaining 2 patients suffered sensorineural hearing loss, although no auditory data was reported.

Based on our data, the frequency of otologic symptoms was higher and the severity was milder than in the previously reported data. One explanation for the differences in the frequency and severity of otologic manifestations between our study and the previous studies might be that we carefully checked for ear symptoms in all patients and, therefore, picked up even mild changes. Although most of these mild ear symptoms could be caused by Eustachian tube dysfunction and readily treatable, it has been reported that mild hearing loss in patients with EGPA sometimes develops into severe progressive hearing loss [Ishiyama and Canalis, 2001]. Such otitis media might be caused by mild vasculitis of their middle ear mucosa. Therefore, even if the otologic manifestations are not severe, patients should be carefully monitored so as not to miss any rapid deterioration in ear symptoms.

The causes of the otologic manifestations have not yet been elucidated. In this study, we demonstrated that not only air-PTAs but also bone-PTAs were significantly higher in the affected ears than in the non-affected ears; however, the severity of hearing loss was mild in our series of patients. The inner ear and auditory nerves of the patients with EGPA might, therefore, be damaged during the early stage of their

otologic symptoms.

We also checked the onset of sinusitis, asthma and otologic symptoms. Sinusitis was the earliest occurring symptom of the three and, interestingly, most of the otologic manifestations occurred after definitive diagnosis. We could not account for this delay. It was also reported previously that otologic manifestations in patients with EGPA start during the advanced phase [Bacciu et al., 2006; Ishiyama and Canalis, 2001]. As the otologic manifestations tend to occur after the other symptoms, with some of them deteriorating rapidly [Ishiyama and Canalis, 2001], we must pay attention to the onset of ear disease even after definitive diagnosis.

Rhinorrhea, nasal obstructions, crust formation and hyposmia were the major symptoms of EGPA [Srouji et al., 2008]. None of these symptoms, except crusting, are specific to EGPA, and are often found in patients with chronic rhinosinusitis. On the other hand, crust formation in the nasal cavity was rather uncommon in patients with chronic rhinosinusitis, but is common in those with GPA. Previous studies have also reported nasal crusting in patients with EGPA, with the incidence of nasal crusting ranging from 14.2 to 75% [Bacciu et al., 2006; Srouji et al., 2008]. This symptom might reflect vasculitis in the mucosa of the nasal cavity and could be used to distinguish EGPA from chronic rhinosinusitis. A comparison of GPA and EGPA revealed that

destructive nasal symptoms, such as septal perforation, saddle nose and granulation of the nasal cavity due to vasculitis, are less severe in patients with EGPA.

We found that 95.2% of EGPA patients showed CT abnormalities and the mean LMS score in patients with EGPA was 13.7 in our study. Among patients with severe asthma, 68% were reported to show sinus CT abnormalities, while their mean LMS was reported to be 7 [Mehta et al., 2008]. Thus, compared to patients with severe asthma, the sinus shadows of patients with EGPA were more severe. The shadows of the ethmoid sinus were more severe than those of the maxillary sinus in patients with EGPA. This pattern of sinus involvement is similar to that of chronic rhinosinusitis with polyps [Dhong et al., 2006]. From these findings, the features of nasal manifestations in patients with EGPA were found to be similar to those of chronic rhinosinusitis, although more severe than those of chronic rhinosinusitis with severe asthma.

We demonstrated that the otologic and nasal manifestations differ between patients with GPA and with EGPA. However, there was no direct evidence to account for this discrepancy. One possible explanation for this difference is the differences in ANCA positivity of the diseases. Patient with EGPA are generally positive for MPO-ANCA whereas patients with GPA tend to exhibit PR3-ANCA. It was reported that patients

positive for PR3-ANCA are more likely to suffer from symptoms affecting the upper respiratory tract, nervous system, eyes than those positive for MPO-ANCA[Franssen et al., 1998]. The vasculitis score and the degree of the granuloma formation were also found to be more severe in PR3-ANCA-positive patients than in MPO-ANCA-positive patients[Franssen et al., 1998].

The definitive diagnosis of EGPA remains challenging as there is no specific marker or specific symptoms for EGPA. The clinical course of EGPA traditionally passes through three disease phases; an allergic phase consisting of asthma and chronic sinusitis, an eosinophilic phase characterized by lung, cardiac and gastrointestinal involvement, and a vasculitis phase with symptoms associated with vasculitis, such as peripheral neuropathy and purpura[Vaglio et al., 2009]. It was reported that these three phases sometimes overlap or do not appear in the usual order[Noth et al., 2003]. In our study, all but one patient moved directly from the allergic phase to the vasculitis phase. In the vasculitis phase, EGPA must be differentiated from other forms of small-vessel vasculitis such as GPA [Vaglio et al., 2013]. GPA patients were mainly found to be positive for PR3-ANCA and may be distinguished from EGPA patients on this basis. However, some GPA patients were positive for MPO-ANCA or negative for both ANCAs. A better understanding of the otolaryngological features of these diseases

may help to differentiate EGPA from other forms of small vessel vasculitis.

The pathological diagnosis of EGPA was also difficult. The main histological features of EGPA are tissue eosinophilia, necrotizing vasculitis, and extravascular eosinophilic granuloma. Biopsy specimens are often taken from the nose due to ease of access. However, it is difficult to take samples specific for EGPA from nasal polyps because tissues from nasal polyps are unlikely to be specific for EGPA as they share many features with chronic rhinosinusitis[Vaglio et al., 2013]. Biopsy should, therefore, be taken from the granulomatous tissue of the nasal cavity.

At the time of definitive diagnosis, the most common symptom not involving the ENT regions were neuropathy of peripheral nerve. Over 80% of patients suffered neuropathy and most of them showed impairment of the motor or sensory nerves of lower-limbs and/or hands. Skin disorders were observed in over half of the EGPA patients, with the major symptom being purpura of the lower limbs. These two major symptoms, nerve impairment and purpura, were the hallmark of EGPA onset, and otolaryngologists should be aware of these characteristic features of EGPA. If these symptoms are observed in patients with rhinosinusitis and asthma, blood eosinophil count, CRP and ANCA should be checked as soon as possible.

Conclusion

Otolaryngologists routinely treat rhinosinusitis patients with asthma. Although only a very small proportion of these patients eventually develop EGPA, symptoms including otologic manifestations in the vascular phase may progress very quickly. As it is difficult to anticipate the development of EGPA during the eosinophilic phase, otolaryngologists should be aware of the characteristic ear and nose manifestations of EGPA as well as the pattern of EGPA onset.

Figure legends

Figure 1 Otologic manifestations of EGPA.

A. The mean pure-tone thresholds for air- and bone-conduction (air-PTA and bone-PTA) in the audiograms of the affected and non-affected ears.

Air-PTAs in the affected ear (●) were significantly greater than those in the non-affected ears (○) at all frequencies ($p<0.05$). The bone-PTAs in the affected ear (▲) were also significantly higher than those in the non-affected ears (△) at 0.5, 2 and 4 kHz ($p<0.05$). The air-PTAs of the affected ears were significantly higher at 4000Hz ($p<0.05$). There were no differences between the air-PTAs and bone-PTAs in the non-affected ears.

B. Pure-tone average thresholds for air conduction (AC) and bone conduction (BC) and mean air-bone gaps (ABGs) before and after treatment

The air-PTA thresholds were significantly higher than the bone-PTA thresholds. The air-PTA was significantly improved from a pre-treatment value of 38.75 ± 17.05 dB HL to a post-treatment value of 20.57 ± 12.16 dB HL ($p<0.0001$). The bone-PTA was improved by the treatment from 24.77 ± 16.25 dB HL to 18.39 ± 13.88 dB HL ($p=0.043$). The mean ABGs were also significantly improved by treatment from 13.98 ± 13.71 dB HL to 3.21 ± 6.27 dB HL ($p=0.0005$).

C. Onset of ear symptoms, sinusitis and asthma in patients with EGPA

Sinusitis and asthma tended to precede the definitive diagnosis of EGPA.

On the other hand, a large proportion of ear symptoms occurred after the definitive diagnosis of EGPA.

D. Hearing disturbances in patients with EGPA and GPA

Hearing disturbances in patients with EGPA were significantly milder than those in patients with GPA.

Figure 2. Nasal and paranasal manifestations of EGPA

A. Nasal manifestations in patients with EGPA and GPA. Crust formation, septal perforation and saddle nose were more frequent in the GPA patients than in patients with EGPA. On the other hand, EGPA were associated with a significantly higher incidence of nasal polyps than GPA.

B. Paranasal sinus CT scores in EGPA patients.

The median LMS score was 13.7 and peak score was between 17 and 20.

LMS: Lund-Mackey Score

C. CT scores for the ethmoid and maxillary sinus in EGPA patients

Shadows of the ethmoid sinus were more severe than those of the maxillary sinus in patients with EGPA.

E; ethmoid sinus, M; maxillary sinus

Table legend

Table 1 Characteristic otologic symptoms and treatments for EGPA patients

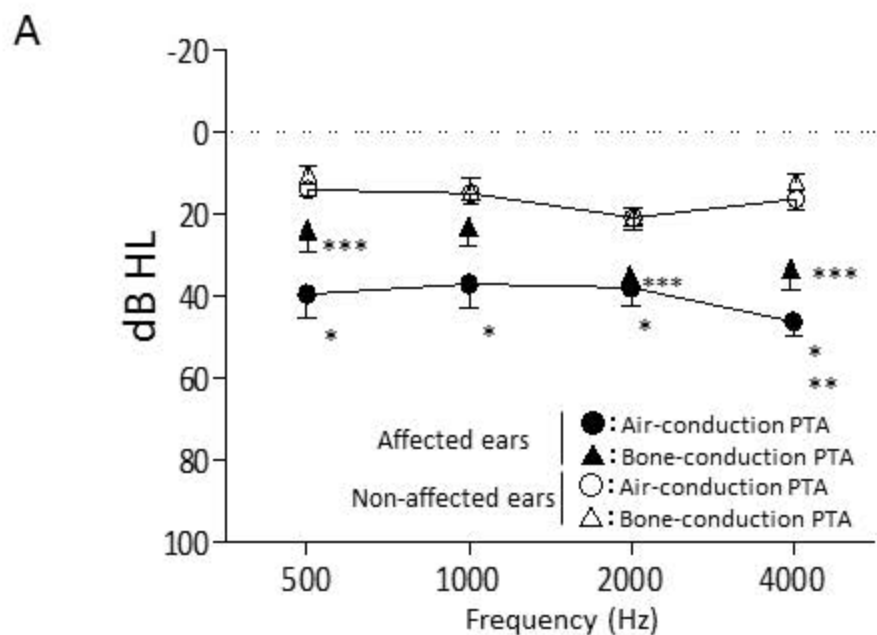
PSL; Prednisolone, (P); steroid pulse therapy, CY; cyclophosphamide, conductive; conductive hearing loss, Mix; mixed hearing loss, SNHL; sensorineural hearing loss,

VB12; Vitamin B 12, CR; complete remission, NR; no recovery

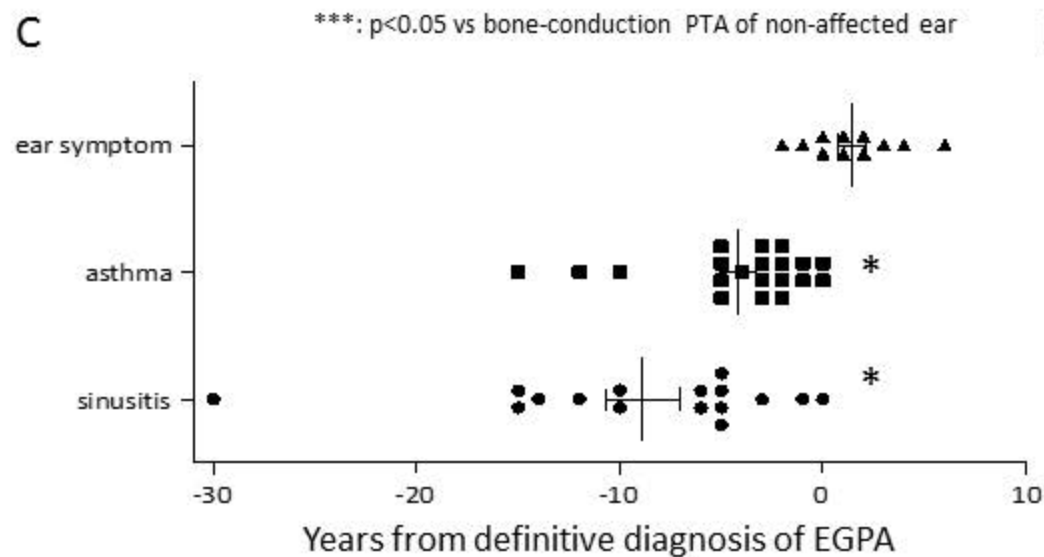
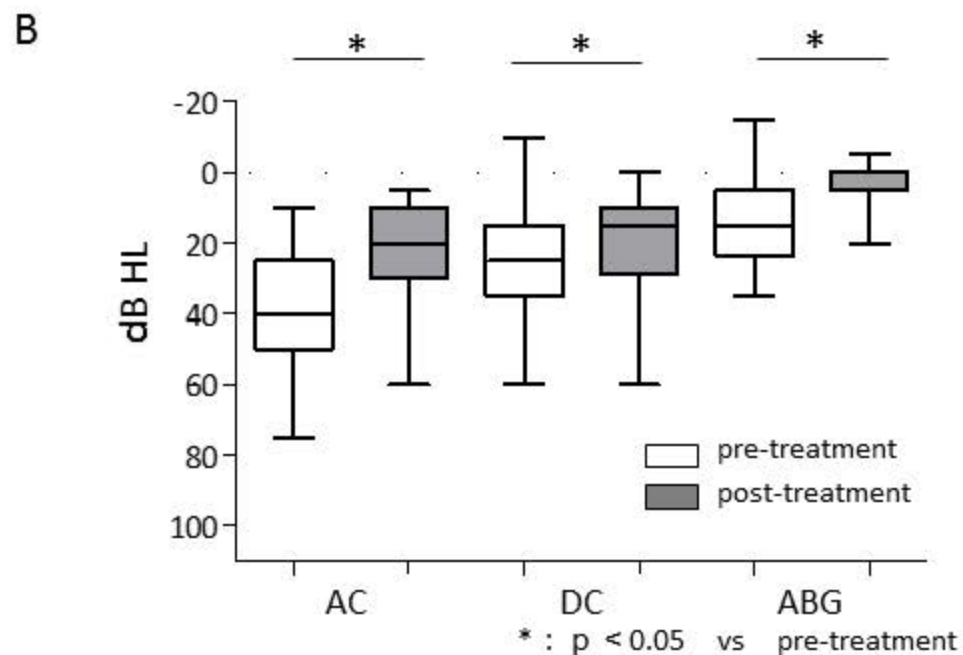
Reference

- Bacciu A, Bacciu S, Mercante G, Ingegnoli F, Grasselli C, Vaglio A, Pasanisi E, Vincenti V, Garini G, Ronda N, Ferri T, Corradi D, Buzio C: Ear, nose and throat manifestations of churg-strauss syndrome. *Acta Otolaryngol* 2006;126:503-509.
- Bacciu A, Buzio C, Giordano D, Pasanisi E, Vincenti V, Mercante G, Grasselli C, Bacciu S: Nasal polyposis in churg-strauss syndrome. *Laryngoscope* 2008;118:325-329.
- Churg J, Strauss L: Allergic granulomatosis, allergic angiitis, and periarteritis nodosa. *Am J Pathol* 1951;27:277-301.
- Dhong HJ, Kim HY, Chung YJ, Kim TW, Kim JH, Chung SK, Kim MG: Computed tomographic assessment of chronic rhinosinusitis with asthma. *Am J Rhinol* 2006;20:450-452.
- Franssen C, Gans R, Kallenberg C, Hagelucken C, Hoorntje S: Disease spectrum of patients with antineutrophil cytoplasmic autoantibodies of defined specificity: Distinct differences between patients with anti-proteinase 3 and anti-myeloperoxidase autoantibodies. *J Intern Med* 1998;244:209-216.
- Ishiyama A, Canalis RF: Otological manifestations of churg-strauss syndrome. *Laryngoscope* 2001;111:1619-1624.
- Jennette JC, Falk RJ, Andrassy K, Bacon PA, Churg J, Gross WL, Hagen EC, Hoffman GS, Hunder GG, Kallenberg CG, et al.: Nomenclature of systemic vasculitides. Proposal of an international consensus conference. *Arthritis Rheum* 1994;37:187-192.
- Jennette JC, Falk RJ, Bacon PA, Basu N, Cid MC, Ferrario F, Flores-Suarez LF, Gross WL, Guillevin L, Hagen EC, Hoffman GS, Jayne DR, Kallenberg CG, Lamprecht P, Langford CA, Luqmani RA, Mahr AD, Matteson EL, Merkel PA, Ozen S, Pusey CD, Rasmussen N, Rees AJ, Scott DG, Specks U, Stone JH, Takahashi K, Watts RA: 2012 revised international chapel hill consensus conference nomenclature of vasculitides. *Arthritis Rheum* 2013;65:1-11.
- Leavitt RY, Fauci AS, Bloch DA, Michel BA, Hunder GG, Arend WP, Calabrese LH, Fries JF, Lie JT, Lightfoot RW, Jr., et al.: The american college of rheumatology 1990 criteria for the classification of wegener's granulomatosis. *Arthritis Rheum* 1990;33:1101-1107.
- Lund VJ, Mackay IS: Staging in rhinosinusitis. *Rhinology* 1993;31:183-184.
- Masi AT, Hunder GG, Lie JT, Michel BA, Bloch DA, Arend WP, Calabrese LH, Edworthy SM, Fauci AS, Leavitt RY, et al.: The american college of rheumatology 1990 criteria for the classification of churg-strauss syndrome (allergic granulomatosis and angiitis). *Arthritis Rheum* 1990;33:1094-1100.

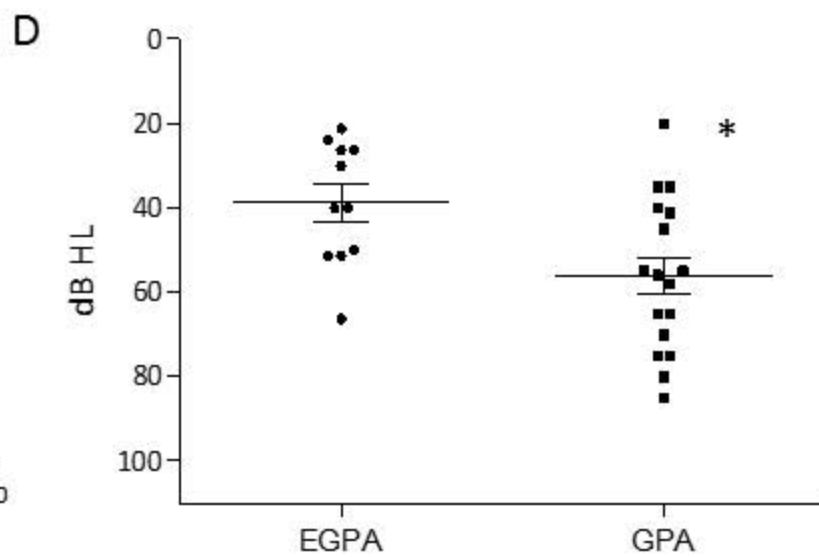
- Mazzoli M, Camp GV, Newton V, Giarbini N, Declau F, Parving A: Recommendations for the description of genetic and audiological data for families with nonsyndromic hereditary hearing impairment. *Audiol Med* 2003;1:148-150.
- Mehta V, Campeau NG, Kita H, Hagan JB: Blood and sputum eosinophil levels in asthma and their relationship to sinus computed tomographic findings. *Mayo Clin Proc* 2008;83:671-678.
- Meltzer EO, Hamilos DL, Hadley JA, Lanza DC, Marple BF, Nicklas RA, Bachert C, Baraniuk J, Baroody FM, Benninger MS, Brook I, Chowdhury BA, Druce HM, Durham S, Ferguson B, Gwaltney JM, Jr., Kaliner M, Kennedy DW, Lund V, Naclerio R, Pawankar R, Piccirillo JF, Rohane P, Simon R, Slavin RG, Togias A, Wald ER, Zinreich SJ, American Academy of Allergy A, Immunology, American Academy of Otolaryngic A, American Academy of O-H, Neck S, American College of Allergy A, Immunology, American Rhinologic S: Rhinosinusitis: Establishing definitions for clinical research and patient care. *Otolaryngol Head Neck Surg* 2004;131:S1-62.
- Noth I, Streck ME, Leff AR: Churg-strauss syndrome. *Lancet* 2003;361:587-594.
- Rosenfeld RM, Andes D, Bhattacharyya N, Cheung D, Eisenberg S, Ganiats TG, Gelzer A, Hamilos D, Haydon RC, 3rd, Hudgins PA, Jones S, Krouse HJ, Lee LH, Mahoney MC, Marple BF, Mitchell CJ, Nathan R, Shiffman RN, Smith TL, Witsell DL: Clinical practice guideline: Adult sinusitis. *Otolaryngol Head Neck Surg* 2007;137:S1-31.
- Srouji I, Lund V, Andrews P, Edwards C: Rhinologic symptoms and quality-of-life in patients with churg-strauss syndrome vasculitis. *Am J Rhinol* 2008;22:406-409.
- Stachler RJ, Chandrasekhar SS, Archer SM, Rosenfeld RM, Schwartz SR, Barrs DM, Brown SR, Fife TD, Ford P, Ganiats TG, Hollingsworth DB, Lewandowski CA, Montano JJ, Saunders JE, Tucci DL, Valente M, Warren BE, Yaremchuk KL, Robertson PJ, American Academy of O-H, Neck S: Clinical practice guideline: Sudden hearing loss. *Otolaryngol Head Neck Surg* 2012;146:S1-35.
- Vaglio A, Buzio C, Zwerina J: Eosinophilic granulomatosis with polyangiitis (churg-strauss): State of the art. *Allergy* 2013;68:261-273.
- Vaglio A, Casazza I, Grasselli C, Corradi D, Sinico RA, Buzio C: Churg-strauss syndrome. *Kidney Int* 2009;76:1006-1011.



*: $p < 0.05$ vs air-conduction PTA of non-affected ear
 **: $p < 0.05$ vs bone-conduction PTA of affected ear
 ***: $p < 0.05$ vs bone-conduction PTA of non-affected ear

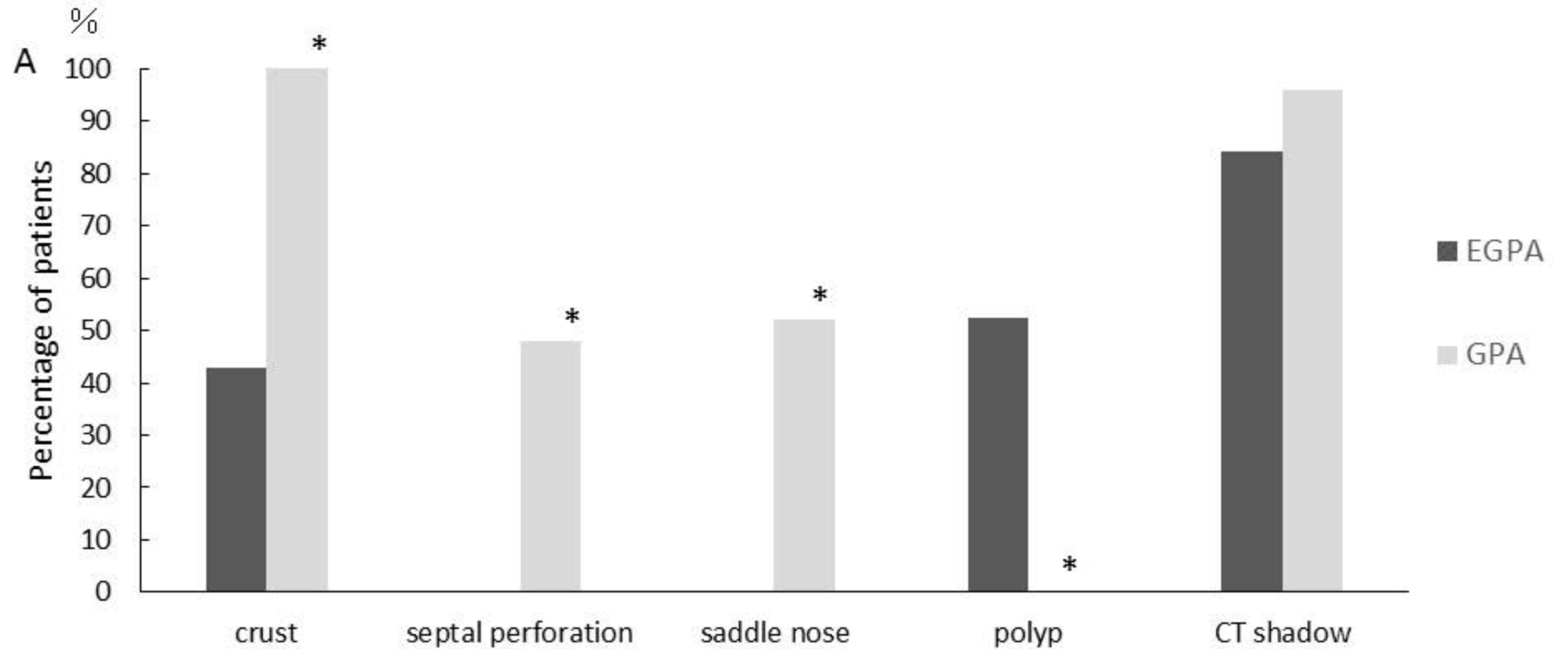


*: $p < 0.05$ vs ear symptom



*: $p < 0.05$ vs EGPA

Fig 1



*: $p < 0.05$ vs EGPA

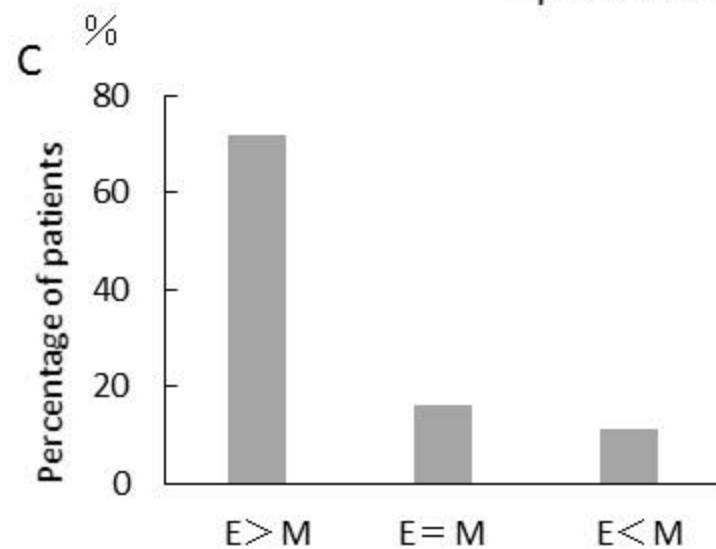
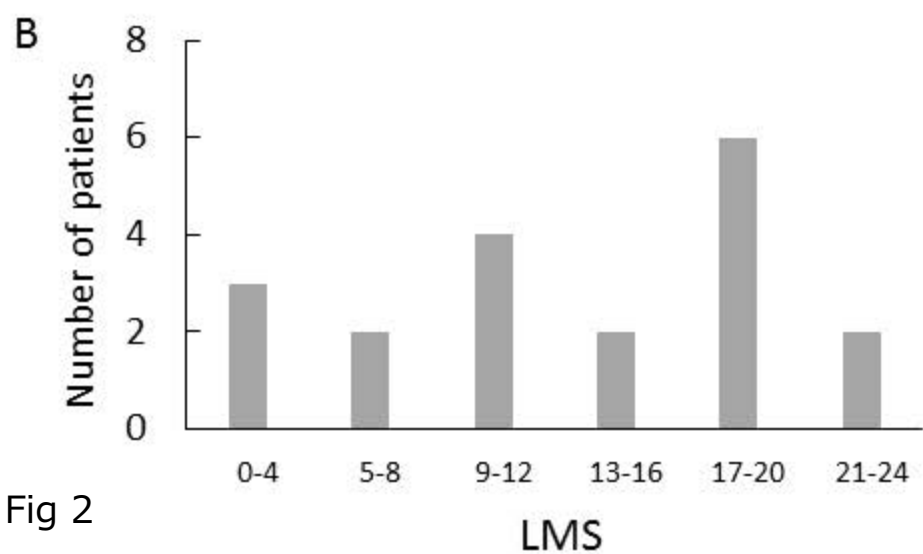


Fig 2

Patient no.	Systemic treatment	Otologic symptoms	Type of hearing impairment	Pattern of hearing loss	Severity of hearing loss	Treatment for otologic symptoms	Treatment results for hearing impairment
1	PSL(P)/CY	rt	conductive	flat	mild	PSL dose up	CR
2	PSL(P)/CY	lt	Mix	low	moderate	carbocisteine/VB12/tube placement	NR
3	PSL	lt	SNHL	high	mild	PSL dose up	CR
4	PSL(P)/CY	lt	SNHL	high	mild	carbocisteine/VB12	CR
5	PSL(P)/CY	rt	Mix	flat	moderate	PSL dose up / CY	CR
6	PSL(P)/CY	rt	Mix	flat	mild	carbocisteine/myringotomy	CR
7	PSL(P)/CY	-					
8	PSL(P)/CY	-					
9	PSL(P)/CY	rt	Mix	flat	mild	carbocisteine	CR
10	PSL/CY	-					
11	PSL(P)	bil	Mix/SNHL	flat/flat	mild/moderate	PSL dose up	CR
12	PSL	-					
13	PSL(P)/CY	-					
14	PSL(P)/CY	rt	conductive	mid	moderate	PSL(P)/CY /myringotomy	CR
15	PSL(P)/CY	-					
16	PSL(P)/CY	rt	Mix	high	mild	PSL dose up /CY/myringotomy	CR
17	PSL	-					
18	PSL	-					
19	PSL/CY	rt	Mix	flat	moderate	carbocisteine /myringotomy	CR
20	PSL(P)/CY	-					
21	PSL	-					