

# Placement of trans-sternal wires according to an ellipsoid pressure vessel model of sternal forces

Aaron R. Casha<sup>a,b,\*</sup>, Alex Manché<sup>a</sup>, Marilyn Gauci<sup>c</sup>, Marie-Therese Camilleri-Podesta<sup>b</sup>,  
Pierre Schembri-Wismayer<sup>b</sup>, Zdenka Sant<sup>d</sup>, Ruben Gatt<sup>e</sup> and Joseph N. Grima<sup>e</sup>

<sup>a</sup> Department of Cardiothoracic Surgery, Mater Dei Hospital, Msida, Malta

<sup>b</sup> Department of Anatomy, University of Malta, Msida, Malta

<sup>c</sup> Department of Anaesthesia, Mater Dei Hospital, Msida, Malta

<sup>d</sup> Department of Mechanical Engineering, University of Malta, Msida, Malta

<sup>e</sup> Metamaterials Unit, Faculty of Science, University of Malta, Msida, Malta

\* Corresponding author. Department of Cardiothoracic Surgery, Mater Dei Hospital, Msida, MSD 2090, Malta. Tel: +356-25-455480/6; fax: +356-25-454154; e-mail: aaron.casha@um.edu.mt (A.R. Casha).

Received 12 August 2011; received in revised form 28 October 2011; accepted 7 November 2011

## Abstract

Dehiscence of median sternotomy wounds remains a clinical problem. Wall forces in thin-walled pressure vessels can be calculated by membrane stress theory. An ellipsoid pressure vessel model of sternal forces is presented together with its application for optimal wire placement in the sternum. Sternal forces were calculated by computational simulation using an ellipsoid chest wall model. Sternal forces were correlated with different sternal thicknesses and radio-density as measured by computerized tomography (CT) scans of the sternum. A comparison of alternative placement of trans-sternal wires located either at the levels of the costal cartilages or the intercostal spaces was made. The ellipsoid pressure vessel model shows that higher levels of stress are operative at increasing chest diameter ( $P < 0.001$ ). CT scans show that the thickness of the sternal body is on average 3 mm and 30% thicker ( $P < 0.001$ ) and 53% more radio-dense ( $P < 0.001$ ) at the costal cartilage levels when compared with adjacent intercostal spaces. This results in a decrease of average sternal stress from 438 kPa at the intercostal space level to 338 kPa at the costal cartilage level ( $P = 0.003$ ). Biomechanical modelling suggests that placement of trans-sternal wires at the thicker bone and more radio-dense level of the costal cartilages will result in reduced stress.

**Keywords:** Sternum • Dehiscence • Biomechanics

## INTRODUCTION

Median sternotomy is the commonest cardiac surgical approach. Dehiscence, although rare (0.5–5%) [1], carries a significant mortality and morbidity of between 10 and 40% [2]. There is no ideal sternal closure and different new methods of closing the chest are regularly reported in the literature. As Robicsek pointed out, there is a need to 'design a biomechanical model, in which forces acting upon the re-united sternal halves may be reproduced and measured' [3].

The integrity of the reunited sternotomy is dependent on both static and dynamic loads acting on the sternum. On the one hand, there is the strength of the sternal sutures and the integrity of the sternal body, while on the other hand there is the strain exerted by the traction of the respiratory muscles resulting in intrathoracic pressure changes. The outcome of this ongoing competition of forces will decide whether the sternotomy closure 'will hold' or not [4].

The chest, including the sternum, is subject to varying forces associated with breathing and coughing. Assessment of the magnitude of these forces has been attempted directly by using strain gauges in cadavers and inflating balloons and

measuring pressures in a cadaveric model of a rewired sternum [5].

Quantification of the forces across a median sternotomy for biomechanical comparisons of closures remains problematic. Cadaveric or animal model testing can only be an approximation because of the changes in tissue properties occurring soon after death, or in different species, respectively.

This paper refines the simple theoretical model developed by our group [6], which predicts the overall force applied across a sternotomy during coughing. It also looks at computerized tomography (CT) data pertaining to the morphology of the body of the sternum, in particular sternal thickness and radio-density, with a view to selection of the placement site of sternal wires according to the ellipsoid pressure vessel model of sternal forces.

## MATERIALS AND METHODS

In the human all the three radii of the ellipsoid are unequal. However, it is only practical to model an ellipsoid pressure vessel with circular (averaged) cross sections.

The formula for circumferential stress  $\sigma$  for an ellipsoid [7] is

$$\sigma = \frac{Pb}{h} \left[ 1 - \frac{b^3}{a^2(2b+h)} \right], \quad (1)$$

where  $P$  is the transmural distending pressure,  $h$  is the wall thickness at the equator,  $b$  is the minor semi-axis (geometric average of semi-transverse diameters) and  $a$  is the major semi-axis (height from apex to equator).

Thoracic CT digital imaging and communications in medicine (DICOM) data from seven adult males, randomly chosen and suitably anonymized, were collected. Measurements of the major semi-axis or height of the chest and of both transverse semi-transverse diameters (measured from external rib surfaces) were taken at various levels of the chest and formula (1) were used to calculate the circumferential wall or sternal stress (Fig. 1). The rib-level denoted the level at the mid-axillary line at which the measurements were taken.

CT imaging was also performed on seven human cadaveric sternums from the Department of Anatomy, University of Malta. The CT imaging for each of the seven sternums consisted of ~350 cuts at a spacing of 0.25 mm. A thin slice re-creation of the lateral part of the sternum in longitudinal section was generated by an open-source software program called OsiriX (OsiriX Foundation, Geneva, Switzerland). This DICOM data viewer has been used for data analysis of all CT DICOM data.

Measurements of the thickness of the sternum at each of four levels of the body of the sternum were taken at two alternative placement sites (Fig. 2) for each of four wires through the body of the sternum. These sites were at ridges at the level of the sterno-costal joints and at valleys at the level of the intercostal spaces. Level 1 compares the second intercostal space with the third sterno-costal joint level, level 2 compares the third intercostal space with the fourth sterno-costal joint level, level 3 compares the fourth intercostal space with the fifth sterno-costal joint level and level 4 compares the fifth intercostal space with the sixth sterno-costal joint level (Fig. 2).

The average radio-density in Hounsfield units (HU) of the cortex of these seven human cadaveric sternums was measured at the ridges and valleys using OsiriX DICOM software. One specimen was discarded as unsuitable due to refractive interference from sternal wires *in situ*. Average values for all four sternal body levels were calculated. The 'UCLA' colour look-up table (CLUT) was used to assign voxel colour and opacity on the basis of CT numbers. This CLUT depicts voxels radio-density on a dynamically variable linear colour scale ranging from purple to blue, green, orange and red for increasingly high radio-density. This colour scale, as used in Fig. 2, was set to a thin slice CT bone window level of 300 HU, window width 1500 HU with maximal intensity projection.

Statistics performed were a Student's *t*-test and an analysis of variance (ANOVA) using Excel software (Microsoft, Redmond, USA). The study was approved by the University of Malta's ethics committee on human research.

## RESULTS

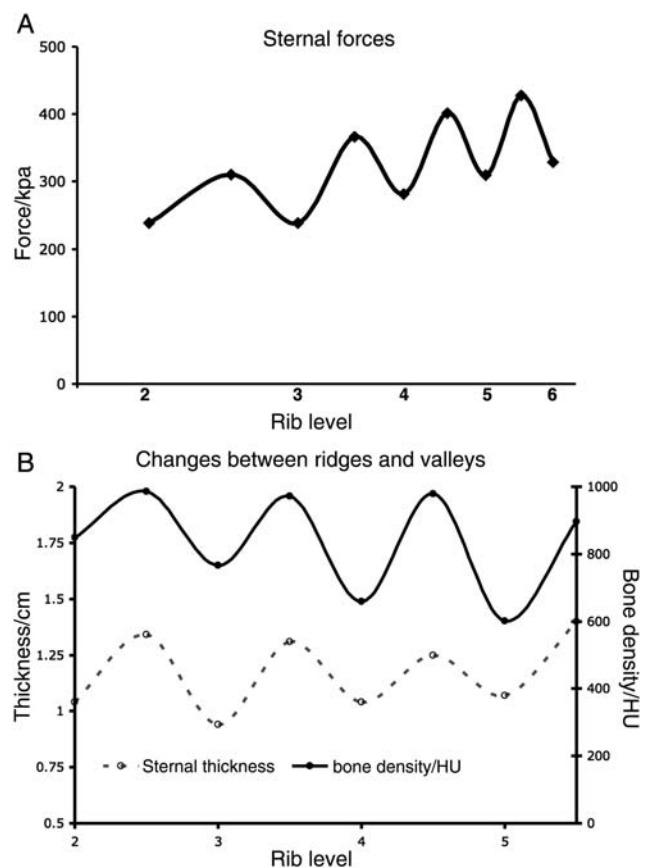
Typical dimensions for an adult male chest are shown in Table 1. The values for wall stress are calculated according to formula (1) from the dimensions of the chest-distending pressure  $P$

equivalent to a maximal cough of 40 kPa [8] and wall thickness  $h$  of 1 cm. Single factor ANOVA showed no statistical difference in CT measurements of the dimensions of the thoracic cavity for seven subjects.

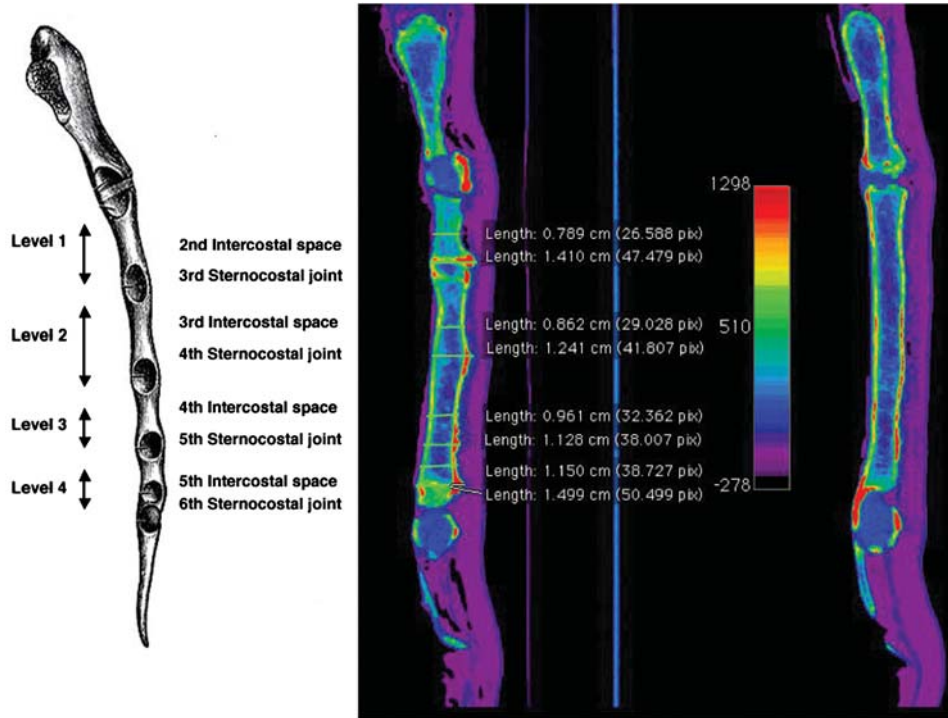
Table 2 shows the valley and ridge thicknesses at four levels of the sternal body for seven different sternums, and also the average sternal valley and ridge thicknesses at these four locations in the body of the sternum. The average 'valley' is  $10.2 \pm 1.9$  mm (SD) and the average 'ridge' is  $13.3 \pm 2.1$  mm (Student's *t*-test,  $P < 0.001$ ). The thickness of the body of the sternum is on average 3 mm and 30% thicker at the costal cartilage levels when compared with the intercostal space level.

Figure 1 shows a graph comparing prediction for stress with the ellipsoid pressure vessel model for different sternal thicknesses. The average ridge stress was 338 kPa and the average valley stress was 438 kPa (Student's *t*-test,  $P = 0.003$ ).

The average bone density in HU at the four ridges and valleys of the sternum is shown in Table 3. The average ridge density was 958 HU and the average valley density was 627 HU, the ridges being 53% more radio-dense than the valleys (*t*-test,  $P < 0.001$ ).



**Figure 1:** (A) Graph comparing prediction for stress with the ellipsoid model for different sternal thicknesses at the intercostal levels (valleys) and sterno-costal joints (ridges). The ellipsoid model correctly predicts that sternal dehiscence or disruption starts at the bottom end of the incision as reported by McGregor *et al.* [5]. Statistically significant difference in forces between ridges and valleys, Student's *t*-test,  $P < 0.001$ . (B) Chart showing sternal thickness and radio-density for ridges and valleys at four levels of the sternal body. The sternal thickness is lower in the valleys,  $n = 7$  (Student's *t*-test,  $P < 0.001$ ) and the ridge radio-density is higher than valley radio-density,  $n = 6$  (Student's *t*-test,  $P < 0.001$ ).



**Figure 2:** The picture on the left shows a lateral view of the sternum (after Gray's Anatomy 1918 edition) and shows four levels—each level represents alternative sites for the insertion of four different wires in the body of the sternum. The thicker one of each pair is called a ridge at the level of the sterno-costal joints, while the thinner site is called a valley at the level of the intercostal space. The middle picture is a thin slice CT of the lateral paramedian part of the sternum. It shows four pairs of measurements at each of the levels in the sternal body. The scale shows radio-density with red being the most dense in this 'UCLA' CLUT. Of note the radio-density is highest at the sterno-costal levels (ridges). The picture on the right shows a thin slice CT of the midline aspect of the same sternum where the striking feature is the homogeneity of the sternal thickness.

EXPERIMENTAL

**Table 1:** Typical dimensions of an adult male chest

Rib level	Semi-transverse diameter, b1 (cm)	Semi-transverse diameter, b2 (cm)	Major semi-axis or height, a (cm)	Stress (kPa)
1	12.0	15.0	2.5	250.7
2	14.0	19.0	5.0	317.0
3	17.0	21.5	8.0	374.1
4	19.0	23.0	10.5	410.3
5	20.5	24.0	13.0	436.6
6	22.0	25.0	16.5	463.1
7	22.0	26.5	21.0	480.0

The geometric average of b1 and b2 make up *b*. See formula (1) in text. From these parameters and distending pressure (40 kPa) and thickness (1 cm), wall stress can be calculated as in the right-hand column.

**DISCUSSION**

About two-thirds of sternal dehiscences are associated with infection [9] and the other third due to mechanical breakdown. This can be due to technical reasons as with paramedian sternotomies, loops of wire with bites that are too small and overtightening of wires in osteoporotic sternums. In a sternal dehiscence, the balance of forces at the wire–bone interface results in sternal wires cutting through bone. The chest wall forces across the divided sternum are transmitted through the sternal wires.

**Table 2:** The valley and ridge thicknesses at four levels of the sternal body for seven cadaveric sternums, and also the average sternal valley and ridge thicknesses at these four locations in the body of the sternum

	Sternal thickness in seven sternums (cm)							Average
	S1	S2	S3	S4	S5	S6	S7	
<b>Valley</b>								
1	0.79	0.71	1.17	0.92	1.29	1.50	0.88	1.04
2	0.90	0.77	1.07	0.85	0.79	1.29	0.89	0.94
3	0.96	1.20	1.07	0.90	1.07	1.17	0.90	1.04
4	1.15	0.96	1.06	1.13	1.23	1.17	0.78	1.07
<b>Ridge</b>								
1	1.41	1.14	1.31	1.13	1.55	1.62	1.23	1.34
2	1.24	1.29	1.41	0.99	1.29	1.67	1.24	1.31
3	1.13	1.29	1.28	1.02	1.58	1.56	0.91	1.25
4	1.50	1.39	1.29	1.43	1.54	1.70	0.97	1.40

Ridge thickness is significantly greater than valley thickness (Student's *t*-test, *P* < 0.001).

Placement of sternal wires in locations in the sternum that may be stronger due to increased density or subjected to lower levels of stress may decrease the risk of sternal dehiscence.

With the application of the physics of membrane stress theory, we can model the effects of forces on the chest by looking at stresses and deformations in thin-walled pressure

**Table 3:** The results of average radio-density in HU for six cadaveric sternums at each of four levels (Fig. 2) in the body of the sternum

Sternal level	Valley/HU	Ridge/HU
1	674	985
2	685	971
3	638	979
4	513	896
Average	627	958

The average result for all levels is also shown. Ridge radio-density is significantly higher than valley radio-density (Student's *t*-test,  $P < 0.001$ ).

vessels. The chest fulfils the requirement of a thin-walled vessel [10] since the radius of the chest is more than 10 times the thickness of the sternum (usually  $\sim 1$  cm).

The chest can be considered as a pressure vessel since pressure differences occur during the respiratory cycle. The pressure differences during ventilation are decidedly modest. Maximal coughing can reach 40 kPa [8], a magnitude larger than the forces in ventilation, and since a cough lasts  $\sim 0.3$  s, the forces generated can be described as explosive.

Although Pascal's principle states that the pressure of a gas is the same everywhere inside a pressure vessel at equilibrium, there are significant differences in wall tension on different parts of a pressure vessel. This variation is described by Laplace's law which describes the relationship between the transmural pressure difference and the tension, radius and thickness of the vessel wall. The formula involved changes according to the shape of the vessel wall [11].

The effect of Laplace's law on the sternum means that not all parts of the sternum are under the same level of tension or force when a patient coughs. The upper part of the sternum or manubrium has the least stress simply because the diameter of the chest wall is the smallest and the manubrium is very thick.

The chest has previously been modelled as a thin-walled cylindrical pressure vessel by our group. Casha *et al.* [6] described the circumferential or hoop force across the sternum as

$$T = rP, \quad (2)$$

where  $T$  is the resultant force required to keep the sternum closed,  $r$  is the radius,  $l$  is the length of the cylinder and  $P$  is the distending pressure (difference between internal and external pressures).

The chest modelled as a cylinder [6] has the advantage of simplicity but gives results for sternal forces that are higher than any other shape model. Another deficiency is that there is no correlation with the level within the chest (changing radius). The ellipsoid model predicts that as the minor semi-axis increases in size (i.e. as the diameter of the torso of the patient increases), the forces become higher. This prediction is validated in that it has been shown that sternotomies dehiscence from the bottom to the top [5].

In the ellipsoid pressure vessel model, a small change in sternal thickness results in large changes in circumferential stress. It may be beneficial in selecting sites for wire placement on the

sternum that are thicker, due to resultant lower localized stress levels (Fig. 2).

Optimal wire placement, however, does not depend solely on sternal thickness and stress levels, but also on sternal strength with bone density acting as a marker. Bone density has been used as a marker of bone strength [12]. Bone density is not usually determined by CT. The reason for this is a lack of reproducibility between different CT scanners. It has been suggested that the reason for this variation is a lack of proper standardization of air calibration [13]. However, the error is in the region of  $22.5 \text{ HU} \pm 10.89$  (SD) from the intended value of  $-1000$  HU, which is an error of 2.25%. The CT examinations used in this paper were done on the same CT scanner in one sitting and so there is no variation of standardization within the data presented.

The average bone density in HU at the four ridges of the sternum is 53% higher than the valleys,  $P < 0.001$ . Placement of trans-sternal wires at the level of the sterno-costal joints where the bone is thickest and densest would reduce the risk of cutting through bone and might decrease the risk of dehiscence. The consistent thickness in the appearance of the body of the sternum (right side of Fig. 2) in the midline gives no clue to differences present laterally. A surgeon can palpate the lateral part of the sternum prior to wiring of the sternum, in order to guide him in placing wires in the ridges—these being not only the thickest parts of the sternum, but also the parts of the lateral part of the sternum that have the highest bone density.

The method described here can be used by alternative methods of closure such as plates or differing wire configurations [14], since it aims to improve selection of the interface between bone and the closing material.

## CONCLUSION

The biomechanical model described here is only an approximation of the shape of the human chest; however, it models the chest more accurately than before. The ellipsoid pressure vessel model of sternal forces suggests that placement of trans-sternal wires at the more radio-dense and thicker part of the sternal body at the level of the costal cartilages will result in reduced stress, and is likely to reduce the risk of wire cutting through bone during coughing.

## Funding

Funding from the University of Malta Medical School (Grant IMF/014/11) and University of Malta Research Fund (Grant 31/389/10) is gratefully acknowledged.

**Conflict of interest:** none declared.

## REFERENCES

- [1] Voss B, Bauernschmitt R, Will A, Krane M, Kröss R, Brockmann G *et al.* Sternal reconstruction with titanium plates in complicated sternal dehiscence. *Eur J Cardiothorac Surg* 2008;34:139–45.
- [2] John LCH. Modified closure technique for reducing sternal dehiscence; a clinical and in vitro assessment. *Eur J Cardiothorac Surg* 2008;33:769–73.
- [3] Robicsek F, Fokin AA. Search for a better mousetrap. The quest for an ideal method of sternal closure. *Eur J Cardiothorac Surg* 2008;33:767–8.
- [4] Robicsek F. Commentary. *J Thorac Cardiovasc Surg* 1999;117:1150.

- [5] [McGregor WE, Trumble DR, Magovern JA. Mechanical analysis of midline sternotomy wound closure. J Thorac Cardiovasc Surg 1999;117:1144-9.](#)
- [6] [Casha AR, Yang L, Kay PH, Saleh M, Cooper GJ. A biomechanical study of median sternotomy closures. Eur J Cardiothorac Surg 1999;15:365-9.](#)
- [7] [Sandler H, Dodge HT. Left ventricular tension and stress in man. Circ Res 1963;13:91-104.](#)
- [8] Murray JF, Nadal JA (eds). *Textbook of Respiratory Physiology*. Philadelphia: WB Saunders and Company, 1994, 531-2.
- [9] [Rand RP, Cochran RP, Aziz S, Hofer BO, Allen MD, Verrier ED \*et al.\* Prospective trial of catheter irrigation and muscle flaps for sternal wound infection. Ann Thorac Surg 1998;65:1046-9.](#)
- [10] [Casha AR, Gauci M, Yang L, Saleh M, Kay PH, Cooper GJ. Fatigue testing median sternotomy closures. Eur J Cardiothorac Surg 2001;19:249-53.](#)
- [11] Young WC, Budynas RG. *Roark's Formulas for Stress and Strain*. New York: McGraw-Hill, 2002, 592-9.
- [12] [Licata A. Bone density vs bone quality: what's a clinician to do? Cleve Clin J Med 2009;76:331-6.](#)
- [13] [Parr DG, Stockley RA. Standardization of CT densitometry \[letter\]. Radiology 2004;230:887.](#)
- [14] [Randecker H. Median sternotomy closure: a simple inexpensive effective technique. Ann Thorac Surg 2005;80:2393-4.](#)