

INTERSEX — CASE REPORT AND DISCUSSION

A.J. PSAILA

M.D., D.C.H. (Lond.), M.R.C.P. (U.K.), M.R.C.P. (Edin.)

*Department of Medicine
St. Luke's Hospital*

Summary

The case is reported of a child with congenital malformation of the external genitalia who was brought up as a girl but has now, at the age of 25, been found to be a male. The factors determining sex and the various clinical types of intersex are discussed.

CASE HISTORY

Details about neonatal period

Healthy infant born at home on the 22nd August 1948. B.W. 9 lbs. Pregnancy normal. Birth attended by midwife. Parents at that time:- Father 26 years, Mother 23 years; both healthy. Infant was healthy at birth and outwardly female — external genitalia looked female. Christened "Mary" at age of 3 weeks.

Family History

Father and mother — both alive and well. The family consists of 4 children. 1) Female now aged 26. 2) The patient, Aged 25. 3) Female, aged 24. 4) Male aged 23. All sibs are healthy with normal sexual organs.

The Problem

This individual who has been taught to be female and has been reared as female all through infancy, childhood and youth is, in fact, a male. He is suffering from bifid scrotum, with undescended testicles and hypospadias. One testicle is palpable in the left part of the scrotum.

Although brought up as a girl the child always had male tendencies, playing with boy's toys, very athletic and always considered to be a "tomboy" and accepted

as such. The first time his parents noticed that something was wrong, was in the early teenage period when there were no signs of female secondary sexual characters. Then, at the age of 14, the child had an attack of appendicitis and at laparotomy no uterus, ovaries, or Fallopian tubes were found. The problem was discussed by the surgeon with the parents and it was decided at that time that once the child had up to then been brought up as a female, they should leave things as they were, and he should carry on leading a "female life".

This was done. The child grew up to be a fully mature adult, with masculine musculature, bone growth and voice, but no facial hair growth. He had to wear a brassiere although he had normal healthy male breasts and he wore female clothing. The patient in himself feels male — his sexual attraction has always been to the female sex, and he has had, on occasions, sexual intercourse and ejaculation. People think of him as a "freak" of nature. He is not accepted by females as a normal male because of his female clothes, etc., and of course, males look upon him as a social misfit. Since the age of 14 he has worked in his father's tailoring shop. He is called by his female name, but as stated before, he is not "accepted" as female either by males or by females.

He has been quite depressed about this problem but kept his feelings to himself, hardly ever discussing the matter with his parents or with anybody else. But on many occasions, he was so depressed that for days on end, he would not leave his home and on occasion he even contemplated suicide. Eventually at the age of 24, he talked the matter over fully with his parents and with a general practitioner and he was seen in consultation at the beginning of December 1973.

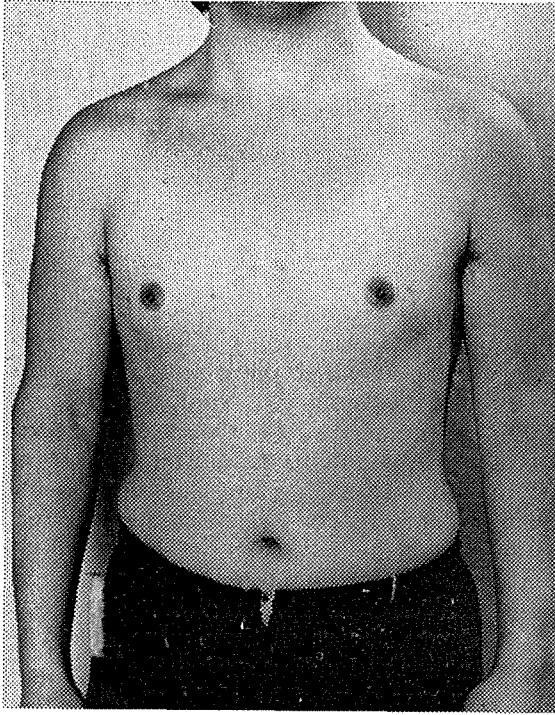


Fig. 1

On examination his general condition was found to be excellent, except for the fact that he suffers from psoriasis. He is a pleasant person to talk to, very sensitive, but quite pleased that something should be done about his problem. He is quite cooperative and on the whole, has a good sense of humour and is quite understanding. He is well built for his age though rather on the short side, being 5 feet 4 inches tall and weighing ten stones.

Full physical examination showed no abnormalities, except that, though his build is masculine, with very muscular legs, arms and back, and his body hair is male in distribution, his facial hair is scanty. External genitalia — pubic hair abundant, male in distribution. There is a cleft scrotum, and a testicle is palpable on the left side. There is also perineal hypospadias and a small penis, the urethra opening in the scrotal cleft at the base of the penis.

Investigations

1. Full blood count and picture nor-

mal. 2. Urinalysis — normal. 3. Intravenous pyelogram — normal. (No abnormalities in kidneys, ureters, bladder and urethra). 4. Chromosome pattern — male. 5. Buccal smears — male.

Chromosome pattern report

Chromosome preparations were carried out from peripheral blood culture. Karyotype showed 46 chromosomes: 22 autosomes and XY sex chromosomes. Chromosome morphology normal. Diagnosis — Karyotype is typical of a male.

Management

In managing this patient the psychological trauma he was suffering from had first to be dealt with. The patient felt male and wanted to lead a male life. The nature of his congenital abnormalities was fully explained and he was reassured that quite a lot could be done to put end to his unease.

A formal application to have him registered as male, on medical grounds,

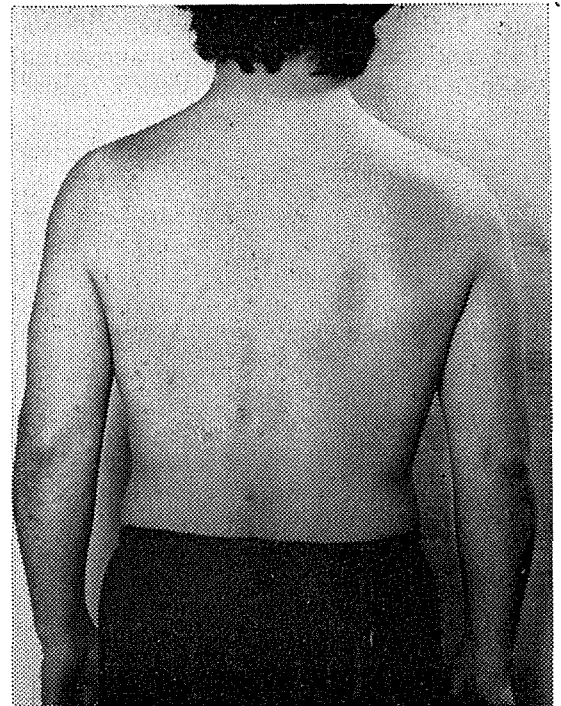


Fig. 2

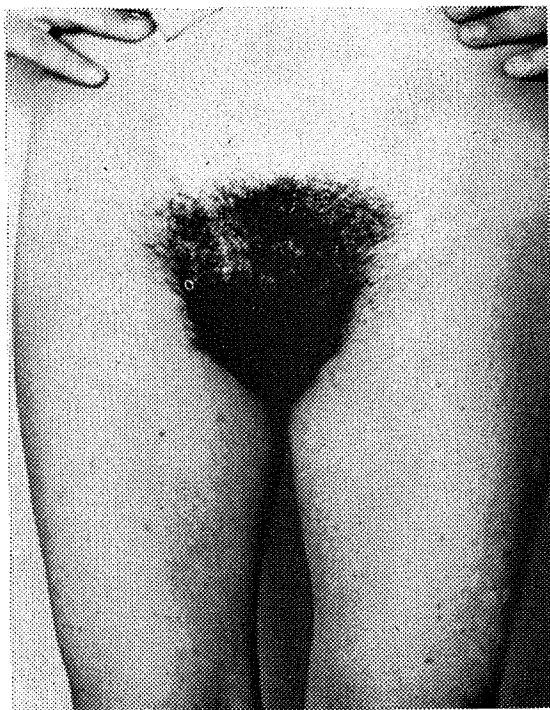


Fig. 3 Appearance of external genitalia.

was made through the Chief Government Medical Officer to the Crown Advocate General on the 26th January 1974. After a series of complicated legal discussions, during which medical evidence was given on several occasions, this was done and the following formal legal notice was published in the Malta Government Gazette for the 9th April 1974, over the signature of Mr. J. V. Borg A./Registrar.

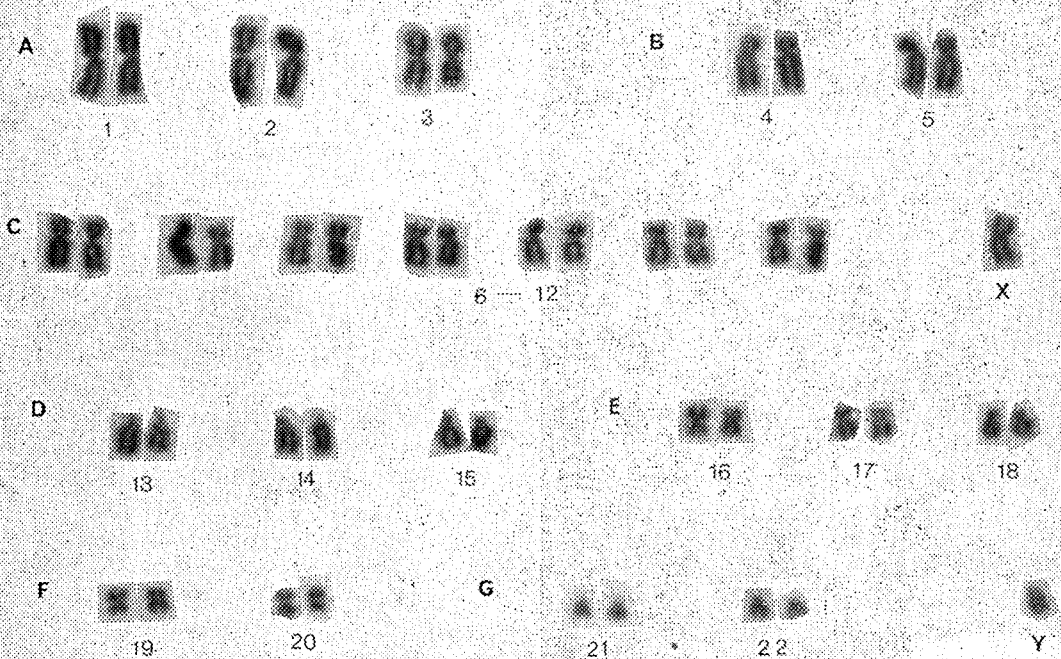
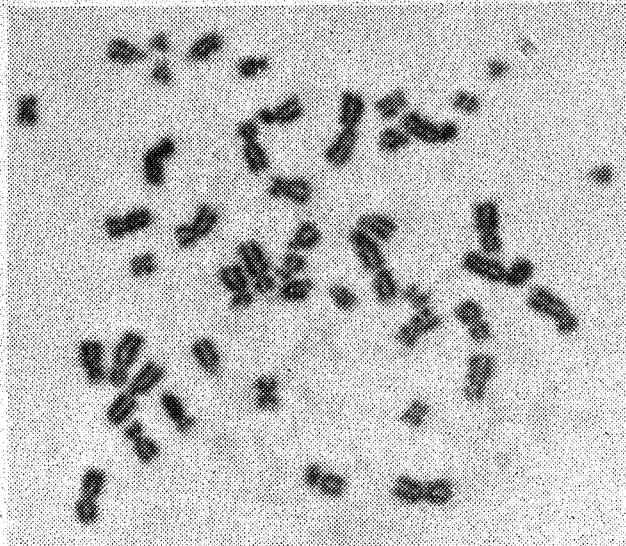
"It is hereby notified in virtue of the powers conferred on it by Section 293 (a) of the Civil Code, the Court of Revision of Notarial Acts, by a decree, dated the 27th Day of March 1974, ordered the correction of the ACT OF BIRTH of M.M. bearing number 7285 of the year 1948, in the sense that in the column entitled "SEX" the word "Female" be substituted by the word "Male"; In the column entitled "Name and Surname", the names "Maria, Stella, Paolina, Giuseppa, Tonina" be substituted by the names "Mark, Paolo, Giuseppi and Anthony" and in the column entitled "Name or Names by

which the child is to be called", the names "Maria Stella" be substituted by the name "Mark".

In the Registry of the Court of Revision of Notarial Acts, this 29th day of March 1974."

This solved the majority of the patient's psychological problems. He is now legally a male with a male passport and he could officially start living a "male" life. He is already wearing male clothes. But it is not easy for him to do this in the village, where for 25 years he was always considered to be female — a strange female at that. However the patient is ready to make a new start in life in the United Kingdom, where he has relatives residing and where things would be easier for him.

The second step in the management of the patient is to correct as far as possible the congenital abnormalities of the male genitalia. The external genitalia still look female at first glance. But as described above, the problem is one of cleft scrotum, with perineal hypospadias, small penis and undescended testicles. One testicle can be felt in the left side of the split scrotum. The patient was seen by Mr. Peter Caldwell, F.R.C.S. of the Sphincter Research Unit, Exeter, on his recent visit to Malta under the auspices of the Health Department. Mr. Caldwell assessed the case and gave a very good prognosis, to the patient. In fact, the case will be operated upon in Exeter in the near future. The scrotum can be easily repaired and the left testicle can be brought down. The perineal hypospadias can also be repaired. A search has to be made for the right testicle. If this is abdominal this will be removed to safeguard against complications in the future. Male hormones will have to be given. Surgery will further boost up the patient's morale. In the future, he will have near normal external genitalia and it will be easier for him to adapt himself fully to the male world. Though he is already 25 and, as he says a good part of his life has been wasted, he is looking forward to this operation which will, as far as humanly possible, put right nature's errors.



Chromosome pattern

Discussion

This case illustrates one type of intersex, the term denoting the condition in patients whose sex characteristics are incompletely differentiated. Several factors combine in determining sex namely the chromosomes, the hormonal patterns, the gonads, the sex organ anatomy as well as the person's psyche. Abnormality in any of these factors can give rise to conditions of intersex and hence we find several clinical types.

The principal types are:

- 1) Female intersex
- 2) Male intersex
- 3) True hermaphroditism
- 4) Sex chromosome variations (e.g. Turner's and Klinefelter's Syndromes)
- 5) Local genital defect. (Nixon and O'Donnell, 1961).

Female Intersex

The Sex chromosomes are XX (female) and the gonads are ovaries, but a masculinising influence during foetal life has interfered with the development of the genitalia. There is usually only a urethral opening in the perineum instead of vaginal and urethral openings. The vagina opens instead into the wide posterior urethra. The clitoris is large but does not carry a urethra. The usual cause of this condition is congenital adrenal hyperplasia. Some patients develop severe electrolyte disturbances because of interference with the production of other adrenal hormones, the mineralocorticoids.

Another condition which presents a similar picture to adrenal female intersex, has been recognised recently in a number of infants. These children have been masculinised by progestin with which the mother was treated in early pregnancy. Here the adrenal hormone output is normal. The abnormalities are caused by the androgenic side effects of progestin therapy.

Male Intersex

In these conditions, the gonads are testes but the external genitalia are not

completely masculine. In one type the external genitalia and bodily form are purely female. The vagina is extremely short and the testicles may be in the posterior abdominal wall or inguinal region. This condition has sometimes been called one of "Testicular feminisation".

In another type the appearance of the external genitalia is equivocal but chromosomes are male. Testes will be found in the inguinal region or posterior abdominal wall.

True Hermaphroditism

This is extremely rare. Ovarian and testicular tissue is present. The anatomy of the genitalia varies widely but there is usually phallus, uterus, vagina and scrotum. The scrotum may contain a testes or ovotestes or the gonads may be internal in the usual ovarian position. Sex chromation is equivocal.

Sex Chromosomal Aberrations

Two types are Turner's syndrome and Klinefelter's Syndrome.

In Turner's syndrome the patient is a stunted girl with webbing of the neck, a low hair line, cubitus valgus and other anatomical abnormalities. These patients have only one sex chromosome — X0 instead of XY (male) or XX. There is a failure in gonadal differentiation or gonadal agenesis and they have amenorrhea.

The much rarer Klinefelter's syndrome appears as a mirror image of Turner's syndrome. At puberty there is eunuchoidism and gynaecomastia in apparent males. The chromosome constitution is XXY — an extra chromosome being present.

Local Genital Defect

This is illustrated by the case discussed. Severe hypospadias with bilateral undescended testes and cleft scrotum may be mistaken for female pseudo-hermaphroditism.

One must finally mention that a person's attitude to sex depends to some extent on upbringing and so whatever medical or surgical measures may be

necessary have to be carried out as early after birth as possible. If, as in our case, diagnosis is late, the patient's attitude to sex is of the utmost importance regarding management.

Acknowledgements

I would like to thank Dr. Vincent Busuttill for referring the patient and Dr.

Alfred Cuschieri of the Department of Anatomy, Royal University of Malta for kindly doing the chromosome studies.

Reference

H.H. Nixon and Barry O'Donnell — 1961, p. 185. "Essential of Paediatric Surgery," (Heinemann, London).