

# A CASE OF OCULO-AURICULO-VERTEBRAL DYSPLASIA (Goldenhar syndrome)

F. DAMATO

M.D., D.O., D.O.M.S., F.R.C.S.

*St. Luke's Hospital*

## Summary

**This is a report on a case of Goldenhar syndrome. It shows the usual association of auricular appendages, epibulbar dermoid and vertebral abnormalities.**

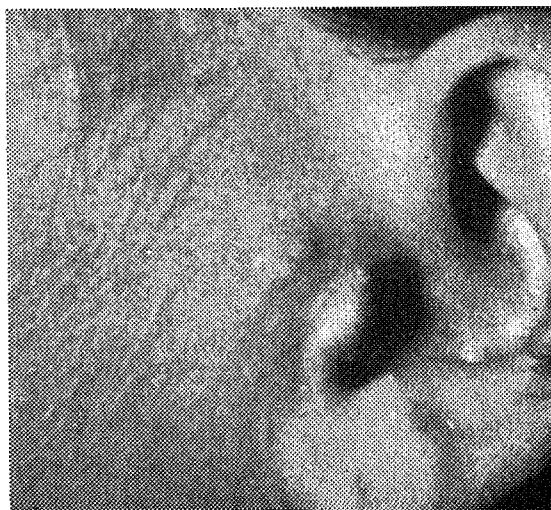Following upon the report by Goldenhar (1952) of the association of epibulbar dermoids, auricular appendages and blind fistulae in the preauricular area, his name has become linked with this particular syndrome. The vertebral anomalies were not reported until later (Sugar *et al.* 1966) and the condition has now become known as oculo-auriculo-vertebral dysplasia.

Though many additional abnormalities have been described epibulbar dermoids or dermolipomata and auricular deformities are the most important and constant abnormalities in this syndrome.

## Case report

A girl J.G. now aged 12, was reported at birth to have two "supernumerary ears", two nodular appendages in front of the tragus of the left ear. On 13.3.67 when she was operated upon for appendicitis, the two nodules were excised. However, it was reported that at the end of the operation, a small cartilaginous remnant was still palpable under the skin. At present, examination of the region anterior to the

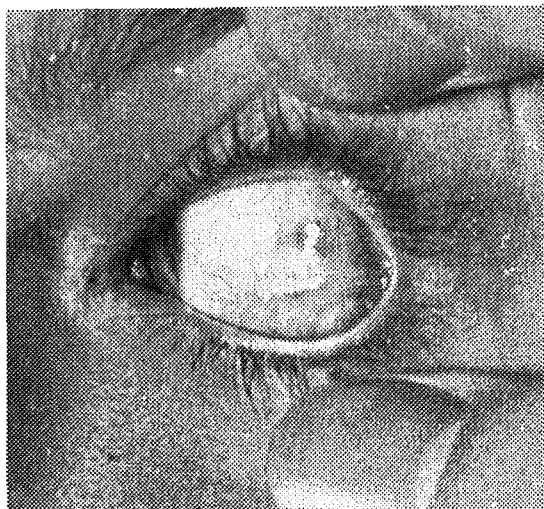
tragus shows a scar; and behind it there is a small hard nodule. (Fig. 1)



**Fig. 1**

The girl was brought again on the 29.1.74 for a growth in the outer canthus of the left eye. Examination showed the presence of a greyish red dermolipoma, occupying the whole extent of the outer canthus for a distance of 5 mm from the angle. There was no impairment of movement of the external Rectus. Apparently, the growth has passed unnoticed for all these years and lately has increased in size. (Fig. 2)

On the 4.2.74 she was operated upon under general anaesthesia. Through a verti-



**Fig. 2**

cal incision in the bulbar conjunctiva, a dense mass of fibrofatty matter mixed with hair and intimately adherent to the con-

junctiva, sclera and the insertion of the external Rectus was gradually dissected out. Intense chemosis and some discharge were present for a fortnight after the operation. Eventually, the wound healed without leaving any impairment of the movement of the external Rectus.

Histological exam showed a subconjunctival admixture of mature fibrous tissues and adult type fat. Some lymphoid cell aggregates were present (conjunctival fibrolipoma). X-ray examination of the chest showed a mild dorsal scoliosis and fusion of the anterior ends of the 4th and 5th ribs. There is as well a Spina Bifida occulta of the first sacral vertebra.

### References

- GOLDENHAR (1952). *J. Genet. Hum.* 1, 243.  
 SUGAR (1966). *Amer. J. Ophth.* 62, 678.