

## Case Report

# Leiomyosarcoma of the Distal Ureter: a Case Report

Gerald Busuttill, Fabian Bonello, Stephen Mattocks

**Abstract**

Leiomyosarcoma of the genitourinary tract is a rare malignancy generally having a poor prognosis, with scarce literature having been published. This case report outlines the clinical progression of a 43-year-old that presented with macroscopic haematuria and was subsequently diagnosed with leiomyosarcoma of the distal ureter.

**Keywords**

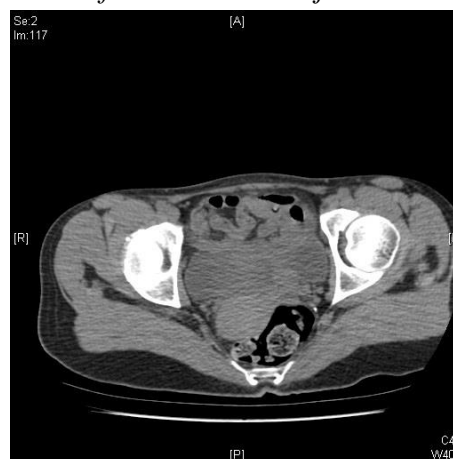Leiomyosarcoma, ureter, haematuria

**Introduction**

Leiomyosarcoma of the ureter is an uncommon urological malignancy which is as yet rather poorly understood, with consequent scant coverage in current literature. This malignancy has been always associated with a poor prognosis, although 5-year survival rates have improved over the years. The following describes a ureteric leiomyosarcoma in a 43-year-old woman.

The patient is a 43-year-old lady with no previous medical history who presented to the emergency department with a one-month history of loin to groin pain radiating to the back and over 10 episodes of haematuria with clots in the previous two months. An ultrasound of the urinary tract showed severe hydronephrosis of the left kidney with a hydroureter that could be followed down to the bladder. This was followed up by a non-contrast CT scan that identified a well-defined, lobulated soft tissue mass at the left vesicoureteric junction that was causing the ureteric obstruction (Figure 1).

**Figure 1:** well-defined, lobulated soft tissue mass at the left vesicoureteric junction.



At cystoscopy, a soft tissue mass originating from the left distal ureter and involving the bladder wall in the vicinity of the ureteric orifice was resected and the left ureter was stented with a double J stent. An initial diagnosis of high grade urothelial carcinoma involving the muscle wall (pT2G3 WHO classification 1973) was made on histological examination of the resected tissue. A positron emission tomography scan using fludeoxyglucose tracer did not show any regional or distant metastases. Because of the exceedingly rare incidence of these tumours, a specific staging system for sarcomas of the ureter does not exist and the TNM staging for transitional cell carcinoma of the ureter is used as published by the American

**Gerald Busuttill** FEBU, FRCSEd Urol\*

Urology Unit,  
Department of Surgery  
Mater Dei Hospital  
geraldbusu@gmail.com

**Fabian Bonello** MD

Urology Unit,  
Department of Surgery  
Mater Dei Hospital

**Stephen Mattocks** FRCS Urol, FEBU

Urology Unit,  
Department of Surgery  
Mater Dei Hospital

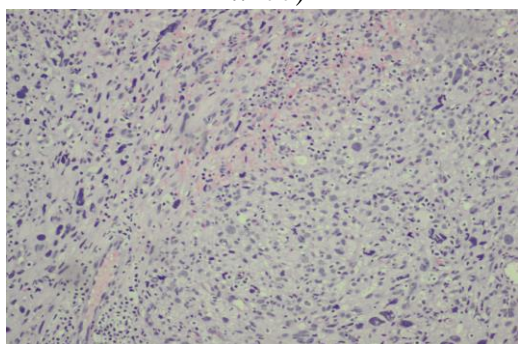
\*Corresponding Author

## Case Report

Joint Committee on Cancer in 2009. Clinical staging of our patient using this system would be T2N0M0 at presentation.

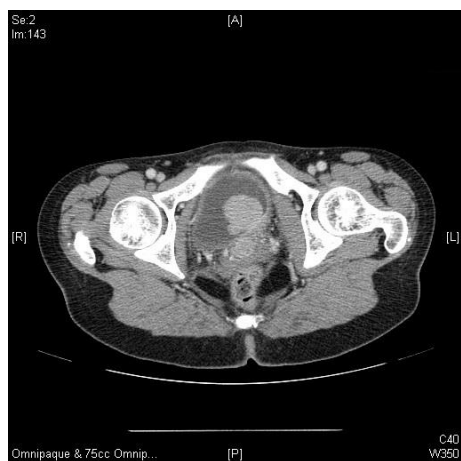After discussion at a multi-disciplinary meeting it was decided to proceed to open left nephroureterectomy. On histological examination of the operative specimen, the diagnosis was revised to pleomorphic leiomyosarcoma (Figure 2) obstructing the ureter with invasion of the bladder wall (with positive surgical margins).

**Figure 2:** Pleomorphic tumor composed of irregular sheets of poorly-differentiated neoplastic cells with occasional bizarre nuclei which are SMA and CD99 positive, p63, CK7, CK20, Desmin, HHF-35, CD117 and CD34 negative. (HE stain, x200)



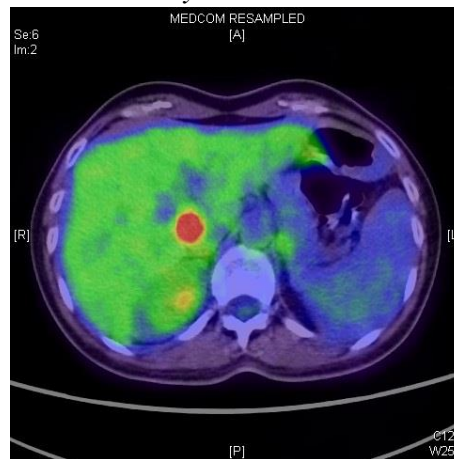
The patient presented again a year after her surgery with multiple episodes of haematuria. CT scan showed locally recurrent disease with another lobulated mass close to the original site of the left ureteric orifice with extensive involvement of the bladder wall (Figure 3). Repeat transurethral resection and histological examination confirmed recurrence of the original disease process.

**Figure 3:** CT showing local recurrence of disease



Repeat fludeoxyglucose PET scanning this time showed multiple metastases to liver and lung (Figure 4), consequently ifosfamide and epirubicin chemotherapy was commenced.

**Figure 4:** PET imaging showing liver involvement by disease



This was shortly followed by an episode of severe haematuria requiring multiple blood transfusions and bilateral embolization of the anterior division of the iliac arteries. Local pelvic progression of the malignant process resulted in contralateral renal obstruction and renal failure which was treated with percutaneous nephrostomy diversion, followed by pelvic external beam radiotherapy in an effort to control local symptoms.

Over the following 6 months, the patient was admitted multiple times for blood transfusions following recurrent episodes of gross intractable haematuria, progressive general deterioration and renal dysfunction eventually resulting in death.

## Discussion

Soft tissue sarcomas are the commonest mesenchymal tumors of the urinary tract, accounting for 1-2% of malignant genitourinary tumors and 2.1% of all sarcomas,<sup>1</sup> with leiomyosarcomas comprising 50% of cases, rhabdomyosarcomas 20% and the rest being rare histological subtypes.<sup>2</sup> In view of the rarity of this malignancy, published literature on the subject is scarce. Understanding of the etiology and pathogenesis of the disease is rather limited, with retinoblastoma 1 gene mutation, previous pelvic radiotherapy and use of cyclophosphamide being considered as likely aetiological agents.<sup>3-4</sup>

Most case reports published to date have involved young female patients, however with less

than 20 cases documented in the literature it is difficult to establish definitive epidemiological patterns.

Most data available pertains to the prognosis of the disease, derived from several case series and multicentre studies over the years.<sup>4-6</sup> Mackenzie et al in 1968 reported that the disease has a poor prognosis, with 10% 3-year overall survival<sup>7</sup>. Survival has improved over the years with recent studies reporting 5-year disease specific survival in the order of 55 – 60%, most likely related to early diagnosis with the more frequent use of cross sectional imaging.<sup>5-7</sup> The most important factors determining prognosis are metastases at presentation and free margins on surgical resection.<sup>2</sup> Rosser *et al* showed that the most common symptoms at presentation are gross hematuria (81% of patients), followed by increased urinary frequency (28%), and dysuria (19%).<sup>8</sup> As diagnosis is often late, with less than 15% of patients presenting at T1 clinical stage.<sup>9</sup> Indeed, our patient was staged at T2 at presentation, patients presenting with muscle invasive disease are considered to have locally advanced disease and invariably their prognosis is poor.

As no randomized controlled trials comparing treatment options in leiomyosarcoma of the urinary tract have ever been published, treatment is largely empirical, with extrapolation of methods used in treatment of epithelial tumors of the ureter. In the above case, surgical excision of the kidney, neighboring lymph nodes and ureter was performed.<sup>10</sup>

In addition to this, the role of adjuvant chemotherapy using multimodal sarcoma chemotherapy protocols using doxorubicin or epirubicin, ifosfamide, cisplatin and docetaxel and external beam radiotherapy have also been advocated, especially in cases of partial cystectomy.<sup>5</sup>

Spiess *et al* (2007) showed that local recurrences occur in about 16% of cases, whereas metastases, most commonly in lung, liver brain and bone, occur in 53% of cases. In metastatic disease, chemoradiation remains the only palliative option available in patients with good performance status who can tolerate such regimens.<sup>5</sup>

This case report outlines the salient features of leiomyosarcoma of the ureter and adds to the published literature on such a rare entity, which should be part of the differential diagnosis in

patients presenting with soft tissue masses in the region, especially in young female patients.

### References

1. Jemal A, Murray T, Ward E et al. Cancer statistics, 2005. *CA Cancer J Clin* 2005;55:10-30.
2. Lee G, Lee SY, Seo S et al. Prognostic Factors and Clinical Outcomes of Urological Soft Tissue Sarcomas. *Korean J Urol* 2011; 52: 669-673.
3. Izumi K, Mizokami A, Sugimoto K et al. Role of surgical resection in adult urological soft tissue sarcoma: 25-year experience. *Urol Int* 2010; 84(3): 309-14.
4. Mondaini N, Palli D, Saieva C et al. Clinical Characteristics and Overall Survival in Genitourinary Sarcomas Treated with Curative Intent: A Multicenter Study. *European Urology* 2005; 47: 468-473.
5. Spiess PE, Kassouf W, Steinberg JR et al. Review of the M.D. Anderson experience in the treatment of bladder sarcoma. *Urologic Oncology: Seminars and Original Investigations* 2007; 25: 38-45.
6. Mackenzie A, Whitmore WF, Melamed MR. Myosarcomas of the Bladder and Prostate. *Cancer* 1968; 22(4): 833-844.
7. Dotan ZA, Tal R, Golijanin D et al. Adult genitourinary sarcoma: the 25-year Memorial Sloan-Kettering experience. *J Urol* 2006; 176(5): 2033-8.
8. Rosser CJ, Slaton JW, Izawa JI, Levy LB, Dinney CP: Clinical presentation and outcome of high-grade urinary bladder leiomyosarcoma in adults. *Urology* 2003, 61:1151-5.
9. Labanaris AP, Zugor V, Meyer B et al. Urinary bladder leiomyosarcoma in adults.. *Int Urol Nephrol* 2008; 40(2): 311-6.
10. Latchamsetty KC, Porter CR, Treatment of Upper Tract Urothelial Carcinoma: A Review of Surgical and Adjuvant Therapy *Rev Urol*.2006 Spring, 8(2): 61-70.