



# THE UNIVERSITY *of* EDINBURGH

## Edinburgh Research Explorer

### Isolated Mediastinal Lymphadenopathy - Performance of EBUS-TBNA in Clinical Practice

**Citation for published version:**

Velu, PP, Reid, PA, Wallace, W & Skwarski, KM 2017, 'Isolated Mediastinal Lymphadenopathy - Performance of EBUS-TBNA in Clinical Practice' *Journal of the Royal College of Physicians of Edinburgh*, vol. 47, no. 1. DOI: 10.4997/JRCPe.2017.111

**Digital Object Identifier (DOI):**

[10.4997/JRCPe.2017.111](https://doi.org/10.4997/JRCPe.2017.111)

**Link:**

[Link to publication record in Edinburgh Research Explorer](#)

**Document Version:**

Peer reviewed version

**Published In:**

*Journal of the Royal College of Physicians of Edinburgh*

**General rights**

Copyright for the publications made accessible via the Edinburgh Research Explorer is retained by the author(s) and / or other copyright owners and it is a condition of accessing these publications that users recognise and abide by the legal requirements associated with these rights.

**Take down policy**

The University of Edinburgh has made every reasonable effort to ensure that Edinburgh Research Explorer content complies with UK legislation. If you believe that the public display of this file breaches copyright please contact [openaccess@ed.ac.uk](mailto:openaccess@ed.ac.uk) providing details, and we will remove access to the work immediately and investigate your claim.



**Isolated Mediastinal Lymphadenopathy - Performance of EBUS-TBNA in  
Clinical Practice**

*Prasad Palani Velu<sup>1</sup>, Philip A Reid<sup>2</sup>, William A Wallace<sup>3</sup>, Kristopher M Skwarski<sup>1</sup>*

1 – Department of Respiratory Medicine, Royal Infirmary of Edinburgh, 51 Little France  
Crescent Edinburgh EH16 4SA

2 - Department of Respiratory Medicine, Western General Hospital, Crewe Road  
South, Edinburgh EH4 2XU

3 – Department of Pathology, Royal Infirmary of Edinburgh, 51 Little France Crescent  
Edinburgh EH16 4SA

**Corresponding Author:**

Dr Prasad Palani Velu

Department of Respiratory Medicine,

Royal Infirmary of Edinburgh

51 Little France Crescent

Edinburgh EH16 4SA

United Kingdom

+447595532926

[prasadpalanivelu@googlemail.com](mailto:prasadpalanivelu@googlemail.com)

**Abstract** (150 words)

**Introduction** - Isolated Mediastinal Lymphadenopathy (IML) is an increasingly common finding as a result of the ubiquity of cross-sectional thoracic imaging.

**Objectives** - We investigated the performance of Endobronchial-Ultrasound Guided Transbronchial Needle-Aspiration (EBUS-TBNA) in establishing a pathological diagnosis in patients with IML.

**Methods** – Retrospective examination of all consecutive EBUS-TBNA examinations performed over 4 years at a tertiary referral centre. Final diagnosis was made using pathology reports, correlated with clinical features and the results of any other investigations.

**Results** - 126 EBUS-TBNA examinations were performed to investigate IML. A positive pathological diagnosis was made following EBUS-TBNA in 54 cases (42.9%). When the results of further investigations and variable radiological follow up was included, the final sensitivity of EBUS-TBNA to make a diagnosis in IML was 80.3% (95% CI 68.7% to 89.1%).

**Conclusions** - This study confirms that EBUS-TBNA has a good yield for both benign and malignant pathologies resulting in IML.

## Introduction

Isolated mediastinal lymphadenopathy (IML) is an increasingly common finding associated with the ubiquity of thoracic CT imaging. For the purpose of this study, we defined IML as the presence of mediastinal or hilar lymph node enlargement (either in single or multiple lymph node stations), without the presence of an obvious associated malignancy or alternative causation at the time of investigation.

IML comprises a heterogeneous group of conditions with varying aetiology including occult metastatic malignancy, benign granulomatous disorders, lymphoproliferative disorders, or reactive lymphadenopathy that may relate to underlying conditions such as interstitial lung disease or rheumatological disorders <sup>[1]</sup>. Patients identified as having IML on imaging will have a provisional diagnosis formulated upon clinical and radiological features, however there is often a need to establish a tissue diagnosis before proceeding with management. These patients are commonly referred to Respiratory Services for further investigation.

Surgical mediastinoscopy has previously been regarded as the 'gold standard' to obtain tissue to make a pathological diagnosis in mediastinal adenopathy. However, this technique does not allow access to all lymph node stations and is associated with a not-insignificant morbidity as it is performed under general anaesthesia <sup>[2]</sup>. The utility of Endobronchial Ultrasound-guided Transbronchial Needle Aspiration (EBUS-TBNA) as an alternative to conventional mediastinoscopy for the diagnosis and staging of patients with suspected lung cancer has been firmly established <sup>[3, 4]</sup>. EBUS-TBNA is a technique that utilises endoluminal ultrasound technology during bronchoscopy to identify lymph nodes that are amenable to sampling using trans-bronchial needle aspiration. Patient selection for this procedure is similar that for conventional bronchoscopy (FEV1 > 1.0L, Oxygen saturations >90% on room air and no coagulopathy or other contraindications to needle sampling) and the procedure can be

performed under sedation as opposed to general anaesthesia. Recent studies have demonstrated superior sensitivity, cost savings and shorter time to treatment that may translate to a survival benefit when EBUS-TBNA is pursued as a first-line investigation for the investigation of non-small cell lung cancer (NSCLC) [5].

There is also emerging evidence supporting the utility of EBUS-TBNA to investigate IML with reported sensitivities of EBUS-TBNA ranging from 82.7% to 92% [1, 6]. Individual studies have reported variable sensitivity of EBUS-TBNA according to the aetiology of IML, including 83 – 85% in sarcoidosis and 38% in lymphoproliferative disorders [7, 8, 9].

A particular difficulty encountered with the use of EBUS-TBNA in the investigation of IML is the high prevalence of 'non-diagnostic' samples, where only benign or reactive cells are obtained following cytological examination. Reactive mediastinal lymphadenopathy is relatively common and samples obtained in these cases are difficult to differentiate from low-grade lymphoma. This presents a dilemma to clinicians and may necessitate further investigations in cases where samples from EBUS-TBNA are non-diagnostic.

Strategies employed to overcome the problem of non-diagnostic samples following EBUS-TBNA in published studies to date range from mediastinoscopy in all patients (as a comparator or gold standard) to clinical and radiological surveillance [1, 6]. These patients however formed part of a 'trial population', and were able to undergo both EBUS-TBNA and/or mediastinoscopy as a comparator. However, this is not always the case in clinical practice due to patient fitness and preference.

There is limited evidence on the performance EBUS-TBNA to investigate IML in routine clinical practice. We aim to assess the diagnostic yield of EBUS-TBNA for IML in a

consecutive patient series. We also report the requirement for subsequent investigations (including mediastinoscopy) and follow-up strategies in cases where EBUS-TBNA yielded non-diagnostic samples.

## **Methods**

Sequential EBUS examinations performed over a 4-year period from January 2011 to December 2014 at the Royal Infirmary of Edinburgh (RIE) – a tertiary referral centre - were retrospectively reviewed. Referrals for EBUS examinations were accepted from a range of specialties. Procedures performed for the staging of lung cancer or for the investigation of a known/suspected primary malignancy (identified on prior cross-sectional imaging) with associated mediastinal lymphadenopathy were excluded from analysis. Patients were identified as having IML if there was evidence of mediastinal/hilar lymphadenopathy on cross-sectional imaging with no evidence of malignant aetiology identifiable on other imaging modalities or investigations to date.

All patients had a pre-sampling Computed Tomography (CT) scan of the thorax. Mediastinal lymph nodes were classified according to the International Staging System. All cases that proceeded to EBUS-TBNA had a minimum lymph node diameter of >10mm.

All procedures were performed or supervised by one of two lead lung cancer physicians. Intubation was performed via the oral route and sedation was achieved with intravenous Midazolam and Alfentanyl. EBUS was performed with the Olympus BFUS 260 endoscope and 22-gauge cytology needle. Images were achieved with an Olympus Prosound  $\alpha$ 10 ultrasound machine. Sonographic nodal characteristics and number of passes were not recorded. Nodal samples were transferred into 'Cytolyt' fixative and processed, as previously described utilising a 'thin layer' technique and subsequent cell blocks <sup>[10]</sup>. Further sections from cell blocks were stained

histochemically or immunohistochemically as indicated by the features identified.

A final diagnosis was made using cytopathology from EBUS-TBNA correlated with clinical picture at presentation and follow-up. In cases where a pathological diagnosis was not obtained following EBUS-TBNA, the decision to organise further investigations was made by the referring teams. Referring teams made a final diagnosis based on any additional pathology, clinical features and multi-disciplinary team decision. Information on further investigations and radiological follow-up were obtained from review of medical records. Statistical analysis was performed using GraphPad Prism software.

## **Results**

A total of 826 EBUS examinations were performed during the 4-year study period. 700 examinations were excluded following identification of radiologically evident primary malignancy. The remaining 126 patients were classified as having IML and were included in the study. Median age was 60 and 87 patients (69.0%) were male. Patient characteristics are summarised in TABLE 1.

Results from EBUS-TBNA aspirates are summarised in FIGURE 1. A Pathological diagnosis was achieved following EBUS-TBNA in 54 cases (42.9%). EBUS-TBNA aspirates yielded benign or reactive lymphoid cells, not confirming a pathological diagnosis - in 72 cases (57.1%) while nodal sampling was insufficient or not achieved in 10 cases (7.9%).

### *Malignant Disease*

A total of 41 patients (32.5%) had a final diagnosis of malignancy in our data set (FIGURE 2). EBUS-TBNA yielded samples diagnostic of malignancy in 31 cases (24.6%). Features suggestive of malignant disease were identified following EBUS-

TBNA in 8 cases (6.3%) and further investigations were performed to confirm the diagnosis in 5 (3.9%) of these patients (two further patients received a consensus clinical diagnosis and one patient initially identified as having an EBUS-TBNA sample suspicious for malignancy was diagnosed with a viral myocarditis) (TABLE 2). Three further cases of malignancy were diagnosed following further investigations in patients where EBUS-TBNA yielded aspirates containing benign or reactive cells only.

A final diagnosis of lymphoma was made in 4 patients (3.2%). EBUS-TBNA provided a pathological diagnosis of lymphoma in 1 case (0.8%), suggested this diagnosis in two cases (1.6%, who went on to have confirmatory investigations) but missed a diagnosis of lymphoma in 1 (0.8%).

#### *Granulomatous Lymphadenitis*

Granulomatous lymphadenitis was identified in 23 cases (18.3%) following EBUS-TBNA. Sarcoidosis was the final diagnosis in 19 of these cases (15.1%), with 1 patient proceeding to have a confirmatory mediastinoscopy after EBUS-TBNA. The remainder of diagnoses were mediastinal TB (negative TB culture, clinical diagnosis) and Idiopathic Interstitial Pneumonia (sarcoidosis was the initial differential diagnosis considered, however a consensus diagnosis of Idiopathic Interstitial Pneumonia was made upon review of imaging). One patient underwent radiological follow up and one patient was lost to follow up.

#### *Samples where pathological diagnosis was not achieved*

EBUS-TBNA did not yield a pathological diagnosis 72 cases (57.1%). Further investigations to ascertain the diagnosis in these cases were performed in 16 cases (12.7%), of which 5 were mediastinoscopies (TABLE 2). Further investigations in cases with non-diagnostic samples yielded a pathological diagnosis in only 13 cases (10.3%) (FIGURE 3).



The remaining 59 cases (46.8%) were deemed to have reactive lymphadenopathy and underwent a combination of further investigations or radiological follow-up with CT chest or Positron Emission Tomography – Computed Tomography (PET-CT). Of these patients, 3 underwent repeat fibre-optic bronchoscopy and 1 underwent EUS but these procedures did not yield a pathological or alternative diagnosis.

### *Performance*

Ideally, sensitivity of EBUS-TBNA would have been assessed against the accepted gold standard (mediastinoscopy) as a comparator. Given however that not all patients in this cohort underwent further investigations, we adopted a pragmatic approach towards a sensitivity calculation.

A 'True Positive' was accepted as the ability of EBUS-TBNA to identify a pathological diagnosis when there was one apparent (ie. Malignant cells or granulomatous lymphadenitis in sarcoidosis). 'True Negatives' were deemed to be cases of reactive lymphadenopathy where EBUS-TBNA identified cytologically benign or reactive lymphoid cells only.

Including cases where nodal sampling was not achieved, the sensitivity of EBUS-TBNA for a diagnosis in our cohort was 80.3% (95% CI 68.7% to 89.1%).

### **Discussion**

A considerable number of EBUS-TBNA examinations (15.3%, 126/826) were performed for the investigation of IML.

A significant proportion of patients in our cohort had a final diagnosis of malignant disease (41 cases, 32.5%) indicating that occult malignancy is an important cause of

mediastinal lymphadenopathy. Malignant disease was identified in 8 cases (6.3%) where EBUS-TBNA failed to achieve a pathological diagnosis (including 3 cases of lymphoma), highlighting the importance of further investigations to obtain a pathological diagnosis where malignancy is suspected even when FNA cytology is negative.

In our unselected series, the overall sensitivity of EBUS-TBNA to yield a pathological diagnosis was 80.3%, in comparison to the sensitivity reported by other studies: 92% by Navani *et al*, and 82.7% by Evison *et al* <sup>[1, 6]</sup>. The large number of negative examinations in our cohort could be attributed to the high proportion of patients with reactive lymphadenopathy (46.8%, 59/126 cases) - similar to the proportion reported by Evison *et al* (48% reactive lymphadenopathy). The mean age of our study population was 60 compared to 58.6 in Evison *et al*, providing further evidence of an association between increasing age and reactive lymphadenopathy <sup>[1]</sup>.

Seventeen (13.5%) patients in total cohort underwent further investigations, 5 of which were mediastinoscopies (one of these was confirmatory despite a positive EBUS-TBNA sample for granulomatous lymphadenitis). It can be postulated that diagnostic EBUS-TBNA helped avoid mediastinoscopy in a proportion of patients in this cohort. In our cohort, patients with non-diagnostic samples who did not undergo further investigations underwent radiological follow-up or were followed up by the referring clinical teams. There was variability in modality used (CT Chest or PET-CT) and duration of follow-up.

The retrospective nature of our study limits our ability to correct for selection bias but patient age was a likely determinant in a low threshold for referral for EBUS-TBNA compared to threshold for referral for subsequent mediastinoscopy when pathology from EBUS-TBNA was non-diagnostic (only 5 in our cohort). The retrospective nature

of our study also limited our ability to access information on rationale behind follow-up strategies pursued by referring teams. Generally there was wide variability between the decision to pursue further investigations or pursue a surveillance strategy using cross-sectional imaging. We believe this is reflective of current clinical practice however we would have preferred to have been able to report the rationale behind these decisions. The lack of a comparator such as mediastinoscopy in patients with non-diagnostic samples limits our interpretation of performance of EBUS-TBNA, allowing us to report an estimated sensitivity but not a specificity, negative or positive predictive values. Lastly, given variability in the decision to pursue further investigations or surveillance, it is possible that some pathological diagnoses may have been missed and reactive lymphadenopathy may have been overcalled.

This study confirms that EBUS-TBNA has a good yield for both benign and malignant pathologies resulting in IML and should be considered as a non-invasive alternative to mediastinoscopy, particularly in cases where lymphoma is thought less likely. Requirement for further investigation and/or surveillance following non-diagnostic cytology from EBUS-TBNA should be reviewed on a case-by-case basis in collaboration with referring teams in a multi-disciplinary forum. When practical, a tissue diagnosis should be pursued, particularly if there are concerns that the diagnosis could be malignancy. A more clearly defined surveillance strategy to standardise follow-up cases where a tissue diagnosis is not obtained is advisable. This could mirror the strategy used to follow-up pulmonary nodules identified on cross-sectional imaging of the chest. Future work focusing on performance of surveillance strategies following non-diagnostic EBUS-TBNA would aid the development of a comprehensive and safe strategy for the investigation and management of IML.

Word Count: 2062



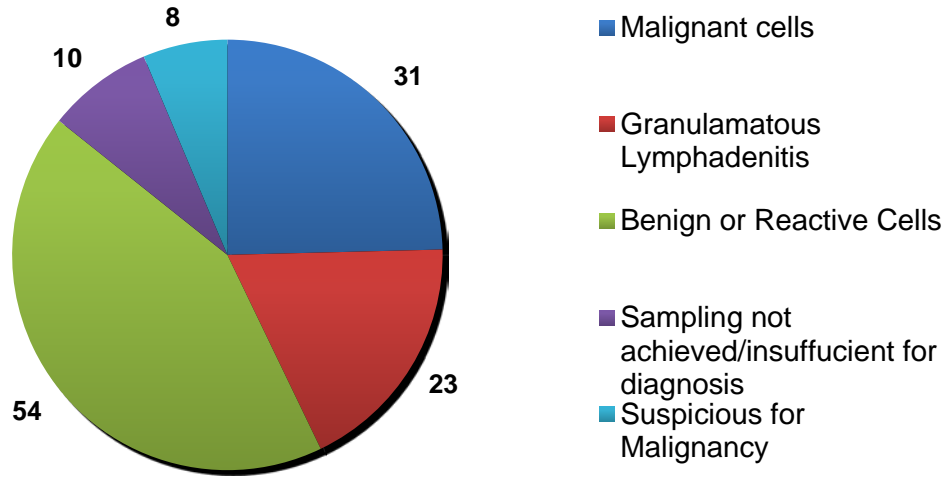
## References

1. Evison et al. A study of patients with isolated mediastinal and hilar lymphadenopathy undergoing EBUS-TBNA. *BMJ Open Respir Res.* 2014 31; 1(1): e000040.
2. Porte H, Roumilae D, Eraldi L, Cordinnier C, Puech P, Wurtz A. The role of mediastinoscopy in the diagnosis of mediastinal lymphadenopathy. *Eur J Cardiothoracic Surg* 1998; 13: 196 – 199.
3. Waller D, Skwarski KM. Is there still a role for mediastinoscopy as the first mediastinal staging procedure for lung cancer? *J R Coll Physicians Edinb.* 2013; 43: 137-43.
4. Navani N, Spiro SG & Janes SM. Mediastinal Staging of NSCLC with endoscopic and endobronchial ultrasound. *Nat Rev Clin Oncol.* 2009; 6(5): 278-86.
5. Navani N et al. Lung cancer diagnosis and staging with endobronchial ultrasound-guided transbronchial needle aspiration compared with conventional approaches: an open-label, pragmatic, randomised controlled trial. *Lancet Respir Med.* 2015; 3(4): 282-9.
6. Navani N et al. Endobronchial Ultrasound-guided transbronchial needle aspiration prevents mediastinoscopies in the diagnosis of isolated mediastinal lymphadenopathy: a prospective trial. *Am J Respir Crit Care Med.* 2012; 186 (3): 255-60.
7. Garwood S, Judson MA, Silverstri G, et al. Endobronchial ultrasound for the diagnosis of pulmonary sarcoidosis. *Chest* 2007; 132: 1298e304.
8. Tremblay A, Stather DR, Maceachern P, et al. A randomized controlled trial of standard vs endobronchial ultrasonography-guided transbronchial needle aspiration in patients with suspected sarcoidosis. *Chest* 2009; 136: 340-46.
9. Iqbal S, DePew ZS, Kurtin PJ, et al. Endobronchial ultrasound and lymphoproliferative disorders: a retrospective study. *Ann Thorac Surg,* 2012; 94(6): 1830-4.
10. Wallace WA, Monaghan HM, Salter DM, et al. Endobronchial ultrasound guided transbronchial needle aspiration and liquid based thin-layer cytology. *J Clin Path.* 2007; 60(4): 388-91.

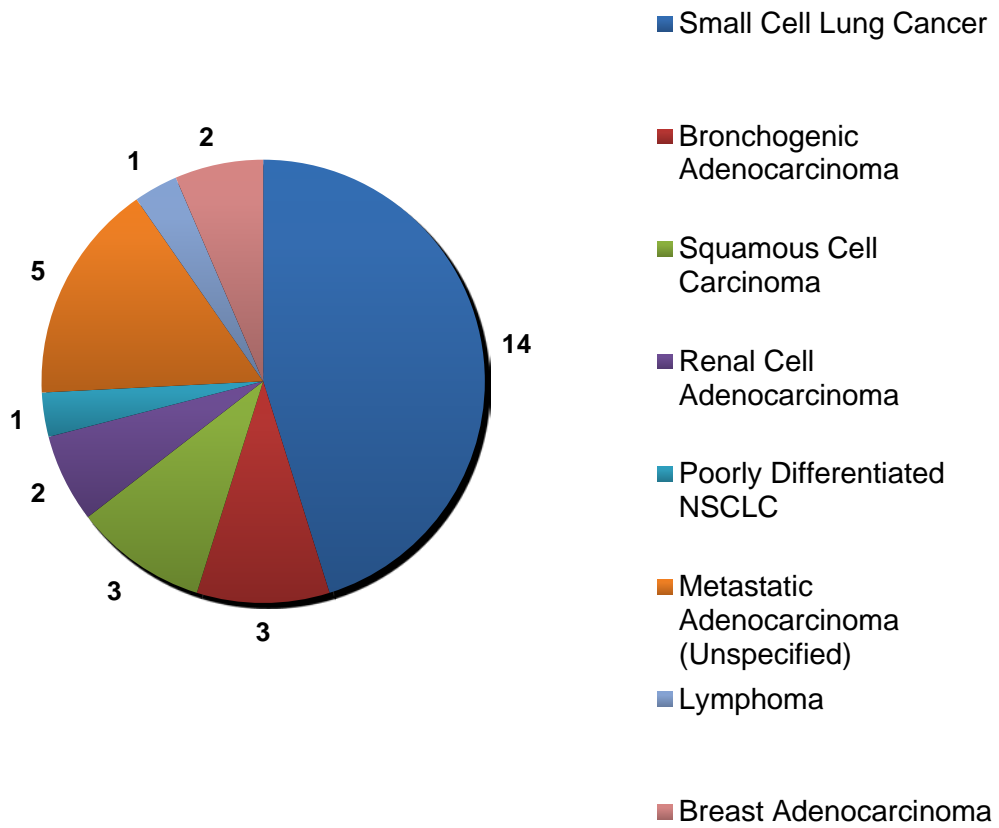
TABLE 1 – Patient Demographics (n=126); Hx – History.

<b>Smoking status</b>	
Non smokers	52 (41.2%)
<10 pack year Hx	19 (15.1%)
>10 pack year Hx	40 (31.7%)
Not available	15 (11.9%)
<b>Ethnicity</b>	
White British	108 (79.4%)
White European	7 (5.6%)
Black African	2 (1.6%)
Indian	4 (3.2%)
Pakistani	4 (3.2%)
Other	1 (0.8%)

**FIGURE 1 - Aspirates obtained following EBUS-TBNA**



**FIGURE 2 - Malignant Diagnoses identified with EBUS-TBNA aspirates**





**FIGURE 3 - Diagnoses Following Further Investigations in Cases with Non-Diagnostic EBUS-TBNA**

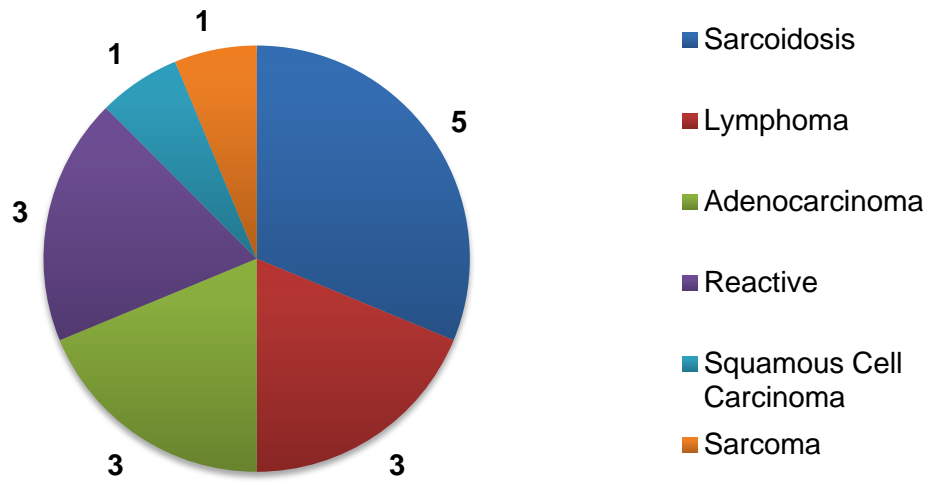


TABLE 2 – Summary of Further Investigations and Final Diagnosis according to initial cytology following EBUS-TBNA

Initial Cytology	Diagnostic Category; Number that underwent further investigations	Further Investigation	Pathological Diagnosis
Non-Diagnostic	Suspicious for Malignancy (8); 5 underwent further investigations	Surgical resection (1)	Sarcoma
		Core Biopsy of Peripheral Lymph Node (1)	Lymphoma
		Bone Marrow Biopsy (1)	Lymphoma
		Fibre-optic Bronchoscopy at 3 months (1)	Squamous cell carcinoma
		EBUS-TBNA at 6 months (1)	Adenocarcinoma
	10 underwent further investigations	Lymph node biopsy (1)	Lymphoma
		Mediastinoscopy – non-diagnostic (1) followed by VATS Biopsy	Reactive Lymphadenopathy - Inflammation and Fibrosis with <i>Aspergillus</i> colonisation
		Mediastinoscopy (1)	Reactive Lymphadenopathy - Sinus Histiocytosis
		Mediastinoscopy (2); 1 mediastinoscopy was non-diagnostic	Sarcoidosis
		VATS Biopsy (1)	Lepidic Adenocarcinoma
		EBUS (1)	Adenocarcinoma
		EUS (1)	Reactive
		EUS-B (1 – non-diagnostic)	Sarcoidosis (Clinical diagnosis)
		Skin Biopsy (1)	Sarcoidosis
	Insufficient/No Nodal Sampling	2 underwent further investigations	Mediastinoscopy (1)
Skin biopsy (1)			Sarcoidosis

VATS – Video-assisted thorascopic surgery; EUS – Endoscopic Ultrasound Fine-Needle Aspiration; EUS-B – Endoscopic Ultrasound Fine-Needle Aspiration with an Endobronchoscope