



# THE UNIVERSITY *of* EDINBURGH

## Edinburgh Research Explorer

### Unexpected active tuberculosis on Post Mortem CT: A case report and review of the literature

**Citation for published version:**

McLaughlin, S, Kind, K, Thomson, L & Bouhaidar, R 2016, 'Unexpected active tuberculosis on Post Mortem CT: A case report and review of the literature' *Forensic Science International*, vol. 266. DOI: 10.1016/j.forsciint.2016.05.023

**Digital Object Identifier (DOI):**

[10.1016/j.forsciint.2016.05.023](https://doi.org/10.1016/j.forsciint.2016.05.023)

**Link:**

[Link to publication record in Edinburgh Research Explorer](#)

**Document Version:**

Peer reviewed version

**Published In:**

Forensic Science International

**Publisher Rights Statement:**

Author's final peer-reviewed manuscript as accepted for publication.

**General rights**

Copyright for the publications made accessible via the Edinburgh Research Explorer is retained by the author(s) and / or other copyright owners and it is a condition of accessing these publications that users recognise and abide by the legal requirements associated with these rights.

**Take down policy**

The University of Edinburgh has made every reasonable effort to ensure that Edinburgh Research Explorer content complies with UK legislation. If you believe that the public display of this file breaches copyright please contact [openaccess@ed.ac.uk](mailto:openaccess@ed.ac.uk) providing details, and we will remove access to the work immediately and investigate your claim.



# Unexpected active tuberculosis on Post Mortem CT: A case report and review of the literature

Siobhan McLaughlin \*, Kirsten Kind, Lynne Thomson, Ralph Bouhaidar

Edinburgh Forensic Radiology and Anthropology Imaging Centre, Royal Infirmary of Edinburgh, Little France Crescent, Edinburgh EH16 4SA, United Kingdom

## **Abstract**

Unexpected active Tuberculosis (TB) at autopsy represents a serious transmissible health risk to mortuary and laboratory staff. Post Mortem CT (PMCT) is widely accepted as a valuable adjunct to autopsy throughout the world, but the uptake and implementation varies from country to country. We present a case of unexpected active TB on PMCT and review the literature on the incidence of and risks from the condition. We use this unexpected finding, and the fact that PMCT was in this case also able to provide the information for parts I and II of the Death Certificate as a further argument for the routine use of PMCT by all Forensic Institutes.

## **Introduction**

Roentgen discovered X rays in 1895. Not even 100 years later, Godfrey Hounsfield and his team further expanded ionising radiation and undertook the first clinical Computerised Tomography (CT) scan on a patient in 1971. Since the initial discovery of both these modalities, they have been refined and finessed for application in living patients, with improvements in dose reduction and image resolution. Just as imaging has been increasingly used in the investigation of pathology in the living, so it seemed only natural that eventually it would be applied to the investigation of cause of death in the dead. Shortly after their discovery, plain films were used in court to document bullet fragments in a victim's leg <sup>i</sup>, and in the 1970's Wullenweber et al used Post Mortem CT (PMCT), again to document gunshot injuries <sup>ii</sup>

The use of PMCT in clinical and academic practice has increased throughout the world, and it is now globally accepted as a means of providing valuable information as to certain causes of death and as an adjunct to autopsy. <sup>iii iv</sup> Furthermore, the number of published papers on the subject increased 10 fold between the years 2000 and 2011, indicating a growth in both the use and acceptance of the modality.<sup>v</sup>

Acquiring CT images in the dead provides a very different challenge to those in the living. Imaging parameters must be altered to take in to account artefact from putrefying tissue and intravenous contrast, the cornerstone of imaging in the living, can only be used in large centres equipped with heart/lung bypass machines. Even then, it is limited to opacifying the vasculature, no longer providing the parenchymal organ enhancement which is so important in imaging of the living.

Image interpretation requires an experienced radiologist, accustomed to the unusual appearances of post mortem tissues. Normal post-mortem putrefaction (intravascular air and unaerated lung) can mimic the appearances of pathology to the untrained eye.

PMCT is particularly accurate in excluding catastrophic intracranial, thoracic or abdominal haemorrhage, and in the documentation of orthopaedic injuries<sup>vi</sup>. Radiopaque foreign bodies such as bullet fragments can be identified and mapped out prior to retrieval at autopsy, and fracture patterns can be established and interpreted before a scalpel has even been picked up. Also of value is the ability to store a permanent record of appearances which may be referred back to after the destructive process of autopsy.

The use of PMCT as a routine investigation varies immensely throughout the world. In some countries, all patients received to forensic institutes will have a full body CT,<sup>vii</sup> where as in others, the use of PMCT will be restricted to certain circumstances.

We present a case which demonstrates powerful reasons why PMCT should be a routine procedure for all forensic units before autopsy, not only because of its ability to provide the cause of death for both parts I and II of the death certificate <sup>viii</sup>but also because PMCT can alert pathologists to possible dangerous communicable infections such as Tuberculosis, and allow them to take adequate protective measures during autopsy.

### **Case history**

A 54 year old Hepatitis C Positive male heavy drinker with known alcoholic liver disease, oesophageal varices, portal hypertension and a duodenal ulcer was found dead at home. He had spent the majority of the previous year compulsorily detained in hospital for treatment for tuberculosis (TB). He completed his treatment and was pronounced disease free and released from hospital 3 months before his death.

2 days before death, witnesses reported a mild-to-moderate traumatic head injury. He rang the police on the day of his death and was discovered dead a few hours later.

### **Post mortem imaging**

PMCT by volumetric acquisition was performed with an Aquilon 64 by Toshiba Medical Systems, Japan. Scan parameters were as follows: 120 kV, 500mA, slice thickness 1 mm. Helical pitch 21 for head and 45 for body, rotation time 1 second for head and 0.5 seconds for body. Reconstruction filter FC 63 and FC 81 for brain and high resolution skull vault, FC 07 and FC51 for body soft tissue and lung.

### **Findings**

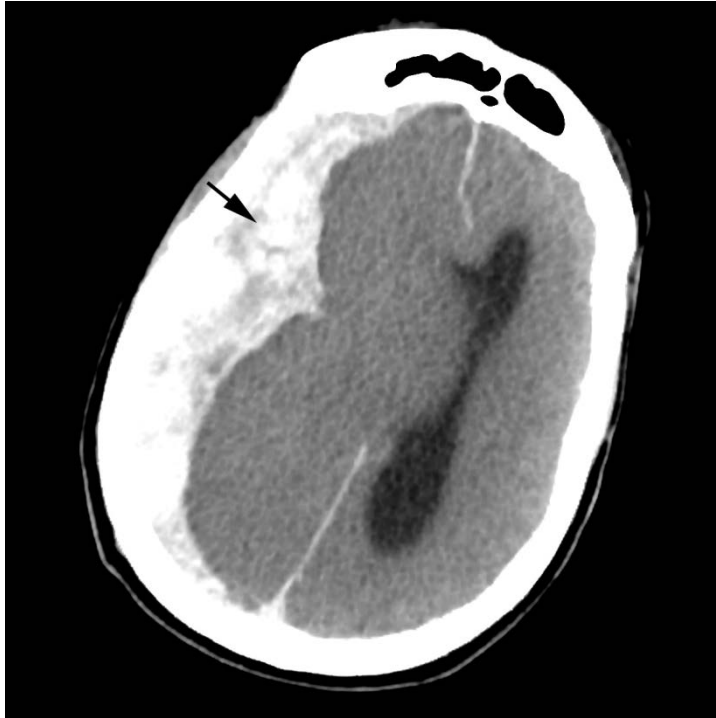
CT revealed an acute, large right sided sub dural haemorrhage. (Fig 1) with mid line shift and effacement of the basal cisterns and foramen magnum where there was also evidence of sub arachnoid haemorrhage (Fig 2)

A burr hole from a previous craniotomy was noted, as was Hyperostosis Frontalis Interna. (Fig 3) Although Hyperostosis is a benign condition often seen in elderly

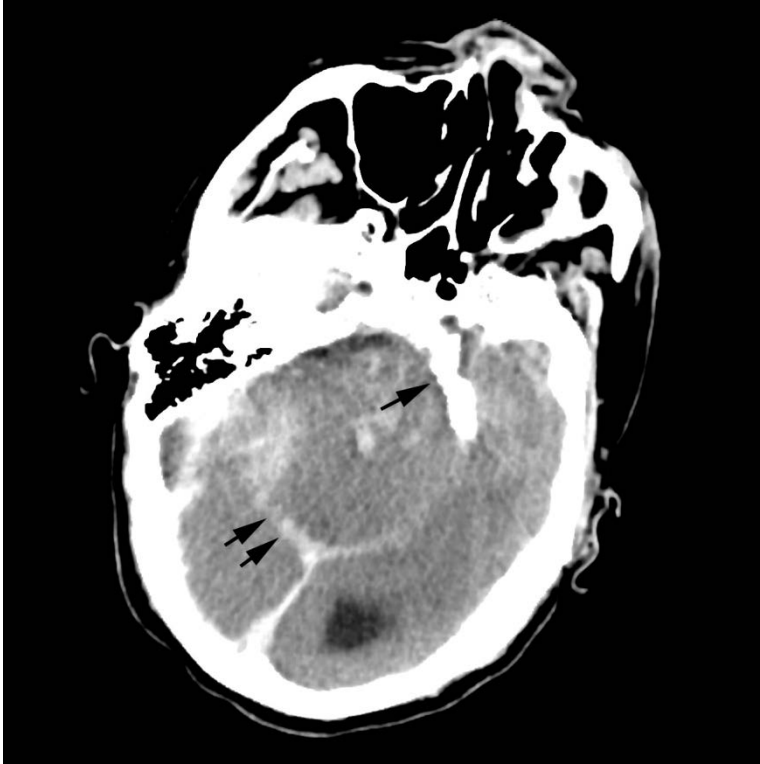
females, it is not often seen in males unless there is associated heavy alcohol consumption.

Imaging of the chest revealed bilateral but predominantly left upper zone cavitating air space opacity and nodularity. (Fig 4)

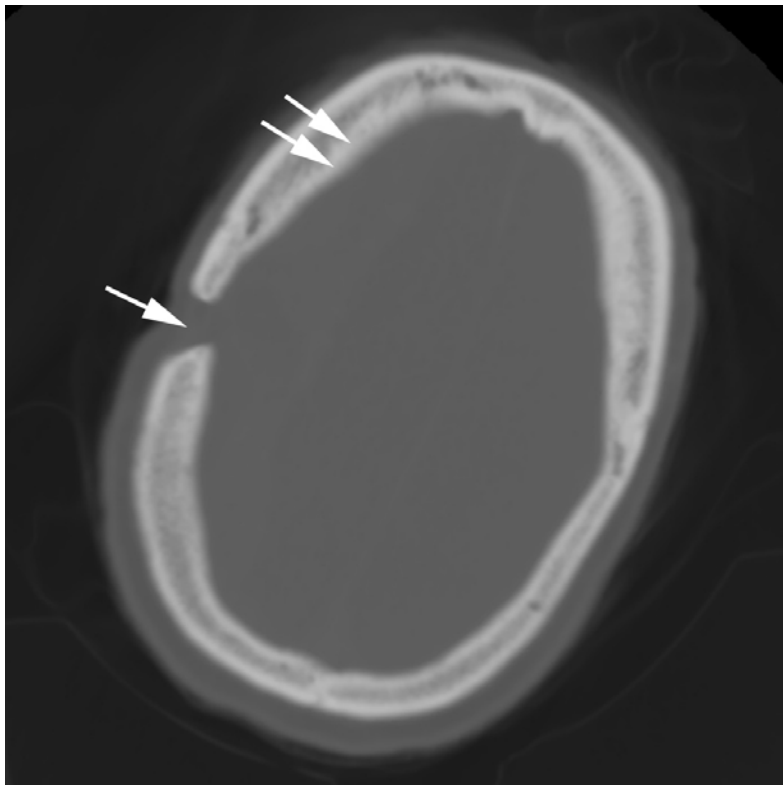
The liver showed diffuse fatty change in keeping with alcoholic steatosis. (Fig 5)



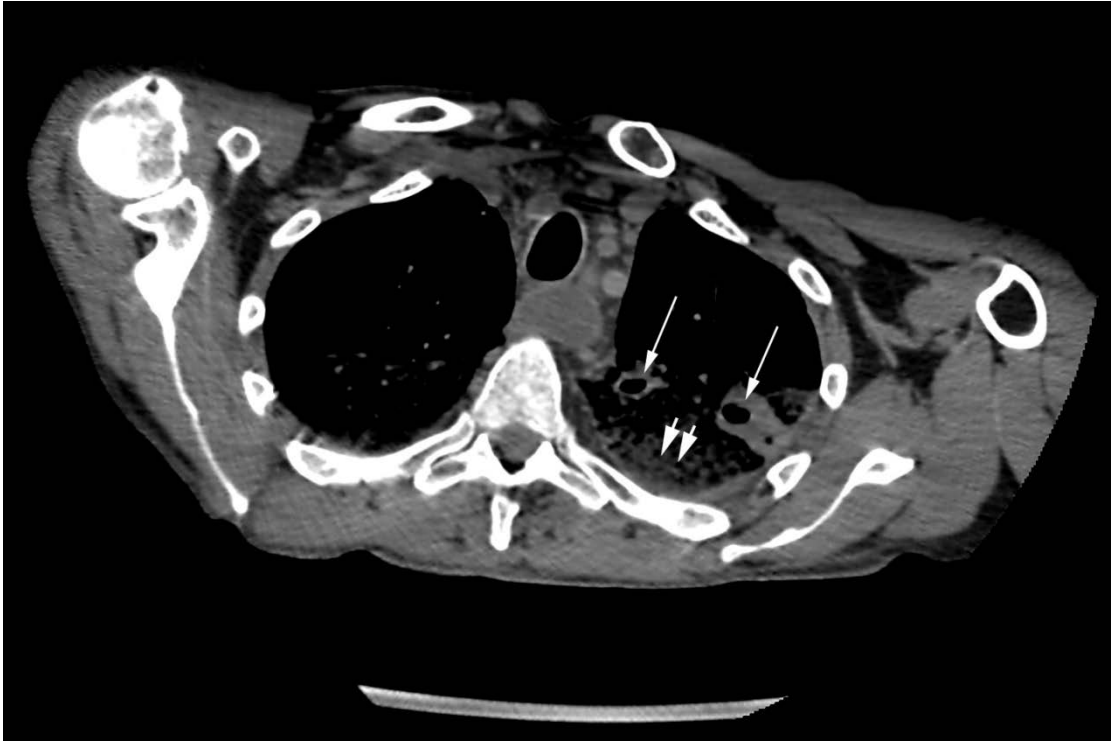
*Figure 1. Large right sided acute sub dural haemorrhage with significant mass effect, mid line shift and effacement of the ipsilateral lateral ventricle. (arrow)*



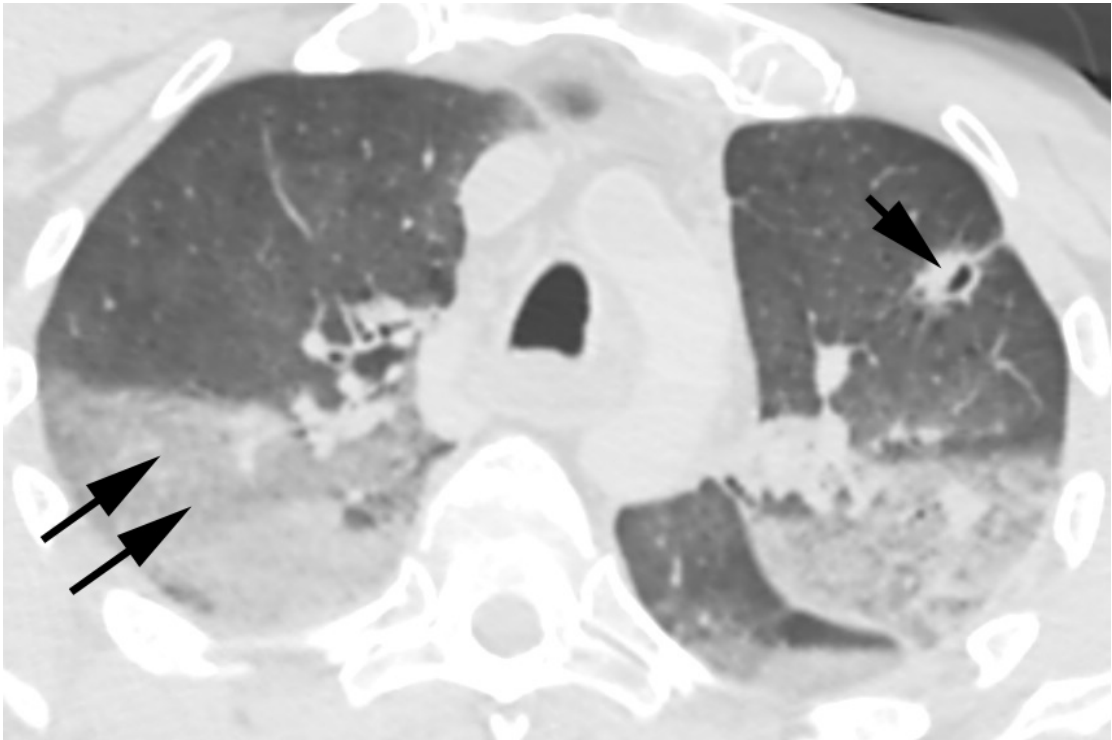
*Figure 2. Effacement of basal cisterns (arrow) with additional haemorrhage (double arrow)*



*Figure 3. Burr hole (arrow) and hyperostosis frontalis interna (double arrow)*



*Figure 4. Left sided upper zone patchy air space opacity (double arrow) with more focal cavitating lesions (single arrows)*



*Figure 5. Dependant consolidation most likely secondary to normal post mortem lividity (double arrows) with focal cavitating lesion (single arrow)*

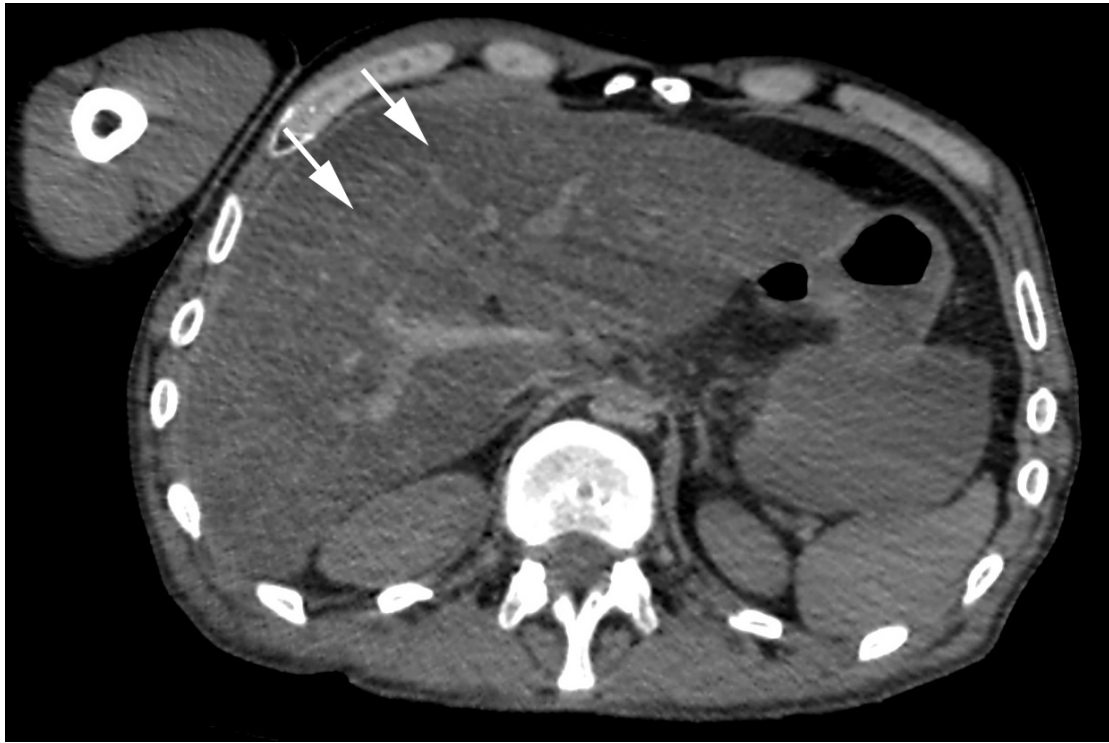

Figure 6. Diffuse hepatic steatosis (arrows)

### **Discussion**

In this case, Post Mortem CT was able to demonstrate not only the immediate cause of death, (the acute sub dural haemorrhage), but also the fact that this was a result of chronic alcohol abuse (previous burr hole for sub dural haemorrhage, hyperostosis frontalis interna and fatty liver). Several benign, malignant and infectious pathologies other than tuberculosis can produce cavitating lung lesions visible on CT, but the appearances in this case, combined with other important negatives, make Tuberculosis a far more likely cause.

Cavitating malignancies from a squamous or adenocarcinoma primary are more likely to be widespread rather than confined to the apices, and metastases are more likely to have a more clearly defined border and less surrounding air space opacity. Pulmonary infarcts (secondary to pulmonary embolism) can cavitate, but are more likely to be solitary, peripheral and larger. Granulomatous lesions such as those associated with Rheumatoid do not have a predilection for the apices, and again tend to present more as well defined focal lesions with less surrounding air space opacity. Fungal infections such as *Aspergillus* and *Cryptococcus* present more as well defined, multiple, small, cavitating lesions. *Aspergillus* often has a characteristic surrounding halo of ground glass opacity, secondary to micro haemorrhage into pulmonary vessels, and *Cryptococcus* does not have such a predilection for the apices and upper lobes.

The unexpected findings of active tuberculosis, confirmed at autopsy, allowed the autopsy to be delayed and performed using Personal Protective Equipment in a special high risk autopsy suite with appropriate ventilation.

Post Mortem CT is often only used in a few areas in selected cases, largely due to financial restraints and difficulties in accessing scanner time. Sometimes mortuary staff will be pressured in to performing an autopsy before all relevant clinical details and past medical history of the deceased have been established, putting staff at risk of communicable disease. Although universal precautions are adhered to, some cases will require more rigorous protection. If staff are not aware of potentially communicable diseases such as Tuberculosis, these cases will not be triaged appropriately.

The 2014 UK incidence of Tuberculosis in the living was 12.3 per 100,000. Low socio economic status and other factors of deprivation such as alcohol abuse continue to be the biggest risk factor, with 73% of cases occurring in patients born out with the UK. In addition 70% of cases were resident in the 40% most deprived areas of the UK. There has also been an increase in cases of multi drug resistant TB, and HIV associated TB.<sup>ix</sup> The incidence of TB is significantly higher in countries of the developing world, particularly in Africa and Asia, where incidence is as high as 1382 per 100,000 in Swaziland, Africa.<sup>x</sup>

It is worth remembering that all of these figures are dependent on accurate collection and recording of statistics, and may underestimate the scope of the problem in the world's poorest countries.

As migration and asylum claims are on the rise throughout mainland Europe, it seems reasonable to question whether there will be an associated increase in TB in countries where there has previously been a low incidence.

There have been many studies estimating the prevalence of TB at autopsy over the years,<sup>xi xii xiii xiv xv xvi xvii xviii</sup> ranging from 0.22% in New Zealand to 8.7% in India. It is worth noting however, that the majority of these cases found at autopsy were unexpected with figures ranging from 44 % to 77.8 %.

The risk to mortuary and lab personnel from exposure to TB is considerable, and has been estimated at 100 – 200 times that of the general population.<sup>xix</sup> There have been reported cases of patients who did not transmit tuberculosis before death releasing significant numbers of tubercle bacilli during autopsy.<sup>xx</sup>

There are numerous measures which can be taken to reduce the risk of transmission of TB during autopsy. The procedure can be performed in a single, enclosed room with down draft negative pressure ventilation, with 12 hour air change and regular change of filters. In addition, staff should wear Personal Protective Equipment such as a Tecno 95 mask and double glove as a minimum, using cut resistant gloves<sup>xxi</sup>

Overall, the increasing ability of PMCT to provide valuable information as to the cause of death, combined with its ability to forewarn pathologists of potential serious biohazards which would be of personal risk, further fuels the argument that PMCT should become a routine investigation in forensic practice.

---

<sup>i</sup> Brogdon, B. G., and Joel E. Lichtenstein. "Forensic radiology in historical perspective." *Critical reviews in diagnostic imaging* 41.1 (2000): 13-42.

<sup>ii</sup> Wüllenweber, R., V. Schneider, and T. Grumme. "[A computer-tomographical examination of cranial bullet wounds (author's transl)]." *Zeitschrift für Rechtsmedizin. Journal of legal medicine* 80.3 (1977): 227-246.



- 
- iii Roberts, Ian SD et al. "Post-Mortem Imaging As An Alternative To Autopsy In The Diagnosis Of Adult Deaths: A Validation Study". *The Lancet* 379.9811 (2012): 136-142. Web.
- iv Thali, MJ et al. "Post Mortem Imaging As An Alternative To Autopsy In The Diagnosis Of Adult Deaths: A Validation Study.". *J Forensic Sci.* 48.2 (2003): 386-403. Print.
- v Baglivo, Manuela, et al. "The rise of forensic and post-mortem radiology—analysis of the literature between the year 2000 and 2011." *Journal of Forensic Radiology and Imaging* 1.1 (2013): 3-9.
- vi Dirnhofer, Richard et al. "VIRTOPSY: Minimally Invasive, Imaging-Guided Virtual Autopsy". *RadioGraphics* 26.5 (2006): 1305-1333. Web.
- ii O'Donnell, C. et al. "Current Status Of Routine Post-Mortem CT In Melbourne, Australia". *Forensic Science, Medicine, and Pathology* 3.3 (2007): 226-232. Web.
- viii *Medical Certification Of Cause Of Death*. 1st ed. World Health Organisation, 1979. Web. 10 Feb. 2016.
- ix Public Health England,. *Tuberculosis In The UK: 2014 Report*. London: Public Health England, 2014. Print.
- x World Health Organisation,. *Global Tuberculosis Report 2013*. Geneva: WHO Press, 2013. Print.
- xi Lee, J.K.M. "Undiagnosed Tuberculosis In Hospitalized Patients- An Autopsy Survey". *The Journal of the Royal Society for the Promotion of Health* 110.4 (1990): 141-143. Web.
- xii Lum, D, and T Koelmeyer. "Tuberculosis In Auckland Autopsies, Revisited". *N Z Med J.* 118.U1356 (2005): 1211. Print.
- xiii Theegarten, D, B Kahl, and M Ebsen. "Frequency And Morphology Of Tuberculosis In Autopsies: Increase Of Active Forms.". *Dtsch Med Wochenschr.* 131.24 (2006): 1371-6. Print.
- xiv Flavin, R J, N Gibbons, and D S O'Briain. "Mycobacterium Tuberculosis At Autopsy--Exposure And Protection: An Old Adversary Revisited". *Journal of Clinical Pathology* 60.5 (2006): 487-491. Web.
- xv Yamamoto, A et al. "Study On Clinico-Pathological Features Of Active Pulmonary Tuberculosis Found At Autopsy In A General Hospital.". *Kekkaku* 84.2 (2009): 71-8. Print.
- xvi Ozsoy, Sait et al. "Tuberculosis Prevalence In Forensic Autopsies". *The American Journal of Forensic Medicine and Pathology* 31.1 (2010): 55-57. Web.
- xvii Garg, Monika et al. "Tuberculous Lesions At Autopsy". *J Indian Acad Forensic Med.* 33.2 (2011): n. pag. Print.
- xix Collins, CH, and JM Grange. "Tuberculosis Acquired In Laboratories And Necropsy Rooms.". *Commun Dis Public Health* 2.3 (1999): 161-7. Print.
- xx Templeton, Gary L. "The Risk For Transmission Of Mycobacterium Tuberculosis At The Bedside And During Autopsy". *Annals of Internal Medicine* 122.12 (1995): 922. Web.
- xxi Royal College of Pathologists,. *Guidelines On Autopsy Practice: Report Of A Working Group Of The Royal College Of Pathologists*. London: Royal College of Pathologists, 2002. Print.