



LJMU Research Online

Wilkinson, CM and Hadi, H

Categorizing facial creases: A review

<http://researchonline.ljmu.ac.uk/6404/>

Article

Citation (please note it is advisable to refer to the publisher's version if you intend to cite from this work)

Wilkinson, CM and Hadi, H (2017) Categorizing facial creases: A review. Journal of Cosmetic Dermatology. ISSN 1473-2130

LJMU has developed [LJMU Research Online](http://researchonline.ljmu.ac.uk/) for users to access the research output of the University more effectively. Copyright © and Moral Rights for the papers on this site are retained by the individual authors and/or other copyright owners. Users may download and/or print one copy of any article(s) in LJMU Research Online to facilitate their private study or for non-commercial research. You may not engage in further distribution of the material or use it for any profit-making activities or any commercial gain.

The version presented here may differ from the published version or from the version of the record. Please see the repository URL above for details on accessing the published version and note that access may require a subscription.

For more information please contact researchonline@ljmu.ac.uk

<http://researchonline.ljmu.ac.uk/>

Categorizing facial creases: A review

Facial creases categorization

Abstract

Ensuring uniformity in the nomenclature standardization of facial creases is important to enable the scholarly community to follow and debate the advancements in research. This review highlights the prevailing disparity in the nomenclature that refers to the same facial crease by researchers and laypeople, and suggests uniform names for the facial creases based on available literature. The previous and current trends in facial crease classification are also discussed. The nomenclature of the facial creases considered for this review include: the nasolabial fold; corner of the mouth lines; upper and lower lip creases around the mouth region; the mandibular folds; the bifid nose; the transverse nasal line; the vertical glabellar line; chin crease; the mental crease; four type of creases around the eyes; forehead creases; and periauricular creases. A figure illustrating the above facial creases is included as reference. It is hoped that the proposed standardization of nomenclature would ensure a more scientific referencing of facial creases enabling more effective scientific interaction among the scholarly community as well as the laypeople interested in the research and application of facial creases.

Keywords: Facial creases nomenclature; uniformity and standardization; facial crease classification

Introduction

The development of facial wrinkling is almost always associated with the aging of individuals wherein the skin loses elasticity prompting researchers to conduct studies on chronological changes based on the face ¹⁻⁶. At the cellular level, there is marked lowering of cell division in the stratum germinativum and with the flattening of the epidermal-dermal interface ⁷. The loss of subcutaneous fat also contributes to the ageing process ⁷. Among menopausal women, the loss of estrogen is also known to lead to reduction in the thickness of the dermis and epidermis ⁸. The amount of skin collagen that diminishes with aging also leads to skin sagging, wherein the skin becomes more coarse, crossed-lined and less elastic ⁹. The development of facial creases being a normal phenomenon during aging attracts the popular interest of laypersons and forms a subject matter of scientific research, as well as necessitating the need for formalizing the nomenclature of these creases.

The first problem in bringing about uniformity in facial crease nomenclature is that there exist multiple terms for one and the same crease on the face. For example, The Collins Dictionary defines ‘wrinkle’ as “a slight ridge in the smoothness of a surface, such as a crease in the skin as a result of age” and a ‘crease’ as “a wrinkle or furrow especially on the face” using ‘wrinkle’ and ‘crease’ interchangeably. ‘Folds’ and ‘furrows’ are also the terms utilized to describe facial creases. A furrow is “any deep groove, especially a deep wrinkle on the forehead” and a fold is “a mark, crease, or hollow made by folding” ¹⁰. The term ‘lines’ has also been utilized to describe a crease ². Lay terms such as crow’s feet for creases manifesting at the periphery of the eyes have also been utilized by previous researchers ^{3, 4, 11}. By definition alone, the words wrinkles, folds, furrows and creases are interchangeable. Lemperle, Holmes, Cohen,

Lemperle ¹² differentiate wrinkles as occurring on the dermal layer of the skin and ‘folds’ as being caused by intrinsic ageing laxity of the skin, gravity, sagging and bone loss.

Researchers have also reported categorization of facial creases by rating the wrinkles based on photographs or images ¹³⁻¹⁵. With the advancement in technology, skin casts or skin replicas have been adopted for the methods to classify crease severity ^{12, 16, 17}. Histological studies have also been carried out in order to identify crease morphology ^{18, 19}. Direct 3D in-vivo measurements ²⁰ and skin elastic measurement utilizing a cutometer were conducted by few researchers ^{15, 16, 21}. Raking light optical profilometry has also been utilized in crease analysis ²². Automated computer crease classification in tandem with photographic assessment was also utilized to investigate the usefulness of computers at classifying wrinkle severity ²³ and for age estimation ²⁴.

There appear to be no consensus on the scaling for measuring the severity of wrinkles and the grading scales reported are seen to be researcher-dependent. In general, these scales include a zero “0” to five “5” range ^{12, 25, 26} where ‘0’ indicates no wrinkle and the highest number indicates severe wrinkling. The ranges for these scales vary from 3-point ¹³ to 14-point¹⁴. The drawbacks in merely utilizing a set of photographs for identification include the dependency on the particular set of photographs, which may lead to false classification, prompting researchers to reclassify crease severity ²⁷. This review is aimed at categorizing creases on the face based on the location and the common names associated with the crease. Creases present on the face include the nasolabial fold, upper and lower lip creases around the mouth region, the mandibular folds, the bifid nose, the transverse nasal line, the vertical glabellar line, the mental crease, creases around the eyes (periorbital lines, upper and lower eyelid lines and infra orbital

crease), forehead creases and periauricular creases. Figure 2 illustrates the creases which are present on the face.

Nasolabial fold

The nasolabial fold (NLF) ¹² is a crease which is situated on the cheek. It starts from the tip of the alae of the nose and ends at the cheek adjacent to the cheilions (corners of the mouth). If the fold is severe, it will combine with the mandibular fold forming a single long crease ²⁸. The nasolabial fold is one of the most studied creases on the face. As such, there are multiple names to refer this crease. Researchers have seen to mention NLF as the melolabial fold ^{29, 30}, nose-lip fold ³¹, nose-cheek fold (“smile line”) ³² or nasomandibular fold ³³. Classification of NLF has been conducted by previous research on dissected cadavers ³⁴⁻³⁶. There is a general agreement that the shape of NLF can be classified based on the angle of the shape, which could be either ‘concave’, ‘straight’ or ‘convex’. However, while Rubin, Mishriki, Lee ³⁵ did not include a figure to show the crease shape morphology in their research, other authors were in disagreement with each other on the classification of ‘convex’ and ‘concave’ NLF creases ^{34, 36}. The differences between the crease classifications is shown in Figure 1.

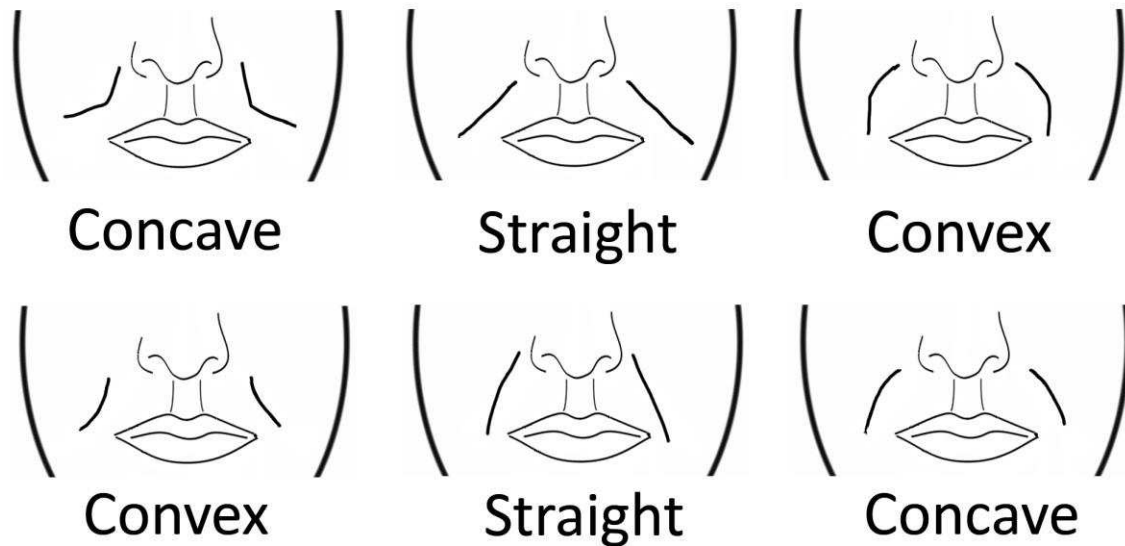


Figure 1 Modified figure showing the comparison of the nasolabial classification by Zufferey³⁶ (top) and Pessa, Zadoo, Adrian, Yuan³⁴ (bottom).

Creases around the lip region

Dunn, Harrison³⁷ categorized the wrinkles around the lips as the upper lip and lower lip wrinkles. The common term for upper lip wrinkles is smoker's lines,³⁸ while some authors mentioned it is as 'upper radial lip lines'³⁹. The nomenclature 'perioral wrinkles' is also utilized to describe creases around the mouth¹⁹. Analysis on ten fresh cadavers between 75 and 93 years of age indicated that women have more perioral wrinkles than men, which may be due to the lack of appendages around the lip region¹⁹. It has to be noted that gravity may have an influence on the wrinkle morphology as the cadavers aged 70 years and above and may have lax skin. Also, the backward gravitational pull on the facial skin in a cadaver in supine position would alter the shape of the crease compared to that in a living person in upright position.

Mandibular fold

Mandibular fold,²⁸ variously designated as the marionette line³⁷, jowls⁴⁰, melomental folds²⁹, labiomandibular fold⁴¹, marionette lines^{27, 38}, cheek-chin fold³¹ or labiomentall fold,⁴² is a crease which originates from the corner of the mouth, usually adjacent of the cheilion superior of

the mandible and ends at the chin border. Lemperle, Holmes, Cohen, Lemperle¹² divided the labiomandibular fold into marionette lines and corner of the mouth lines. The fold may surpass the chin border if a person has lax skin. The fold becomes prominent with increased age⁴¹. This fold is the result of two fat compartments (submandibular and mandibular septum fat compartment) and the overlying skin⁴⁰. The fold morphology would be altered when there are changes in facial expression⁴¹.

Bifid Nose Wrinkle

The bifid nose wrinkle or crease is a vertical wrinkle on the tip of the nose when it is bifid. It is the only crease without an underlying bony morphology and the manifestation of this crease is due to the paired alar cartilage⁴³. The columellar segments and the intervening soft tissue give rise to a smoother nose in individuals lacking this crease⁴³. It has also been shown that individuals with bifid nose have a split nasal spine⁴⁴. While Dunn, Harrison³⁷ called the bifid nose 'nose tip groove', Oneal, Beil, Izenberg, Schlesinger⁴³ and Rynn⁴⁴ did not refer to the crease in general, but stated that the absence of the soft tissue will result in the bifid appearance of the nose. The female nose tip has been categorized based on a four-grade scale in beauty magazines and the interdomal crease was stated⁴⁵.

Transverse nasal line

The transverse nasal line as indicated by Dunn, Harrison³⁷ is horizontal wrinkles present on the root of the nose. The wrinkle, also known as the fighter's wrinkle^{46 in 47}, transverse nasion lines⁴² and wrinkles of the nasal root³¹. The wrinkle has also been classified as a groove between the lower third and the upper two-third of the nose⁴⁸, which is slightly lower than the crease noted by Dunn, Harrison³⁷. The crease formation may be due to an anomaly present in the human gene⁴⁸. The exact location varies among individuals. The formation of the wrinkle may be related to

the strength of attachment of the procerus muscle ⁴⁹ or the depth of the eyes when the eyes are deep set ⁴⁹ or due to the muscles at the glabellar region of the face ⁴⁷.

Vertical glabellar line

The vertical glabellar lines ³⁷ are also referred to as vertical wrinkles of the glabella ³¹, glabellar frown lines ^{12, 42, 50} or frown lines, ³⁸ are creases located on the glabellar region of the forehead, usually between the eyes and above the nose. The wrinkle morphology is based on the development of the temporalis muscles, brow ridges, glabella and the relief of the occipital bone ⁵¹.

Mental crease and mental pit

The mental crease ⁴⁹ that is also mentioned as lip chin fold ³¹ or chin crease ¹² is a crease that is present on the mandible. Little research on the crease structure has been carried out by other researchers. A study was performed on linking the crease morphology with Pseudoxanthoma elasticum (PXE), an inheritable disease ⁵². Skulls which have a groove in the labiomental region exhibit a strong muscle attachment in the area supporting a cleft chin in the face ⁴⁹.

Creases around the eyes

There are some creases around the eyes. Lateral to the eyes are periorbital lines ¹². These are also known as the lateral canthal creases ³⁷, temporal wrinkles ³¹ and crow's feet ^{27, 53}. These creases originate from the corners of the eyes and terminate at the lateral side of the head. It has been shown that the crow's feet can be utilized as an indicator of decreased renal function ⁵⁴.

There are also creases inferior to the eyes. The crease adjacent to the eyes are called the lower eyelid ³⁷, eye-fold below the orbit ³¹ or the malar crescent ⁴². This crease is a crescentic crease due to the protrusion of the eyeballs. The upper eyelid, like the lower eyelid has a crease

directly above the eyes. The crease has been mentioned by few researchers ^{15, 17, 37, 55}. The supraorbital margin dictates the shape of the upper eyelid fold ⁵⁶. When there is an overhang in the middle of the supraorbital rim, the fold is defined more laterally and becomes thicker ⁵⁶. A medial epicanthic fold is determined by a low nasal root while an intermediate fold is determined by a low orbit with an overhang at the brow bridge. A dissection study on eight cadaver faces in the eye region revealed that the lower eyelid fat pads are individualized and do not combine with the posterior intra orbital fat ⁵⁷.

The infra orbital crease is a crease which is situated inferior to the lower eyelid crease of the eyes originating from the nose region and following the lower margins of the orbital rim. It has been shown that the crease overlaps the lower border of the infra orbital foramen 52% of the time ²⁸. The infra orbital crease is also known as the nasojugal groove ^{42, 58}, nose-cheek wrinkle ³¹, or the nasojugal fold ^{7, 59}. Camp, Wong, Filip, Carter, Gupta ⁵⁸ defined the nasojugal groove as a crease which is bordered laterally by the mid-pupillary line and superiorly by the medial canthal line. A definition of the fold was not provided by Shaw, Katzel, Koltz, Yaremchuk, Giroto, Kahn, Langstein ⁵⁹ and Sadick, Karcher, Laura ⁷ in their research.

Forehead Creases

Creases on the forehead are almost exclusively horizontal in pattern. The creases are either called horizontal forehead creases ², forehead lines ²⁷ and horizontal forehead lines ¹². Extensive research on grading the forehead wrinkles have been conducted by previous researchers ^{5, 12, 22, 23, 25, 27, 53}. Researchers seem to be unanimous in naming this crease as this is the only crease which is present on the facial musculature covering the frontal bone.

Periauricular Crease

The periauricular lines ^{12, 60} are creases around the ear region commonly occurring in the medial of the face around the tragus region. This crease is rarely studied ^{12, 60} and this may be due to the location of the crease on the face. The crease is nearer to the ears, which makes detection of the crease difficult when viewing the face in a frontal view. Only when the face is viewed laterally will people be able to recognize the crease.

Summary

An earlier report on standardizing the nomenclature of creases was brought out by Işcan ³¹ although the nomenclature prescribed did not acquire popularity among researchers. In order to simplify classification, it is proposed that a figure showcasing the crease or wrinkle of interest on the face is included in future research articles. Based on the names stated in this review, Figure 2 has been modified from a previous paper³⁷ with additional creases. Figure 2 has also been adopted in previous research ⁶¹.

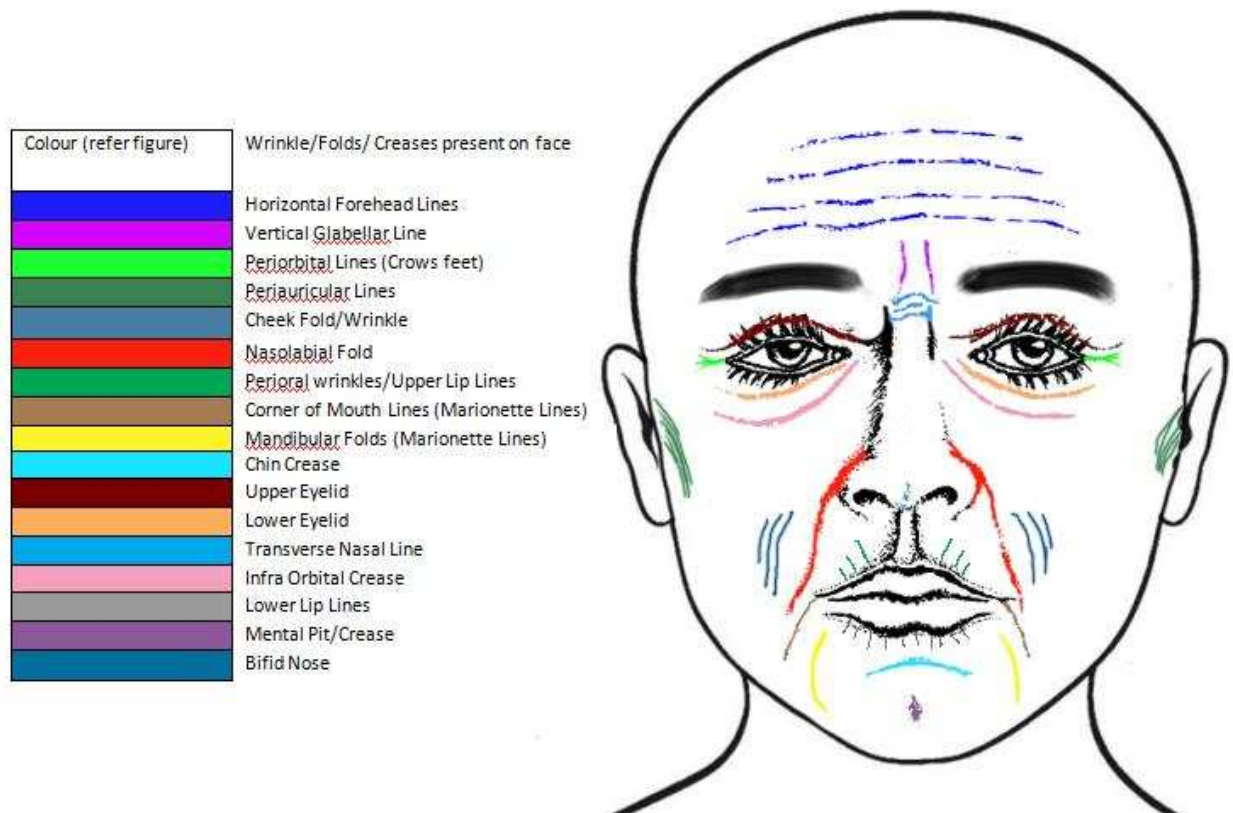


Figure 2 Common creases available on the face.

This review article brings out the difficulties in limiting the description of a crease using a single term since the use of multiple terms are common, both among scientific researchers and laypersons, for a considerably long time. The existence of such differences may also be due to the extent of the common usage of a particular terminology by researchers and the local community. However, it is still possible for researchers to include figures depicting the creases in general in their research article to ensure uniformity in recognition and for ease of identification. Ideally, limiting the terms utilized would make it easier for researchers and laypersons to refer to a specific crease without the need for figures depicting the crease morphology of interest. It is

hoped that the common terms brought forward by other researchers in this review article are utilized by future researchers.

References

1. Akazaki S, Nakagawa H, Kazama H, et al. Age-related changes in skin wrinkles assessed by a novel three-dimensional morphometric analysis. *The British Journal of Dermatology*. Oct 2002;147(4):689-695.
2. Albert AM, Ricanek K, Jr., Patterson E. A review of the literature on the aging adult skull and face: implications for forensic science research and applications. *Forensic Science International*. Oct 2 2007;172(1):1-9.
3. Gonzalez-Ulloa M. *The aging face*: Piccin Nuova Libreria S.p.A.; 1987.
4. Gonzalez-Ulloa M, Flores ES. Senility of the face--basic study to understand its causes and effects. *Plastic and Reconstructive Surgery*. Aug 1965;36:239-246.
5. Luebberding S, Krueger N, Kerscher M. Comparison of Validated Assessment Scales and 3D digital fringe projection method to assess lifetime development of wrinkles in men. *Skin Res Technol*. May 31 2013.
6. Neave R. Age changes to the face in adulthood. In: Clement J, Ranson DL, eds. *The Craniofacial Identification in Forensic Medicine*: Hodder Arnold; 1998:306.
7. Sadick N, Karcher C, Laura P. Cosmetic dermatology of the aging face. *Clinics in Dermatology*. 2009;27:S3-S12.
8. Case RM, Waterhouse JM. *Human physiology: Age, stress, and the environment*: OUP Oxford; 1994.
9. Christiansen JL, Grzybowski JM. *Biology of aging*: William C. Brown; 1993.
10. Collins. *Collins Dictionary. The American Heritage® Dictionary of the English Language, Fourth Edition*. 4th ed: Houghton Mifflin Company <http://www.thefreedictionary.com> Accessed On: 17 May 2013; 2009.
11. Yoo MA, Seo YK, Shin MK, Koh JS. How much related to skin wrinkles between facial and body site? Age-related changes in skin wrinkle on the knee assessed by skin bioengineering techniques. *Skin Res Technol*. Feb 2016;22(1):69-74.
12. Lemperle G, Holmes RE, Cohen SR, Lemperle SM. A classification of facial wrinkles. *Plastic and Reconstructive Surgery*. 2001;108(6):1735-1750.
13. Ernster VL, Grady D, Miike R, Black D, Selby J, Kerlikowske K. Facial wrinkling in men and women, by smoking status. *American Journal of Public Health*. Jan 1995;85(1):78-82.
14. Nouveau-Richard S, Yang Z, Mac-Mary S, et al. Skin ageing: a comparison between Chinese and European populations. A pilot study. *Journal of Dermatological Science*. Dec 2005;40(3):187-193.
15. Tsukahara K, Sugata K, Osanai O, et al. Comparison of age-related changes in facial wrinkles and sagging in the skin of Japanese, Chinese and Thai women. *Journal of Dermatological Science*. Jul 2007;47(1):19-28.
16. Fujimura T, Haketa K, Hotta M, Kitahara T. Loss of skin elasticity precedes to rapid increase of wrinkle levels. *Journal of Dermatological Science*. Sep 2007;47(3):233-239.
17. Takema Y, Tsukahara K, Fujimura T, Hattori M. Age-related Changes in the Three-dimensional Morphological Structure of Human Facial Skin. *Skin Research and Technology*. 1997;3:95-100.
18. Contet-Audonneau JL, Jeanmaire C, Pauly G. A histological study of human wrinkle structures: comparison between sun-exposed areas of the face, with or without wrinkles, and sun-protected areas. *The British Journal of Dermatology*. Jun 1999;140(6):1038-1047.

19. Paes EC, Teepen HJ, Koop WA, Kon M. Perioral wrinkles: histologic differences between men and women. *Aesthetic Surgery Journal*. Nov-Dec 2009;29(6):467-472.
20. Fujimura T, Haketa K, Hotta M, Kitahara T. Global and systematic demonstration for the practical usage of a direct in vivo measurement system to evaluate wrinkles. *International Journal of Cosmetic Science*. Dec 2007;29(6):423-436.
21. Takema Y, Yorimoto Y, Kawai M, Imokawa G. Age-related changes in the elastic properties and thickness of human facial skin. *The British Journal of Dermatology*. Nov 1994;131(5):641-648.
22. Jiang LI, Stephens TJ, Goodman R. SWIRL, a clinically validated, objective, and quantitative method for facial wrinkle assessment. *Skin Res Technol*. Nov 2013;19(4):492-498.
23. Cula GO, Bargo PR, Nkengne A, Kollias N. Assessing facial wrinkles: Automatic detection and quantification. *Skin Res Technol*. Feb 2013;19(1):e243-251.
24. Kwon YH, Da Vitoria Lobo N. Age classification from facial images. *Computer Vision and Image Understanding*. 1999;74(1):1-21.
25. Ezure T, Amano S. The severity of the wrinkling at the forehead is related to the degree of ptosis of the upper eyelid. *Skin Research and Technology*. 2010;16:202-209.
26. Tsukahara K, Takema Y, Fujimura T, Moriwaki S, Kitahara T, Imokawa G. Determination of age-related changes in the morphological structure (sagging) of the human cheek using a photometric scale and three-dimensional surface parameters. *International Journal of Cosmetic Science*. Aug 2000;22(4):247-258.
27. Carruthers A, Carruthers J. A validated facial grading scale: the future of facial ageing measurement tools? *Journal of Cosmetic and Laser Therapy*. Oct 2010;12(5):235-241.
28. Mohd Hadi Pritam H. *Facial Creases in Human Identification*. Dundee: Centre for Anatomy and Human Identification, University of Dundee; 2012.
29. Bagal A, Dahiya R, Tsai V, Adamson PA. Clinical experience with polymethylmethacrylate microspheres (Artecoll) for soft-tissue augmentation: a retrospective review. *Archives of Facial Plastic Surgery*. Jul-Aug 2007;9(4):275-280.
30. Gassner HG, Rafii A, Young A, Murakami C, Moe KS, Larrabee WF, Jr. Surgical anatomy of the face: implications for modern face-lift techniques. *Archives of Facial Plastic Surgery*. Jan-Feb 2008;10(1):9-19.
31. Işcan MY. Introduction of techniques for photographic comparison: Potential and problems In: Işcan MY, Helmer RP, eds. *Forensic Analysis of the Skull*: John Wiley & Sons; 1993:57-70.
32. Fedosyutkin BA, Nainys JV. The relationship of skull morphology to facial features. In: Işcan MY, Helmer RP, eds. *Forensic Analysis of the Skull*: John Wiley & Sons; 1993:199-214.
33. Robbins LB, Brothers DB, Marshall DM. Anterior SMAS plication for the treatment of prominent nasomandibular folds and restoration of normal cheek contour. *Plastic and Reconstructive Surgery*. Nov 1995;96(6):1279-1287; discussion 1288.
34. Pessa JE, Zadoo VP, Adrian EK, Jr., Yuan C. Variability of the midfacial muscles: Analysis of 50 hemifacial cadaver dissections. *Journal of the American Society of Plastic Surgeons*. 1998;102(6):1888-1893.
35. Rubin LR, Mishriki Y, Lee G. Anatomy of the nasolabial fold: the keystone of the smiling mechanism. *Plastic and Reconstructive Surgery*. Jan 1989;83(1):1-10.
36. Zufferey J. Anatomic variations of the nasolabial fold. *Plastic and Reconstructive Surgery*. Feb 1992;89(2):225-231; discussion 232-223.
37. Dunn KW, Harrison RK. Naming of parts: a presentation of facial surface anatomical terms. *British Journal of Plastic Surgery*. Dec 1997;50(8):584-589.
38. Clinic TYB. Facial aging guide for marionette lines and crows feet from Yorkshire Botox clinic. 2010; <http://www.botoxandfillersclinic.co.uk/facial-aging/>. Accessed 21 October 2013, 2013.
39. Abate AF, Nappi M, Ricciardi S, Tortora G. FACES: 3D FACial reConstruction from anciEnt Skulls using content based image retrieval *Journal of Visual Language and Computing*. 2004;15(2004):373-389.

40. Reece EM, Rohrich RJ. The aesthetic jaw line: management of the aging jowl. *Aesthetic Surgery Journal*. Nov-Dec 2008;28(6):668-674.
41. Pessa JE, Garza PA, Love VM, Zadoo VP, Garza JR. The anatomy of the labiomandibular fold. *Plastic and Reconstructive Surgery*. Feb 1998;101(2):482-486.
42. Pober JM, Aston SJ. Aesthetic surgery of the brow, face, and neck In: Georgiade GS, Reifkohl R, Levin LS, eds. *Georgiade Plastic, Maxillofacial, and Reconstructive Surgery: Williams & Wilkins*; 1997:553-562.
43. Oneal RM, Beil RJ, Izenberg PH, Schlesinger J. Surgical anatomy of the nose. *Operative Techniques in Plastic and Reconstructive Surgery*. 2000;7(4):158-167.
44. Rynn C. Craniofacial approximation and reconstruction: Tissue depth patterning and the prediction of the nose. Dundee: Centre for Anatomy & Human Identification, University of Dundee; 2006.
45. Bures S. Tip points: defining the tip. *Aesthetic Plastic Surgery*. Mar-Apr 1999;23(2):113-118.
46. Lange F. *El Lenguaje Del Rostro*. Barcelona: Luis Miracle; 1942.
47. Figallo EE, Acosta JA. Nose muscular dynamics: the tip trigonum. *Plastic and Reconstructive Surgery*. Oct 2001;108(5):1118-1126.
48. Shelley WB, Shelley ED, Pansky B. The transverse nasal line: an embryonic fault line. *The British Journal of Dermatology*. Dec 1997;137(6):963-965.
49. Wilkinson C. *Forensic facial reconstruction*. Vol 4. First ed: Cambridge University Press; 2004.
50. Honeck P, Weiss C, Sterry W, Rzany B. Reproducibility of a four-point clinical severity score for glabellar frown lines. *British Journal of Dermatology*. Aug 2003;149(2):306-310.
51. Gerasimov MM. *The reconstruction of face on the base of structure of skull*. 1975 ed: Translated by: Tshernezky, W. (1975); 1955.
52. Lebwohl M, Lebwohl E, Bercovitch L. Prominent mental (chin) crease: a new sign of pseudoxanthoma elasticum. *Journal of the American Academy of Dermatology*. Apr 2003;48(4):620-622.
53. Qiu H, Long X, Ye JC, et al. Influence of season on some skin properties: winter vs. summer, as experienced by 354 Shanghaiese women of various ages. *International Journal of Cosmetic Science*. Aug 2011;33(4):377-383.
54. Park BH, Lee S, Park JW, et al. Facial wrinkles as a predictor of decreased renal function. *Nephrology (Carlton)*. Dec 2008;13(6):522-527.
55. Tsukahara K, Takema Y, Kazama H, et al. A photographic scale for the assessment of human facial wrinkles. *Journal of Cosmetic Science*. 2000;51:127-139.
56. Wilkinson C. *Facial anthropology and reconstruction* In: Thompson T, Black S, eds. *Forensic Human Identification: CRC Press*; 2006.
57. Rohrich RJ, Ahmad J, Hamawy AH, Pessa JE. Is intraorbital fat extraorbital? Results of cross-sectional anatomy of the lower eyelid fat pads. *Aesthetic Surgery Journal*. May-Jun 2009;29(3):189-193.
58. Camp MC, Wong WW, Filip Z, Carter CS, Gupta SC. A quantitative analysis of periorbital aging with three-dimensional surface imaging. *Journal of Plastic, Reconstructive & Aesthetic Surgery*. Feb 2011;64(2):148-154.
59. Shaw RB, Jr., Katzel EB, Koltz PF, et al. Aging of the facial skeleton: Aesthetic implications and rejuvenation strategies. *Plastic and Reconstructive Surgery*. Jan 2011;127(1):374-383.
60. Bosset S, Barre P, Chalon A, et al. Skin ageing: clinical and histopathologic study of permanent and reducible wrinkles. *European Journal of Dermatology*. May-Jun 2002;12(3):247-252.
61. Hadi H, Wilkinson CM. The post-mortem resilience of facial creases and the possibility for use in identification of the dead. *Forensic Sci Int*. Apr 2014;237:149 e141-149 e147.

