

RVC OPEN ACCESS REPOSITORY – COPYRIGHT NOTICE

This is the peer-reviewed, manuscript version of the following article:

L.Greve, S.Dyson, T.Pfau, Alterations in thoracolumbosacral movement when pain causing lameness has been improved by diagnostic analgesia (2017), *The Veterinary Journal*.

<http://dx.doi.org/10.1016/j.tvjl.2017.03.009>

© 2017. This manuscript version is made available under the CC-BY-NC-ND 4.0 license

<http://creativecommons.org/licenses/by-nc-nd/4.0/>.

The full details of the published version of the article are as follows:

TITLE: Alterations in thoracolumbosacral movement when pain causing lameness has been improved by diagnostic analgesia

AUTHORS: Greve, L; Dyson, S; Pfau, T

JOURNAL: VETERINARY JOURNAL

PUBLISHER: Elsevier

PUBLICATION DATE: 3 May 2017 (online)

DOI: 10.1016/j.tvjl.2017.03.009

Original Article

Alterations in thoracolumbosacral movement when pain causing lameness has been improved by diagnostic analgesia

L. Greve ^{a, b, *}, S. Dyson ^a, T. Pfau ^b

^a*Centre for Equine Studies, Animal Health Trust, Lanwades Park, Kentford, Newmarket, Suffolk CB8 7UU, UK*

^b*Department of Clinical Science and Services, The Royal Veterinary College, University of London, Hawkshead Lane, North Mymms, Hatfield AL9 7TA, UK*

* Corresponding author. Tel.: +44 163 8751908.

E-mail address: line.greve@aht.org.uk (L. Greve).

Highlights

- This study investigated if thoracolumbosacral movement changes when pain causing lameness is improved by diagnostic analgesia
- Improvement in lameness by diagnostic analgesia resulted in reduced asymmetry of the thoracolumbosacral movement
- Improvement in lameness by diagnostic analgesia resulted in increased thoracolumbosacral range of motion

Abstract

Lameness, thoracolumbosacral pain and reduced range of motion (ROM) often coexist; better understanding of their relationship is needed. The objectives were to determine if thoracolumbosacral movement of horses changes when pain causing lameness is improved by diagnostic analgesia. We hypothesised that reduction of lameness will increase ROM of the thoracolumbosacral region. Thirteen horses with different types of hind limb lameness were

trotted in straight lines and lunged on a 10 m diameter circle on left and right reins before and after lameness was subjectively substantially improved by diagnostic analgesia. Inertial sensor data were collected from the withers, thirteenth (T13) and eighteenth thoracic (T18) vertebrae, third lumbar (L3) vertebra, tubera sacrale (TS), left and right tubera coxae. ROM of flexion-extension, axial rotation, lateral bending, dorsoventral, lateral-lateral motion and vertical movement symmetry were quantified at each thoracolumbar site. Hip hike difference (HHD), maximum difference (MaxDiff) and minimum difference (MinDiff) for the pelvic sensors were measured. Percentage changes for before and after diagnostic analgesia were calculated; mean \pm standard deviation (SD) or median [interquartile range] were determined.

Associations between the change in pelvic versus thoracolumbar movement symmetry after each local analgesic technique were tested. After resolution of lameness, HHD decreased by 7% [68%] ($P = 0.006$). The MinDiff decreased significantly by 33% [61%] ($P = 0.01$), $45 \pm 13\%$ ($P = 0.005$) and $52 \pm 23\%$ ($P = 0.04$), for TS, L3 and T18, respectively. There was significantly increased ROM in flexion-extension at T13, in axial rotation at T13, T18, L3 and in lateral-lateral ROM at L3. Thoracolumbosacral asymmetry and reduced ROM associated with lameness were both altered immediately by improvement in lameness using diagnostic analgesia.

Keywords: Back pain; Equine; Inertial measurement units; Lameness; Laterality

Introduction

Quadrupedal animals adapt to hind limb lameness by extending the thoracolumbar region and decreasing the range of motion (ROM) of the lumbosacral vertebral column (Buchner et al., 1996;

Gómez Álvarez et al., 2008). Equine thoracolumbar movement has been described in vitro (Jeffcott and Dalin, 1980; Townsend et al., 1983) and in vivo (Faber et al., 2000; 2001a, b; Licka et al., 2001a, b), but the association between lameness and thoracolumbar pain is poorly understood. Lameness and thoracolumbar pain are interrelated (Landman et al., 2004; Gómez Álvarez et al., 2007, 2008; Greve and Dyson, 2013), however it can be challenging to establish whether altered thoracolumbar movement is caused by primary thoracolumbar pain or is secondary to lameness.

Inertial measurement units (IMUs) have been validated against optical motion capture as a reliable and accurate tool to measure limb asymmetries, and rotational and translational thoracolumbar movement (Pfau et al., 2005; Warner et al., 2010; Martin et al., 2014). They also enable asymmetry between left and right sides of the stride to be quantified (Keegan et al., 2001; Kramer et al., 2004). Experimentally induced lameness (Buchner et al., 1996; Gómez Álvarez et al., 2007, 2008) or induced epaxial muscle pain (Wennerstrand et al., 2004, 2009) alter the thoracolumbar kinematics. In experimentally induced weight-bearing hind limb lameness, there is redistribution of load between the forelimbs and hind limbs (Weishaupt et al., 2004) and on the circle, hind limb lameness introduces a movement pattern mimicking ipsilateral forelimb lameness (Rhodin et al., 2013). Saddle-slip consistently to one side occurs in approximately 50% of horses with hind limb lameness (Greve and Dyson, 2013, 2014), indicating that hind limb lameness may alter thoracolumbar movement in ridden horses. Comparison of thoracolumbar dimensions between lame and sound horses that were in regular work over one year showed that there were smaller changes in lame horses, suggesting that lameness results in reduced ability to use the thoracolumbar epaxial muscles correctly (Greve and Dyson, 2015a). Using IMUs in

sound horses, mild asymmetry in pelvic and thoracolumbar movement can be measured in circles, because the inside and outside hind limbs are each describing a path with a difference in radius; inside forelimbs and hind limbs take shorter steps than outside limbs (Hobbs et al., 2011). To date, there have been no studies that have quantified asymmetry in thoracolumbar movement and hind limb gait in horses with hind limb lameness before and after reduction in pain by diagnostic analgesia.

The overall purpose of this study was to study the relationship between hind limb asymmetry and thoracolumbosacral functionality by using an ‘inverse model’ which assesses the response to improvement in naturally occurring lameness by diagnostic analgesia. The objectives were: (1) to quantify movement of the thoracolumbosacral region in subjectively lame horses in straight lines in hand, on the lunge, comparing left and right reins; and (2) to determine if thoracolumbosacral movement of horses changes when pain causing lameness is improved by diagnostic analgesia. We hypothesised that: (1) hind limb lameness would induce asymmetry in the thoracolumbosacral movement between the left (LH) and right (RH) hind limb stance phases that would be different between predominantly LH lameness and RH lameness; and (2) elimination/reduction of the hind limb pain will reduce the asymmetry in thoracolumbosacral movement and increase the ROM.

Materials and methods

A prospective study was performed at the Animal Health Trust (AHT) and Royal Veterinary College (RVC). Six consecutive horses with hind limb lameness at the RVC and seven at the AHT were included. Diagnosis was assigned prospectively based on the results of a

comprehensive clinical evaluation, diagnostic analgesia and imaging. Age, breed, sex, body mass, height and work discipline were recorded. The study was approved by the Ethical Review Committee of the AHT (number 39 2014; Approval date 12 September 2014) and there was informed owner consent.

Inertial measurement units

Each horse was instrumented with seven MTx (18xgravity, 1200 degree/s) miniaturised IMUs (Xsens Technologies BV) and one combined IMU/global positioning system (GPS) sensor (MTi-G) (Xsens Technologies BV) at the level of the tubera sacrale (TS) that measured stride-time, velocity and radius of the circle during lungeing. The MTx IMUs were attached to the head (the poll, using a custom-made velcro attachment to the head piece of the bridle) and to the left and right tubera coxae (TC), the withers, the thirteenth (T13), and eighteenth (T18) thoracic vertebrae, and the third lumbar vertebra (L3). These sensors were in custom-made pouches and attached with double-sided tape (F ball Impact Tape, F. Ball Company). An elasticated surcingle was used to fix the wireless transmitter unit (Xbus, Xsens Technologies BV) to the horse's body. Sensors were attached in three strings (1: head; 2: left and right TC, TS, L3 3: withers, T13, T18) to the Xbus transmitting IMU data at a sampling rate of 100Hz per individual sensor channel. All horses assessed at the AHT were also assessed ridden (Appendix A: Supplementary Information: Ridden).

Dynamic assessment with IMUs

All the horses were trotted in hand on a hard surface and then lunged on the left and right reins using a consistent lungeing technique, with a lunge line attached via couplings to the bit

rings. The handlers were asked to keep the same lunge line length throughout the entire examination. IMU data were collected for at least 20 s. Notes and video recordings acquired during data collection described deviations from the expected movement condition, e.g., changes in gait, speed or gait quality. If a horse deviated from the required movement condition (e.g. broke into a different gait), data collection was repeated. One trot trial on both left and right reins in trot was recorded for each circumstance. Horses at the AHT were also assessed ridden by an experienced rider.

All horses were examined by experienced lameness clinicians (Royal College of Veterinary Surgeons Specialist in Equine Orthopaedics, SJD, or Diplomate of the European College of Veterinary Surgeons, AFJ, RKS). In order to provide consistency in lameness between centres, grading was performed by the first author on a 0-8 scale (Dyson, 2011) under each circumstance. All horses were handled by experienced people who were asked to allow the horses to trot at their preferred speeds in hand and on the lunge. The speed was not standardised among horses. The same person handled an individual horse throughout its investigation. All horses were assessed in hand and on the lunge on a 10m diameter circle before and after each nerve block. The lameness was graded before and after diagnostic analgesia for each circumstance. Diagnostic analgesia was performed in all lame limbs and IMU data were collected for at least 20 s under all circumstances after each nerve block.

Data processing

Vertical displacement of the TS and the left and right TC was determined. Processing of IMU data followed published methods (Pfau et al., 2005) with custom-written software in MATLAB (The Mathworks).

Quantification of kinematic symmetry measures

The following kinematic symmetry measurements were determined: symmetry index (SI), MinDiff and MaxDiff for the pelvis and HipHike difference (HHD) (Pfau et al., 2012; Starke et al., 2012). For further details see Appendix A: Supplementary Information: Symmetry measures. A horse moving perfectly symmetrically would have a SI of 1 and MinDiff, MaxDiff and HHD values of 0.

3D kinematics of the vertebral column

A standard right-handed orthogonal Cartesian coordinate system was used (craniocaudal or x: positive values along the line of progression; dorsoventral or z: axis vertical [aligned with the gravitational field] and positive in the upward direction; lateral-lateral or y: axis perpendicular to the first two axes positive to the left of the line of progression). The craniocaudal (x), lateral-lateral (y) and dorsoventral (z) displacement data in the horse-based reference system were calculated following published methods (Pfau et al. 2005; Warner et al., 2010) with modified highpass filter frequencies chosen as 1.5 Hz for dorsoventral and 0.75 Hz for lateral-lateral movement.

Outcome variables

Three rotational/angular variables were measured in degrees. These included flexion-

extension, the body rotation about the transverse (lateral-lateral) axis ROM; axial rotation, the body rotation about the longitudinal (craniocaudal) axis ROM; and lateral bending, the body rotation about the vertical axis ROM, for the withers, T13, T18, L3 and TS. Two translational movements were assessed in mm: dorsoventral movement, the displacement in the vertical direction (up and down movement) of the whole horse and lateral-lateral movement (side to side movement of the whole horse) at the withers, T13, T18 and L3. The asymmetry of the two oscillations of the thoracolumbar movement during a stride based on the SI was also assessed. SI was always calculated as the movement amplitude of the first half of the stride (left hind limb [LH] right forelimb [RF] diagonal stance phase) minus the movement amplitude of the second half of the stride (right hind limb [RH] and left forelimb [LF] diagonal stance phase) and then normalised by dividing by the range of motion and adding one. A symmetry index < 1 indicated less movement in the first half of the stride. A symmetry index > 1 indicated less movement amplitude in the second half of the stride. Asymmetry was defined as the absolute value of $(1-SI) \times 100\%$. In addition, the differences between the two peaks (maxima) [MaxDiff] and two troughs (minima) [MinDiff] of the vertical movement signal were measured. $SI < 1$, $MinDiff < 0$ and $MaxDiff > 0$ indicates left-sided asymmetry. $SI > 1$, $MinDiff > 0$ and $MaxDiff < 0$ indicates right-sided asymmetry. Percentage change between before and after diagnostic analgesia was calculated as $(\text{before}-\text{after})/\text{before} \times 100\%$.

Statistics

For sample size calculation see Appendix A: Supplementary Information: Sample size required. Descriptive analysis was carried out for subjective lameness evaluation and objective outcome variables. Percentage changes in objective outcome variables and subjective lameness

grade before and after diagnostic analgesia when the horses were subjectively maximally improved compared with baseline were calculated. ‘Maximally improved’ involved assessment of many parameters including pelvic asymmetry, regularity of rhythm, step length, impulsion, engagement, balance, body lean, limb flight, quality of paces and quality of contact with the bit (only assessed in ridden horses). Data were assessed for normal data distribution using the Shapiro-Wilk test. Mean \pm standard deviations (SD) for normally distributed data and median and interquartile range for not normally distributed data were determined for the percentage changes in the thoracolumbosacral outcome variables. For parametric variables, a one-sample *t* test was used and for non-parametric data, a one-sample Wilcoxon rank test was used, to test if the mean or median percentage changes, respectively, were different from zero.

For each horse, multiple median movement symmetry values for hind limbs and the thoracolumbosacral region (one before and several after diagnostic analgesia) were calculated across the available strides for every local analgesic technique. The change in movement symmetry in the hind limbs after each local analgesic technique was plotted against the change in thoracolumbosacral movement symmetry after each local analgesic technique and tested for linear associations. All statistical analyses were performed using SPSS Statistics 20 (SPSS, Inc) with significance set at $P < 0.05$.

Results

For information about horses included and quantification of lameness before diagnostic analgesia and speed before and after diagnostic analgesia see Tables 1-2 and Appendix A: Supplementary Results.

Before diagnostic analgesia: Quantification of thoracolumbosacral movement

When assessing the symmetry of the thoracolumbosacral movement in the horses with predominant RH lameness versus horses with predominant LH lameness, there were significant differences between the two groups in movement symmetry at the withers, T13, T18, L3 and TS measured as SI, MinDiff and MaxDiff ($P < 0.001$) (Table 3). Horses with predominant RH lameness (HHD < 0 mm) reached a lower minimum height along the thoracolumbosacral region during the LH (not lame or least lame) diagonal stance phase compared with the RH (lame or lamest) diagonal stance phase. The opposite pattern was seen for horses with predominantly LH lameness (Table 3). Similar patterns but fewer significant differences were observed between predominant LH and RH lame horses for the four other movement symmetry measures MinDiff, MaxDiff and SI of TS (Appendix A: Supplementary Tables 1-3).

Quantification of improvement in lameness by diagnostic analgesia

The median [interquartile range, IQR] and minimum/maximum values of the percentage changes before and after diagnostic analgesia of all outcome variables are shown in Fig. 1. After ‘maximal improvement’ of the lameness, the subjective lameness grade decreased compared with the initial assessment by on average 1.6 grades in straight lines, 0.8 grades on the left rein and 1.5 grades on the right rein on a circle (see Tables 1 and 2 for lameness grades and movement symmetry data after diagnostic analgesia). The MinDiff of TS and HHD decreased by median [IQR] 33% [61%] ($P = 0.01$) and 7% [68%] ($P = 0.006$), respectively. The stride length (quantified as velocity times stride-time) increased by mean \pm SD $5 \pm 2\%$ ($P < 0.001$). There was no significant increase of flexion-extension ROM ($5 \pm 18\%$), and movement in the lateral-lateral

($6 \pm 12\%$) and the dorsoventral ($4 \pm 7\%$) directions and lateral bending ROM (median [IQR]) 0% [14%]. There was a significant increase in ROM for axial rotation 5% [9%] ($P = 0.007$).

Quantification of thoracolumbar movement after improvement of lameness

MinDiff significantly changed by mean [95% Confidence Interval (CI)] -45% [-74;-16] for L3 ($P = 0.005$), whereas no significant changes were seen for T18 -53% [-102;-3] ($P = 0.05$), for T13 -45% [-93;4] % ($P = 0.07$) and the withers (-18% [-55;20], $P = 0.3$). The mean and 95% CI are shown in Fig. 2. Greater movement through the trunk was verified objectively in straight lines and on the lunge by increased flexion-extension ROM, axial rotation ROM, lateral bending ROM and lateral-lateral ROM at all regions; the mean and 95% CI at each measured thoracolumbosacral region are illustrated in Fig. 3. There was significantly increased ROM (median [IQR]) at T13 for flexion-extension 10% [52%] ($P = 0.02$) and at T13 for axial rotation 12% [22%] ($P = 0.02$). There was also significantly increased ROM (mean [95% CI]) at T18 for axial rotation 13% [7;19] ($P < 0.001$); at L3 for axial rotation 11% [4;18] ($P = 0.004$) and at L3 for lateral-lateral movement 7% [1;12] ($P = 0.02$) (Fig. 3). Six horses and seven horses exhibited a decrease in the dorsoventral ROM at T13 or at the withers, respectively.

Sequential blocks

For each horse, multiple median movement symmetry values for the hind limbs and the thoracolumbosacral region (the value before and after each diagnostic analgesic technique, depending on the number of sources of pain) were calculated across the available strides. The change in movement symmetry in the hind limbs after diagnostic analgesia was plotted against the change in thoracolumbosacral movement symmetry after diagnostic analgesia and plotted

against the changes in subjective lameness grades (Fig. 4).

Discussion

The results supported the hypothesis that hind limb lameness induces asymmetry in the thoracolumbosacral movement between the left and right hind limb stance phases that was different between predominantly LH versus RH lameness. The hypothesis that elimination of the hind limb pain would reduce the asymmetry in the thoracolumbosacral movement and increase the ROM was also supported.

The IMUs used for measuring thoracolumbosacral movement before and after elimination of pain with diagnostic analgesia provided a quantitative means of investigating the effect of pain in the limbs \pm SI joint region pain on the symmetry and ROM of the back. Several studies have described the kinematics of the limbs in trot (Back et al., 1995a, b), and others have investigated the kinematics of the trunk (Wennerstrand et al., 2004, 2009). The association between hind limb gait and thoracolumbosacral movement in sound horses, comparing straight lines with circles, has been investigated (Greve et al., 2015b). The effects of experimentally induced unilateral lameness on trunk movement have been described (Faber et al., 2001a; Gómez Álvarez et al., 2007, 2008; Rhodin et al., 2013), but this is the first study which has used biomechanical methods to study the influence of naturally-occurring lameness, which may involve one or more limbs, on the kinematics of the thoracolumbosacral region. The overall purpose of the study was to measure the relationship between hind limb asymmetry and thoracolumbosacral functionality by using an ‘inverse model’ which assessed the response to improvement in naturally occurring lameness by diagnostic analgesia. In this ‘inverse model’, the removal of lameness by diagnostic analgesia and subsequent alteration in range of motion of

the thoracolumbar region may not restore the range of motion of the thoracolumbar region to that which had been present prior to the onset of lameness. The sample size was small, but the approach gives a starting point for elucidating the basic mechanisms by which lameness may lead to altered thoracolumbosacral functionality, clinically evident as saddle slip (Greve and Dyson, 2013, 2014), thoracolumbar pain and reduced ROM (Zimmerman et al., 2011), sacroiliac joint region pain (Dyson and Murray, 2003; Barstow and Dyson, 2015), structural changes in back dimensions over time (Greve and Dyson, 2015a) and compensatory lameness (Rhodin et al., 2016). Whether different changes in thoracolumbosacral movement are seen in horses with primary thoracolumbosacral pain and no associated lameness remains to be determined.

In experimentally induced weight-bearing forelimb and hind limb lameness, there is a reduction in the peak vertical ground reaction force (GRF) in the lame limb, and there are asymmetric timings of the transitions between the lame and sound diagonals and redistribution of load between the forelimbs and hind limbs during stance (Weishaupt et al., 2004, 2006). In 10 Warmblood horses trotting in straight lines and on the lunge, a small ipsilateral and contralateral compensatory hind limb asymmetry was observed in induced forelimb lameness, and a large compensatory ipsilateral forelimb asymmetry was seen in induced hind limb lameness (Rhodin et al., 2013). The vertebral column may be critical in providing an efficient transfer in force between the hind limbs and forelimbs, and it is possible that the reduced ROM of the vertebral column observed in the current study is related to the compensatory mechanism of force distribution (Weishaupt et al., 2006; Rhodin et al., 2013; for further discussion, see Appendix A: Supplementary Information Discussion).

In a study of 805 horses examined in first-opinion practice, there was a high proportion of horses with coexistent lameness and thoracolumbar pain (Landman et al., 2004). Using surface electromyography, significant differences in activities of the longissimus dorsi, semitendinosus and gluteus medius muscles were demonstrated bilaterally between 12 non-lame horses and 12 horses with unilateral hind limb lameness (Zaneb et al., 2009). It was speculated that these lameness-related changes contribute to the development of epaxial muscle pain in lame horses. The functions of the thoracolumbar and pelvic muscles during locomotion with and without pain are complex and coordinated interaction between motor and neural activity (neuromotor control) is required (Moseley et al., 2002; McGill et al., 2003; Moseley and Hodges, 2005). Thus far, the importance of neuromotor control of the thoracolumbosacral movement and the association with development of pain has only been investigated in humans (Comerford and Mottram, 2001; McGill et al., 2003; Wagner et al., 2005; Freeman et al., 2010).

Low back pain in humans occurs more frequently with pronated foot function (Menz et al., 2013) and with leg length inequality (Giles and Taylor, 1981). A pronated foot results in increased internal rotation of the femur and an anterior pelvic tilt (Levine and Whittle, 1996). Presumably, equine hind limb lameness may induce comparable compensatory mechanisms, which in turn may limit the ROM that long-term could lead to thoracolumbosacral pain.

In humans, changes in movement that accompany pain are explained by the vicious cycle (muscle activity increases in a stereotypical manner in pain) (Roland, 1986) and the adaptation to pain theory (decreased activity of muscles that are painful during voluntary efforts, in contrast with increased activity of antagonist or opposing muscles) (Lund et al., 1991). Hodges and

Tucker (2011) proposed that the adaptation to pain is associated with redistribution of activity between and within muscles, and alters mechanical behaviour such as reduced ROM and modified movement. Moreover, the adaptation to pain results in protection from additional pain or injury, and is not simply explained by changes in excitability; there are complementary, additive, or competitive changes at many levels of the motor system. Finally, the adaptation to pain has short-term benefit, and potential long-term consequences because of factors such as decreased movement and increased load.

Short-term, experimentally induced lameness reduced thoracolumbar motion (Buchner et al., 1996; Gómez Álvarez et al., 2007, 2008), and it was suggested that lameness may have an important role in the pathogenesis of thoracolumbar pain. Reduced trunk ROM in ridden sports horses has frequently been attributed to pathology in the thoracolumbosacral vertebral column (Wennerstrand et al., 2004). Lactic acid injected into the epaxial muscles in Standardbreds worked on a treadmill induced reduced ROM in the thoracolumbar vertebral column, changes in the stride pattern, and an inability to perform at fast paces (Jeffcott et al., 1982). Clinical observations indicate that primary thoracolumbar pain may induce reduced ROM of the thoracolumbosacral region and a quadrupedally restricted gait, or limited engagement and impulsion of the hind limbs (Jeffcott, 1980; Girodroux et al., 2009; Zimmerman et al., 2011). Results of the current study show that relief of limb pain immediately enables lame horses to show an increased ROM of the thoracolumbosacral region. This supports the clinical observation that reduced thoracolumbar ROM may be a manifestation of primary hind limb lameness or sacroiliac joint region pain. Subjective assessment and quantification of thoracolumbosacral movement before and after diagnostic analgesia, especially the caudal thoracic and cranial

lumbar regions, are potentially important when assessing lame horses. No conclusions about specific types of lameness can be drawn because of the small number of horses, however common patterns were identified.

Hind limb symmetry patterns on the lunge vary between horses. Some horses were lamer with the lame(r) hind limb on the outside of a circle and others were lamer when the lame(r) hind limb was on the inside of a circle. There are many biomechanical factors that could influence pain e.g., changes in propulsive and transversal forces, vertical impulse, loading rate, peak moment around longitudinal and vertical axes etc. (Chateau et al., 2005, 2013). However, there is no clear explanation for the differences in patterns of lameness among horses. Investigation of many more horses with similar diagnoses is required.

In the present study, the asymmetry of the thoracolumbosacral movement was dependent on the lameness: the horses reached a lower minimum height along the thoracolumbosacral region during the sound or least lame diagonal stance phase compared with the lame(r) diagonal stance phase. Alteration in asymmetry of thoracolumbosacral movement may explain why some horses with hind limb lameness have saddle-slip (Greve and Dyson, 2013, 2014). It is possible that differences in vertical and forwards-backwards forces and movement (Bell et al., 2016) are related to saddle movement, but quantitative assessment of many more horses is warranted.

In a kinematic study of 27 hound-type dogs, the thoracolumbar joint angle was defined by the positions of three reflective markers on the dorsal midline of the thoracolumbar region (Hicks et al., 2013). Eleven dogs (41%) demonstrated a two- to 10-fold increase in the mean

thoracolumbar lateral angular displacement on the side with a lower degree of weight bearing (lame side) compared with the side with a greater degree of weight bearing during the swing phase of the gait cycle. If similar changes occurred in thoracolumbar angular movement in ridden horses with hind limb lameness, this might account for saddle-slip. However, there is currently no practical method of accurately measuring this using IMUs.

IMUs measure movement resulting in many outcome variables. This led to testing the associations between many parameters. It is important to be aware that there is a higher risk of Type 1 error if many comparisons are assessed using the same data. However, our sample size was too small to adjust for the increased Type 1 error due to multiple comparisons. There appeared to be linear associations between MinDiff for all regions, HHD and subjective changes, however, more horses are needed with observations that are independent, i.e. not involving repeated measures on the same horse, to be able to perform statistical tests for linear associations.

Conclusions

The results of the study have increased our understanding of thoracolumbosacral movement in lame horses in straight lines in hand and on the lunge. Improvement in lameness by diagnostic analgesia resulted in increased thoracolumbosacral ROM and reduced asymmetry of movement.

Conflict of interest statement

None of the authors of this paper has a financial or personal relationship with other people

or organisations that could inappropriately influence or bias the content of the paper.

Acknowledgements

We thank the many horses and their owners who participated in the study and Roger Smith and Andrew Fiske-Jackson for performing clinical lameness examinations.

Appendix A: Supplementary Information

Supplementary data associated with this article can be found, in the online version, at doi: ...

References

- Back, W., Schamhardt, H.C., Savelberg, H.H., van den Bogert, A.J., Bruin, G., Hartman, W., Barneveld, A., 1995a. How the horse moves: 1. Significance of graphical representations of equine forelimb kinematics. *Equine Veterinary Journal* 27, 31-38.
- Back, W., Schamhardt, H.C., Savelberg, H. H., van den Bogert, A.J., Bruin, G., Hartman, W., Barneveld, A., 1995b. How the horse moves: 2. Significance of graphical representations of equine hind limb kinematics. *Equine Veterinary Journal* 27, 39-45.
- Barstow, A., Dyson, S., 2015. Clinical features and diagnosis of sacroiliac joint region pain in 296 horses: 2004–2014. *Equine Veterinary Education*, 27, 2042-3292.
- Bell, R.P., Reed, S.K., Schoonover, M.J., Whitfield, C.T., Yonezawa, Y., Maki, H., Pai, P.F., Keegan, K.G., 2016. Associations of force plate and body-mounted inertial sensor measurements for identification of hind limb lameness in horses. *American Journal of Veterinary Research* 77, 337-345.
- Buchner, H., Savelberg, H., Schamhardt, H., Barneveld, A., 1996. Head and trunk movement adaptations in horses with experimentally induced fore- or hind limb lameness. *Equine Veterinary Journal* 28, 71-76.
- Chateau, H., Degueurce, C., Denoix, J.M., 2005. Three-dimensional kinematics of the equine distal forelimb: effects of a sharp turn at the walk. *Equine Veterinary Journal* 37, 12-18.
- Chateau, H., Camus, M., Holden-Douilly, L., Falala, S., Ravary, B., Vergari, C., Lepley, J., Denoix, J.M., Pourcelot, P., Crevier-Denoix, N., 2013. Kinetics of the forelimb in horses

- circling on different ground surfaces at the trot. *The Veterinary Journal* 198 (Suppl. 1), 20-26.
- Comerford, M.J., Mottram, S.L., 2001. Movement and stability dysfunction – contemporary developments. *Manual Therapy* 6, 15–26.
- Dyson, S., Murray, R., 2003. Pain associated with the sacroiliac joint region: a clinical study of 74 horses. *Equine Veterinary Journal* 35, 240-245.
- Dyson, S., 2011. Can lameness be reliably graded? *Equine Veterinary Journal* 43, 379-382.
- Dyson, S., Greve, L., 2016. Subjective gait assessment of 57 sports horses in normal work: a comparison of the response to flexion tests, movement in hand, on the lunge and ridden. *Journal of Equine Veterinary Science* 38, 1-7
- Faber, M., Schamhardt, H., Weeren, R. van, Johnston, C., Roepstorff, L., Barneveldt, A., 2000. Basic three dimensional kinematics of the vertebral column of horses walking on a treadmill. *American Journal of Veterinary Research* 61, 399-406.
- Faber, M., Johnston, C., Schamhardt, H., van Weeren, R., Roepstorff, L., Barneveld, A., 2001a. Basic three-dimensional kinematics of the vertebral column of horses trotting on a treadmill. *American Journal of Veterinary Research* 62, 757-764.
- Faber, M., Johnston, C., Schamhardt, H.C., Weeren, P.R. van, Roepstorff, L., Barneveldt, A., 2001b. Three dimensional kinematics of the equine spine during canter. *Equine Veterinary Journal* 33, 145-149.
- Faber, M., Johnston, C., Weeren, P.R. van, Barneveldt, A., 2002. Repeatability of back kinematics in horses during treadmill locomotion. *Equine Veterinary Journal* 34, 235-241.
- Freeman, M.D., Woodham, M.A., Woodham, A.W., 2010. The role of the lumbar multifidus in chronic low back pain: a review. *The Journal of Injury, Function and Rehabilitation* 2, 142–146.
- Giles, L.G., Taylor, J.R., 1981. Low back pain associated with leg length inequality. *Spine* 6, 510-521.
- Girodroux, M., Dyson, S., Murray, R., 2009. Osteoarthritis of the thoracolumbar synovial intervertebral articulations: clinical and radiographic features in 77 horses with poor performance and back pain. *Equine Veterinary Journal* 41, 130-138.
- Gómez Álvarez, C. B., Wennerstrand, J., Bobbert, M. F., Lamers, L., Johnston, C., Back, W., van Weeren, P. R., 2007. The effect of induced forelimb lameness on thoracolumbar kinematics during treadmill locomotion. *Equine Veterinary Journal* 39, 197-201.

- Gómez Álvarez, C. B., Wennerstrand, J., Bobbert, M. F., Lamers, L., Johnston, C., Back, W., van Weeren, P. R., 2008. The effect of induced hind limb lameness on thoracolumbar kinematics during treadmill locomotion. *Equine Veterinary Journal* 40, 147-152.
- Greve, L. Dyson, S., 2013. An investigation of the relationship between hind limb lameness and saddle-slip. *Equine Veterinary Journal* 45, 570-577.
- Greve, L., Dyson, S., 2014. The interrelationship of lameness, saddle-slip and back shape in the general sports horse population. *Equine Veterinary Journal* 46, 687-694.
- Greve, L., Dyson, S., 2015a. A longitudinal study of back dimension changes over 1 year in sports horses. *The Veterinary Journal* 203, 65-73.
- Greve, L., Pfau, T., Dyson, S., 2015b. Thoracolumbar movement in sound horses trotting in straight lines in hand and on the lunge. *Equine Veterinary Journal* 47 (Suppl. 48), 11.
- Hicks A. D., 2013. Kinetic and kinematic evaluation of compensatory movements of the head, pelvis and thoracolumbar spine associated with asymmetrical weight bearing of the pelvic limbs in dogs. PhD thesis, The University of Tennessee, Knoxville, USA. pp. 10-50.
- Hobbs, S.J., Licka, T., Polman, R., 2011. The difference in kinematics of horses walking, trotting and cantering on a flat and banked 10 m circle. *Equine Veterinary Journal* 43, 686-694.
- Hodges, W. P., Tucker, K., 2011. Moving differently in pain: A new theory to explain the adaptation to pain. *Pain* 152, 90-98.
- Jeffcott, L. B., 1980. Disorders of the thoracolumbar spine of the horse - a survey of 443 cases. *Equine Veterinary Journal* 12, 197-210.
- Jeffcott L. B., Dalin G., 1980. Natural rigidity of the horse's backbone. *Equine Veterinary Journal* 12, 101-108.
- Jeffcott, L.B., Dalin, G., Drevemo, S., Fredricson, I., Bjorne, K., Bergquist, A., 1982. Effect of induced back pain on gait and performance of trotting horses. *Equine Veterinary Journal* 14, 129-133.
- Johnston, C., Holme, K., Faber, M., Erichsen, C., Eksell, P., Drevemo, S., 2002. Effect of conformational aspects on the movement of the equine back. *Equine Veterinary Journal* 34 (Suppl. 34), 314-318.
- Keegan, K.G., Pai, P.F., Wilson, D.A., Smith B. K., 2001. Signal decomposition method of evaluating head movement to measure induced forelimb lameness in horses trotting on a treadmill. *Equine Veterinary Journal* 33 (Suppl. 5), 446-451.
- Kramer, J., Keegan, K.G., Kelmer, G., Wilson, D.A., 2004. Objective determination of pelvic movement during hind limb lameness and pelvic height differences. *American Journal*

- Veterinary Research 65, 741-747.
- Landman, M.A., de Blaauw, J.A., van Weeren, P.R., Hafland, L.J., 2004. Field study of the prevalence of lameness in horses with back problems. *Veterinary Record* 155, 165-168.
- Levine, D., Whittle, M.W., 1996. The effects of pelvic movement on lumbar lordosis in the standing position. *Journal of Orthopedic Sports Physiological Therapy* 24, 130-135.
- Licka, T., Peham, C., Zohmann, E., 2001a. Range of back movement at trot in horses without back pain. *Equine Veterinary Journal* 33 (Suppl. 33), 150-153.
- Licka, T., Peham, C., Zohmann, E., 2001b. Treadmill study of the range of back movement at the walk in horses without back pain. *American Journal of Veterinary Research* 62, 1173-1179.
- Lund, J.P., Donga, R., Widmer, C.G., Stohler, C.S., 1991. The pain-adaptation model: a discussion of the relationship between chronic musculoskeletal pain and motor activity. *Canadian Journal of Physiology and Pharmacology* 69, 683-694.
- Martin, P., Chateau, H., Pourcelot, P., Duray, L., Cheze, L., 2014. Comparison between inertial sensors and motion capture system to quantify flexion-extension motion in the back of a horse. *Equine Veterinary Journal* 46 (Suppl. 46), 43.
- May, S.A., Wyn-Jones, G., 1987. Identification of hindleg lameness. *Equine Veterinary Journal* 19, 185-188.
- McGill, S.M., Grenier, S., Kavci, N., Cholewicki, J., 2003. Coordination of muscle activity to assure stability of the lumbar spine. *Journal of electromyography and kinesiology* 13, 353-359.
- Menz, H. B., Dufour, A. B., Riskowski, J. L., Hillstrom, H. J., Hannan, M. T., 2013. Foot posture, foot function and low back pain: the Framingham Foot Study. *Rheumatology (Oxford)* 52, 2275-2282.
- Moseley, G.L., Hodge, P.W., 2005. Are the changes in postural control associated with low back pain caused by pain interference? *Clinical Journal of Pain* 21, 323-329.
- Pfau, T., Witte, T.H., Wilson, A.M., 2005. A method for deriving displacement data during cyclical movement using an inertial sensor. *Journal Experimental Biology* 208, 2503-2514.
- Rhodin, M., Pfau, T., Roepstorff, L. Egenvall, A., 2013. Effect of lungeing on head and pelvic movement asymmetry in horses with induced lameness. *The Veterinary Journal* 198 (Suppl. 1), 39-45.
- Rhodin, M., Roepstorff, L., French, A., Keegan, K., Pfau, T., Egenvall, A., 2016 Head and pelvic

- movement asymmetry during lungeing in horses showing symmetrical movement on the straight. *Equine Veterinary Journal* 48, 315-320.
- Roland, M., 1986. A critical review of the evidence for a pain–spasm–pain cycle in spinal disorders. *Clinical Biomechanics* 1, 102–109.
- Starke, S.D., Willems, E., May, S.A., Pfau, T., 2012. Vertical head and trunk movement adaptations of sound horses trotting in a circle on a hard surface. *The Veterinary Journal* 193, 73-80.
- Townsend, H. G. G., Leach, D. H., Fretz, P. B., 1983. Kinematics of the equine thoracolumbar spine. *Equine Veterinary Journal* 15, 117-122.
- Wagner, H., Anders, C.H., Puta, C.H., Petrovitch, A., Mörl, F., Schilling, N., Witte, H., Blickhan, R., 2005. Musculoskeletal support of lumbar spine stability. *Pathophysiology* 12, 257–265.
- Warner, S.M., Koch, T.O., Pfau, T., 2010. Inertial sensors for assessment of back movement in horses during locomotion over ground. *Equine Veterinary Journal* 42, 417–424.
- Weishaupt, M.A., Wiestner, T., Hogg, H.P., Jordan, P., Auer, J.A., 2004. Compensatory load redistribution of horses with induced weightbearing hind limb lameness trotting on a treadmill. *Equine Veterinary Journal* 36, 727-733.
- Weishaupt, M.A., Wiestner, T., Hogg, H.P., Jordan, P., Auer, J.A., 2006 Compensatory load distribution of horses with induced weight-bearing forelimb lameness trotting on a treadmill. *The Veterinary Journal* 171, 135–146.
- Wennerstrand, J., Johnston, C., Roethlisberger- Holm, K., Erichsen, C., Eksell, P., Drevemo, S., 2004 Kinematic evaluation of the back in the sport horse with back pain. *Equine Veterinary Journal* 36, 707–711.
- Wennerstrand, J., Gómez Alvarez, C.B., Meulenbelt, R., Johnston, C., van Weeren, P.R., Roethlisberger-Holm, K., Drevemo, S., 2009. Spinal kinematics in horses with induced back pain. *Veterinary Comparative Orthopaedics and Traumatology* 22, 448-454.
- Zaneb, H., Kaufmann, V., Stanek, C., Peham, C., Licka, T. F., 2009. Quantitative differences in activities of back and pelvic limb muscles during walking and trotting between chronically lame and nonlame horses. *American Journal of Veterinary Research* 70, 1129-1134.
- Zimmerman, M., Dyson, S., Murray, R., 2011. Close, impinging and overriding spinous processes in the thoracolumbar spine: The relationship between radiological and scintigraphic findings and clinical signs. *Equine Veterinary Journal* 44, 178-184.

Figure legends

Fig. 1. Boxplot of the percentage changes in the range of motion of the thoracolumbosacral region before and after lameness was subjectively maximally improved by diagnostic analgesia. These results represent the median values i.e., the vertical line, the interquartile ranges i.e., the grey boxes and the maximum/minimum values i.e., the horizontal lines, for trotting in straight lines and in circles on the lunge in 13 subjectively lame horses. Angular motion/rotations measured in degrees: FE, flexion-extension; AR, Axial rotation; LB, lateral bending. Translational motion measured in mm: LL, lateral-lateral motion; DV, dorsoventral motion. Tubera sacrale, TS. Circles, mean; Bars, standard error.

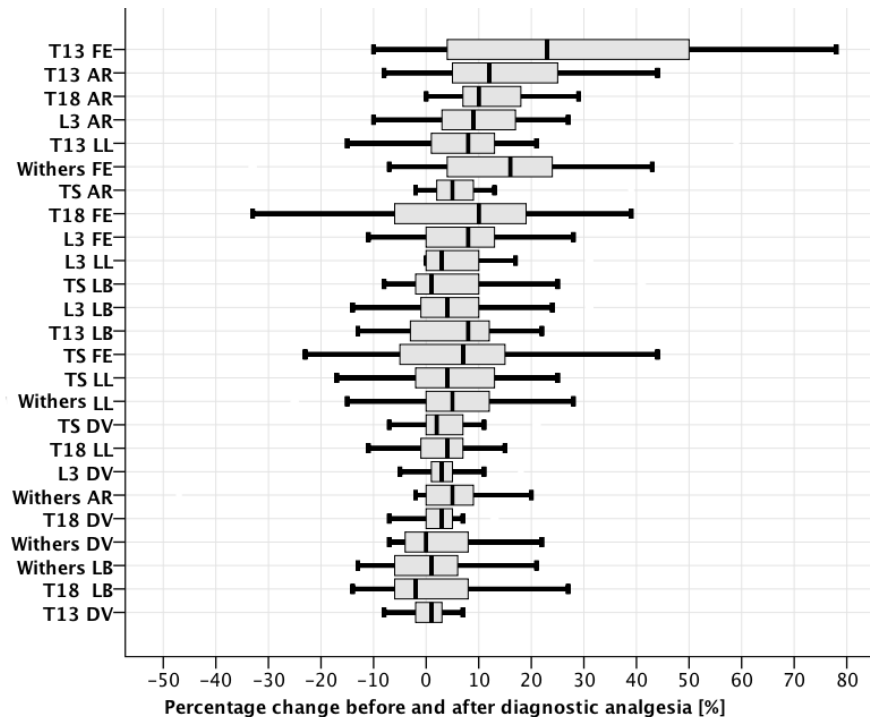


Fig. 2. The mean and 95% CI of the percentage change of the difference between the two troughs (minima) [MinDiff] of the vertical movement signal [mm] of the thoracolumbar region of the average of trotting in straight lines and in circles on the lunge in 13 subjectively lame horses before and after lameness was subjectively maximally improved by diagnostic analgesia. Tubera sacrale, TS and HHD, HipHikeDifference defined as the difference in upward movement of each tuber coxae during contralateral hind limb stance. Circles, mean; Bars, standard error.

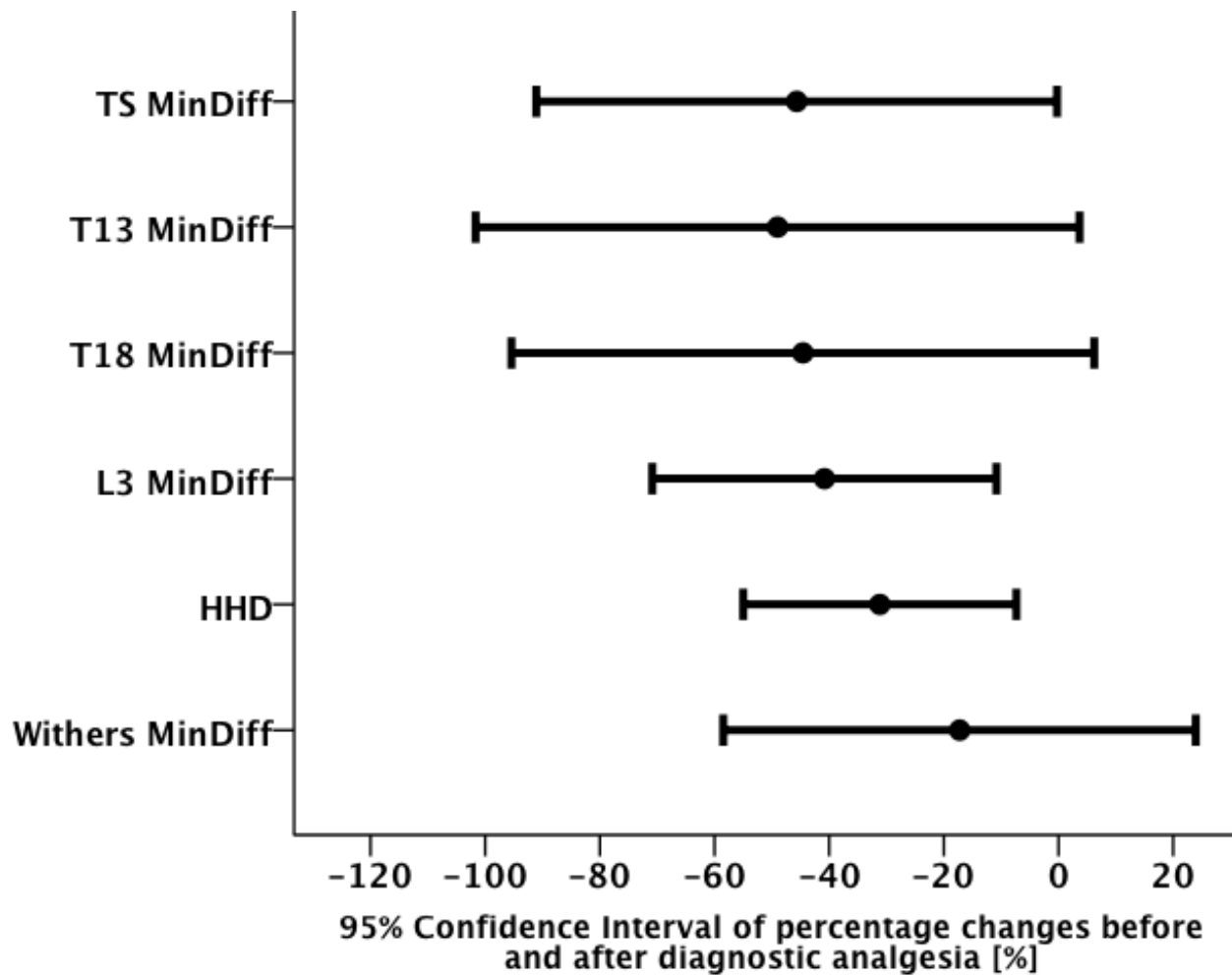


Fig. 3. The mean and 95% CI of the percentage changes in the range of motion of the thoracolumbosacral region before and after lameness was subjectively maximally improved by diagnostic analgesia. These results represent the mean values for trotting in straight lines and in circles on the lunge in 13 subjectively lame horses. Angular motion/rotations measured in degrees: FE, flexion-extension; AR, Axial rotation; LB, lateral bending. Translational motion measured in mm: LL, lateral-lateral motion; DV, dorsoventral motion. Tubera sacrale, TS; Circles, mean; Bars, standard error.

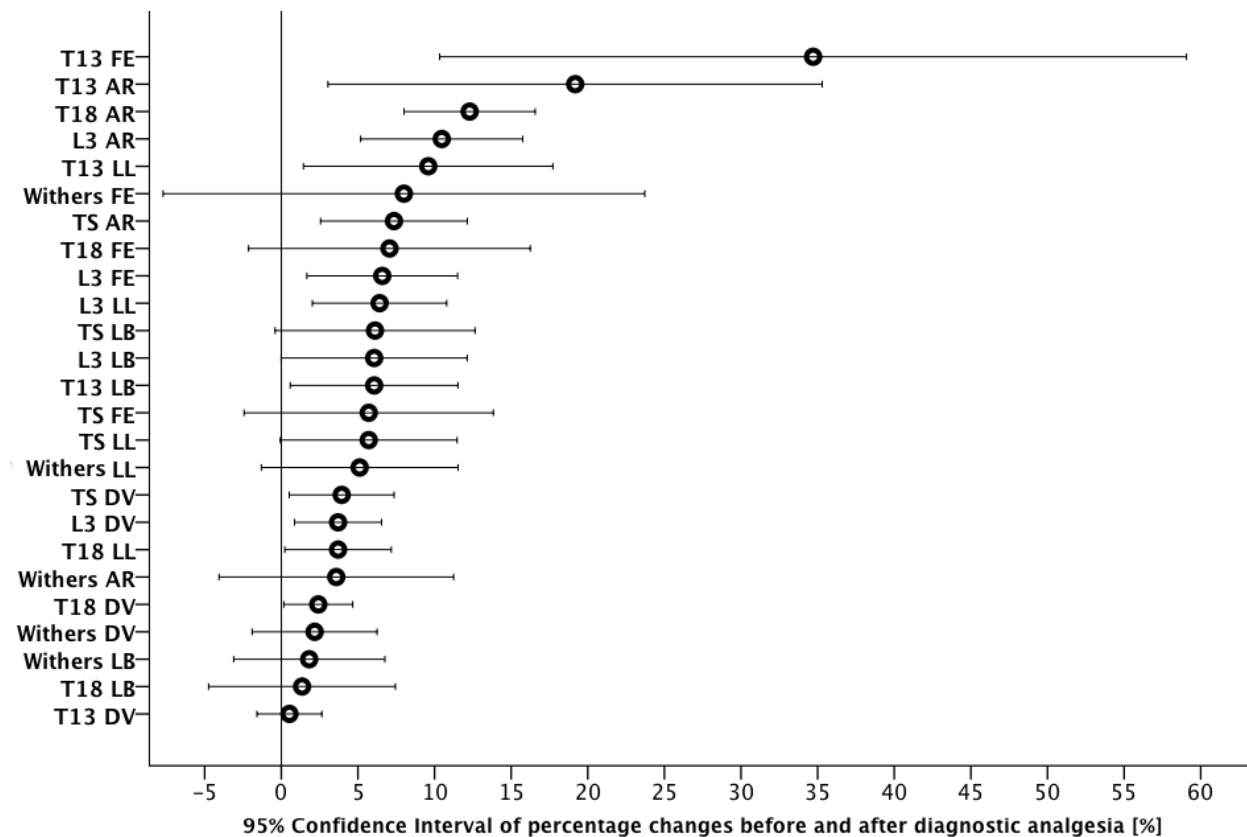


Fig. 4. Thirteen subjectively lame horses had multiple median movement symmetry values for the hind limbs and the thoracolumbosacral region (the values before and after each diagnostic analgesic technique, depending on the number of sources of pain) calculated across the available strides. The change in movement symmetry measured as the difference between the two troughs (minima) [MinDiff which is abbreviated as MinD] of the vertical movement signal [mm] after diagnostic analgesia was plotted against the change in thoracolumbosacral movement symmetry after diagnostic analgesia and plotted against changes in subjective lameness grades using a 0-8 scale, Dyson, 2011). There appear to be linear associations between MinDiff for all regions, HHD and subjective changes, however, more horses are needed with observations that are independent, i.e. not involving repeated measures on the same horse, to be able to perform statistical tests for linear associations. TS, Tubera Sacrale; HHD, HipHikeDifference defined as the difference in upward movement of each tuber coxae during contralateral hind limb stance.




Table 1

The hind limb movement symmetry in five horses with unilateral hind limb lameness ^a assessed in straight lines and on the lunge on both the left and right reins before and after diagnostic analgesia.

Lameness pattern on the lunge	Diagnostic analgesia	Straight lines				Left rein				Right rein			
		Subj**	Max-Diff [mm]	HHD [mm]	Min-Diff [mm]	Subj**	Max-Diff [mm]	HHD [mm]	Min-Diff [mm]	Subj**	Max-Diff [mm]	HHD [mm]	Min-Diff [mm]
Lamest when the lame hind limb was on the outside of the circle	Before	3 LH	-15	15	4	1 LH	1	35	-9	3 LH	-17	32	-1
	After	1 LH	-10	5	-1	Sound	6	12	12	1 LH	-19	5	-1
	Before	4 LH	-11	30	11	Sound	-4	18	11	2 LH	-4	18	7
	After	3 LH	-4	24	12	Sound	-7	28	8	1 LH	-11	5	8
Lamest when the lame hind limb was on the inside of the circle	Before	3 RH	4	-18	-12	Sound	-7	31	22	5 RH	17	-62	-38
	After**	1 RH	-1	-9	-10	1 LH	-12	40	28	1 RH	-2	-31	-25
	Before	5 RH	31	-41	-14	3 RH	25	-30	-15	4 RH	17	-38	-17
	After	0 ^b RH	14	1	-7	1 RH	12	0	-3	1 RH	7	-17	-3
	Before	2 LH	3	13	8	2 LH	-3	39	30	Sound	-7	-15	-18
	After	1 LH	0	11	11	1 LH	-3	33	26	Sound	2	-12	-13

^a Lameness was graded on a 0-8 (Dyson, 2011) scale for each circumstance under which the horse was examined. The numbers represent the lameness grades at the initial assessment and at the final assessment i.e., ‘maximally’ improved.

^b Subtle residual gait asymmetry, but less than grade 1. ‘Improved’ after diagnostic analgesia involved assessment of many parameters in addition to pelvic movement, including regularity of rhythm, step length, impulsion, engagement, balance, body lean, limb flight.

Subj**, Lameness limb and lameness grade; MaxDiff, The difference between the two peaks (maxima) of the vertical movement of the tubera sacrale (TS); MinDiff, The difference between the two troughs (minima) of the vertical movement of the TS; HHD, HipHike-Difference, defined as the difference in upward movement of each tuber coxae during contralateral hind limb stance (mm); HL(s), hind limbs; LH, left hind limb; RH, right hind limb.

Table 2

The hind limb movement symmetry in eight horses with bilateral hind limb lameness ^a assessed in straight lines and on the lunge on both the left and right reins before and after diagnostic analgesia.

Lameness pattern on the lunge	Diagnostic analgesia	Straight lines				Left rein				Right rein				
		Subj**	Max-Diff [mm]	HHD [mm]	Min-Diff [mm]	Subj**	Max-Diff [mm]	HHD [mm]	Min-Diff [mm]	Subj**	Max-Diff [mm]	HHD [mm]	Min-Diff [mm]	
Lamest on the hind limb which was on the inside of the circle	Before	1 RH	1	-5	-3	1 LH	0	31	22	2 RH	-2	-26	-27	
	After	0* RH	-4	-8	-8	0* LH	1	25	19	0* RH	-8	-22	-28	
	Before	3 LH	3	12	6	1 LH	-4	17	11	1 RH	9	-22	-17	
	After	1 LH	0	6	8	Sound	1	11	12	1 RH	21	-35	-12	
	Before	1 LH	-3	8	2	1 LH	5	23	23	1 RH	-7	-21	-24	
	After	Sound	3	-2	-3	Sound	6	25	29	Sound	-1	-18	-23	
	Before	3 LH	-14	24	-1	1 LH	-3	25	11	1 RH	-7	-7	-21	
	After	0* LH	-6	13	1	1 LH	-1	35	21	Sound	-9	-6	-14	
	Lamest on one hind limb on one or both reins	Before	2 LH	0	11	12	2 LH	-6	21	16	3 LH	-6	34	26
		After	Sound	-2	7	8	Sound	0	17	16	2 LH	-7	18	16
		Before	Sound	4	-4	0	1 RH	12	12	14	1 RH	-1	-31	-20
		After	0* RH	6	-14	-3	Sound	9	3	10	Sound	-2	-38	-19
Before		Sound	-6	5	-2	Sound	9	5	15	1 RH	-4	-22	-23	
After		Sound	-5	-1	-7	0* RH	6	0	7	Sound	-6	-19	-23	
Lamest on the hind limb which was on the outside of the circle	Before	1 RH	10	7	7	1 RH	29	0	19	2 LH	2	-12	-10	
	After	Sound	5	-4	5	1 LH	16	0	9	1 RH	6	-18	-10	

^a Lameness was graded on a 0-8 (Dyson, 2011) scale for each circumstance under which the horse was examined. The numbers represent the lameness grades at the initial assessment and at the final assessment i.e., 'maximally' improved.

^b Subtle residual gait asymmetry, but less than grade 1. 'Improved' after diagnostic analgesia involved assessment of many parameters in addition to pelvic movement, including regularity of rhythm, step length, impulsion, engagement, balance, body lean, limb flight.

Subj**, Lane limb and lameness grade; MaxDiff, The difference between the two peaks (maxima) of the vertical movement of the tubera sacrale (TS); MinDiff, The difference between the two troughs (minima) of the vertical movement of the TS; HHD, HipHikeDifference, defined as the difference in upward movement of each tuber coxae during contralateral hind limb stance (mm); HL, hind limbs; LH, left hind limb; RH, right hind limb;

Table 3

The symmetry of the thoracolumbosacral movement in 13 subjectively lame horses assessed trotting in straight lines and in circles on the lunge, comparing predominant right hind limb lameness and left hind limb lameness.^a

Parameter	Thoracolumbar region	Mean \pm SE		<i>P</i>
		HHD < 0mm RH lameness	HHD > 0mm LH lameness	
SI	Withers	1.09 \pm 0.04	0.92 \pm 0.03	< 0.001 ^b
	T13	1.10 \pm 0.03	0.89 \pm 0.02	< 0.001 ^b
	T18	1.12 \pm 0.04	0.91 \pm 0.02	< 0.001 ^b
	L3	1.13 \pm 0.04	0.91 \pm 0.02	< 0.001 ^b
	TS	1.15 \pm 0.05	0.93 \pm 0.03	< 0.001 ^b
MaxDiff [mm]	Withers	5.5 \pm 2.4	-1.3 \pm 1.7	0.02 ^b
	T13	5.7 \pm 2.2	-2.7 \pm 1.6	< 0.001 ^b
	T18	6.1 \pm 2.1	-2.8 \pm 1.3	< 0.001 ^b
	L3	6.2 \pm 1.9	-2.5 \pm 1.2	< 0.001 ^b
	TS	6.0 \pm 2.1	-2.4 \pm 1.6	< 0.001 ^b
MinDiff [mm]	Withers	-0.8 \pm 3.3	4.8 \pm 3.1	0.2
	T13	-3.3 \pm 2.3	7.4 \pm 2.0	< 0.001 ^b
	T18	-4.9 \pm 2.0	6.1 \pm 1.4	< 0.001 ^b
	L3	-5.5 \pm 2.4	6.2 \pm 1.6	< 0.001 ^b
	TS	-7.1 \pm 3.5	4.6 \pm 2.7	0.01 ^b
HHD	TC	-13.8 \pm 4.9	9.9 \pm 3.0	< 0.001 ^b

^a For all horses that had average HHD < 0mm for in hand in straight lines and on the lunge (which does not necessarily equate to right hind limb [RH] lameness on both reins on the circle, but when taking all three exercise conditions into account, there was predominantly RH asymmetry) versus the horses that had on average HHD > 0mm for in hand in straight lines and on the lunge (predominantly left hind limb [LH] lameness), there were significant differences in the symmetry at the withers, T13, T18, L3 and TS measured as SI, MinDiff and MaxDiff ($P < 0.001$), when the means of in hand and lungeing on both reins were compared. Horses with predominantly RH lameness (HHD < 0 mm) reached a lower minimum height along the thoracolumbosacral region during the LH (not lame or least lame) diagonal stance phase compared with the RH (lame or lamest) diagonal stance phase when looking at the average of in hand and lungeing on both reins. The opposite pattern was seen for horses with predominantly LH lameness.

^b Statistically significant differences between the two groups (Student's *t* test).

TS, Tubera sacrale; TC, Tubera coxae; HHD, HipHikeDifference defined as the difference in upward movement of each tuber coxae during contralateral hind limb stance; RH, right hind limb; LH, left hind limb