

RVC OPEN ACCESS REPOSITORY – COPYRIGHT NOTICE

This is the peer reviewed version of:

Mehl NS, Khalid M, Srisuwatanasagul S, Swangchan-Uthai T, and Sirivaidyapong S. Comparison of the ovarian and uterine reproductive parameters, and the ovarian mRNA and protein expression of LHR and FSHR between the prepubertal and adult female cats. *Reprod Dom Anim.* 2017;52(Suppl. 2):41–44. <https://doi.org/10.1111/rda.12926>

This article may be used for non-commercial purposes in accordance with [Wiley Terms and Conditions for Self-Archiving](#).

The full details of the published version of the article are as follows:

TITLE: Reproduction in Domestic Animals

AUTHORS: NS Mehl, M Khalid, S Srisuwatanasagul, T Swangchan-Uthai, S Sirivaidyapong

JOURNAL TITLE: Reproduction in Domestic Animals

PUBLISHER: Wiley

PUBLICATION DATE: 12 April 2017 (online)

DOI: 10.1111/rda.12926

Faculty of Veterinary Science, Chulalongkorn University

Bangkok, Thailand

Comparison of the ovarian and uterine reproductive parameters, and the ovarian mRNA and protein expression of LHR and FSHR between the prepubertal and adult female cats.

Nicole Sirisopit Mehl^A, Muhammad Khalid^B, Sayamon Srisuwatanasagul^C,
Theerawat Swangchan-Uthai^A, and Sudson Sirivaidyapong^A.

^ADepartment of Obstetrics, Gynaecology and Reproduction, Faculty of Veterinary Science, Chulalongkorn University, Bangkok, Thailand. ^BDepartment of Production and Population Health, The Royal Veterinary College, University of London, UK, and

^CDepartment of Anatomy, Faculty of Veterinary Science, Chulalongkorn University, Bangkok, Thailand. cudnicole@gmail.com

Contents

This study aimed to evaluate and compare the ovarian and uterine characteristics along with the ovarian mRNA and protein expression of LHR and FSHR between the prepubertal and adult female cats. The uterine horns and ovaries were collected from prepubertal and adult female cats at their follicular, luteal and interestrus stages of the estrous cycle (n = 6/group). Endometrial and myometrial thickness, uterine gland diameter, ovarian weight and type of follicles were analyzed. The mRNA and protein expression of LHR and FSHR was analyzed by IHC and qPCR, respectively. The ovarian weight of prepubertal cats was significantly lower than that of adult cats. No differences were recorded in the numbers of primordial and

primary follicles between the study groups, while adult luteal cats had significantly lower numbers of antral follicles compared to prepubertal cats. No differences in the ovarian expression of FSHR mRNA, LHR protein or mRNA were found between the prepubertal and adult cats, but significantly lower FSHR protein expression was found in prepubertal cats compared to adult luteal cats.

Introduction

Ovarian cycle in mammals is controlled by gonadotropins (LH and FSH) and their receptors in the reproductive tract. Felid species are known to have a complicated ovarian cycle. However, the knowledge of the normal functions of the reproductive tract can play an important role in the development and improvement of reproductive assistance and contraceptive technology. While gonadotropins play an important role to control the function and the development of the reproductive tract, there is limited information about their actions on the felids' reproductive organs; some available information shows that LHR and FSHR expression is related to the follicle diameter (Saint-Dizier et al. 2007). Additional information in this area would be very valuable regarding the techniques used for reproductive assistance and/or contraception not only in domestic cats but also in wild felid species. The main objective of this study was to evaluate and compare the ovarian and uterine characteristics along with the ovarian mRNA and protein expression of LHR and FSHR between the prepubertal and adult female cats.

Materials and Methods

Experimental design and animals

With the approval of the university ethical committee by Chulalongkorn University Laboratory Animal Center (license number 13310056) and the consent of the owners, ovaries and uteri were collected from cats admitted for ovariohysterectomy (OVH) in the small animal hospital, Faculty of Veterinary Science, Chulalongkorn University, Bangkok, Thailand. Ovaries and uteri were collected from prepubertal cats (n = 6) at the age of 3 months and adult cats at the age of 1 – 3 years when they were at their follicular (n = 6), luteal (n = 6) and inactive (n = 6) stage of the estrous cycle. Stage of the estrous cycle was determined in these cats by their behavior, vaginal cytology and serum estradiol and progesterone concentrations (Johnston et al. 2001). Structures present on the ovaries (follicles and corpora lutea) obtained after ovariohysterectomy were also used to confirm the stage of the estrous cycle.

Morphology of female reproductive organs

After ovariohysterectomy, ovarian weight, structures present on the ovary and their morphological appearance were recorded. The ovaries and uteri were divided into two parts; one part was fixed in 4% (w/v) paraformaldehyde for 48 to 72 hours and then stored in 70% ethanol until processing, whereas the other part was snap frozen in liquid nitrogen and stored at -80 °C until RNA extraction. Fixed uterine and ovarian tissues were embedded in paraffin wax and cut into 5µm sections by a rotor microtome, applied to gelatin-coated slides and left to dry in an incubator at 37°C, then stained with hematoxylin and eosin staining.

Histological investigation of the uterus was performed under light microscope; five sections per uterine horn and five fields per section at 40X magnification were captured for the measurement of the thickness of endometrium and myometrium and

five fields per section at 200X magnification for the measurement of the uterine gland diameter. Different types of follicles (primordial, primary, secondary and antral) and corpora lutea were counted from 5 sections per ovary and 5 fields per section under light microscope at 100X magnification. The number of different types of follicles were recorded per mm² of the ovarian cortex area.

LHR and FSH Expression and Quantification of the immunohistochemical staining and Quantitative real-time polymerase chain reaction (qPCR) for the LHR and FSHR mRNA in the ovarian tissue

The ovarian tissue sections were deparaffinized to perform the immunohistochemical staining as reported in our previous study (Mehl et al. 2016).

The pattern and intensity of protein staining for LHR and FSHR were determined semi-quantitatively using a histochemical score (H-SCORE) method. A mean expression index was calculated for the LHR or FSHR in each ovarian tissue section from an individual animal (Ishibashi et al. 2003, Ponglowhapan et al. 2008, Chowdhury et al. 2010).

For the mRNA expression, extraction and reverse transcription of mRNA and the procedure of Quantitative real-time PCR were performed following the method described in our previous study (Mehl et al. 2016).

Statistical analysis

General linear model (GLM) was performed to compare the ovarian weight, the endometrial gland diameter, the thickness of endometrium and myometrium, the number of corpora lutea and follicles (primordial, primary, secondary and antral), the

mRNA and protein expression of LHR and FSHR among the different experimental groups of cats. The differences between the mean values were considered significant at $P \leq 0.05$.

Results

Morphology of female reproductive organs

The ovarian weight (g) of prepubertal cats (0.08 ± 0.01) was significantly lower ($P \leq 0.05$) than that of adult cats at luteal (0.13 ± 0.02) and follicular stage (0.12 ± 0.01) of the estrous cycle. No differences were observed in the ovarian weight between prepubertal cats and the cats at the inactive stage (0.08 ± 0.01) of their estrous cycle. No differences were recorded in the numbers of primordial and primary and secondary follicles between the prepubertal and adult cats except the adult luteal cats had significantly lower ($P \leq 0.05$) numbers of antral follicles compared to prepubertal cats (Table 1). The number of corpora lutea in the luteal cats was significantly higher ($P \leq 0.05$) compared to pre-pubertal cats and adult cats at their follicular and inactive stages of the estrous cycle (Table 1).

The endometrial gland diameter of the prepubertal cats was significantly lower ($P \leq 0.05$) compared to the adult female cats in follicular and luteal stage. Moreover, the epithelium of endometrial glands in the prepubertal and inactive adult cats was composed of a single layer of cuboidal cells while the epithelium of the endometrial glands in the follicular and luteal adult cats was composed of a single layer of

columnar cells with abundant secretion in the glands. Significantly higher ($P \leq 0.05$) thickness (μm) of myometrial layer of the uterine horn was also found in the adult cats at follicular and luteal phase (733.57 ± 153.29 and 705.36 ± 142.90 , respectively) compared to the prepubertal cats (392.27 ± 56.80).

LHR and FSH protein and mRNA Expression

Protein expression of LHR was observed in the cytoplasm of theca cells, interstitium of the ovarian tissue and granulosa cells of large antral follicles only, whereas the FSHR protein expression was found in the granulosa cells of antral follicles only. No differences were recorded in the ovarian expression of FSHR mRNA, LHR protein or mRNA between the prepubertal and adult cats, but significantly lower FSHR protein expression was found in prepubertal cats compared to adult luteal cats (Figures 1 and 2).

Discussion

The main objective of this study was to evaluate and compare the ovarian and uterine characteristics along with the ovarian mRNA and protein expression of LHR and FSHR between the prepubertal and adult female cats. In this study we found that prepubertal cats had significantly lower ovarian weight compared to the adult cats at follicular and luteal phase, which may simply reflect an incomplete development of the ovaries in the prepubertal cats. Understandably though, the highest number of antral follicles was observed in the prepubertal cats that may be due to an absence of ovulation in this group. The higher number of CL in the adult luteal cats is probably no more than a reflection of the stage of the estrous cycle when tissues were collected.

Epithelium of the endometrial gland in prepubertal cats was presented with a single layer of cuboidal cells while in adult cats at follicular and luteal phases it was presented with a single layer of columnar epithelium with abundant of secretion in the glands. The columnar epithelium and the secretion in the gland show that there is an indication of a higher activity of the epithelial cells in these cats. The significantly higher value of myometrial thickness in the adult cats in active stages of their estrous cycle (follicular and luteal phase) compared with prepubertal cats also confirms that their reproductive tract in the adult cats are more active/mature compared to the prepubertal cats.

FSH takes part in stimulating the development of ovarian follicles (Misrahi et al. 1998) and the higher expression of FSHR expression observed in the adult luteal cats may represent a higher rate of follicular development in these cats compared to the prepubertal cats. Moreover, expression of FSHR is related to the diameter of the follicles (Saint-Dizier et al. 2007). However, we did not measure the diameter of the follicles, so it remains unclear whether this is the case in our study. Nevertheless, lower FSHR protein expression observed in prepubertal cats than the adult luteal cats while may represent an overall higher activity of FSHR during the luteal phase and not a fully functional FSH-FSHR axis in the prepubertal cats, it is not clear from the results of this study which part of ovarian tissues (follicles, corpus luteum or interstitium) was responsible for this increased expression.

In conclusion, no differences were observed in the ovarian protein or mRNA expression of gonadotropin receptors between the prepubertal and adult cats except that lower FSHR protein expression was observed in prepubertal cats compared to the adult cats at their luteal stage of the estrous cycle. Moreover, higher values for the

uterine gland diameter and myometrial thickness in adult cats suggest an active/mature uterine function in adult compared to prepubertal cats.

Acknowledgements

This study was supported by the Royal Golden Jubilee PhD program, the 90th anniversary of Chulalongkorn University (Ratchadaphiseksomphot Endowment Fund) and the Research Unit of Obstetric and Reproduction in animals of Chulalongkorn University, Bangkok, Thailand. The authors are thankful to Dr Zhangrui Cheng for laboratory assistance and Dr Em-on Olanratmanee for help in statistical analysis of the data.

Table legend

Table 1. Mean \pm SEM numbers of structures (follicles and corpora lutea) per mm² of ovarian tissue in adult (follicular, luteal and inactive) (n = 6/stage) and pre-pubertal (n = 6) female cats

Groups	Numbers (SEM)/mm ² of ovarian tissue				
	Primordial follicle	Primary follicles	Secondary follicles	Antral follicles	Corpora lutea
Adult (Follicular)	234.33 \pm 45.12 ^a	16.33 \pm 5.04 ^a	8.67 \pm 2.04 ^a	8.33 \pm 1.09 ^{ab}	0.67 \pm 0.67 ^a
Adult (Luteal)	204.67 \pm 30.14 ^a	10.33 \pm 2.39 ^a	4.00 \pm 1.03 ^b	4.67 \pm 0.42 ^a	1.46 \pm 0.99 ^b
Adult (Inactive)	249.00 \pm 57.50 ^a	11.33 \pm 2.91 ^a	6.33 \pm 1.67 ^{ab}	6.67 \pm 1.98 ^{ab}	0.00 \pm 0.00 ^a
Pre-pubertal	344.67 \pm 64.63 ^a	25.33 \pm 5.28 ^a	9 \pm 3.61 ^{ab}	9.00 \pm 1.69 ^b	0.00 \pm 0.00 ^a

Values with different superscripts within a column differ significantly (p < .05).

Figure legend

Figure 1. The mean (\pm SEM) level of protein expression for the ovarian LHR and FSHR in pre - pubertal cats and adult cats at inactive, follicular and luteal phase (n = 6/phase) of their oestrous cycle. Different letters on bars for a certain receptor indicate significant ($p \leq .05$) differences.

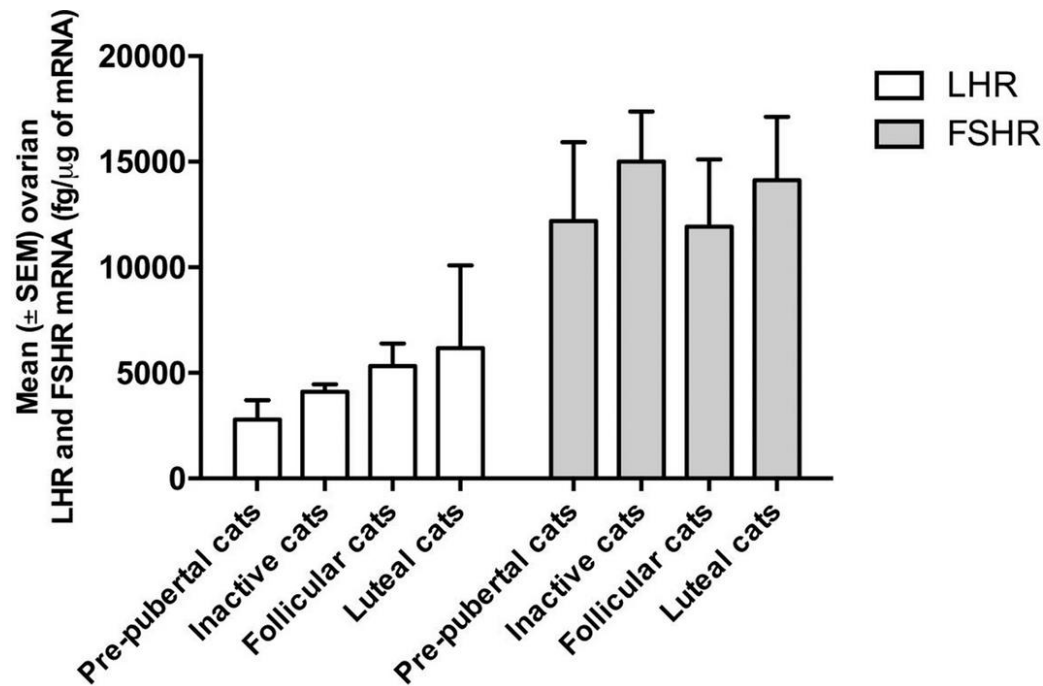
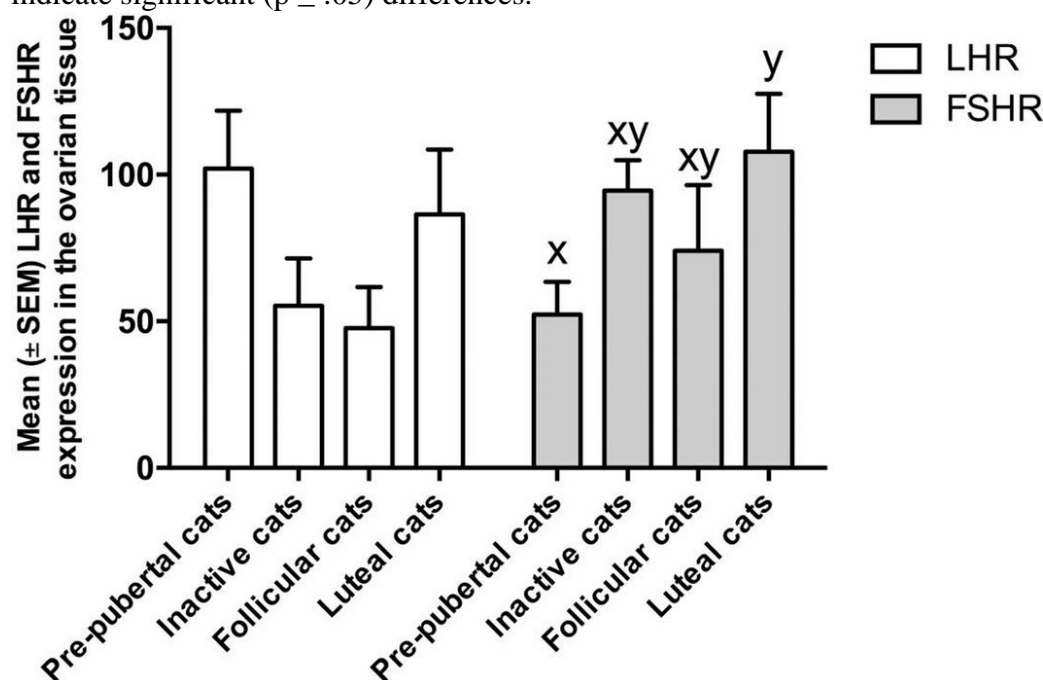


Figure 2. The mean (\pm SEM) mRNA (fg/μg of RNA) for the ovarian LHR and FSHR in pre - pubertal cats and adult cats at inactive, follicular and luteal phase (n = 6/phase) of their oestrous cycle. Different letters on bars for a certain receptor indicate significant ($p \leq .05$) differences.



References

- Chowdhury M. W. H.; Scaramuzzi R. J.; Wheeler-Jones C. P. D.; Khalid M., 2010: The expression of angiogenic growth factors and their receptors in ovarian follicle throughout the estrous cycle in the ewe. *Theriogenology*, 73 856 - 872.
- Ishibashi H.; Suzuki T.; Suzuki S.; Moriya T.; Kaneko C.; Takizawa T.; Sunamori M.; Handa M.; Kondo T.; Sasano H., 2003: Sex steroid hormone receptors in human thymoma. *J. Clin. Endocrinol. Metab.*, 88 2309-2317.
- Johnston S. D.; Root Kustritz M. V.; Olson P. N. S., 2001: The feline estrous cycle. *Canine and Feline Theriogenology*, 1 edn. Saunders Elsevier, Philadelphia, PA 19106, pp. 396-405.
- Mehl N. S.; Khalid M.; Srisuwatanasagul S.; Swangchan-Uthai T.; Sirivaidyapong S., 2016: GnRH-agonist implantation of prepubertal male cats affects their reproductive performance and testicular LH receptor and FSH receptor expression. *Theriogenology*, 85 841-848.
- Misrahi M.; Beau I.; Meduri G.; Bouvattier C.; Atger M.; Loosfelt H.; Ghinea N.; Hai M. V.; Bougneres P. F.; Milgrom E., 1998: Gonadotropin receptors and the control of gonadal steroidogenesis: physiology and pathology. *Baillieres Clin. Endocrinol. Metab.*, 12 35-66.
- Ponglowhapan S.; Church D. B.; Khalid M., 2008: Differences in the expression of luteinizing hormone and follicle-stimulating hormone receptors in the lower urinary tract between intact and gonadectomised male and female dogs. *Domest. Anim. Endocrinol.*, 34 339-351.
- Saint-Dizier M.; Malandain E.; Thoumire S.; Remy B.; Chastant-Maillard S., 2007: Expression of follicle stimulating hormone and luteinizing hormone receptors during follicular growth in the domestic cat ovary. *Mol. Reprod. Dev.*, 74 989-996.