

Twin pregnancy in a liver transplant recipient with HIV infection

MCI Van Schalkwyk¹, RH Westbrook², J O'Beirne², A Wright³, A Gonzalez³, MA Johnson¹ and S Kinloch-de Loës^{1*}

¹ Division of Infection and Immunity

² Department of Hepatology

³ Department of Obstetrics, Royal Free Hospital, London, UK

Abstract

We are not aware of a report detailing the complex obstetrical and medical management of twin pregnancy in the context of HIV infection and early post-liver transplantation period. Here we describe the successful outcome of a twin pregnancy in a 28-year-old HIV-positive female receiving antiretroviral therapy and immunosuppressive therapy who was the recipient of a liver transplant for previous drug-induced liver failure.

Keywords: pregnancy, HIV, liver transplantation, twin, liver function tests

Introduction

Liver and kidney transplantations are now more commonly performed in the HIV patient population [1,2]. There is evidence from centres in the US and Europe to suggest that the 1–5-year survival following liver transplantation in those infected with HIV is comparable to HIV-seronegative individuals [3,4]. As the number of individuals living with long-term HIV infection continues to rise, the need for transplantation may be expected to increase in both male and female patients [5–7]. Currently, there is limited information in the literature on pregnancy outcome in the setting of liver transplantation and HIV infection [8].

Case report

A 28-year-old Zimbabwean-born female was originally diagnosed with HIV infection in 2003 at 32 weeks of her first pregnancy. She was commenced on antiretrovirals (ART) at this time with a protease inhibitor-based regimen, and gave birth to an uninfected infant. Treatment for HIV infection was discontinued after pregnancy as she had a preserved CD4 T cell count. In January 2012 treatment was re-started with a single-tablet combination of tenofovir, emtricitabine and efavirenz. In July she was admitted to her local hospital with deranged liver function tests (LFTs) on a background of a 1-month history of jaundice and dark urine, at which stage ART was discontinued.

She was subsequently transferred to the Liver Unit at the Royal Free Hospital, London in August 2012 for her ongoing management. At the time of the transfer her LFTs were abnormal and INR was at 4.2 (range: 0.9–1.2). Despite medical management, her liver dysfunction progressed and she developed grade 3 hepatic encephalopathy (Figure 1). The assumed diagnosis was acute liver injury secondary to efavirenz. She met the King's College non-acetaminophen poor prognostic criteria, and was super-urgently listed for, and subsequently underwent, liver transplantation (LT). Histology was consistent with fulminant hepatitis with bridging and extensive confluent necrosis, ductular reaction and mixed inflammation. There was massive architectural collapse with moderate hepatocellular and canalicular cholestasis. No viral inclusions or ground-glass cells could be seen and special stains did not reveal significant background fibrosis or cirrhosis. At the time of transplantation her HIV viral load was <40 copies/mL with a CD4 T cell count of 173 cells/mm³, which had decreased acutely during this period (Figure 2A, B). She had an uneventful post-LT recovery and was discharged 3 weeks later on tenofovir 245 mg daily, emtricitabine 200 mg daily and raltegravir 400 mg twice daily

for HIV control, and tacrolimus, azathioprine and prednisolone as immunosuppressive therapy [9].

The patient conceived naturally at 7 months post-LT. At this time, she had normal LFTs, an undetectable HIV viral load and preserved CD4 T cell count (Figures 1, 2). A dichorionic, diamniotic twin pregnancy was diagnosed by ultrasound (US) scan and her care was facilitated via a multidisciplinary team including HIV physicians, obstetricians, midwives and hepatologists at the Royal Free Hospital, London. At approximately 8 weeks' gestation (April 2013) elevated serum aminotransferases were noted (Figure 1) and the patient was admitted for further investigations. An acute hepatitis viral screen was negative. On admission (9 May 2013) her tacrolimus level was 4.5 µg/mL (range: 5–15) but normal on discharge (10 May 2013) at 5.5 µg/mL. There was no change made to her tacrolimus dose. A liver US scan revealed patent hepatic vasculature with no evidence of biliary dilatation. A liver biopsy taken at the end of the first trimester revealed normal hepatic architecture with a mild, predominantly lymphoplasmocytic inflammatory infiltrate in a few portal tracts along with scattered eosinophils. There was no bile duct damage or endotheliitis. These findings were consistent with mild hepatitic features, the cause of which was not evident morphologically. There were no diagnostic features of acute cellular rejection (ACR). The tacrolimus level was at 4.8 µg/mL on 29 May 2013 and 3.7 µg/mL on 31 May 2013 during her admission. Liver enzymes remained elevated from the 10th until the 20th week of pregnancy, at which time they normalised (Figure 1).

At 27 weeks' gestation the patient developed acute kidney injury with an increased creatinine (maximum level of 166 µmol/L), which resolved spontaneously by 30 weeks, after hospital admission. She was reviewed by the Renal team and no identifiable cause was found. Serum creatinine increased again at 34 weeks' gestation, with a concomitant rise in blood pressure. The patient was closely monitored at this stage for pre-eclampsia and underwent a semi-emergency Caesarean section at 35 weeks' gestation under general anaesthetic, in view of her rising blood pressure and deteriorating renal function. Steroids were administered at the end of pregnancy to avoid respiratory distress of the newborns. The patient delivered two healthy HIV-negative infants with no evidence of compromise to the mother in terms of the control of her HIV infection or liver graft function (Figures 1, 2). The newborns had good birth weights (Twin 1 of 2110 grams and Twin 2 of 2032 grams) and were admitted into the neonatal unit at birth and discharged after 3 weeks.

The mother remained on the same ART regimen and immunosuppressive therapy post-delivery. Of note, close monitoring of tacrolimus levels and liver and renal function had been required at regular intervals throughout her pregnancy. The

*Corresponding author: Sabine Kinloch-de Loës, Division of Infection and Immunity, Royal Free Hospital, London NW3 2QG, UK
Email: sabine.kinloch@nhs.net

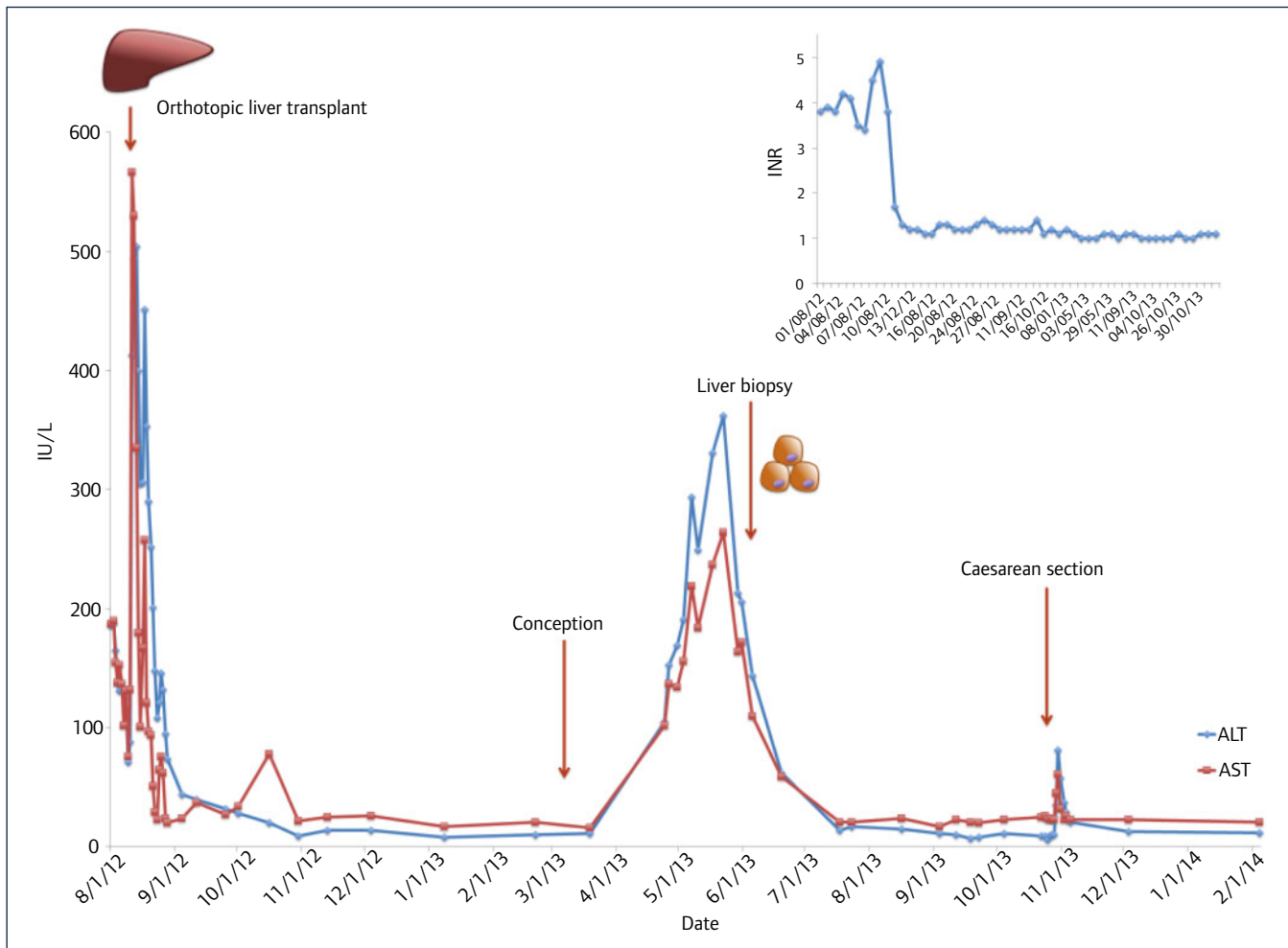


Figure 1. Liver enzymes (LFTs) and function (INR) measured over the timeline of patient management: Aspartate aminotransferase (AST) and alanine aminotransferase (ALT) were measured during times of patient admission and in the outpatient setting. Marked derangement in LFTs and INR was observed at the time of liver transplantation. At conception, LFTs and INR were normal. During the first trimester a rise in LFTs was present although INR remained normal throughout pregnancy. A liver biopsy was performed during the period of LFTs derangement. Caesarean section was performed at gestational age of 35 weeks+0 days

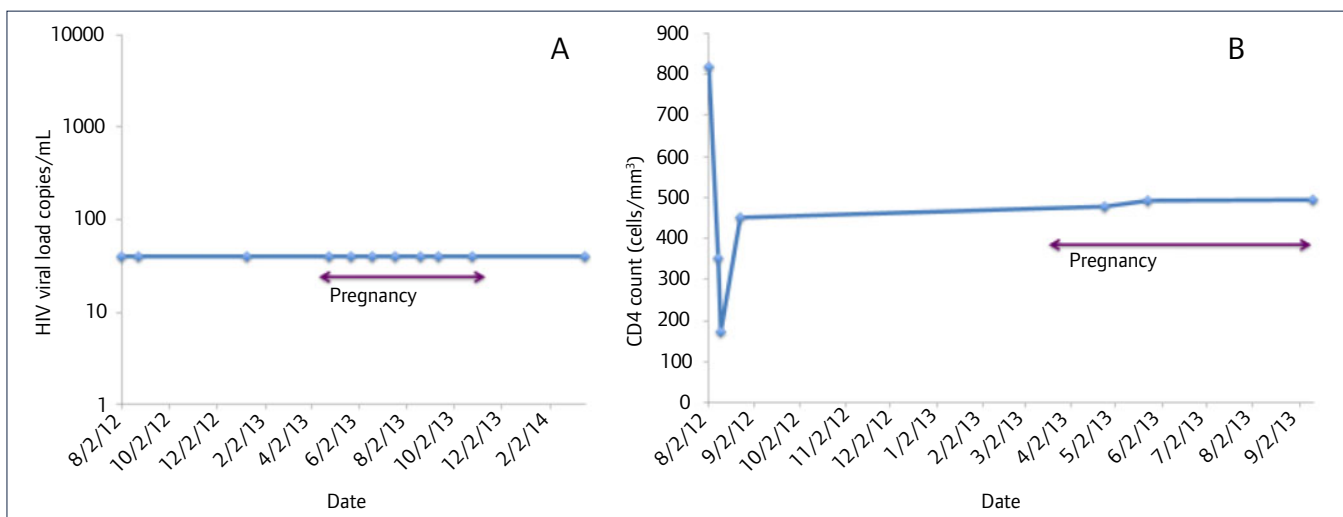


Figure 2. HIV viral load and CD4 cell count measured over the timeline of patient management: HIV viral load (A) and CD4 count (B) were monitored periodically from the time of patient transfer. The patient’s HIV infection remained well controlled throughout pregnancy

tacrolimus dose required reduction post-delivery and the patient was discharged on 4 mg twice daily and azathioprine.

Discussion

We report on the successful outcome of a twin pregnancy in an HIV-positive patient on antiretroviral and immunosuppressive

therapy (tacrolimus and azathioprine) with a history of recent liver transplantation for acute liver failure secondary to ART drug toxicity. The complexity of the management of such a case was highlighted by the involvement of several specialist teams within the same hospital, such as HIV physicians, transplant surgeons, liver specialists and HIV-dedicated obstetricians and midwives. Although there was an overall positive outcome for both the

mother and babies, the patient required intensive monitoring, particularly with regards to the control of her HIV infection, liver transplant and renal function. She required multiple admissions for deranged LFTs resulting in a liver biopsy to exclude an acute rejection episode and monitor her renal function and blood pressure in the later stages of pregnancy. A semi-urgent Caesarean section was performed for the management of hypertension and deteriorating renal function.

Previous studies have confirmed the complex management and risks associated with pregnancy in LT recipients [10–13]. Although a successful outcome for the mother, baby and graft can be expected in the majority of cases, with a reported live birth rate of up to 80%, there remain concerns regarding an increased risk of ACR, maternal infections, gestational diabetes, renal impairment and pre-eclampsia. In terms of the fetus there is a risk of prematurity (30%) and intra-uterine growth restriction [10,13]. It is now widely accepted amongst LT physicians that pregnancy post-LT should be delayed for 12 months. This is due to increasing data showing that pregnancies within 12 months of LT are associated with a significant and prohibitive increased risk of ACR [10]. Whilst most ACR cases in conjunction with pregnancy can be controlled with augmentation of baseline immunosuppression, graft loss and the need for re-transplantation have been reported [10,13,14].

The experience in managing the case described here is consistent with findings of these studies in that a decline in both liver and renal functions was observed and required a liver biopsy and semi-emergency Caesarean section, respectively. Of note, a good birth weight was observed for the twin newborns and both the mother and infants remain well to date. Furthermore, the findings of Westbrook *et al.* and other case series [10] note that therapy with calcineurin inhibitors is safe in pregnancy and should be continued, as was the case with our experience in this patient.

Due to the risk of multiple complications in solid organ recipients when pregnant, a multidisciplinary approach remains pivotal in order to prevent or manage such cases, in terms of antiretroviral therapy, immunosuppression, graft function and antenatal care.

The timing of a liver biopsy and the management of the patient during the period of increasing LFTs in the first trimester of pregnancy required regular interactions between multiple specialist teams, including for the decision to delay biopsy until the second trimester. However, there are no data to suggest that a liver biopsy is harmful in pregnancy via the ultrasound-guided route.

Most series of LT in HIV infection involve patients who are co-infected with hepatitis B or C [2,7]. This is due to the increased risk of co-infected HIV patients developing decompensated chronic liver disease. Liver transplantation for HIV in isolation is a relatively

rare phenomenon, with the indication being acute liver failure secondary to an idiosyncratic drug reaction to HIV therapy [6,7,15]

To conclude, this case report highlights the fact that pregnancy post LT is a realistic option for women who are infected with HIV. It clearly stresses the importance of adopting a multidisciplinary approach for all aspects of patient care throughout pregnancy and regular monitoring of maternal and fetal progress. This transplant recipient remained clinically stable with a favourable outcome for a twin pregnancy. The patient was successfully managed through episodes of increased LFTs with liver biopsy as well as blood pressure increase with deteriorating renal function consistent with pre-eclampsia, leading to a semi-urgent Caesarean section which resulted in the birth of two healthy HIV-negative infants of preserved birth weight. There was no evidence of compromise to the control of the patient's HIV infection or of graft rejection.

References

1. Roland ME, Stock PG. Solid organ transplantation is a reality for patients with HIV infection. *Curr HIV/AIDS Rep* 2006; **3**: 132–138.
2. Locke JE, Durand C, Reed RD *et al.* Long-term outcomes after liver transplantation among human immunodeficiency virus-infected recipients. *Transplantation* 2016; **100**: 141–146.
3. Cooper C, Kanters S, Klein M *et al.* Liver transplant outcomes in HIV-infected patients: a systematic review and meta-analysis with synthetic cohort. *AIDS* 2011; **25**: 777–786.
4. Aguerro F, Forner A, Manzano C *et al.*; FIPSE Investigators. Human immunodeficiency virus infection does not worsen prognosis of liver transplantation for hepatocellular carcinoma. *Hepatology* 2016; **63**: 488–498.
5. Sherman KE, Rockstroh J, Thomas D. Human immunodeficiency virus and liver disease: An update. *Hepatology* 2015; **62**: 1871–1882.
6. Joshi D, Agarwal K. Role of liver transplantation in human immunodeficiency virus positive patients. *World J Gastroenterol* 2015; **21**: 12311–12321.
7. Roland ME, Barin B, Huprikar S *et al.*; HIVTR Study Team. Survival in HIV-positive transplant recipients compared with transplant candidates and with HIV-negative controls. *AIDS* 2016; **30**: 435–444.
8. Moreno A, Quereda C, Bärceña R; Ramón y Cajal-La Paz Liver Transplant Group. Successful pregnancy after orthotopic liver transplantation in a patient with HIV infection. *N Engl J Med* 2005; **353**: 2517–2518.
9. Tricot L, Teicher E, Peytavin G *et al.* Safety and efficacy of raltegravir in HIV-infected transplant patients cotreated with immunosuppressive drugs. *Am J Transplant* 2009; **9**: 1946–1952.
10. Westbrook RH, Yeoman AD, Agarwal K *et al.* Outcomes of pregnancy following liver transplantation: The King's College Hospital experience. *Liver Transpl* 2015; **21**: 1153–1159.
11. Westbrook RH, Dusheiko G, Williamson C. Pregnancy and liver disease. *J Hepatol* 2016; **64**: 933–945.
12. Margioulas-Siarkou C, Kalogiannidis I, Petousis S *et al.* Pregnancy after liver transplantation. How safe? A retrospective case-series study in a large tertiary hospital. *J Matern Fetal Neonatal Med* 2016; **29**: 2120–2124.
13. Kubo S, Uemoto S, Furukawa H, Umeshita K, Tachibana D; Japanese Liver Transplantation Society. Pregnancy outcomes after living donor liver transplantation: results from a Japanese survey. *Liver Transpl* 2014; **20**: 576–583.
14. Radomski JS, Moritz MJ, Munoz SJ, Cater JR, Jarrell BE, Armenti VT. National transplantation pregnancy registry: analysis of pregnancy outcomes in female liver transplant recipients. *Liver Transpl Surg* 1995; **1**: 281–284.
15. Sonderup MW, Maughan D, Gogela N *et al.* Identification of a novel and severe pattern of efavirenz drug-induced liver injury in South Africa. *AIDS* 2016; **30**: 1483–1485.