

Gain of 12p encompassing CCND2 is associated with gemistocytic histology in IDH mutant astrocytomas

Felix Sahn^{1,2}, Andrey Korshunov², Daniel Schrimpf^{1,2}, Damian Stichel^{1,2}, David T.W. Jones³, David Capper^{1,2}, Christian Koelsche^{1,2}, David Reuss^{1,2}, Annkathrin Kratz^{1,2}, Kristin Huang^{1,2}, Annika K. Wefers^{1,2}, Matthias Schick⁴, Melanie Bewerunge-Hudler⁴, Michel Mittelbronn⁵, Michael Platten^{6,7,8}, Daniel Hänggi⁹, Astrid Jeibmann¹⁰, Andreas Unterberg¹¹, Christel Herold-Mende¹¹, Stefan M. Pfister^{3,12}, Sebastian Brandner¹³, Wolfgang Wick^{6,14}, Andreas von Deimling^{1,2}

1. Department of Neuropathology, Institute of Pathology, Ruprecht-Karls-University Heidelberg, Heidelberg, Germany,
2. Clinical Cooperation Unit Neuropathology, German Consortium for Translational Cancer Research (DKTK), German Cancer Research Center (DKFZ), Heidelberg, Germany
3. Division of Pediatric Neurooncology, German Consortium for Translational Cancer Research (DKTK), German Cancer Research Center (DKFZ), Heidelberg, Germany
4. Genomics and Proteomics Core Facility, Microarray Unit, German Cancer Research Center (DKFZ), Heidelberg, Germany
5. Department of Neuropathology (Edinger Institute), University Hospital Frankfurt, Frankfurt, Germany
6. Neurology Clinic, University Hospital Heidelberg, Heidelberg, Germany
7. Clinical Cooperation Unit Neuroimmunology and Brain Tumor Immunology, German Consortium for Translational Cancer Research (DKTK), German Cancer Research Center (DKFZ), Heidelberg, Germany
8. Neurology Clinic, University Hospital Mannheim, Mannheim, Germany
9. Department of Neurosurgery, University Hospital Mannheim, Mannheim, Germany
10. Institute of Neuropathology, University Hospital Münster, Münster, Germany
11. Department of Neurosurgery, University Hospital Heidelberg, Heidelberg, Germany
12. Department of Pediatric Oncology, Haematology and Immunology, Heidelberg University Hospital, and National Center for Tumor Diseases (NCT), Heidelberg, Germany
13. Division of Neuropathology of the UCL Institute of Neurology in London, London, UK
14. Clinical Cooperation Unit Neurooncology, German Consortium for Translational Cancer Research (DKTK), German Cancer Research Center (DKFZ), Heidelberg, Germany

Gemistocytic astrocytoma represents a small subgroup accounting for approximately 5% of diffuse astrocytic glioma. The WHO classification defines gemistocytic astrocytoma by presence of “a conspicuous, though variable, fraction of gemistocytic neoplastic astrocytes” [5]. These cells should account for at least 20% of the tumor cells. The term “gemistocytic” was coined by Nissl in 1904 for cells with homogeneous, faintly eosinophilic cytoplasm with short branching processes. It originates from the German word “gemästet” (filled, stuffed, swollen), sometimes also referred back to the Greek “gemistos” with similar meaning.

The neoplastic nature of gemistocytic cells in astrocytoma could be clearly demonstrated by binding of an IDH1R132H mutant protein specific antibody [1]. However, so far no molecular drivers characteristic for this gemistocytic differentiation have been identified. Previous molecular analyses reported higher frequencies of *TP53* and *PTEN* mutations [14], lower frequency of *IDH* mutations, and alterations in *RRAS* and *ERCC1* [7]. Several studies found shorter progression-free-survival in gemistocytic astrocytoma cases compared to fibrillary astrocytoma [4,8-10], whilst others did not confirm this finding [a reference should be given here].. However, there appears to be a contradiction between the accelerated progression and lower proliferative activity of gemistocytes compared to other tumor cells in the same sample, or in general in diffuse glioma [2-4,15].

To identify potentially recurrent alterations associated with gemistocytic morphology in astrocytoma we performed high-throughput high-resolution genetic and epigenetic analysis on a set of 24 gemistocytic astrocytomas. The control group consisted of 47 *IDH* mutant astrocytomas WHO grade II, 104 *IDH* mutant anaplastic astrocytomas WHO grade III, and 293 *IDH* wild-type glioblastomas WHO grade IV.

The Illumina Infinium HumanMethylation450 BeadChip (450k) array data was used for methylation profiling and to calculate a low-resolution copy number profile (CNP) as previously described [12].

Targeted re-sequencing was performed on the genes and with the technology as reported previously [11].

A distinctive feature of tumours with gemistocytic histology was a recurrent numerical aberration in the telomeric region of chromosomal arm 12p, encompassing *CCND2* (Figure 1A). An integrated analysis of copy-number variation (Stichel et al., in preparation) in all gemistocytic astrocytoma of our cohort also indicated 12p as the most consistently altered locus (Figure 1B).

In particular, focal gain of *CCND2* and adjacent regions was seen in 8 of 9 gemistocytic astrocytomas WHO grade II and in 13 of 15 anaplastic astrocytomas with distinct gemistocytic morphology (Table 1). Instead, this alteration was observed in only 5 of 47 fibrillary astrocytomas WHO grade II and in only 19 of 104 anaplastic astrocytomas lacking gemistocytic morphology. The alterations detected by analysis of copy number plots based on 450K analysis were confirmed by FISH in a subset of 18 cases (11 gemistocytic cases, 7 fibrillary cases), yielding concordance in 17 out of 18 (94%) cases (Figure 1B). The single non-concordant case was an anaplastic gemistocytic astrocytoma without indications of chromosome 12 gain by 450k but low-level gain detected by FISH probe directed against 12p12 encompassing *CCND2*.

This difference was highly significant within grade II and grade III gliomas, respectively (each $p < 0.0001$, Fisher's exact test). Also, the event of 12p/*CCND2* gain was significantly associated with gemistocytic histology over the entire diffuse astrocytic glioma cohort ($p < 0.0001$, Table 1).

Unsupervised clustering of methylome profiles from gemistocytic and fibrillary astrocytoma did not separate these from each other (data not shown).

To assess the mutational landscape of gemistocytic astrocytoma, 17 tumours were further analysed by panel sequencing. All cases harboured IDH1R132 mutations (16/17 IDH1R132H, 1/17 IDH1R132G) and *TP53* mutations. Other recurrently mutant genes were *ATRX* (10/17), *ALK* (2/17), *CSF1R* (2/17), *FGFR1* (2/17), *GSE1* (2/17), *MSH6* (2/17), *NF1* (2/17), and *SMO* (2/17, not affecting the activating hot-spots). These findings are in line with studies describing high rates of TP53 mutations in gemistocytic astrocytomas, but contrasts reports on high frequencies of *PTEN* mutations of which none was found in the present set.

Recent reports suggested aberrations of copy number and methylation of *ERCC1* and *RRAS* as a possible marker for gemistocytic astrocytoma [7]. However, we could not detect these aberrations in our dataset (mean beta values for *ERCC1* promoter sites 0.09 and 0.1, for *RRAS* promoter sites 0.08 and 0.09, in gemistocytic and control samples, respectively).

Upregulation of *CCND2* due to higher copy abundance also provides an explanation for several prior observations on this sub-entity: *CCND2* is physiologically upregulated in radial glial cells of the subventricular zone during brain development, and activating *CCND2* mutations result in megalencephaly whilst abrogation of *CCND2* leads to microcephaly [6]. The higher abundance of *CCND2* protein might also disrupt the regular cell cycle, preventing the transition from S to G2 phase, and explain lower mitotic activity but higher pleomorphism with higher number of multi-nucleated cells in such cases. Moreover, the recent approval of inhibitors of the CDK4/6 axis [13], both interacting with *CCND2*, also opens an additional therapeutic approach for this glioma subtype.

Table 1 Subtypes of diffuse glioma and 12p status

Subtype	12p gain	12p balanced/del
<i>all All (56)</i>	13 (23%)	43 (77%)
<i>All gem (9)</i>	8 (89%)	1 (11%)
<i>All non-gem (47)</i>	5 (11%)	42 (89%)
<i>all AIII (119)</i>	29 (24%)	90 (76%)
<i>AIII gem (15)</i>	13 (87%)	2 (13%)
<i>AIII non-gem (104)</i>	19 (18%)	85 (82%)
<i>all GBM (293)</i>	32 (11%)	261 (89%)

Figure 1

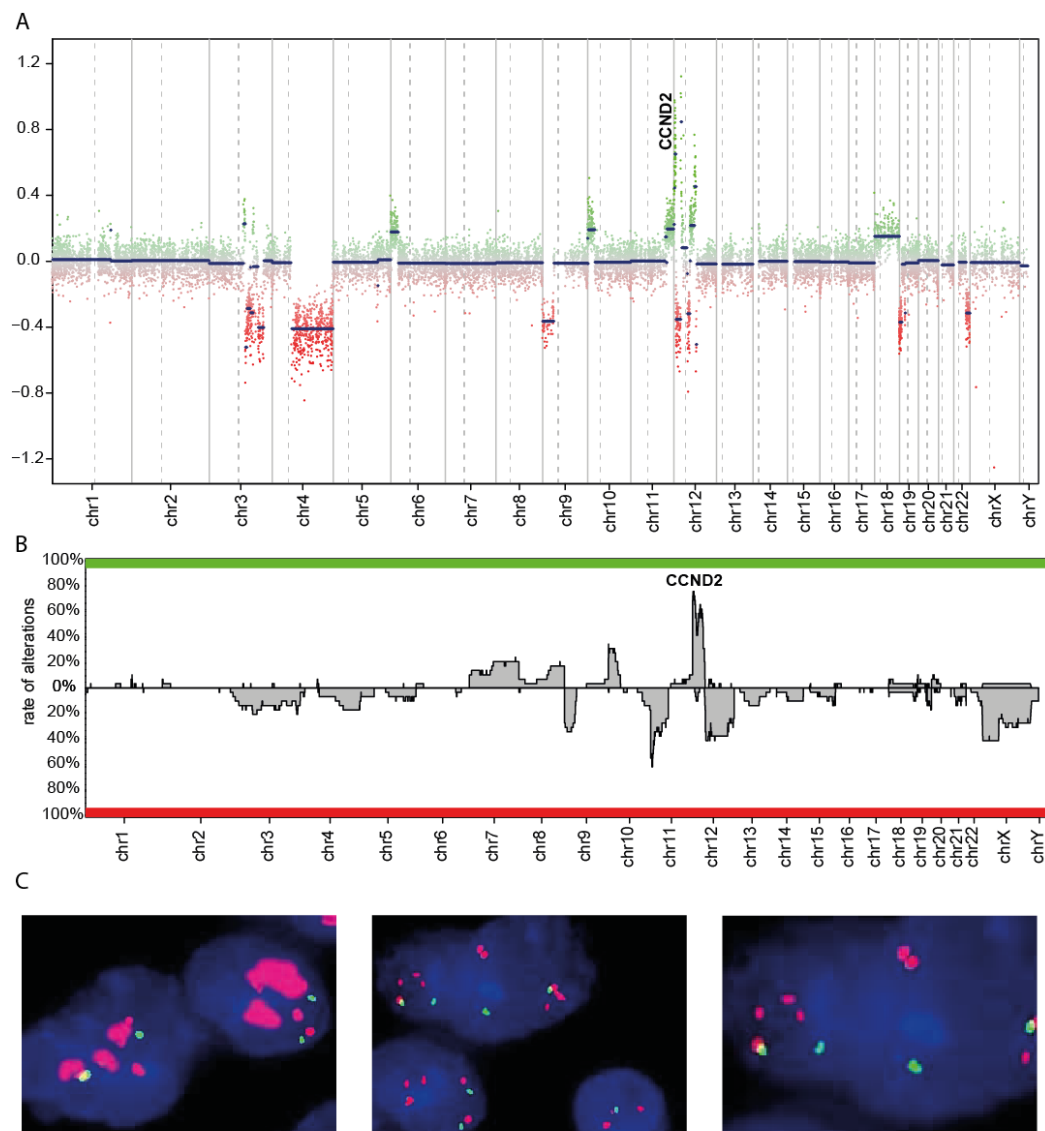


Figure 1 Representative copy-number profile of a gemistocytic astrocytoma (A). Integrated copy-number analysis across all gemistocytic astrocytoma (B). Fluorescence in-situ hybridization of a case with amplification (left) and low-level gain of CCND2 (middle, higher magnification right).

References

- 1 Capper D, Sahm F, Hartmann C, Meyermann R, von Deimling A, Schittenhelm J (2010) Application of mutant IDH1 antibody to differentiate diffuse glioma from nonneoplastic central nervous system lesions and therapy-induced changes. *The American journal of surgical pathology* 34: 1199-1204
- 2 Hoshino T, Wilson BC, Ellis WG (1975) Gemistocytic astrocytes in gliomas. An autoradiographic study. *Journal of neuropathology and experimental neurology* 34: 263-281
- 3 Kros JM, Schouten WC, Janssen PJ, van der Kwast TH (1996) Proliferation of gemistocytic cells and glial fibrillary acidic protein (GFAP)-positive oligodendroglial cells in gliomas: a MIB-1/GFAP double labeling study. *Acta Neuropathol* 91: 99-103
- 4 Krouwer HG, Davis RL, Silver P, Prados M (1991) Gemistocytic astrocytomas: a reappraisal. *Journal of neurosurgery* 74: 399-406
- 5 Louis DN, Perry A, Reifenberger G et al. (2016) The 2016 World Health Organization Classification of Tumors of the Central Nervous System: a summary. *Acta Neuropathol* 131: 803-820
- 6 Mirzaa GM, Parry DA, Fry AE et al. (2014) De novo CCND2 mutations leading to stabilization of cyclin D2 cause megalencephaly-polymicrogyria-polydactyly-hydrocephalus syndrome. *Nature genetics* 46: 510-515
- 7 Ohta T, Kim YH, Oh JE et al. (2014) Alterations of the RRAS and ERCC1 genes at 19q13 in gemistocytic astrocytomas. *Journal of neuropathology and experimental neurology* 73: 908-915
- 8 Okamoto Y, Di Patre PL, Burkhardt C et al. (2004) Population-based study on incidence, survival rates, and genetic alterations of low-grade diffuse astrocytomas and oligodendrogliomas. *Acta Neuropathol* 108: 49-56
- 9 Peraud A, Ansari H, Bise K, Reulen HJ (1998) Clinical outcome of supratentorial astrocytoma WHO grade II. *Acta Neurochir (Wien)* 140: 1213-1222
- 10 Peraud A, Kreth FW, Wiestler OD, Kleihues P, Reulen HJ (2002) Prognostic impact of TP53 mutations and P53 protein overexpression in supratentorial WHO grade II astrocytomas and oligoastrocytomas. *Clinical cancer research : an official journal of the American Association for Cancer Research* 8: 1117-1124
- 11 Sahm F, Schrimpf D, Jones DT et al. (2015) Next-generation sequencing in routine brain tumor diagnostics enables an integrated diagnosis and identifies actionable targets. *Acta Neuropathol*:
- 12 Sturm D, Witt H, Hovestadt V et al. (2012) Hotspot mutations in H3F3A and IDH1 define distinct epigenetic and biological subgroups of glioblastoma. *Cancer cell* 22: 425-437
- 13 Walker AJ, Wedam S, Amiri-Kordestani L et al. (2016) FDA Approval of Palbociclib in Combination with Fulvestrant for the Treatment of Hormone Receptor-Positive, HER2-Negative Metastatic Breast Cancer. *Clinical cancer research : an official journal of the American Association for Cancer Research* 22: 4968-4972
- 14 Watanabe K, Peraud A, Gratas C, Wakai S, Kleihues P, Ohgaki H (1998) p53 and PTEN gene mutations in gemistocytic astrocytomas. *Acta Neuropathol* 95: 559-564
- 15 Watanabe K, Tachibana O, Yonekawa Y, Kleihues P, Ohgaki H (1997) Role of gemistocytes in astrocytoma progression. *Lab Invest* 76: 277-284