



1983

## An Investigation Into the Cellular and Humoral Organization of the Thymic Microenvironment

Howard R. Higley  
*Loyola University Chicago*

Follow this and additional works at: [https://ecommons.luc.edu/luc\\_diss](https://ecommons.luc.edu/luc_diss)

 Part of the [Anatomy Commons](#)

---

### Recommended Citation

Higley, Howard R., "An Investigation Into the Cellular and Humoral Organization of the Thymic Microenvironment" (1983). *Dissertations*. 2163.  
[https://ecommons.luc.edu/luc\\_diss/2163](https://ecommons.luc.edu/luc_diss/2163)

This Dissertation is brought to you for free and open access by the Theses and Dissertations at Loyola eCommons. It has been accepted for inclusion in Dissertations by an authorized administrator of Loyola eCommons. For more information, please contact [ecommons@luc.edu](mailto:ecommons@luc.edu).



This work is licensed under a [Creative Commons Attribution-Noncommercial-No Derivative Works 3.0 License](#).  
Copyright © 1983 Howard R. Higley

204

AN INVESTIGATION INTO THE CELLULAR AND HUMORAL ORGANIZATION  
OF THE THYMIC MICROENVIRONMENT.

by

HOWARD R. HIGLEY  
DOCTOR OF PHILOSOPHY

A Submitted to the Faculty of the Graduate  
School of Loyola University of Chicago in Partial  
Fulfillment of the Requirements for the Degree of

January

1983

LIBRARY  
LOYOLA UNIVERSITY MEDICAL CENTER

## ACKNOWLEDGMENTS

I would like to thank my dissertation advisor Dr. C. C. C. O'Morchoe for his efforts in the preparation of this document and for providing me with a place to read, work and think during my graduate program. I am also indebted to the members of my dissertation committee and to several other distinguished scientists whose aid and assistance were invaluable. I would also like to acknowledge the patient support of my wife and family throughout my studies. Finally, I would like to express my appreciation for the comradeship of the graduate students of the Department of Anatomy past and present, who made this educational experience memorable.

## VITA

The author, Howard R. Higley, was born in Dubuque, Iowa on December 18, 1951 and his elementary and secondary education was obtained in the public school system of that city. He attended the University of Iowa in Iowa City, Iowa from 1970-1974 where he received a Bachelor of Arts degree in Zoology. He began his graduate studies in the Department of Biological Sciences of the State University of New York at Brockport where he held a teaching assistantship in basic zoology and botany from 1974-1976. He entered the doctoral program in the Department of Anatomy at Loyola University Stritch School of Medicine, Maywood, Illinois in 1976 and held a basic science fellowship from 1976-1980 while teaching gross anatomy, histology and neurosciences courses. He was awarded the Arthur J. Schmitt Fellowship and elected to the Society of Sigma Xi in 1980. He is presently a postdoctoral fellow in the Department of Pathology at the Stritch School of Medicine.

## TABLE OF CONTENTS

Vita .....	1
Acknowledgments .....	11
General Introduction .....	1
Review of Literature .....	4
Introduction .....	4
Epithelial cells .....	4
a) cortical epithelium .....	5
b) medullary epithelium .....	7
Mesenchymal cells .....	12
Thymic hormones .....	15
Thymic lymphocytes .....	21
Aims .....	26
Chapter I: Morphometric Analysis of Non-Lymphoid Cell Changes During Postnatal Development .....	28
Introduction .....	28
Materials and Methods .....	30
Results .....	33
Discussion .....	36
Summary .....	42
Chapter II: Thymic Interdigitating Cells .....	62
Introduction .....	62
Materials and Methods .....	64

Results .....	67
Discussion .....	71
Summary .....	77
<b>Chapter III:</b>	
<b>Thymic Myoid Cells .....</b>	<b>85</b>
Introduction .....	85
Materials and Methods .....	87
Results .....	89
Discussion .....	92
Summary .....	95
<b>Chapter IV:</b>	
<b>Immunocytochemical Localization of Thymic Hormones .....</b>	<b>106</b>
Introduction .....	106
Materials and Methods .....	107
Results .....	110
Discussion .....	113
Summary .....	115
Conclusion .....	126
General Summary .....	129
Bibliography .....	131

## LIST OF TABLES AND FIGURES

### Chapter I

Table I.	Thymic medullary volume .....	43
Table II.	Thymic lymphoid versus non-lymphoid cell density .....	44
Figure 1.	Total thymic cell density .....	45
Figure 2.	Thymic non-lymphoid cell density of cortex and medulla ..	47
Figure 3.	Thymic non-lymphoid cell volume density of cortex and medulla .....	47
Figure 4.	Electron micrograph of thymic medullary epithelial cell..	49
Figure 5.	Electron micrograph of interdigitating cell .....	49
Figure 6.	Electron micrograph of thymic medullary macrophage .....	49
Figure 7.	Electron micrograph of cystic epithelial cell .....	49
Figure 8.	Percentage of non-lymphoid cell subtypes in thymic medulla .....	51
Figure 9. (a,b,c,d)	Volume density of organelles in medullary non-lymphoid cell subtypes .....	53
Table III.	Volume density of thymic medullary epithelial cell organelles .....	58
Table IV.	Volume density of thymic interdigitating cell organelles .....	59
Table V.	Volume density of thymic medullary macrophage organelles .....	60
Table VI.	Volume density of thymic cystic epithelial cell organelles .....	61

### Chapter II

Figure 1.	ATPase staining of calf thymus .....	77
Figure 2.	ATPase staining of rat thymus .....	77
Figure 3.	Acid phosphatase staining of calf thymus .....	77

Figure 4 and 5.	S-100 staining of human thymus .....	82
Figure 6.	S-100 staining of human thymus .....	82
Figure 7.	Rat thymic medullary interdigitating cell .....	83
Figure 8.	Electron micrograph of adult rat interdigitating cell ...	83
Figure 9.	Electron micrograph of adult rat macrophage .....	83
Figure 10.	Electron micrograph of neonatal rat interdigitating cell.	84
Figure 11.	Electron micrograph of day 15 rat interdigitating cell...	84

### Chapter III

Figure 1.	Calf thymic myoid cell .....	96
Figure 2.	Electron micrograph of adult rat myoid cell .....	96
Figure 3.	Light and dark myoid cells .....	98
Figure 4.	Electron micrograph of dark myoid cell .....	98
Figure 5.	Electron micrograph of light myoid cell .....	98
Figure 6 and 7.	ACHE reaction in calf thymic myoid cell .....	100
Figure 8.	ACHE reaction in calf thymic epithelial cell .....	100
Figure 9.	Electron micrograph of rat Hassall's corpuscle .....	102
Figure 10.	Calf Hassall's corpuscle .....	102
Figure 11.	Keratin staining of human thymus .....	104
Figure 12.	PAS staining of human thymus .....	104

### Chapter IV

Table I.	Thymic hormones .....	117
Figure 1.	Immunofluorescence staining of thymosin VI in human thymus .....	118
Figure 2.	Immunofluorescence staining of thymopoietin in human thymus .....	118



Figure 3.	Immunoperoxidase staining of thymosin IV in human thymus .....	120
Figure 4.	Immunoperoxidase staining of thymopoietin in human thymus .....	120
Figure 5 and 6.	Immunoperoxidase staining of thymopoietin in calf thymus .....	122
Figure 7.	Electron micrograph of rat cortical epithelial cell ....	124
Figure 8.	Electron micrograph of rat macrophage .....	124
Figure 9.	Electron micrograph of rat medullary epithelial cell ...	124

## INTRODUCTION

### General Introduction

The thymus has been shown to be central to the development of a functioning immune system. However, the nature of the interaction between maturing lymphocytes and other cells and the endocrine products of this gland is incompletely understood. The presence of a substantial thymus gland only in young animals and the gradual involution as aging progresses, long presented a picture of an organ that was only transiently functional, perhaps unnecessary. Miller and Osoba's (1961) pioneering work on the immunologic basis of a wasting disease induced by neonatal thymectomy has led to a rich field of research that explores the mechanism by which the thymus exerts its particular influence on the developing lymphocyte.

In all vertebrates the thymus originates embryologically from the primitive pharynx as an epitheliomesenchymal rudiment. In mammals the thymus is a derivative of the third branchial pouch that is heavily infiltrated with lymphocytes. Four distinct histologic regions can be recognized: 1) the subcapsular lymphoproliferative zone or outer cortex, 2) the inner cortex, 3) the medulla and 4) the perivascular connective tissue spaces; inner medulla, septa and capsule. The subcapsular zone contains large lymphoblasts undergoing intense proliferative activity.

This response is not antigen driven in contrast to mitotic activity within the germinal centers of the peripheral lymphoid organs. One to eight assymmetric divisions produce small lymphocytes that are passively crowded toward the inner cortex where they predominate. Eventually these small lymphocytes enter the vasculature to seed the T-dependent areas of lymph node, spleen and gut-associated lymphoid tissues.

The non-lymphoid component of the thymus contains both epithelial and mesenchymal elements. The relative contribution of each to thymic immuno-differentiating activities is still unclear. The epithelial stromal cells can be roughly divided into two forms, driven in contrast to mitotic activity within the germinal centers nucleoli, and cytoplasmic tonofilaments. They are connected to other epithelial cells of the gland by desmosomes to form a net-like 'cyto-reticulum' that holds the lymphocytes in place. In the outermost portion of the gland, the cortex, epithelial cells are found, that are stellate in form and enmesh large numbers of lymphocytes in their long processes. The central part of the gland, the medulla, contains fewer lymphocytes and a second type of epithelial cell more voluminous in nature.

Mesenchymal cells also occur in both these thymic zones. Macrophages contain the remains of lymphocytes within their cytoplasm and it is thought that these phagocytes act to clear the thymus of its effete or self-reactive cells. Cells related to the dendritic reticulum cells of the lymph node and to the Langerhans cell of the epidermis are also present in the thymus. The function of these cells is at present unk-

noun. A variety of other cell types such as myoid cells, neuroendocrine cells and granulocytes have been described.

The epithelial-reticular cells of the thymus have long been implicated in the production of T-cell differentiating factors, known collectively as 'thymic hormones'. The epithelial origin of these factors is supported by several lines of research but the morphologic and histochemical evidence of secretory activity in thymic epithelial cells has been confusing and often contradictory. The relative contribution of each of the mesenchymal elements to the physiology of T-lymphocyte maturation also warrants further study. It is hoped that an additional more detailed light, and electron microscopic, morphometric, histochemical and immunocytochemical categorization of thymic stromal elements presented here will aid in the identification of the cells responsible for T-lymphocyte differentiation.

## REVIEW OF LITERATURE

### Introduction

The non-lymphoid cellular component of the thymus is a highly heterogeneous population. Various classifications of these cells, formulated on morphologic or histochemical bases, have been proposed by several investigators (Mandel 1968, Hoshino 1963, Clark 1973, Bennett 1978, Duijvestijn and Hoefsmit 1981). Most agree that there is a framework of cells of an epithelial-reticular nature that enmesh lymphocytes, and cells that are mesenchymal-reticular in character which are associated with the vasculature. The role that any or all of these cells play in producing the unique environment that permits thymocyte differentiation has been a matter of controversy. (Bennett 1978, Duijvestijn and Hoefsmit 1981).

### Epithelial Cells

Although light microscopic identification of large pale staining cells with vesicular nuclei as epithelial cells, in a predominantly lymphoid thymus, may be generally accurate, true confirmation of the epithelial lineage of a thymic stromal cell can only be made at the ultrastructural level on the basis of the presence of tonofilaments or desmosomes. A stain claimed to be specific for tonofilaments, Buffalo Black-Tannic acid, has been used to demonstrate so-called cell-web containing elements in the thymus (Pereira and Clermont 1971). Tonofilaments are fibrils 30-60 Angstrom units in diameter that are closely

related to keratins biochemically and immunologically (Tien-Sun et al. 1979), They are found in large numbers in the cytoplasm of some thymic epithelial cells, and the similarity of these cells to the keratinocytes of the skin is striking. Differences exist between the epithelial cells of the thymic cortex and those of the medulla, although both contain tonofilaments. This distinction has been noted in all mammalian species examined including, the guinea pig (Mandel 1968), the mouse (Clark 1966, Hoshino 1963, Mandel 1970), the hamster (Ito and Hoshino 1966), the monkey (Chapman 1971), the rat (Hwang et al. 1974, van Haelst 1967, Pfoch 1971, Rappay 1971), the dog (Gorgollon et al. 1978) and the human (Bearman 1978).

**Cortical Epithelium** Cortical stellate epithelial cells exhibit an extremely attenuated cytoplasm drawn out into long cytoplasmic processes that surround the many lymphocytes seen in the cortex. At the core of these processes are bundles of tonofilaments. Epithelial cells have a basement membrane at the surface of the thymic lobule and adjoining the vascular trabeculae, but only in apposition to the connective tissue elements. Stellate cell cytoplasmic organelles are generally concentrated near the nucleus. These include membrane bound bodies that range in appearance from characteristic 'clear' vesicles with smaller dense bodies rimming the interior surface of the vesicle, to electron dense bodies that may be either lysosomal or secretory in nature.

Cortical epithelial cells have been claimed to have functions critical for maturation of the thymic immune system. Mandel (1968) as a

result of his studies on the guinea pig suggested that the pale cortical reticular cell contained secretory granules that contained a lymphocytopoietic substance. These granules were shown to be negative for acid phosphatase, making it unlikely that they were lysosomal in nature. He considered that medullary epithelial cells played no role in lymphocytopoiesis. In his opinion, medullary tissue was only necessary as an epithelial source for the more functionally specialized cortical stellate cells. Metcalf and Ishidate (1962) discussed a periodic acid-Schiff positive reaction (PAS) in a cortical cell and noting its proximity to mitotic figures, postulated a lymphocytotropic function. It is now known that the special 'clear' granules of cortical epithelial cells, although PAS positive, are not readily visible with the light microscope, making the 'secretory' cell of Metcalf and Ishidate (1962) more likely to be a macrophage with inclusions of phagocytosed lymphocyte remains. Other cortical epithelial cells seem even less likely to be capable of secretory activity. Frazier (1973) described a very dark cortical or dense reticular cell in the chick, that was most probably a degenerating cell. Izard (1968) has also seen such cells and described them as being increased in number in the leukemic mouse thymus.

Despite the inability to identify a true secretory granule in the epithelial cells of the thymic cortex, there is still evidence that cortical stellate epithelium may be 'thymotropic'. Mandi and Glant (1973) and Goldstein (1975) have identified cortical immunofluorescence staining of stromal elements for several thymic hormone preparations, but

emphasized prominent medullary staining as well. Wekerle (1980) was able to isolate lymphoepithelial complexes from thymic cortex. These consisted of cortical epithelial 'nurse cells' with 'emperipolised' or internalized lymphocytes within their cytoplasm. He considered that cell to cell contact, as well as exposure to the hormonal milieu during this intraepithelial transit, were essential steps in T-lymphocyte generation. The stellate cell of the cortex is, in fact, this 'nurse' cell. Zinkernagel's (1978) finding that the thymic epithelial H2 type determines the context of subsequent antigen recognition during cell-mediated immune reactions, supports this view of epithelial-lymphocyte cell membrane interaction. Cortical epithelial cells may contribute to the thymic lymphocyte differentiating microenvironment by contact mediated mechanisms rather than by the elaboration of soluble factors.

**Medullary Epithelium** Medullary or hypertrophic epithelial cells are readily distinguished from cortical epithelial cells by virtue of their larger nuclear size, more extensive cytoplasm and lack of specific 'clear' cortical epithelial cell granules (Mandel 1968). They often contain a variety of other inclusions and are packed with tonofilaments and connected to the other cells by numerous desmosomes. Several subtypes of medullary epithelial cells have been described (Mandel 1968, Duijvestijn and Hoefsmit 1981). Mandel (1968) noted a squamous form, while Duijvestijn and Hoefsmit (1981) referred to the same cell as epithelial-reticular. These cells are probably supportive in nature, but they contain an occasional electron dense granule that some investigators



have associated with secretory activity (Vetters and Macadam 1973). It is more likely that their protein synthetic apparatus is concerned with the synthesis of keratin-like products.

Villous or cystic forms of epithelial cells (Mandel 1968) or vacuolated epithelial cells (Duijvestijn and Hoefsmit 1981) are also seen in the medulla and possess peculiar vesicles in their cytoplasm. The walls of these vesicles often contain several microvillous projections directed into the lumen. These vesicles vary in size and shape and in the extent of the microvillous border. Cilia have also been observed in the lumina of such vesicles. The microvilliform vesicles of the medullary hypertrophic epithelial cells may contain a secretory substance. Studies have sought to prove that these cells are the source of thymic hormone. Hoshino (1963) showed these vesicles to vary greatly in shape and size in the mouse and was the first to demonstrate electron microscopically that their lumina contained an amorphous substance. Hoefsmit (1975) identified material in the inclusions of these hypertrophic epithelial cells as glycoprotein using the silver methenamine-PAS technique, in guinea pigs and rats. Clark (1973) provided both radioautographic and histochemical data in mice that showed that these cells were active in the synthesis of some sulfated mucopolysaccharides or glycoproteins. Disodium<sup>35</sup> sulfate and C<sup>14</sup> glucosamine were not incorporated into cortical epithelial cells. Labeling was seen in medullary epithelium with these isotopes. Neither of these products are constituents of any known thymic hormone, however they are probably

indicators of a keratinization process. Clark (1973) described three categories of inclusions in medullary epithelium. Small dense granules, clustered vacuoles and large cysts that stained variably with PAS-Alcian Blue (a test for glycoproteins and mucosubstances) were seen in proximity to the silver grains in the autoradiographs. The PAS positive inclusions also showed some acid phosphatase activity. The relative proportion of these inclusions varied predictably with the age of the animal. Bennet (1978) showed incorporation of tritiated fucose into vacuoles of the hypertrophic epithelial cells as well as into the stellate cells of the cortex. He noted that although the thymic hormones are all proteins when released, the native hormone may be stored in epithelial cell vacuoles as glycoproteins. The effect on thymocytes of this PAS positive glycoprotein or mucosubstance found in villous and cystic epithelial cells of the thymic medulla is unknown. It is now understood that T-cell differentiation proceeds not only by the sequential appearance of cell surface markers during transit through the thymus but also by the disappearance or masking of certain markers (Scheid et al. 1975). The finding that the sialic acid content of the thy-1 antigen increased during T-lymphocyte maturation (Hoessli 1980) might suggest a need for exportable epithelial cell glycoproteins. Indeed, villous cells might function by 'covering up' cell membrane markers during medullary steps of differentiation (personal communication J. Sharp).

Abrahamson (1968) demonstrated lysosomal changes in some medullary epithelial cells at the electron microscopic level following cortisone

induced involution and recovery. He contended that the association of lysosomal enzymes with PAS positive material may be in the nature of control and degradation of secretory material for eventual release. Rappay (1971) noted cellular acid phosphatase and non-specific esterase reactivity in a light microscopic examination of the stromal cells in a developing series of rat thymi. Ito (1978) has shown medullary epithelial cell inclusions that are alkaline phosphatase positive.

Thymic or Hassall's corpuscles are medullary epithelial cell islands or aggregates. They differ markedly in size and configuration between species and even between lobules within a single gland (Blau 1968, Kotani et al. 1981, Caso 1979). Multicellular Hassall's corpuscles are composed of large swirls of squamous epithelial cells often with a necrotic center. The ultrastructural features of these cells include, dense plaques of tonofilaments or keratin in their cytoplasm and desmosomes connecting them to the other epithelial cells of the corpuscle. Some cells appear to be undergoing degeneration, while others are relatively intact. Interspersed among the epithelial cells can be seen various granulocytes and some macrophages. In some species, simple Hassall's corpuscles can also be seen. These structures consist of a single voluminous epithelial cell, wrapped by a single epithelial lamella, with relatively few tonofilaments within its cytoplasm. Hassall's corpuscles are by no means static structures. They are being remodeled throughout development (Kotani et al. 1981) and it may be that the single cell forms are the precursors or nucleation centers of the multicellular corpuscles.

Hassall's corpuscles have often been implicated in the acquisition of immunocompetence (Blau 1968). Caso (1979) has observed that only 10-50% of all corpuscles in five different species contained the sulfhydryl groups of keratin. The remainder appeared quite active, exhibiting histochemical reactivity for glycoproteins and mucoid substances. Blau (1968) cited the increase in size and number of Hassall's corpuscles that preceded recovery from irradiation of the guinea pig thymus as evidence for their active role in lymphocytopoiesis. Other authors (Kostewicki 1964) cited the acid phosphatase content of Hassall's corpuscles as an indication of some phagocytic function, perhaps preformed by associated macrophages, in degrading and recycling lymphocyte materials. It has also been suggested that thymic corpuscles are responsible for the production or sequestration of thymic peptides. Van den Tweel (1978) has shown specific immunocytochemical staining for a thymic hormone preparation in Hassall's corpuscles and epithelial cells of the calf and man at the light microscopic level.

Such examples do not, however, confirm the true in situ synthesis of hormone. Perhaps they indicate the sequestration of the polypeptide for presentation to the developing lymphocyte. In fact the heavily keratinized end form of Hassall's corpuscles, seem less likely prospects for actual production of hormone than the more active appearing large medullary cells or simple Hassall's corpuscles.

The mesenchymal component of the mammalian thymus consists of connective tissue cells that support the vasculature, as well as thymic phagocytes and occasional wandering blood cells. Numerous inclusion containing cells are seen in the cortex of many species (Hoefsmit 1975). Ultrastructural examination reveals these cells to have the internalized apoptotic remains of numerous thymocyte nuclei within their cytoplasm. These cells resemble the tingible body macrophages of the lymph node germinal center. It has been suggested by Duijvestijn and Hoefsmit (1981) that macrophages are normally present in the epithelial compartment of the thymus only in small numbers. However, they are capable of migrating from the connective tissue trabeculae into the thymic parenchyma itself. Other authors describe macrophages in substantial numbers among the lymphocytes of the thymic cortex and especially describe their concentration at the cortico-medullary boundary (Hwang et al. 1974). This boundary, although never a sharp line of demarcation histologically, denotes a substantial change in the thymic microenvironment as evidenced by the physiologic and functional differences between lymphocytes obtained from these two regions (Stutman 1975, Schlesinger et al. 1975, Schied et al. 1975). Differences in immunocompetence, cell surface character, size and number have been described between medullary and cortical lymphocytes. The segregation of the cortical milieu from the medulla and the rest of the body may be maintained by a blood-thymus barrier proposed by the studies of Raviola and Karnovsky (1972). This barrier may be maintained by epithelial cells 'sealing off' the cortical

vasculature and may be 'backed up' by the concentrations of macrophages seen at the cortico-medullary border.

Macrophages are also seen in the thymic medulla along with another type of mesenchymal-reticular cell, the interdigitating cell (IDC). The IDC has a voluminous cytoplasm with a cytocentrum and a periphery that is largely devoid of all organelles, giving it a 'clear' or electron-lucent appearance. This cell has a highly dendritic profile and resembles cells found in the T-cell areas of peripheral lymphoid organs and in the epidermis. (Van Haelst 1969, Thorbecke et al. 1980, Duijvestijn and Hoefsmit 1981). The function of the thymic interdigitating cell is at present unknown, but in other tissues it performs an essential accessory cell function in the immune response (Steinman et al. 1978, 1979).

Another cell type seen at the cortico-medullary boundary, is the autofluorescent cell (Sainte-Marie 1965). This cell exhibited a yellow-green fluorescence in acetone fixed frozen sections viewed with ultraviolet illumination. The granules of the autofluorescent cell contained PAS positive material and acid phosphatase activity. Oil red O staining indicated that these inclusions contained lipid. Autofluorescent cells are not unique to the thymus, having been found in other lymphoid organs. Sainte-Marie (1965) dismissed the suggestion that they are macrophages because they are not found in the usually macrophage rich lymphatic sinuses of the lymph node. He contended that the development of these cells paralleled the development of immunity in young animals and that autofluorescent cells developed under the influence of the thy-

mus and may be involved in hormone secretion. These cells were not the vitamin A containing fluorescent cells described in the thymus by Ito (1978), as these latter cells were only found along the connective tissue trabeculae, and not at the cortico-medullary boundary.

Hakonson's (1974) treatment of the chick thymus with formaldehyde gas demonstrated another type of fluorescent cell. These cells contained 5-hydroxytryptophan, could also be induced to store L-dopa and stained with both silver and chromaffin techniques. It has been argued that these cells should be included in Pease's (1974) APUD system. This diffuse endocrine network is typified by cells that contain amines, peptides and sometimes esterases and include among others, the neuroectodermally derived enterochromaffin cells of the gut. The amines are thought to aid in the secretion of the peptide hormones within these cells. The obvious hormone in question in the thymus would be a lymphocytopoietic agent. The plausibility of this idea is increased when it is recalled that the thymus too, is composed of foregut derived branchial pouch endoderm. The identification of these cells strictly on the basis of their argyrophilia is dubious at best as granulocytes also encountered in thymic tissue non-specifically adsorb silver, making unequivocal identification of a unique APUD cell difficult. Whether these enterochromaffin cells do indeed produce a thymic hormone remains to be proven.

Mast cells are active in IgE mediated hypersensitivity reactions and some mastocytogenesis does occur in the thymus of some species (Met-

calf 1966). It has been suggested that mast cells can arise directly from thymocyte precursors and a mast cell precursor or 'P-cell' can be found in the thymic parenchyma (Burnet 1966). Metcalf (1966) has distinguished two different populations of mast cells in the NZB mouse on the basis of their reaction to an elastin stain. He also suggests that in addition to containing histamine, heparin and allied substances, mast cell granules might act as ion-exchange pellets to absorb monosaccharides or other products such as polypeptides secreted by epithelial cells, and thereby play a role in T-cell transformation.

A final non-lymphoid cell type found in the thymus, is the myoid cell. This cell contains myofilaments and has many of the characteristics of the striated muscle cell (Van de Velde and Friedman 1970, Strauss et al. 1966). Whether this cell is mesenchymally derived or more closely related to the thymic epithelial cell has not yet been established.

### Thymic Hormones

The first indirect evidence that the thymus might elaborate a humoral substance that produces immunoreconstitution after neonatal thymectomy came from Osoba and Miller (1963), who grafted thymectomized mice intraperitoneally with thymi enclosed in Millipore diffusion chambers. This technique was as effective in restoring immune function as simple thymus grafting. Assays used by them and by other workers to confirm this restoration included decreased allograft rejection time (Osoba and Miller 1963), increased delayed hypersensitivity response to sheep



red blood cells (Law et al. 1964), and an increased capability of cells from restored mice to initiate a graft versus host splenomegaly or lethal runting syndrome in appropriate hosts (Stutman et al. 1970). Control chambers either empty or containing other normal or neoplastic tissues, including spleen and lymph node were ineffective in restoring immune function as defined by the assays mentioned (Stutman et al. 1969). Criticism that questioned the integrity of the chambers was answered by the observation that T6 chromosome marker-containing thymus grafts revealed no thymus derived donor cells in the lymphoid tissues of the host (Barclay et al. 1964).

An elegant natural experiment supporting the hormonal nature of thymic activity was shown in neonatally thymectomized female mice that exhibited an improvement in immune response during pregnancy. The assumption that placental transfer of the fetal thymic substance is responsible for this potentiation of immunity rather than increased sex hormone levels was indicated by absence of the effect in a pseudo-pregnant animal (Osoba 1973).

Studies which examined recovered chambers histologically, addressed the question of which cell types contributed the restorative factor. Chambers usually contained only epithelial cells, the lymphocytes having died and fragmented (Osoba and Miller 1963). Furthermore, serial transfer of an in vivo pre-incubated thymus graft or pre-irradiated graft (a procedure that depleted the thymus of lymphocytes leaving the more radio-resistant epithelial cells) were both equal in restora-

tive ability to intact thymi (Hays 1964). Neither experiment negated the possibility that thymic epithelial cells were sequestering and releasing thymocyte products that were themselves lymphocytopoietic. In the light of current immunologic theory implicating the T-cell as both a direct effector and as a regulator of the immune response, many of the effects of the early Millipore filter experiments can be better understood. Recent studies (Bach et al. 1971, Kumoro and Boyse 1973) demonstrated the appearance of T-cell surface markers on cells of thymectomized adult and athymic nude mice that have been grafted with thymi in diffusion chambers. These improved T-cell bioassays have aided in the search for thymic extracts equally active as the intact gland in restoring immune function.

Several groups of investigators have isolated biologically active thymic factors from a variety of mammalian sources, including calf, man, pig, rat and mouse, utilizing a variety of preparative procedures. Those factors most thoroughly studied are thymosin, thymic humoral factor (THF), thymopoietin, and circulating thymic factor (FTS)

Goldstein and White (1966) initially utilized a crude lymphocytopoiesis assay that measured the increased incorporation of labeled amino acids and nucleotides into lymph node protein and DNA of thymectomized mice and used this to direct the purification of a factor they called thymosin. A number of fractions have since been prepared (Goldstein et al. 1978). The most active, fraction V, was a complex solution of many proteins. Among them was thymosin alpha 1, a 22 amino acid polypeptide

that was 10 to 1000 times more effective in restoring several specific immune parameters than its parent preparation, fraction V. Alpha 1 also induced the appearance in cortical cells of terminal nucleotidyl transferase. This enzyme randomly polymerized nucleotides onto a DNA strand without a template, an action that is significant in light of Jerne's theory (1971) that the thymus is the site of random mutation and selection of non-self reactive clones of T-cells. Another polypeptide B1 has been shown to be ubiquitin, a non-histone chromosomal protein found universally in all tissue of both plants and animals, that can induce the appearance of T-cell surface markers, but can induce B-cell and granulocyte effects as well (Schlesinger et al. 1975A). A final fraction, alpha 7, has been shown to be inductive of a suppressor T-cell population. These cells are thought to inhibit aberrant production of immunoglobulin by B-cells, an essential function in the prevention of autoimmune states (Horowitz et al. 1977). As to the cellular source of thymosin, Blankwater (1978) has produced fraction V from calves that have been irradiated and whose thymi contain only epithelial and stromal elements.

Thymic pathology has long been associated with the wasting muscle disease myasthenia gravis. Thymectomy has been found to improve the status of some patients. Injection of thymic extracts into animals with experimental autoimmune thymitis caused a neuromuscular blocking phenomenon that was utilized to isolate the thymic humoral mediator responsible (Goldstein 1975). Thymopoietin has since been shown to be active in

assays of T-immune restoration as well. Purification has given a peptide of 49 amino acids and a synthetic fragment of this peptide has been shown to produce the hormonal effect (Schlesinger et al. 1975B). The supernatant of certain cultures of thymic epithelium was shown by radioimmunoassay to possess thymopoietin-like substances (Schlesinger et al. 1975B). Epithelial cultures obtained from patients with severe combined immunodeficiency did not secrete this agent (Pahwa et al. 1978). Since these patients have a bone marrow defect, it was presumed that some interaction between bone marrow cells and thymic epithelium was essential for thymic hormone production.

Bach et al. (1972) developed a sensitive and complex assay for the appearance of theta marker on lymphocyte cell surfaces. T-cells spontaneously rosette when incubated with heterologous red cells. This reaction can be inhibited by anti-theta serum or azothioprine. Bach et al. (1972) screened low molecular weight components of normal serum to find a substance active in potentiating the reappearance of rosette forming cells after thymectomy. This fraction termed FTS was later purified and found to be a nonapeptide (Bach et al. 1977). The rosette test has been used extensively for the final purification of the other two previously mentioned thymic hormones. Radioimmunoassay has shown fluctuation in human FTS levels during the aging process (Pahwa et al. 1979).

Trainin (1970) dialysed a crude homogenate of the thymus and found a small molecular weight preparation containing thymic humoral factor (THF). THF activity was evaluated by its ability to restore T-cell

competence in an in vitro graft versus host reaction. Purification yielded an active acidic protein of approximately 3,000 molecular weight with a 30 amino acid composition distinct from the aforementioned factors. Trainin (1974) also isolated an FTS-like factor from crude THF preparations that is capable of restoring mitogen responsiveness to the T-cells of thymectomized animals, a capability not present in Bach's FTS.

Other thymic extracts include; lymphocyte stimulating hormone (Luckey 1973), a factor that may have some effect on antibody synthesizing B-cells but none in restoration of cell mediated immune function after thymectomy; and stromal thymic factor, isolated from chick thymus and active in avian T-cell potentiation, but not completely active in mammalian systems (Teodorozyk et al. 1975).

The characterization of all these factors as protein led to the criticism that thymic hormone action was no more than a non-specific antigen-adjuvant effect or alternatively the result of endotoxin contamination (Goldstein et al. 1975). Rigorous conditions of preparation excluded the possibility of endotoxin effects and syngeneic sources of the factor were capable of restorative effects (Kruger et al. 1970). Furthermore, mere 1-2 hour in vitro preincubation of factors with lymphocytes, far short of the time required for the mitogenesis of immunogen activation, yielded an increase in T-cell markers (Bach et al. 1975). The specificity of thymus as a source of hormonal factor was shown by the ineffectiveness of extracts prepared in an identical fashion

from other tissues including liver, kidney, muscle, spleen or lymph node (Stutman et al. 1970). However, antibodies to crude thymic extracts showed immunochemical cross-reactivity with fractions from these other tissues, indicating common antigens such as epithelial antigens. Presumably, the antigens were not germane to the hormonal effects of these extracts (van den Tweel et al. 1978).

Other substances can also influence the appearance of T-cell markers. Epinephrine, insulin, poly-adenosine:uracil, and prostaglandin E2 all have a similar mode of action to thymic hormones via a second messenger cAMP (except thymosin which acts via cGMP) but none seems relevant to normal T-cell differentiation. Epinephrine is only active in greater than physiologic concentrations, insulin actually decreases theta levels, poly adenosine:uracil can activate B-cells as well as T-cells and prostaglandin E2 works through a different receptor than the known thymic hormones (Scheid et al. 1975).

### Thymic Lymphocytes

The thymic cortex is divided into inner and outer or lymphoproliferative zones. This division is based on the distribution of small lymphocytes and large or lymphoblastic cells. Large lymphocytes (8 $\mu$ m) or lymphoblasts populate the zone immediately beneath the thymic capsule. Their nuclei are large with prominent nucleoli and their cytoplasm is filled with many polyribosomes. Many mitoses are seen in this comparatively narrow lymphoproliferative zone. By far the most numerous cell in the thymus is the small lymphocyte (5 $\mu$ m). These cells are produced by

one to eight divisions of the lymphoblasts and are then crowded toward the inner cortex and eventually into the medulla before leaving the gland (Leblond and Sainte-Marie 1960). A resident population of medullary lymphocytes that does not populate the peripheral lymphoid organ has also been postulated (Elliot 1977).

The concept of T-cell subclasses has been summarized by Stutman (1975). Data from a number of studies have indicated that T-cell differentiation progresses from a bone marrow (or fetal liver) prothymocyte, low in theta antigen, to a cortisone-sensitive, theta-positive, cortical immunoincompetent thymocyte or T0 stage. Stem cells may be one of the targets of some thymic hormones. Bone marrow cells may be influenced to migrate to the thymus by FTS (Bach 1973). Incubation of bone marrow cells with thymosin V gives a cell population capable of initiating a graft versus host response in an appropriate host that is sensitive to inhibition by anti-theta serum (Touraine et al. 1974). This may indicate processing beyond the T0 stage by the thymosin complex. Thymic humoral factor does not seem to be active in this assay (Small and Trainin 1971). Subsequent steps in differentiation may require direct transit through the thymus and exposure to its internal humoral and cellular milieu. Zinkernagel (1978) has shown that the H-2 or histocompatibility type of the thymic epithelium determines the H-2 reactivity of thymocytes maturing within the cytotreticulum.

Further differentiation of the T0 cell yields a partially immunocompetent cortisone insensitive T1 cell that is relatively sessile,

spleen seeking, and long lived (Stutman 1975). This T-cell is thought to be functional in immunologic memory and to possess suppressor activity. T1 cells are actively stimulated in mixed lymphocyte cultures and exhibit all three Ly antigens but are low in theta antigen. These cells are sensitive to adult thymectomy and reappear after treatment with THF, thymosin or circulating thymic factor, (Bach and Carnaud 1976), indicating normal maintenance of these cells in the periphery by these hormones. NZB mice, a strain that succumbs to glomerulonephritis as a result of high levels of circulating antibody to nuclear antigen, are thought to lack a specific suppressor T-cell population. These mice respond to treatment with several thymic hormone preparations by exhibiting an increase in suppressor cell numbers (Dauphinee et al. 1974). Lymphocytes from patients with systemic lupus erythematosus, a human disease thought to have a similar etiology show an increase in suppressor cell activity when incubated with several thymic hormones. (Scheinberg et al. 1975, Horowitz et al. 1977).

T2 cells mature in the peripheral lymphoid system, are lymph node seeking, short lived and are capable of being stimulated by plant mitogens (Stutman 1975). These T-cells have been shown to contain a population of cells that are cytotoxic and that possess helper function. Both antigen and thymic factors may drive the T1 cell to fully competent T2 status (Cantor and Boyse 1975). Several thymosin subfractions have been proposed to be effective in the activation of cytotoxic or killer T-cells, other fractions are implicated in the differentiation of anti-



body helper T-cells (Goldstein et al. 1978). Whether the various thymic factors represent different native hormones liberated by the thymus, each influencing different steps in T-cell maturation, or variants of one hormone that in vivo has an effect on all transitions from subset to subset, remains to be clarified.

Clinical trials of thymosin and THF show some application of thymic hormone therapy in the restoration of T-cell levels in individuals with immunodeficiency diseases and in immunodepressed cancer patients (Goldstein et al. 1978). On the other hand, individuals with rheumatoid arthritis have been reported to have increased circulating levels of thymic hormone (Bach et al. 1975). Some patients with congenital agenesis of the thymus or DiGeorge's syndrome have responded well to thymosin V therapy or fetal thymus transplant (Pahwa et al. 1979). Patients with ataxia-telangectasia, a genetic disorder with variable T-cell defects and progressive neurologic deterioration have responded to a block transplantation of thymus-sternum complex (Lopulchin et al. 1973). The sternal marrow presumably acts as a stem cell source while thymic epithelium processes these cells to increase T-cell levels. Pure thymic epithelium has been used in attempts to reconstitute immunologically, cases of severe combined immunodeficiency in which there was no bone marrow donor available (Hong et al. 1978). Only a 20-30% success rate has resulted from this therapy with several individuals succumbing to a curious B-cell lymphoma. Thymosin has increased the number of E-rosettes in patients whose T-cell number was depleted by cancer che-

motherapy (Goldstein et al. 1978). However, the functional capacity of this increased number of T-cells to deal with the tumor burden is questionable. In fact, in an animal model, thymopoietin and THF were shown to be ineffective in restoring host resistance to a mouse leukemia as compared to sham thymectomized controls, even though absolute T-cell numbers were increased (Martinez et al. 1978).

Regardless of the difficulty in interpreting these complex thymic hormone effects there will undoubtedly be further development of applications of thymology to clinical situations.

## AIMS

The heterogeneity of non-lymphoid cell types found in thymic tissue makes interpretation of their role in the establishment of a T-lymphocyte differentiating microenvironment difficult. Therefore, it was the purpose of this work to recognize and classify the variety of non-lymphoid cell types found in the normal thymus and compare their distribution and arrangement during thymic development. This was accomplished at both the light and electron microscopic level utilizing morphometrics, histochemistry and immunocytochemistry applied to thymic cells of different ages in the rat and of the calf and human infant. It was intended that this comparative and developmental approach would provide a better understanding of normal thymic structure and function. The specific aims of the study were:

1. To determine the proportion of the thymus occupied by the medulla during thymic development.
2. To determine the absolute cell numbers and the volume density of the non-lymphoid cell component of the cortex and medulla in the developing thymus.
3. To determine the relative numbers of non-lymphoid cell subtypes in the thymus (epithelial cells, interdigitating cells, macrophages, voluminous epithelial cells), and to ascertain whether these numbers changed with age.
4. To determine whether morphologic evidence of non-lymphoid cell secretory activity could be detected by ultrastructural morphometric analysis of the developing thymus.

5. To ascertain whether thymic medullary interdigitating cells have staining properties for ATPase and S-100 protein similar to the Langerhans cell of the epidermis.

6. To examine the distribution of the interdigitating cell in the mammalian thymus and to compare it with that of the conventional macrophage?

7. To ascertain whether thymic myoid cells possess membrane associated acetylcholinesterase.

8. To investigate whether thymic myoid cells and epithelial cells possess similar cytoplasmic markers such as keratin or myoglobin, that might indicate they are of a common endodermal origin.

9. To determine whether antibodies to thymosin and thymopoietin are localized in the thymus and whether these hormones are secreted by different thymic non-lymphoid cells.

CHAPTER I  
MORPHOMETRIC ANALYSIS OF NON-LYMPHOID CELL  
CHANGES DURING POSTNATAL DEVELOPMENT

Introduction

The thymus is composed of an epithelial and lymphoid parenchyma together with a connective tissue stroma that forms the thymic capsule and the intrathymic septa associated with its blood vessels. Lymphocytes are enmeshed in the epithelial 'cytoreticulum' and cells of mesenchymal origin are also found within this network. Both these forms of non-lymphoid cell may be necessary components of the unique intrathymic micro-environment needed for T-cell maturation (Jenkinson et al. 1981). Although cells that bear obvious structural hallmarks of secretion are not frequently seen within the thymus (Gorgollon et al. 1978, Duijvestijn and Hoefsmit 1981), immunofluorescent and cytochemical studies suggest that certain of the epithelial elements are responsible for the secretion of thymic hormones (Mandi and Glant 1973, Goldstein 1975). However, the particular cellular elements to which this secretion may be attributed are not yet known. Nor is the contribution of the mesenchymal cells to T-cell differentiation understood. The study reported here deals with a quantitative analysis of the various non-lymphoid cells of the thymus during postnatal development and looks for evidence of their secretory activity.

Ultrastructural findings on the non-lymphoid cellular component of the thymus in various species, are in general agreement. Epithelial cells are readily distinguished by their intracytoplasmic tonofilaments and desmosomal attachments to adjacent epithelial cells. Various subtypes have been described according to their structural characteristics (Mandel 1968, Hoshino 1963, Clark 1973). However, many authors (Bearman et al. 1978) consider these subtypes to be merely minor variations of a single type of cell. The three principle forms which have been described are the stellate epithelial cell found in the cortex and hypertrophic or squamous epithelial cell and the cystic or voluminous epithelial cell found only in the medulla. These later cells are characterized by a more globular shape coupled with the presence of intracytoplasmic cysts in which microvilli are often seen (Bennet 1978).

Macrophages are also a prominent feature of the thymus and vary in their structural appearance according to their level of phagocytic activity (Hoefsmit 1975). Other, rarer, non-lymphoid cells have been described. These include the non-epithelial interdigitating cell (Kaiserling 1974, Klug and Mayer 1979, Duijvestijn and Hoefsmit 1981, Von Gaudecker et al. 1980) resembling the Langerhans cells found in the skin; peculiar myoid cells containing myofilaments (Puchtler et al. 1975, Bearman et al. 1978, Gilmore and Bridges 1974); and such cells as mast cells, plasma cells and granulocytes that are largely or entirely confined to the septal perivascular regions.

Published studies on these non-lymphoid cells, with few exceptions, have been qualitative. Hwang et al. (1974) obtained quantitative data on the number and volume of lymphocytes, lymphoblasts and epithelial cells in the cortex and medulla of the one day old, ten day old and 75 day old rat. Their study did not, however, provide data on the subtypes of non-lymphoid cells and so it was to this issue that the present study was addressed. The purpose was to provide information towards an understanding of the role these cells might play in the secretion of thymic hormone. More specifically it was the purpose of this study to: 1) obtain cell counts, both absolute and differential, and volume density measurements of the non-lymphoid cells in the developing rat thymus; 2) obtain similar data in the calf, because the calf thymus has been the primary source of several thymic hormone preparations (Goldstein et al. 1966, Goldstein 1975); and 3) analyze quantitatively the various cytoplasmic components of non-lymphoid cells within the thymus of the rat.

#### Materials and Methods

Thymi were obtained from Sprague-Dawley rats of either sex from the following ages groups (n=number of animals): One day old (n=9); day 8 (n=9); day 15 (n=6); day 22 (n=6); day 36 (n=3); day 50 (n=3); day 65 or adult (n=3). Samples were collected from several litters. Six calf thymi, from animals less than one year old, were obtained from a local slaughter house. Unfortunately the precise age of these calves could not be ascertained.

Rat tissues were fixed for one hour in phosphate buffered 4% glutaraldehyde, post-fixed for one hour in 2% osmium tetroxide and dehydrated in a series of graded alcohols. Some calf tissue was fixed similarly, whereas the rest was fixed in 10% buffered formalin. Rat and calf tissue was embedded in Araldite 6005 or Epon 812, and additionally some calf tissue was embedded in glycol methacrylate (JB-4). One micron thick Epon or Araldite and three micron thick methacrylate sections were stained with toluidine blue or hematoxylin and eosin. Thin sections for electron microscopy were stained with uranyl acetate and lead citrate.

Sixty blocks from each group of rats and a total of 60 blocks of embedded calf thymus were examined by light and electron microscopy in the following ways.

- 1) Medullary and cortical volume as a percentage of total lobular volume in the rat thymus was estimated by a planimetric method. Fourteen blocks from each age group were selected at random for analysis. Images of one micron thick sections from blocks with a face of 2-5 mm in diameter, containing medullary, cortical and mixed profiles were projected by camera lucida onto the digitizing tablet of a Zeiss Videoplan and traced to give total medullary area as a function of total lobular area. Ten larger tissue blocks of calf thymus (10-15 mm face) embedded in JB-4 methacrylate, sectioned and stained with toluidine blue or hematoxylin and eosin, were analyzed in the same manner.

- 2) Morphometric evaluation of sections stained with toluidine blue were carried out on photographs (1,400X final magnification) of ten



cortical and ten medullary fields from each group of rats and 20 cortical fields and 20 medullary fields from calf thymi, all selected at random. All non-lymphoid cells in each micrograph were counted. Lymphocytes were counted in smaller areas located in the four corners of each photograph and from these data the percentage of non-lymphoid cells was determined for each age group. These micrographs were also used to determine the volume density of lymphoid and non-lymphoid elements by a standard morphometric technique using intersects on a test grid of 100 points laid over each print (Weibel 1973).

3) Blocks of medulla from each group of rats were sectioned for electron microscopy. Each non-lymphoid cell in individual grid spaces of 200 mesh copper grids was counted. At least 100 non-lymphoid cells from each age group were counted and these data were used to derive the total number of non-lymphoid cells per 1000 square microns well as to obtain differential counts of the subtypes of non-lymphoid cells. The subtypes counted included, squamous epithelial cells, identified by the presence of tonofilaments and desmosomes; voluminous or cystic epithelial cells, which also contained tonofilaments but in addition contained cyst-like inclusions with microvilli; interdigitating or Langerhans-like cells, which had a characteristic central concentration of organelles often including Birbeck granules and a peripheral clear area of cytoplasm; and macrophages, which contained dense bodies and internalized remains of lymphocytes within their cytoplasm. Myoid cells, containing myofilaments, were not included because of their relative scarcity.

4) Non-lymphoid cells from at least ten blocks from each age group were analysed morphometrically. In most instances, at least 12 cells from each of the four main cell types were examined from each age group at a magnification of 15,000X. Only cells that appeared to be sectioned centrally were photographed. The volume density of the principal organelles was calculated by standard morphometric techniques with a test grid of 100 points over each 8x10 micrograph. Organelles that occupied less than 5% of the non-nuclear volume in each group were counted but for reasons of scale are not displayed graphically. Statistical significance between data points was determined by the Student's T-test.

## Results

### Medullary volume

Rat thymus from all age groups revealed a demarcation of the organ's lobules into cortical and medullary zones. The neonatal thymus however, was infiltrated more uniformly with lymphocytes than were thymi from the other age groups and so quantitative data for medullary volume were not obtained.

The growth of the rat medulla in relation to the total organ growth is displayed in Table I. It can be seen that as maturation progressed the medullary volume proportionately increased until it occupied approximately 30% of the total organ in the adult. The calf thymic medulla averaged about 15% of the total organ.

## A) Rat

The number of cells per unit area of cortex in the rat increased continuously during the first three or four weeks of age; thereafter it stayed relatively constant (Figure 1). Medullary cellularity increased between the first and eight day but subsequently showed little change (Figure 1).

Lymphoid and non-lymphoid cells could be distinguished by light microscopy, generally on the basis of their nuclear characteristics. Lymphocytes outnumbered non-lymphoid cells in both cortex and medulla for all age groups examined (Figure 2). The percentage of non-lymphoid cells in the cortex decreased during the first two weeks of age but thereafter was constant at about 2%. In contrast, there was little change in the percentage of non-lymphoid cells in the medulla between one and 65 days of age, it was constant at about 12%. The actual numbers of lymphoid and non-lymphoid cells in the cortex and medulla per 1000 square microns were calculated from the values shown in Figures 1 and 2 and are given in Table II.

The volume density of cortical non-lymphoid cells was highest in the neonatal thymus. It decreased significantly during the first two weeks of development ( $p < 0.01$ ) and remained low until after 50 days (Figure 3). By 65 days however, the value was comparable to that during the first week of age. The volume density of lymphoid cells necessarily varied inversely with that of non-lymphoid cells. The volume density of non-lymphoid cells in the medulla remained relatively constant at an average of 33% in all age groups (Fig. 3).

## B) Calf

Cortical and medullary cell counts and volume density data for the calf were more variable than with the rat, presumably because of the different ages of these sub-yearling animals (Table I). The mean values determined for the percentage of non-lymphoid cells in the cortex (3.3%) and medulla (15.5%) and their volume density (6.7% and 39.8% respectively) were generally comparable to those seen in rats after the first weeks of age.

### Medullary differential cell counts by electron microscopy

The four main subtypes of non-lymphoid cells in the thymic medulla were identified by the ultrastructural characteristics depicted in Figures 4-7. Figure 8 displays the percentage of each of these cell types in the developing rat medulla. Epithelial cells containing tonofilaments made up the majority of cells that were identified in the rat medulla especially during the first weeks of age. The percentage of epithelial cells declined from a high of 75% at one day of age to about 52% at 65 days of age. An abrupt drop at 50 days coincided with a relative increase in the percentage of interdigitating cells and macrophages. The percentage of interdigitating cells increased significantly ( $p < 0.05$ ), over its neonatal level of about 10% to a level of about 33% at 50 and 65 days. Macrophages showed a significant increase in numbers ( $p < 0.05$ ) temporarily at 50 days of age but otherwise remained close to 10% of the medullary non-lymphoid cell population. The proportion of cystic epithelial cells increased significantly at 15 and 22 days of age ( $p < 0.05$ ), from a value of about 3-5% before and after that period.

Volume density of cellular organelles of non-lymphoid cell subtypes

There was no change in the volume density of any non-nuclear organelle in epithelial cells (Figure 9a; Table III) and interdigitating cells (Figure 9b; Table IV) during development. However, there was a trend in epithelial cells for the volume density of all organelles to increase with age at the expense of the cell matrix. In contrast, the volume density of several specific organelles and cytoplasmic structures in the other two major subtypes of medullary non-lymphoid cells did change significantly during development (Figures 9c; Table V and Figures 9d; Table VI). Cystic epithelial cells showed progressive increases in the volume density of cysts (Figure 9d; Table VI) and the volume density of cytoplasm occupied by dark inclusion bodies in macrophages decreased significantly until day 22 (Figure 9c; Table V). Since the dark inclusions were homogeneous electron dense bodies or contained the remains of lymphocytes they were considered to be both lysosomes and phagosomes.

## Discussion

The ages selected for analysis of the developing thymus, in the present study were intended to reflect times at which the immunologic role of the thymus might be expected to change. The purpose was to determine whether such changes were accompanied by subtle, yet quantitatively significant, alterations in non-lymphoid cellular morphology. Thus although some T-lymphocyte development occurs prenatally (Owen and Moore 1967), it is in the neonate where the immune system is first

exposed to the environment. T-cell differentiation and non-lymphoid cellular activity might therefore be expected to be prominent at this time. Weaning appears to be the next most critical event, when the animal becomes independent of maternal nutritional and immunologic support. For the rat this occurs at approximately 22 days. The next major change in mammalian immune development occurs during sexual maturation, which is after 65 days in the rat. In the postpubertal mammal, thymic involution commences, cellular immune function begins to wane and therefore non-lymphoid cellular activity may be expected to decline.

The largest concentration of non-lymphoid cells in the thymus is in the medullary zone. The proportion of the rat thymus that is formed by the medulla was found to increase to about 30% at seven weeks of age (Table I). The rate of increase was not even but because of variations in the data significance could not be attached to the increment of increase. Our findings appear to be in disagreement with those of Hwang et al. (1974) who found that the medulla of the rat occupied a constant proportion of about 5% of the organ throughout development. Light microscopic planimetry was used in the present study in distinction to the "measurement of thickness" described by Hwang et al. (1974). Although the difference in technique may be important Hammmar (1921) has emphasized the difficulty of calculating the cortical-medullary 'index' because of the variable nature of the gland and the irregularity of the medulla. The reports of other studies, however, were more consistent with our findings than with those of Hwang et al. (1974). For example,

Leblond and Sainte-Marie (1960) found that the medulla represented 25% of the thymus in a 10 week old rat. Kindered (1940) using a different technique, calculated a value of 22% for the thymic medulla of the 15 day old rat. He did however record a slight drop in volume occupied by the medulla on the twentieth day of age (17%). Boyd (1932) determined that 20-30% of the human thymus was composed of medulla between birth and 15 years of age.

The percentage of medullary non-lymphoid cells (Figure 2) and their volume density (Figure 3) were found to be relatively constant throughout postnatal development. This is in contrast to the data of Hwang et al. (1974) who found the percentage of epithelial cells in the medulla of the rat to fall from 48% at one day old to 29% at 10 days old and rise again to 82% at 75 days. The reason for such a wide discrepancy from the data of the present study is not clear. Our figure of 10-15% is comparable to those of 8%, 7.5% and 9.7% reported by Kindered (1940) for 'reticulum' cells in the thymic medulla of 15, 20 and 80 day old rats respectively. The conclusion to be drawn from the data of the present study is that the number of non-lymphoid cells per unit area of medulla (Table II) changes little with age. Thus the absolute number of these cells increases in proportion to the increase in the size of the medulla.

Consideration of the stromal elements is necessary in volume density measurements of the components of the thymus. Hwang et al. (1974) reported that fibroblasts and vasculature are rarely encountered in the

thymic parenchyma and therefore their calculation of epithelial cell parameters included the connective tissue stroma. Boyd (1932) on the other hand found thymic connective tissue and fat to make up from 20-25% of the human organ between birth and age 15 years. In the present study connective tissue composed an average of 25% of the cortex and 35% of the medulla in all age groups. These values were not included in the calculation of volume density of lymphoid and non-lymphoid cells. Thus the high estimate by Hwang et al. (1974) pertaining to the volume density of the epithelial cells within the thymic medulla might have been due in part to their inclusion of the connective tissue stroma.

The individual development of non-lymphoid cells shown in Fig 8, is to our knowledge the first such differential count. Both Hwang et al. (1974) and Kindered (1940) grouped the non-lymphoid cells together as 'epithelial cells' and 'reticulum cells' respectively. The data presented here show significant changes in the relative proportion of individual cell types especially after weaning. As might be expected the neonatal thymus is predominantly epithelial. Interdigitating cells, considered to be of bone marrow origin (Balfour et al. 1981) progressively increase in relative as well as absolute numbers. Presumably the increase is the result of a continuous migration from the circulatory system into the medulla of the thymus. The relative percentage of medullary macrophages showed some fluctuation, but no clear trend was evident.



How and why the number and volume density of non-lymphoid cells, especially of the epithelial cell, change during development is not understood. Epithelial cells may differentiate along several pathways. Stem cells in the medulla may be the source of stellate cells that form the cortical cytotreticulum (Mandel 1968). Other medullary epithelial cells may increase their synthesis of tonofilaments to such an extent that they become filled with plaques of keratin. Hassall's corpuscles are the end products of differentiation along this line. Still other medullary epithelial cells, the so-called voluminous or hypertrophic cells, accumulate glycosaminoglycans within vacuoles in their cytoplasm. These vesicles eventually expand and coalesce to form microvillous cystic structures (Figure 7). Pfoch (1971) reported that 'clear vesicles' seen in the newborn were absent from the 13 week old rat. He also suggested that the decrease in vesicular content with advancing age coincided with secretion levels of humoral thymic factor. However, these structures are unlikely to secrete a thymic hormone, as histochemical analysis (Clark 1973, Caso 1979) has shown the content of the cysts to be PAS positive and therefore probably a glycosaminoglycan. The glycosaminoglycan product from these cells may have an effect on T-cell differentiation in the medulla, by 'covering-up' cell surface antigens in the maturing thymocyte (personal communication J. Sharp). Indeed, Hoessli et al. (1980) showed that T-cell differentiation is accompanied by an increase in the sialic acid content of theta antigen. Hirokawa (1977) states that microvillous vesicles are present in the newborn

thymic medullary epithelium while rarely seen after one month of age. In the present study, the changes in cystic volume density (Fig. 7) reveal a steady dilation of these structures at least until sexual maturity. These findings are in agreement with those of Mandel (1970) who observed only a few voluminous epithelial cells in the prenatal mouse thymus, while these same cells were more numerous and had larger vesicular profiles in the thymus of the 52 day old mouse.

The information contained in Figure 9 provides a quantitative base for the differences in the main subtypes of non-lymphoid cells. Apart from the steady increase in the volume density of cysts in the voluminous cells with age, and the transient decrease in the volume density of dark inclusions in the medullary macrophage, no obvious changes in the organelles of other cells were detected. Certainly there were no structural correlates of secretory activity that varied with the expected levels of thymic hormone secretion (Pahwa et al. 1979). This finding is in keeping with the qualitative observations of this and other studies, that cells revealing classic characteristics of protein hormone secretion are rare in the thymic medulla. This in no way denies the endocrine role for non-lymphoid cells in T-cell differentiation. A unique form of local hormonal or paracrine secretion may be operating. The immunohistologic evidence (Goldstein 1975, Mandi and Glant 1973, Teodorczyk et al. 1975, van den Tweel et al. 1978, Higley in press). so far available indicates that epithelial cells do in fact contain various thymic factors. How these proteins are active in the intrathymic milieu remains to be elucidated.

## Summary

Thymic non-lymphoid cells have been shown to influence the differentiation of T-lymphocytes. A morphometric analysis of these cells identified changes in absolute number and volume density during thymic development in the rat. The thymic medulla has a larger percentage of non-lymphoid cells than the cortex, so medullary cells were of particular interest. The expansion of the thymic medullary volume with age was documented by planimetry. Several subtypes of non-lymphoid cell were identified by electron microscopy, including both squamous and cystic epithelial cells, interdigitating cells and macrophages. Changes in their relative proportion were determined. Subcellular evidence of secretory activity was sought by analysis of the volume density of organelles in each of the non-lymphoid cell classes.

TABLE I

Medullary Volume as a Percentage of Total Thymic Volume

Age(days)	Medullary Volume (%)	Number of samples*
Rat 8	12.7	18
15	13.6	9
22	22.3	21
36	15.8	25
50	30.7	20
65	31.0	18
Calf	14.7	45

\* #of medullary profiles

Table II

Day	Cortex		Medulla	
	#non-Ly	#Lys	#non-Ly	#Lys
1	2.27	33.98	2.47	20.3
8	1.3	42.7	3.25	29.25
15	0.66	52.33	3.3	29.7
22	1.47	57.5	4.3	26.93
36	1.52	59.47	4.8	27.2
50	1.1	53.9	3.43	24.06
65	1.25	54.47	3.63	30.1

(Numbers are cells per 1000 square microns)

(non-Ly= non-lymphoid cells)

(Lys= lymphocytes)

## Legend

Fig. 1 Total cell counts per 1000 sq microns in the cortex and medulla of the developing rat thymus. (mean  $\pm$  SEM), \*-p<0.05, \*\*-p<0.01 (when compared to neonatal values).

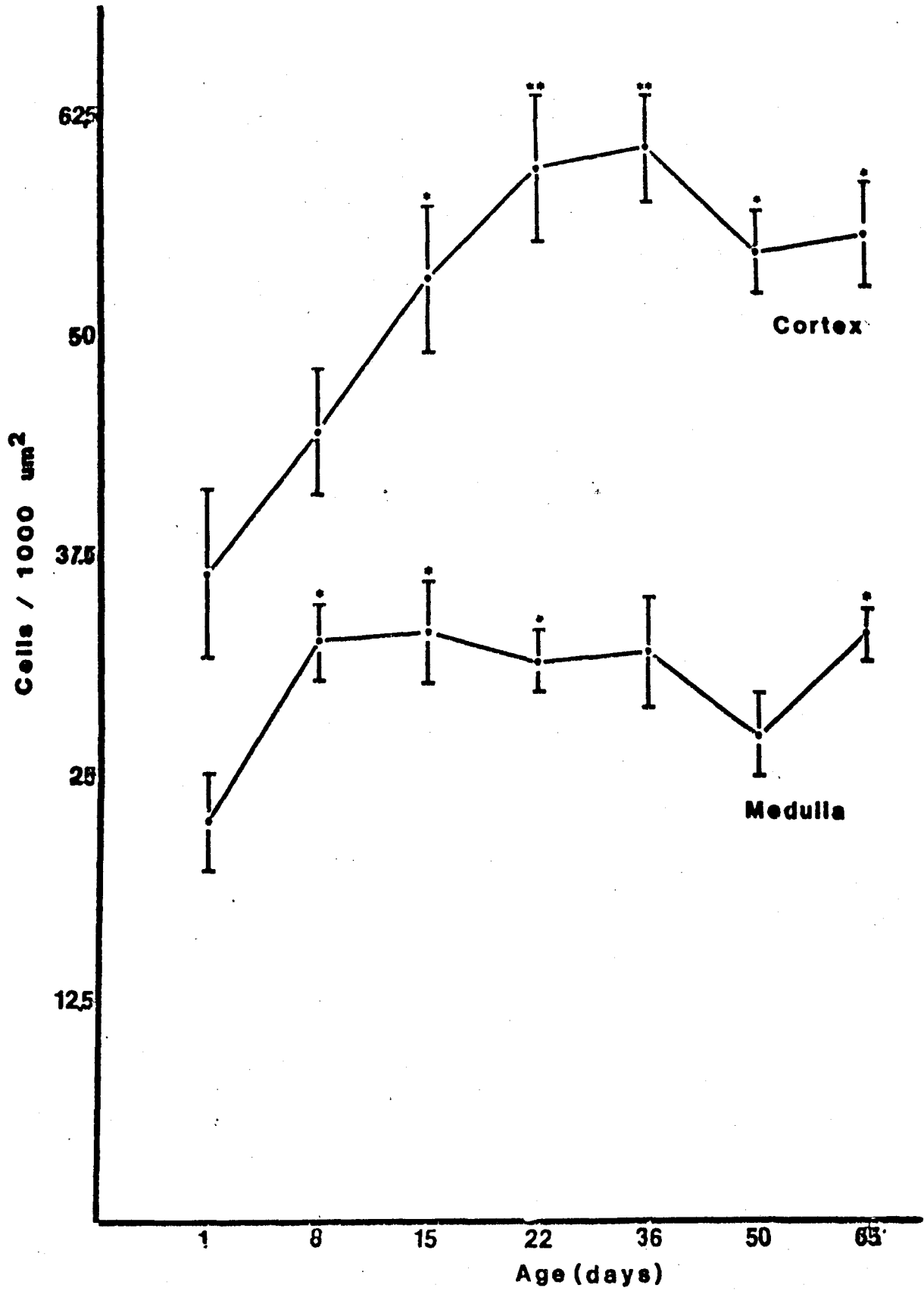


Fig. 2 Percentage of non-lymphoid cells in the rat of different ages. (mean  $\pm$  SEM), \*-p<0.01 (when compared to neonatal values).

Fig. 3 Volume density of non-lymphoid cells in the rat thymus at different ages. (mean  $\pm$  SEM), \*-p<0.05 compared to day 1, \*\*-p<0.01 compared to day 1, \*\*\*-p<0.005 compared to day 8.



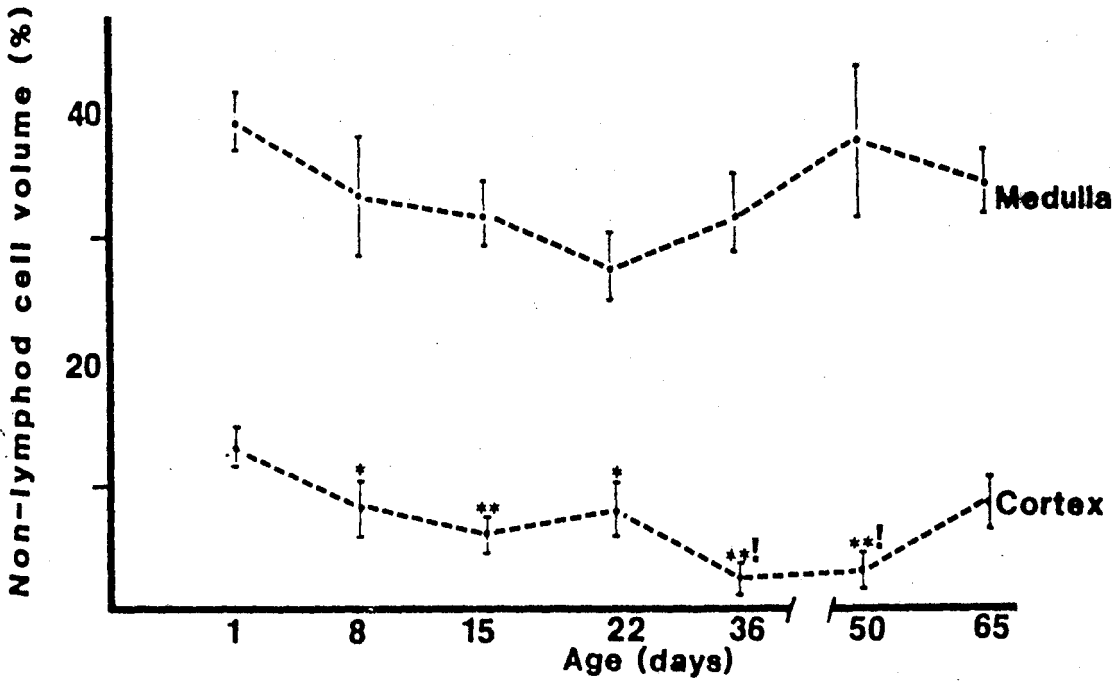
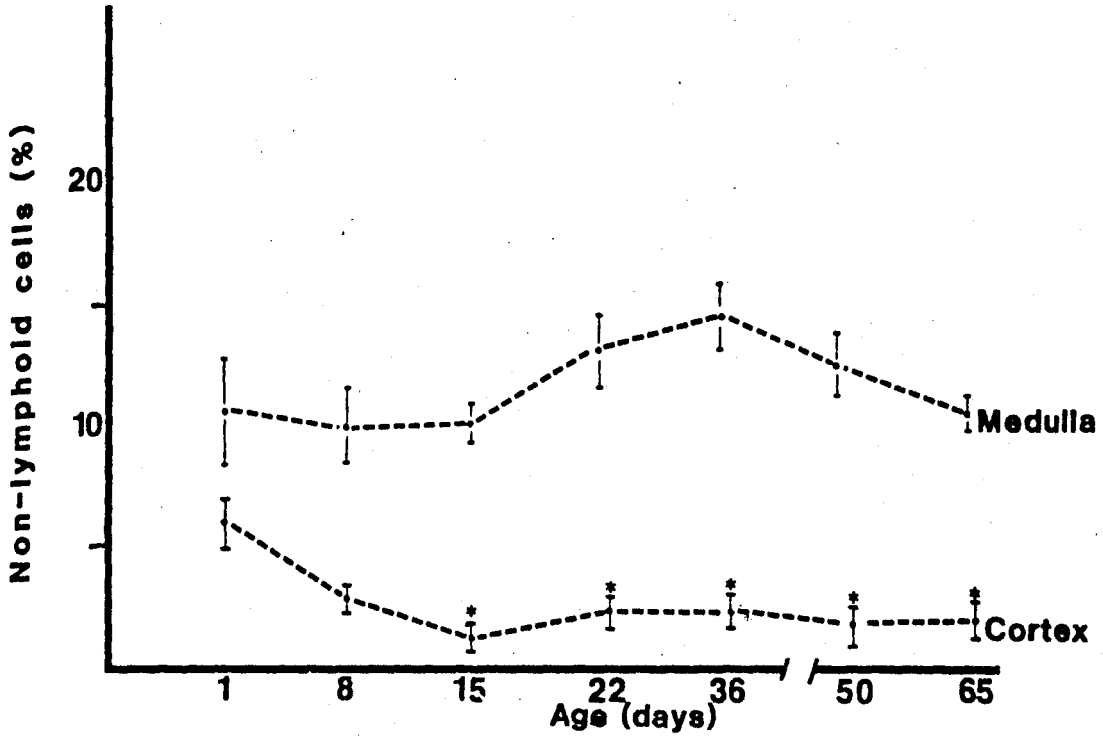


Fig. 4 Electron micrograph of part of a thymic medullary epithelial cell depicting the characteristic tonofilaments (t). Nucleus (n). (10,250X).

Fig. 5 Electron micrograph of part of an interdigitating or thymic Langerhans-like cell showing the concentration of organelles close to the nucleus. (8,500X).

Fig. 6 Electron micrograph of part of a thymic medullary macrophage containing phagocytosed lymphocytes. (9,750X).

Fig. 7 Electron micrograph of part of a medullary epithelial hypertrophic cell containing a microvillous cyst. (10,000X).

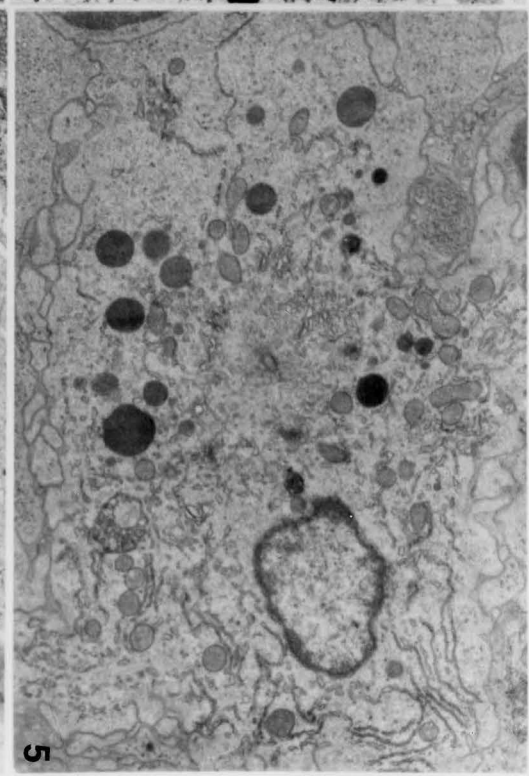
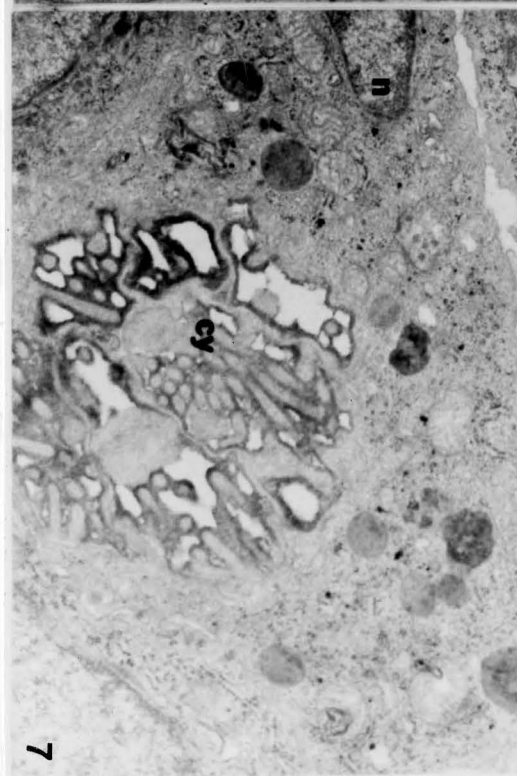
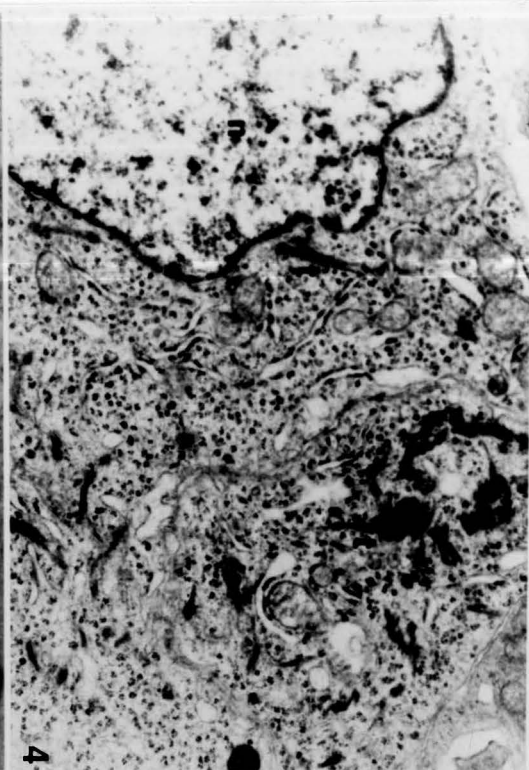
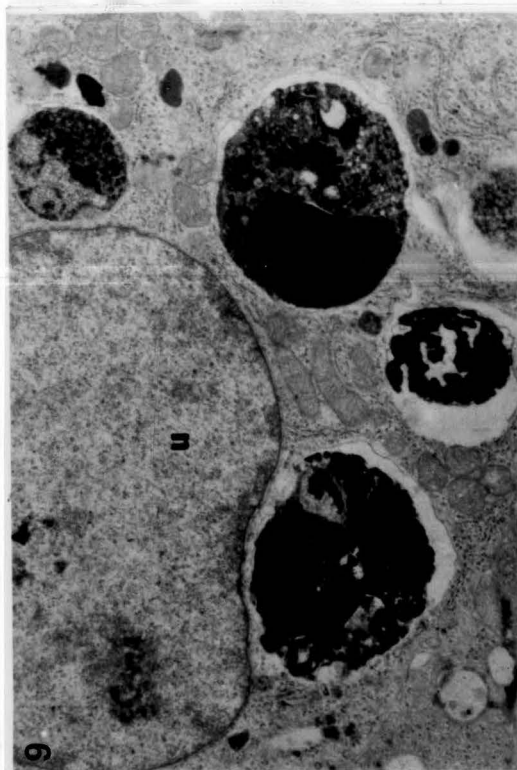


Fig. 8 Proportion of the four main subtypes of non-lymphoid cells in the medulla of the rat thymus at different ages. (mean  $\pm$  SEM).

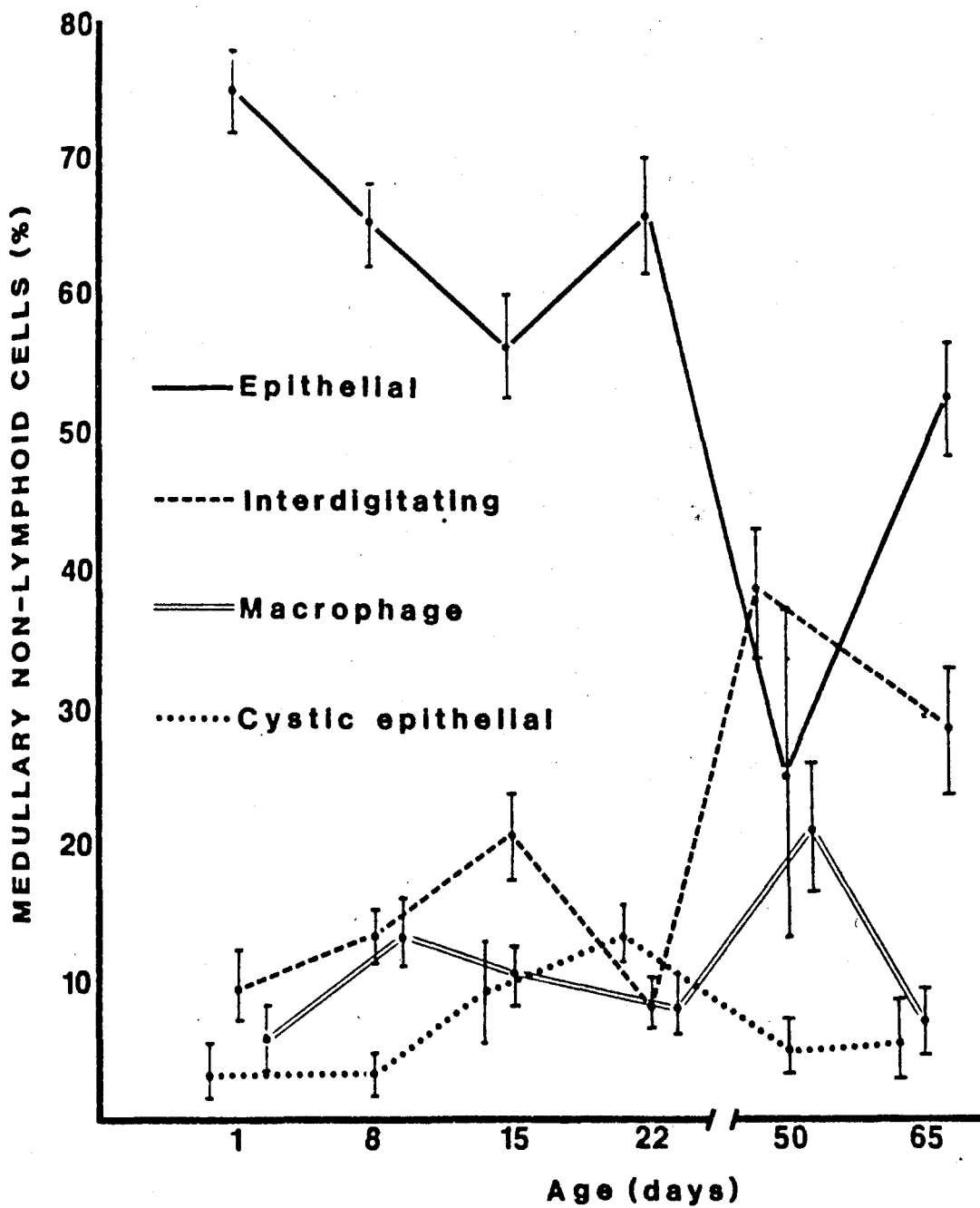
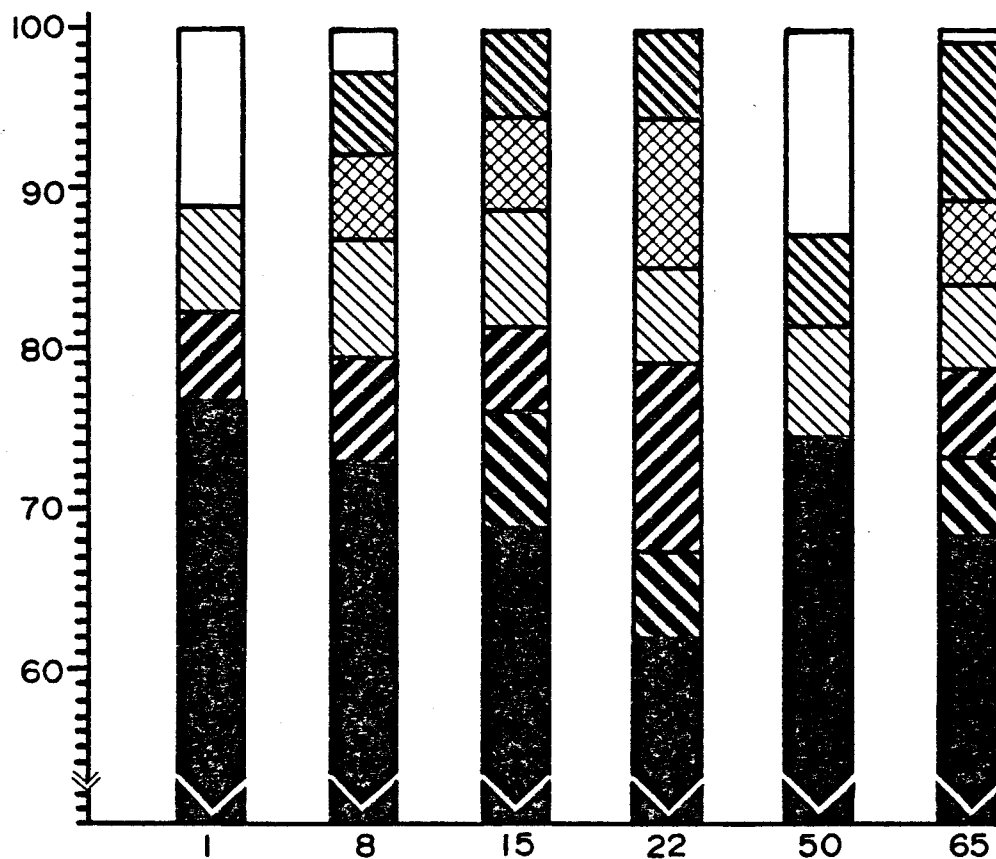


Fig. 9 Volume density of principal non-nuclear cellular components in 4 types of thymic non-lymphoid cells. The unshaded part of the top of several columns represents organelles that comprised less than 5% of the non-nuclear cytoplasm of the cells. a) epithelial cells b) Langerhans-like or interdigitating cells c) macrophages d) cystic epithelial cells. \*  $p < 0.05$ , \*\*  $p < 0.01$  (as compared to day 8).

# EPITHELIAL CELL

VOL %



LEGEND:

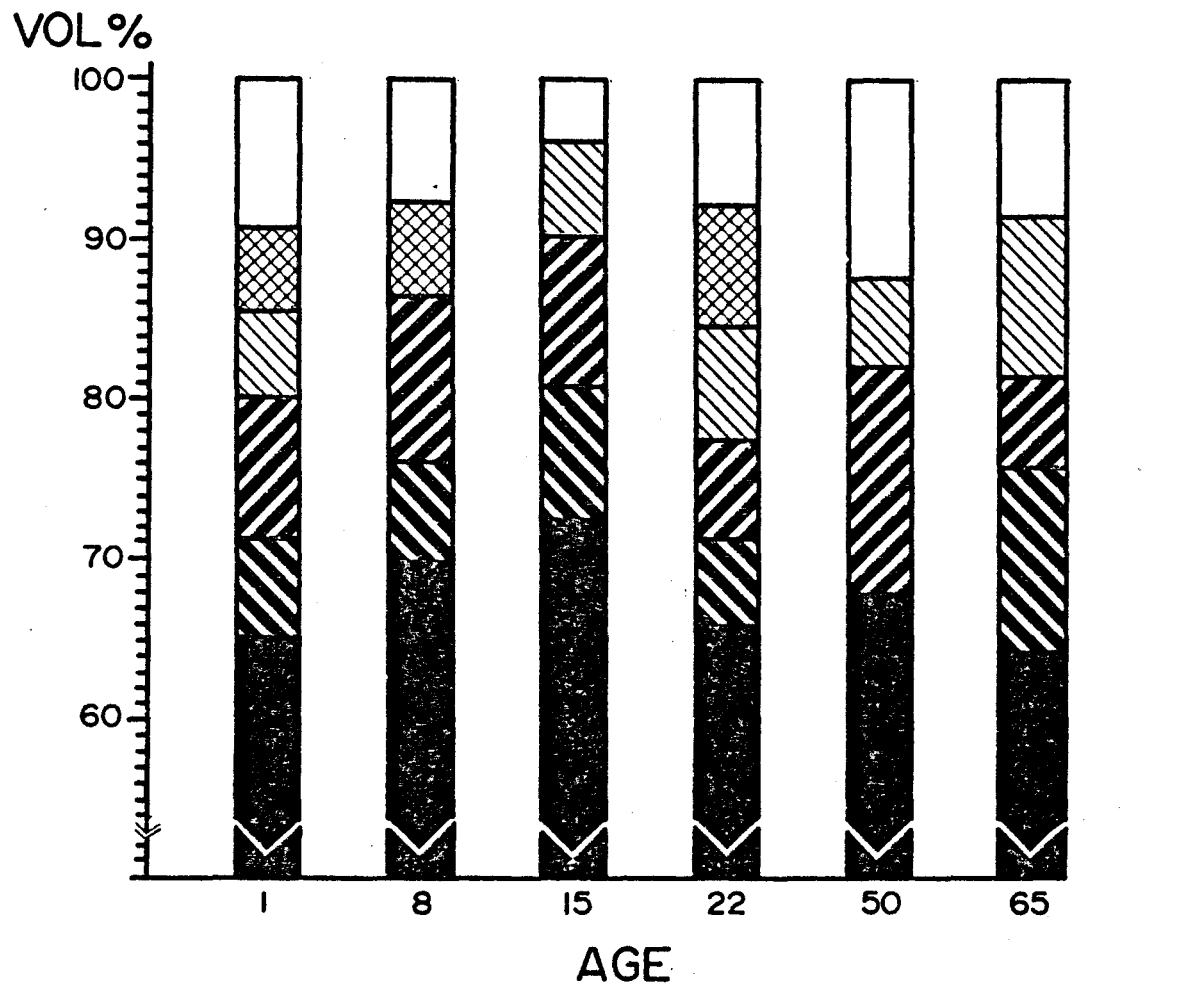
 CYTOPLASM  
 ROUGH ER

 DARK INCLUSION  
 MITOCHONDRIA

 GOLGI & VESICLES  
 TONOFILAMENTS

 OTHERS

# INTERDIGITATING CELL



LEGEND:

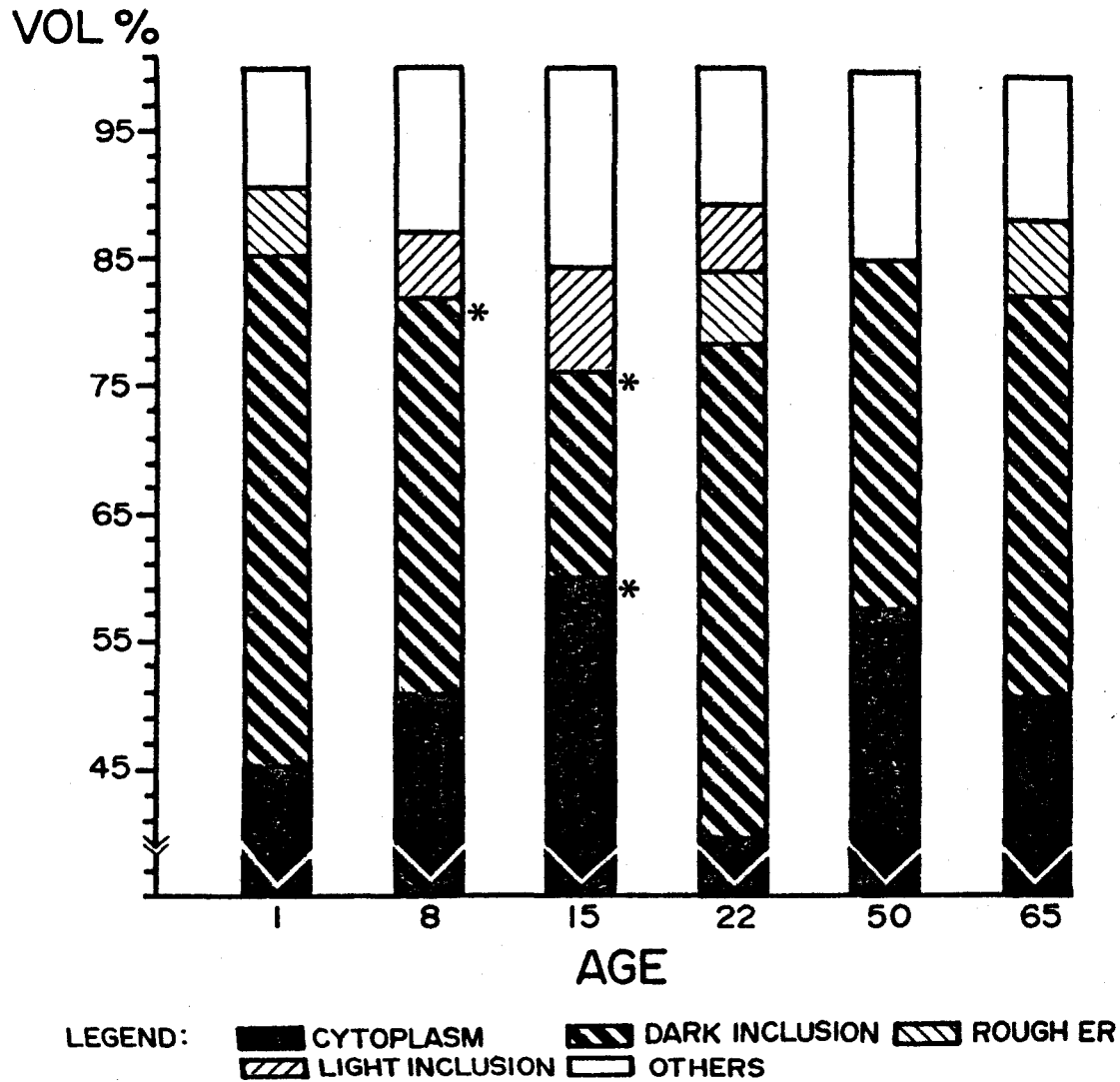
■ CYTOPLASM  
 ▨ ROUGH ER

▩ DARK INCLUSION  
 ▤ MITOCHONDRIA

▧ GOLGI & VESICLES  
 □ OTHERS

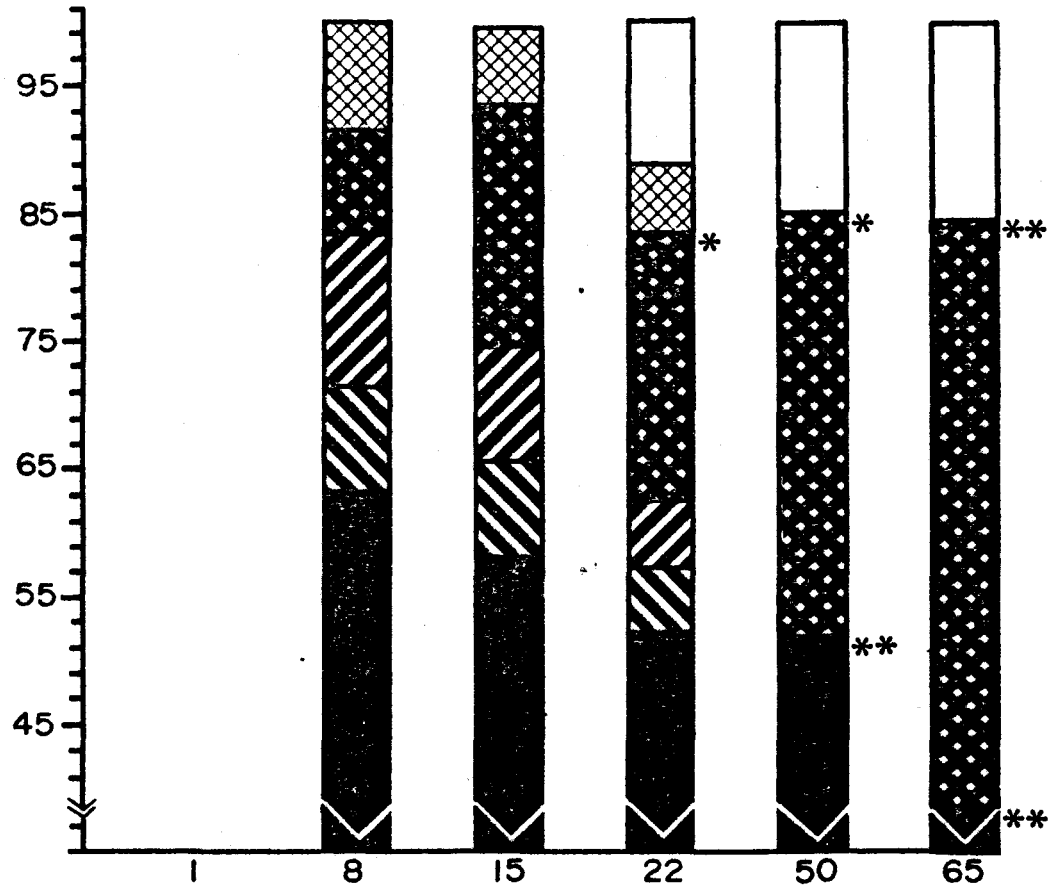


## MACROPHAGE



## CYSTIC EPITHELIAL CELL

VOL %



LEGEND:

■ CYTOPLASM  
 ● CYST

▨ DARK INCLUSION  
 ⊠ MITOCHONDRIA

▨ GOLGI & VESICLES  
 □ OTHERS

Table III  
 Volume Density (as %) of Organelles of  
 Rat Thymic Epithelial Cells During Development

Age(days)	Cyto	Dk Inc	G&V	Mito	RER	Tono
1	76.5+2.0	< 5.0	5.8+2.2	< 5.0	6.5+1.7	< 5.0
8	72.8+2.4	< 5.0	6.6+2.5	5.4+1.6	7.4+1.7	5.0+2.3
15	68.5+2.7	7.6+1.1	5.2+2.6	5.8+2.7	7.4+2.5	5.7+1.8
22	61.5+2.7	5.9+1.7	11.7+2.7	9.3+1.5	5.9+1.3	5.6+2.0
50	74.3+4.1	< 5.0	< 5.0	< 5.0	7.2+1.1	5.7+3.2
65	68.1+6.7	5.1+3.2	5.5+1.8	5.4+2.1	5.2+2.2	9.7+4.6

(Cyto=cytosol, Dk Inc=dark inclusions, G&V=Golgi and vesicles

Mito=mitochondria, RER=rough endoplasmic reticulum, Tono=tonofilaments)

Table IV  
 Volume Density (as %) of Organelles of Rat  
 Thymic Interdigitating Cells During Development

Age(days)	Cyto	Dk Inc	G&V	Mito	RER
1	65.1+3.6	6.2+2.8	8.8+1.6	9.2+2.4	5.3+1.7
8	69.7+3.7	6.5+2.5	10.3+2.4	5.9+1.6	< 5.0
15	72.4+5.1	8.5+2.1	9.4+2.9	< 5.0	5.8+1.2
22	65.8+3.0	5.6+2.1	6.0+2.2	7.5+2.1	7.3+1.8
50	67.8+6.3	< 5.0	14.2+6.8	< 5.0	5.7+1.8
65	64.1+3.9	11.8+3.1	5.6+2.8	< 5.0	10.1+3.7

(Cyto=cytosol, Dk Inc=dark inclusions, G&V=Golgi and vesicles

Mito=mitochondria, RER=rough endoplasmic reticulum)

Table V  
 Volume Density (as %) of Organelles of Rat  
 Thymic Macrophages During Development

Age(days)	Cyto	Dk Inc	Lt Inc	G&V	Mito	RER
1	45.0+5.3	40.4+7.1	< 5.0	< 5.0	< 5.0	5.2+2.3
8	50.6+5.0	31.1+5.6	5.0+3.5	< 5.0	< 5.0	< 5.0
15	59.9+5.5	16.3+1.6	8.1+4.8	< 5.0	< 5.0	< 5.0
22	39.3+6.6	39.0+11.0	5.2+1.7	< 5.0	< 5.0	5.8+2.6
50	57.4+3.5	27.6+5.2	< 5.0	< 5.0	< 5.0	< 5.0
65	50.5+3.4	31.7+4.9	< 5.0	< 5.0	< 5.0	6.0+1.8

(Cyto=cytosol, Dk Inc=dark inclusions, G&V=Golgi and vesicles

Mito=mitochondria, RER=rough endoplasmic reticulum,

Lt Inc=light inclusions)

Table VI

Volume Density (as %) of Organelles of Rat  
Thymic Cystic Epithelial Cells During Development

Age(days)	Cyto	Dk Inc	G&V	Mito	Cyst
8	64.4+1.8	8.5+1.1	12.0+2.1	9.3+3.2	9.1+2.8
15	57.9+5.1	7.8+5.2	8.8+5.1	6.0+2.7	19.0+5.5
22	52.1+3.7	5.3+2.8	5.1+1.2	5.4+1.9	20.9+9.3
50	51.5+2.7	< 5.0	< 5.0	< 5.0	33.6+4.0
65	37.5+1.9	< 5.0	< 5.0	< 5.0	46.9+4.4

(Cyto=cytosol, Dk Inc=dark inclusions, G&V=Golgi and vesicles

Mito=mitochondria, Cyst=microvillous cyst)

## CHAPTER II

### THYMIC INTERDIGITATING-RETICULUM CELLS

#### Introduction

A form of non-lymphoid cell present in the mammalian thymus as well as the spleen and lymph node has been called by several names including, mesenchymal-histiocytic cell (van Haelst 1969), interdigitating-reticulum cell (Veldman 1970, Lennert et al. 1978, Klug and Mayer 1979, Von Gaudecker et al. 1980, Duijvestijn and Hoefsmit 1981). and special or oval cell (Olah et al. 1968, Bennett 1978). The cell has been found to have several morphologic, histochemical and immunochemical features in common with the Langerhans cell of the skin (Thorbecke et al. 1980). For example, both cells contain the characteristic cytoplasmic inclusion, the Birbeck granule (Birbeck et al. 1951). Also, Ia antigen and Fc receptors have been reported on the the epidermal Langerhans cell and on the interdigitating-reticulum cell of the mammalian thymus (Hoffman-Fezer et al. 1978, Rowden et al. 1977, Rouse et al. 1979, Balfour et al. 1981). Amino peptidase, non-specific-esterase, and 5'-nucleosidase reactivity have also been demonstrated as common enzymatic features of these cell types (Muller-Hermelink et al. 1974).

The recent demonstration of so-called 'dendritic antigen-presenting cells' in various lymphoid organs by Steinman et al. (1978,1979) has

raised questions on the relationship between these cells and cells of the macrophage series. Morphologic and functional assays of such cells isolated from spleen, lymph nodes and thymi suggest that the antigen-presenting dendritic cells may be the equivalent of the interdigitating cells of the thymus (Steinman et al. 1980). Furthermore, although such cells may represent only a small percentage of the total macrophage population of lymphoid organs, they may function in the control of a number of important immune phenomena, such as antigen presentation (Steinman et al. 1980). The inclusion of the interdigitating cell as a macrophage may not be justified because of its comparative lack of phagocytic capacity. Nevertheless, the proposal that the interdigitating-reticulum cell of the lymphoid tissue and the epidermal Langerhans cell have a common bone marrow origin in the form of a blood-borne monocyte or macrophage precursor has been supported by a number of authors (Katz et al. 1979).

The intent of the investigation reported here was to examine the interdigitating cell and the macrophage population of the thymus, using four different markers—two for interdigitating cells and two for conventional macrophages. Magnesium-dependent adenosine triphosphatase (ATPase) staining, a histochemical technique that readily distinguishes Langerhans cells from epidermal keratinocytes (Juhlin and Shelley 1977), was employed in the identification of Langerhans-like cells in thymic tissue. Because enzyme expression may be species and age specific (Smith 1961), thymi from two animal species (rat and calf) and several age groups (rat) were examined.



S-100 is an acidic protein once thought to be restricted to the nervous system as a component of glial cell cytoplasm (Moore et al. 1968). Recent investigations (Cocchia et al. 1981, Takahashi et al. 1981) have shown that this antigen also occurs in epidermal Langerhans cells and in the related interdigitating-reticulum cells of the lymph node. Accordingly, immunocytochemical techniques were used in the present study to examine the human thymus for cells that contain this protein. Coupled with these light microscopic studies, ultrastructural confirmation of thymic cells morphologically similar to Langerhans cells was performed.

The study also employed immunohistochemical and cytochemical staining for two lysosomal enzymes (acid phosphatase and lysozyme) that are strongly associated with phagocytic cells.

## Materials and Methods

Thymic tissue from rat and calf was examined by light and electron microscopy. Thirty-six Sprague-Dawley rats were sacrificed and thymi obtained from one day old animals, animals 1,2,3,5 weeks of age, and adults (65 days). Six samples of calf thymus were obtained at a local slaughter house from animals less than one year old. Human thymic tissue was obtained at autopsy from an infant that had died of a congenital heart defect. The following histochemical procedures were carried out:

Adenosine Triphosphatase (ATPase) reaction. Tissues from the rat and calf were frozen in a cryostat at -20 degrees C and 10 micron-thick sections were cut and then air dried on glass slides. ATPase activity

was assessed by the method of Wachstein and Meisel (1957). The sections were fixed for 5 minutes in 10% formalin in cacodylate buffer, and then rinsed in buffer before incubation in a reaction mixture of 125mg/ml adenosine triphosphate, 2% lead nitrate and 0.1M MgSO<sub>4</sub> in Tris maleate buffer (pH 7.4) for 1-2 hours at room temperature. Sections were again rinsed and then immersed in a dilute solution of ammonium sulfide for 1 minute, rinsed, mounted in glycerine and examined. Control slides were incubated in the presence of 0.25mM cysteine, an inhibitor of non-specific alkaline phosphatase activity (Padykula and Herman 1955).

Acid phosphatase. Parallel sections were stained for acid phosphatase using the method of Gomori (1956). Sections were incubated in a substrate of 3% sodium B-glycerophosphate, 0.12 g lead nitrate in sodium acetate buffer (pH 5.0) for 4 hours at 37 degrees C. Slides were then rinsed in buffer and immersed in a dilute solution of ammonium sulfide for 1 minute, rinsed, mounted in glycerine and examined. Control reactions consisted of elimination of the B-glycerolphosphate from the preparation.

S-100 and Lysozyme. Human thymus was fixed in either 10% buffered formalin or Bouin's solution and embedded in paraffin. Five micron-thick sections were mounted on glue-coated slides and heated to 60 degrees C for 30 minutes before being deparaffinized in two changes of xylene. The sections were then rehydrated and treated with 3% hydrogen peroxide to eliminate endogenous peroxidase activity and then exposed to a 0.125% solution of trypsin in calcium chloride buffer for 5-10 minutes. This

treatment exposed antigenic sites inactivated during fixation and greatly enhanced the staining reaction for S-100. The slides were then washed for 15 minutes in phosphate buffered saline (PBS) and exposed to the immunocytochemical staining sequence, as follows. Rabbit antibody to calf brain S-100 protein (kindly provided by Dr. S Pfeiffer) or human lysozyme (rabbit anti-muramidase from Immulok, Carpenteria, Calif.) was applied to sections for 1 hour at room temperature at a dilution of 1:10 in PBS. Slides were then washed in three changes of PBS. Two different reagents were used in the indirect procedure. Slides were incubated with either FITC or peroxidase-labeled goat anti-rabbit IgG for 30 minutes at room temperature. Slides were again rinsed in three changes of PBS. FITC preparations were mounted in glycerine and viewed by ultraviolet illumination on a Nikon Ultraphot microscope with barrier filter (650-440 nm) and exciter filter (BG12 or UG1) combination. Peroxidase preparations were developed with 0.05% diaminobenzidine-0.01% hydrogen peroxide or 0.05% ethylaminocarbazol-0.1% hydrogen peroxide substrate and then viewed by bright-field microscopy.

Control reactions consisted of deletion of the primary antiserum, or substitution of normal rabbit serum for the specific immune sera.

Electron microscopy Thymic tissue from both rat and calf was fixed for 2 hours in 4% phosphate buffered glutaraldehyde (pH 7.6) at 4 degrees C, post-fixed in 2% osmium tetroxide for 1 hour, then dehydrated in a graded ethanol series and embedded in Epon 812. One micron thick-sections were stained with toluidine blue. Thin sections were mounted on

200 mesh copper grids and contrast was enhanced with uranyl acetate and lead citrate. Grids were then examined using a Hitachi HU-IIB electron microscope.

## Results

### ATPase Activity

A brown reaction product delineated ATPase reactive structures in both the rat and calf thymus (Figures 1 and 2). Cysteine added to the incubation medium caused no diminution of the staining reaction, indicating that true ATPase was demonstrated. In the rat, cellular ATPase reactivity was restricted to medullary fields in all ages examined (Figure 2). Although the medulla increased in size in maturity, the numbers of cells that stained intensely for ATPase did not appear to change with age. The reaction was often so intense as to obscure the individual cell boundaries, but where they could be distinguished, the positive cells were seen to be dendritic in form with long processes radiating away from the cell center. This was a cell surface reaction. In addition to the staining of dendritic cells, staining of blood vessels was also seen in both cortex and medulla.

ATPase reactivity was differently distributed in the calf thymus. Reactive cells with a dendritic pattern were not found in the medulla, although they were prominent in the calf cortex (Figure 1). These ATPase positive cells were more sparsely distributed than in the rat medulla. Medullary ATPase staining in the calf was restricted to epithelial cell aggregates (Hassall's corpuscles) and to the vasculature.

Acid phosphatase staining in both species was largely confined to the cortex and was particularly prominent in a band of granular reactive cells at the cortico-medullary boundary (Figure 3). However, some diffuse staining for acid phosphatase was seen in Hassall's corpuscles in the calf medulla. Deletion of the B-glycerophosphate from the reaction mixture eliminated these deposits. In the cortex, acid phosphatase positive cells were evenly distributed and their staining was punctate and restricted to inclusion bodies which were presumed to be lysosomes. In the rat thymus of all ages, the only area that contained both acid phosphatase and ATPase positive cells was the cortico-medullary boundary. Parallel sections of calf thymus were stained by the two histochemical procedures and it was concluded that each procedure displayed a different population of cells.

S-100 and Lysozyme

Indirect immunofluorescence and immunoperoxidase staining of infant human thymus revealed S-100 positive cells restricted to medullary areas of the gland. These cells were dendritic in outline (Figure 4 and 5) and sparsely distributed throughout the medulla. Both Hassall's corpuscles and lymphoid elements were negative for this antigen, but glial components of myelinated nerves in thymic connective tissue trabeculae were strongly positive. Analysis of parallel sections stained for the presence of lysozyme demonstrated a different population of cells restricted to the thymic cortex and some medullary Hassall's corpuscles (Figure 6). This staining pattern was punctate in appearance, quite different from the pattern of S-100 reactivity.

### Ultrastructural Observations

Electron microscopic examination of the rat thymic medulla showed interdigitating or Langerhans-like cells in various forms as well as 'conventional' macrophages (Figures 7,8 and 9). Typically, the Langerhans-like cell exhibited a lobulated, often eccentric euchromatic nucleus. The cytoplasm was characteristically divided into an organelle-rich 'cytocytrium' and an organelle-poor or 'clear' ectoplasmic periphery. The cytocytrium was often present near the nucleus and consisted of a collection of dense bodies, mitochondria and other organelles organized around a centriole from which radiated arrays of microtubules. These cells also displayed a highly convoluted plasma membrane with an electron-dense extracellular matrix between the interdigitations. Cellular processes were seen between the surrounding lymphocytes often at some distance from the cell body. No pyknotic lymphocyte nuclei were seen in the cytoplasm of these cells.

In contrast, ultrastructural evidence of phagocytosis was observed in macrophages that were present in large numbers at the rat cortico-medullary border and in the rat cortex (Figure 9). These cells contained numerous remains of thymocytes within their cytoplasm. Various other dense bodies, stacks of rough endoplasmic reticulum and occasional Golgi bodies were also present in these cells, but no organization of their cytoplasm into a cytocytrium and a 'clear' ectoplasmic zone was seen. Macrophages were also seen in the calf cortical and cortico-medullary zone and were comparable to the examples seen in the rat.

Only interdigitating cells contained Birbeck granules. These rod-like inclusions exhibited a central electron-dense line and cross-striations of a regular periodicity (Inset Figure 10). Although not present in every plane of section, these granules were usually in the region of the cytocentrum but some examples were found in the peripheral cytoplasm. The shape of the interdigitating cells in the rat thymic medulla ranged from roughly spherical forms seen most commonly in samples of tissue from the youngest animals to highly dendritic types in older thymi (Figures 10 and 11).

In the calf cortex, interdigitating cells were more difficult to locate by electron microscopy, owing to their sparse distribution, but those seen appeared to be identical in all respects to those cells examined in the rat thymic medulla.

## Discussion

In the present investigation two classes of immune accessory cells have been displayed histochemically and immunocytochemically in parallel sections of mammalian thymus. It is proposed that the cells which showed acid phosphatase and lysozyme activity corresponded to the 'conventional' macrophages, while the presence of S-100 protein and ATPase activity delineated thymic interdigitating cells. The two cell types were also recognized by their ultrastructural appearance. Although the evidence was suggestive that the surface staining pattern associated with ATPase histochemistry and the cytoplasmic S-100 immunoreactivity was limited to cells which ultrastructurally conformed to the interdigi-

tating or Langerhans-like cell, it was not conclusive since any one cell could not be viewed by both light and electron microscopy.

The literature on the cytochemical staining patterns of various cells included in the mononuclear phagocyte system, while containing areas of dispute, suggests a subdivision into actively phagocytic and poorly phagocytic types. While Langerhans cells in the epidermis (Wolf 1967) and interdigitating cells in peripheral lymphoid organs (Muller-Hermelink et al. 1974) have been shown to contain low amounts of acid phosphatase, macrophages seen in the spleen and peritoneal exudates contain large quantities (Steinman et al. 1979, Eikelenbloom 1978). The cytochemical studies are supported by ultrastructural studies which illustrate the paucity of dense single membrane-limited organelles typical of lysosomes in Langerhans cells or interdigitating cells (Steinman et al. 1979, Rausch et al. 1977, Thorbecke 1980, Hoefschmit 1975). The data concerning surface ATPase staining patterns is less certain. Although this has been a reliable marker for Langerhans cells (Wolf 1967, Juhlin and Shelly 1977) and is present on interdigitating cells (Muller-Hermelink et al. 1974), the cells isolated from the mouse spleen by Steinman et al. (1979), that appear to be of a similar lineage, have not yet been shown to express the enzyme. Whether this reflects problems in isolation and preservation of activity, or delineates a further subpopulation of cells is not at present known. Similarly there is uncertainty about the presence of ATPase staining on the surface of macrophages (Eikelenbloom 1978).



The ATPase reactivity of the calf thymus, to our knowledge, has not been described before. The pattern of staining for this enzyme was reported for murine thymus by Smith (1961). She indicated that in the 4-5 week old and 8-11 month C57B1/6 mouse thymus the medulla was more reactive for ATPase than the cortex. The positive cells were described as oval medullary cells, with no mention of dendritic forms. In the AKR mouse thymus, a strain susceptible to leukemia, the ATPase staining was highly variable and was not confined to either the cortex or medulla; positive cells were scattered throughout the lobule. Smith (1961) demonstrated strain differences in the distribution of acid phosphatase positive cells in the thymus of C57B1/6 mice as compared to AKR mice. She showed acid phosphatase reactive cells restricted to the cortex of AKR mice. C57B1/6 mice showed reactive cells in the medulla, the same area that showed the highest concentration of ATPase positive cells.

The relationship of the thymic interdigitating cell to the epidermal Langerhans cell was not appreciated until Olah et al. (1968) described the ultrastructure of the rat thymic medullary special cell that had an appearance similar to the cell of the skin. While the function of this cell in the thymus is at present unclear, several roles have been postulated. Keratinization is a process unique to the thymus among lymphoid organs, and it has been suggested that the thymic Langerhans-like cell as well as its equivalent in the epidermis may be involved in keratin formation (Silberberg-Sinakin et al. 1980) Antigen trapping and presentation are a more likely function and have been shown

for the dendritic-reticular cell of the lymph node and spleen (Mitchel and Abbot 1965, Veerman and Rooijen 1975) as well as for the epidermal Langerhans cell. In conflict with this view is the fact that the thymic medulla is not generally thought of as a site for antigen processing.

The lack of acid phosphatase staining of interdigitating cells, when examined by light microscopy, suggests that the dense bodies seen ultrastructurally are either too sparse to reveal a positive reaction or are indeed not lysosomes. Some authors suggest that these inclusions may be secretory in nature, (Gery and Waksman 1972) and that thymic interdigitating cells could thereby influence T-cell differentiation.

As shown in the present study, both acid phosphatase positive and ATPase positive cells share the cortical zone in the calf. In the rat the presence of ATPase positive cells and acid phosphatase positive cells in two different compartments may be a species difference. It presumably reflects the migratory patterns of interdigitating cells as compared to conventional macrophages. Whether some rat interdigitating cells may move to the thymic cortex later in life, as implied by their distribution in the calf, remains to be demonstrated. Transit through the thymus for the epidermal Langerhans cell seems to be unnecessary, as they can be found in the skin of the athymic nude mouse (Hunter et al. 1976). The thymic resident interdigitating cell may enter the organ through the medulla during prenatal life as suggested by the restriction of ATPase staining to the rat medulla even in the earliest ages examined. If true, this route of entry is the opposite of the lymphoid pre-

cursor cells which are thought to start their passage through the thymus at the cortical surface and then pass into the medulla before leaving the gland.

The electron microscopic appearance of a spherical form of interdigitating cell, most frequently seen in the early examples of rat thymus, may represent the immature form of this cell. Such a theory is consistent with the evidence from the skin where a variation in the morphologic appearance of Langerhans cells has been seen in normal and traumatized samples (Wolf 1972). It has been proposed that relatively adendritic cells in the basal layer of the epidermis may represent new immigrants from the bone marrow stem cell pool. Such indeterminate cells (Zechckson and Mottaz 1968) often do not show Birbeck granules in their cytoplasm although they have clearly been related to the mature Langerhans cells by surface Ia-antigen activity (Rowden et al. 1979).

S-100 a 20,000 MW protein, so-called because of its solubility in 100% saturated ammonium sulfate, is widely distributed in different animal species. Long known to be present in astrocytes and oligodendroglia of the central nervous system, Schwann cells of the peripheral nervous system and satellite cells of the sympathetic ganglia (Lundwin et al. 1976, Eng et al. 1976), S-100 content correlates well with the degree of maturation of the nervous system, but its exact function remains obscure.

Recently a number of seemingly unrelated cell types have been shown to contain this protein. These cells include melanocytes and mela-

noma cells (both in situ or from cultured lines), Langerhans cells of the epidermis, interdigitating-reticulum cells from the peripheral lymphoid tissue, and chondrocytes of both mesenchymal and neuroectodermal derivation (Cocchia et al. 1981, Takahashi et al. 1981, Gaynor et al. 1980, Steffanson et al. 1982). S-100 is thought to be a calcium binding protein related to calmodulin and troponin C but whether the protein functions in a similar manner in such disparate cell types is not known. Alternatively, all the cells that have this marker protein may be more closely related to neuroectoderm than previously thought. It has been suggested that complete thymic function is dependent on the developmental inclusion of a neuroectodermal component into the thymic stroma (Jenkinson et al. 1981). The finding of S-100 protein in human thymic dendritic cells strengthens the postulate that these cells are related to interdigitating-reticular cells in other lymphoid organs.

#### Summary.

An investigation of the interdigitating cells and conventional macrophages of the thymus was carried out in the rat, calf and human. Cytochemical staining for surface adenosine triphosphatase (ATPase) and for lysosomal acid phosphatase illustrated two distinct populations of cells with different distribution patterns in the cortex and medulla of the thymus of the rat and calf. Immunohistochemical staining for S-100 protein and lysozyme delineated two cell populations in the human thymus. Electron microscopic observations of the thymic regions containing the interdigitating cell population confirmed similarities between these

cells, other lymphoid interdigitating reticulum cells (IDC) and the epidermal Langerhans cells.

## Legend

Fig. 1 Frozen section calf thymus (400X). ATPase reaction prominent in cortex (c), absent in medulla (m). Inset-High power ATPase positive cortical dendritic cell.

Fig. 2 Frozen section 15 day old rat thymus (530X). ATPase reaction most prevalent in medulla (m), cortical reaction (c) restricted to the vasculature.

Fig. 3 Frozen section calf thymus (1,900X). Acid phosphatase reaction delineates cortico- medullary boundary macrophages. Cortex (c), medulla (m).

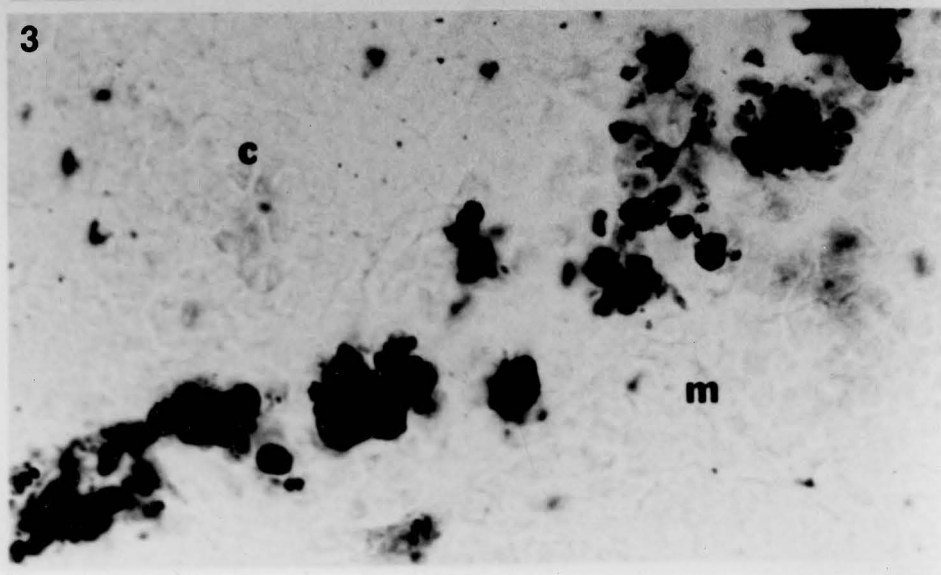
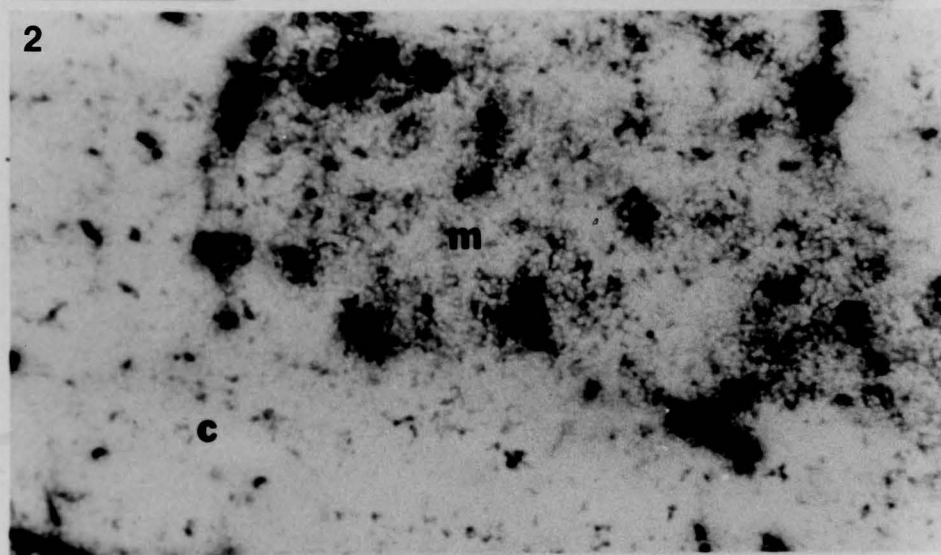
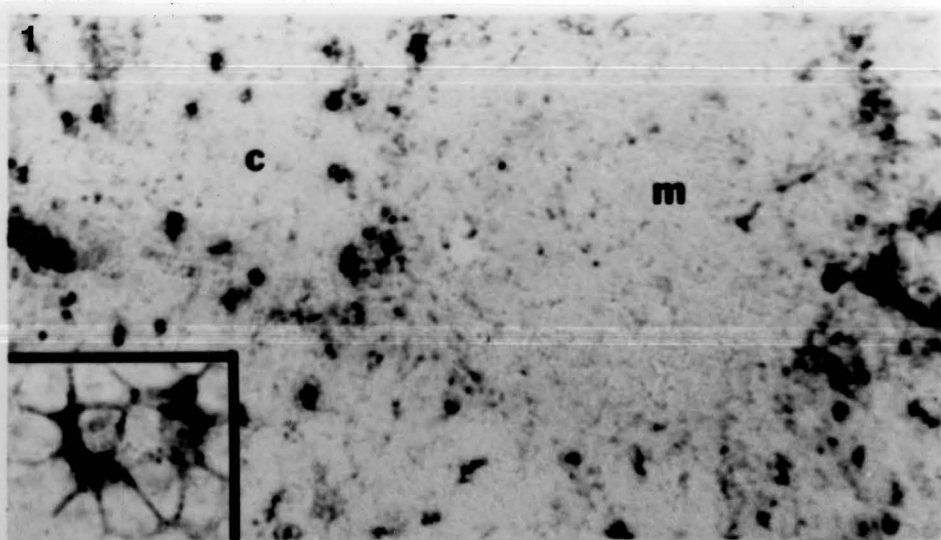


Fig. 4 Human thymus stained for S-100 (200X). Trypsinized paraffin section, indirect immunoperoxidase. (c) cortex, (m) medulla, arrows- reactive dendritic cells.

Fig. 5 Human thymus stained for S-100 (950X). Reactive dendritic cells in medulla. (c) cortex, (H) unstained Hassall's corpuscles. arrows-interdigitating cells.

Fig. 6 Human thymus stained for lysozyme (200X). Parallel paraffin section, indirect immunoperoxidase. (c) cortex, (m) medulla. Reactive macrophages can be seen in the cortex and in some Hassall's corpuscles.



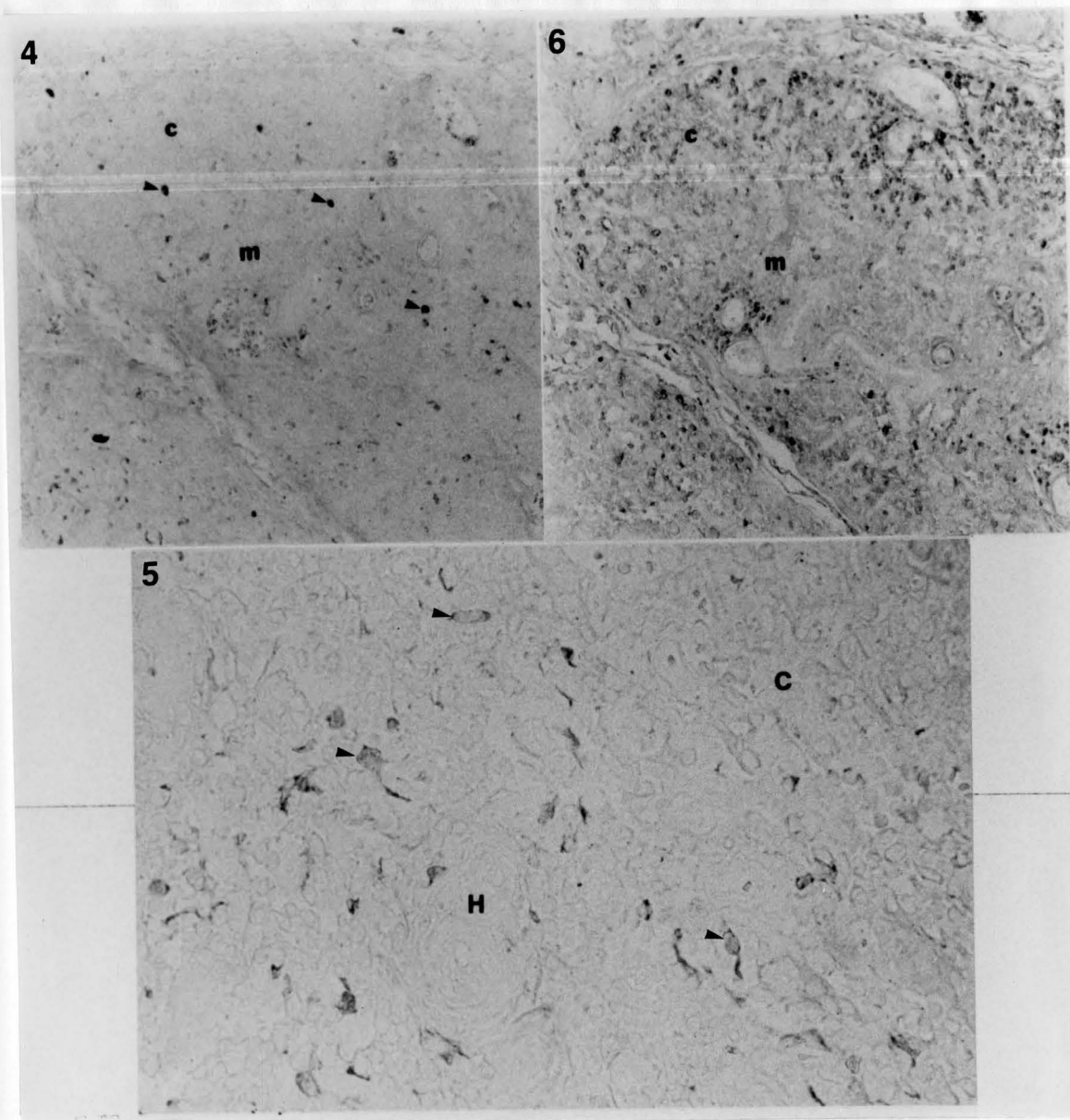
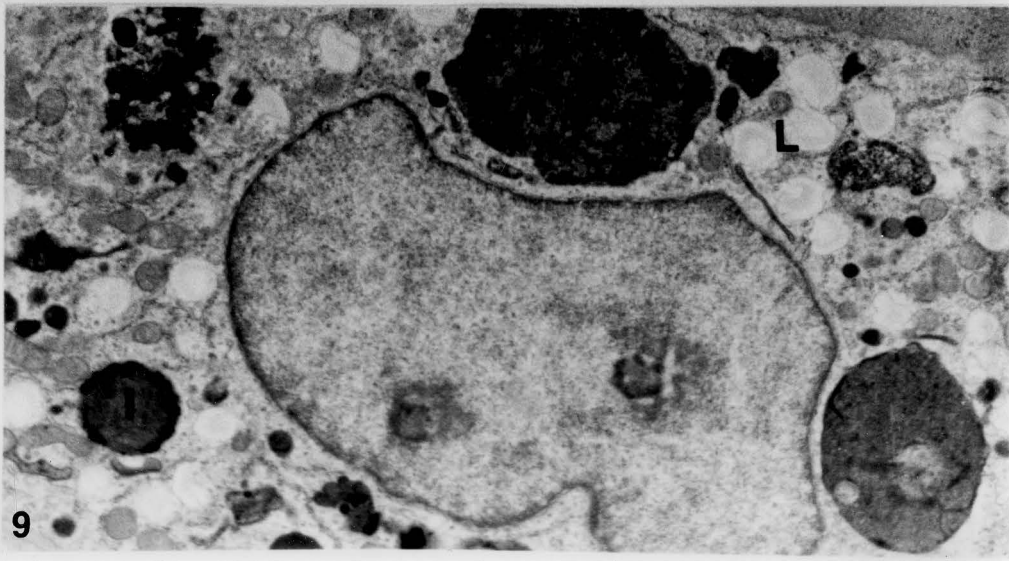
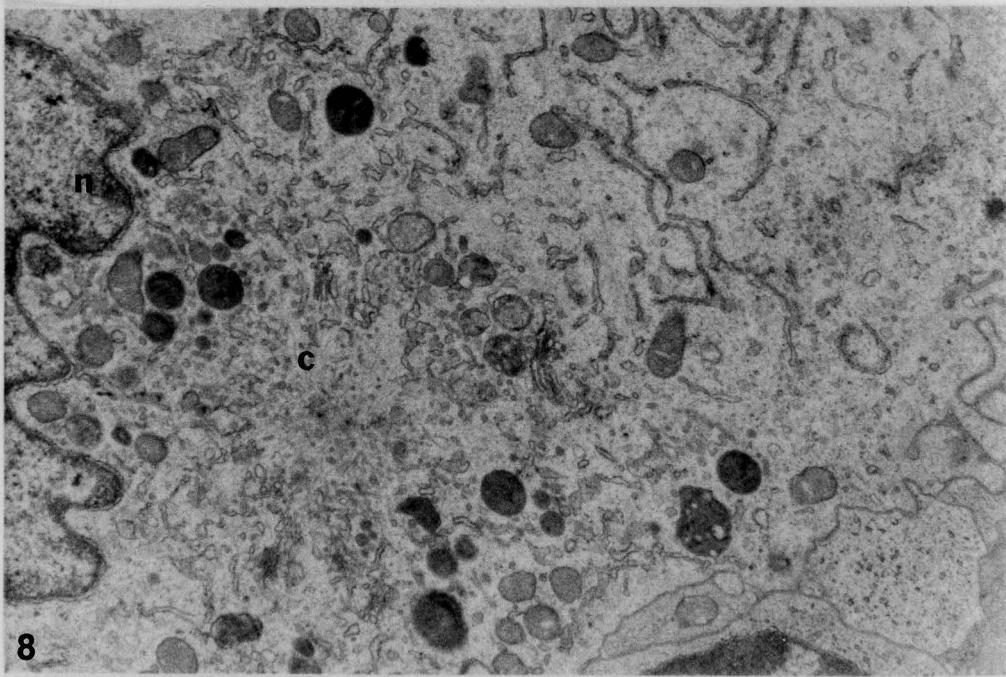
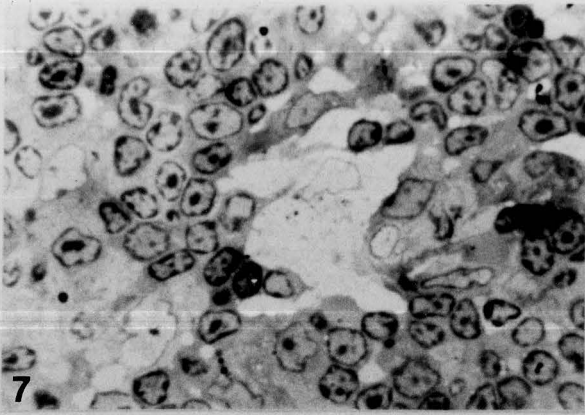


Fig. 7 One micron toluidine blue section of rat thymic interdigitating cell. (1,000X).

Fig. 8 Electron micrograph of adult rat thymic medulla.(19,250x). Region of the cytocentrum (c) of the interdigitating cell showing accumulation of dense bodies and mitochondria. (n-nucleus).

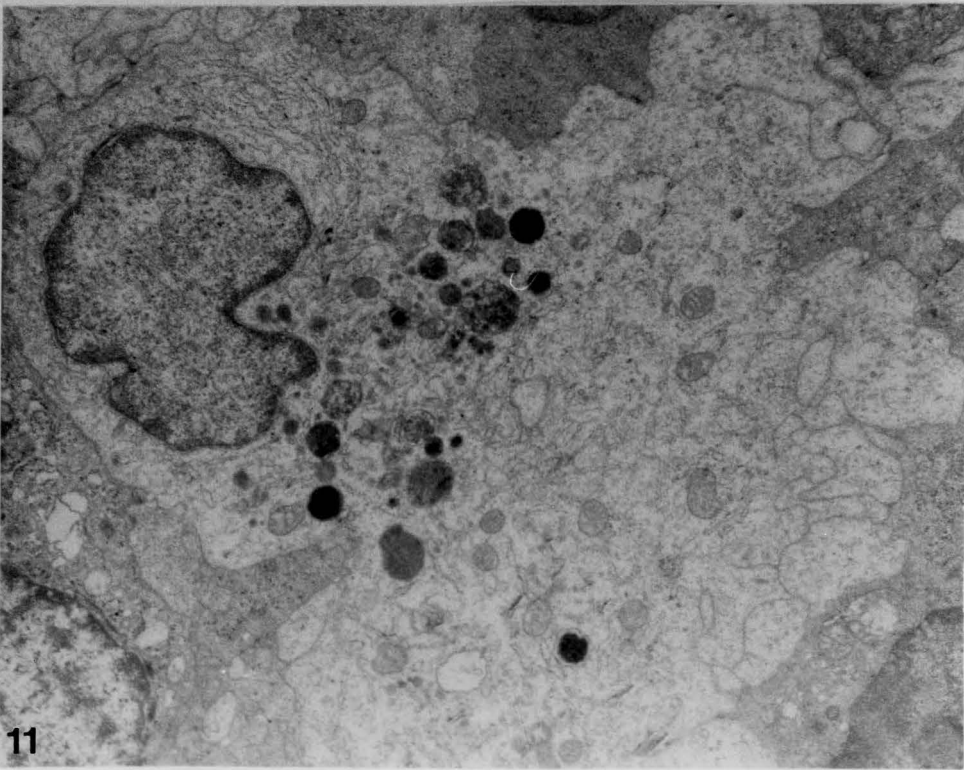
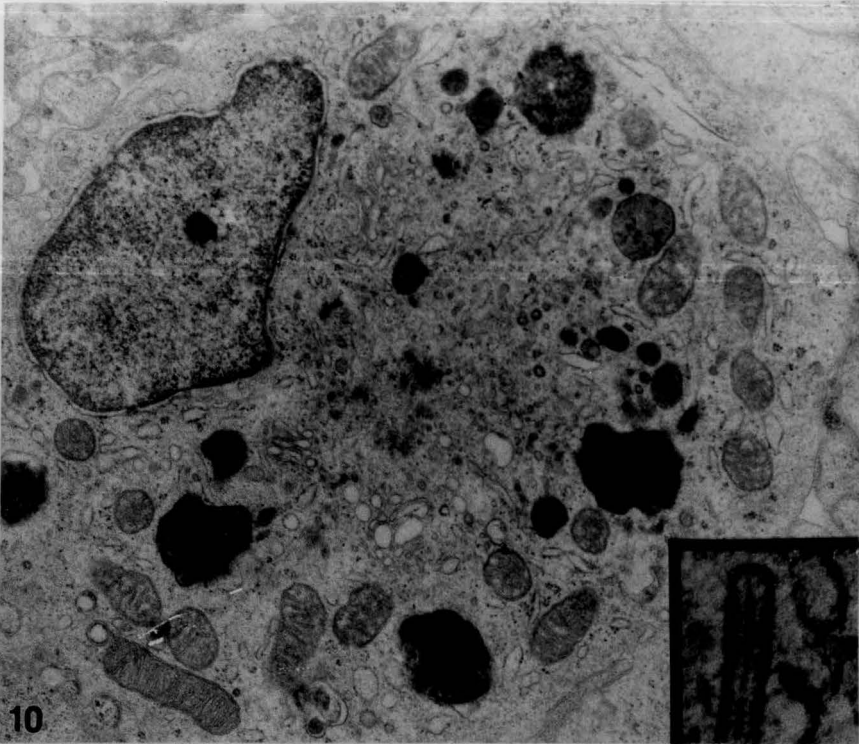
Fig. 9 Electron micrograph of macrophage from adult rat cortex. (8,500X). Note electron dense inclusions (i) and electron lucent lipid droplets (L).



...ating  
...dium  
...old rat

Fig. 10 Electron micrograph of non-dendritic form of interdigitating cell from neonatal rat thymic medulla. (7,260X). Inset-Birbeck granule (43,290X).

Fig. 11 Electron micrograph of interdigitating cell from 15 day old rat thymic medulla. (3,220X). Note cytoplasmic extensions.



in the  
- folds  
are so  
are in  
- cyto  
1972)  
- ribos.  
forms  
of and  
as of  
- pro-  
- ribo-  
- that  
(196),  
- ribo-  
- ribo-  
- gated

CHAPTER III  
THYMIC MYOID CELLS

Introduction

Myoid cells have been demonstrated at one stage or another in the development of the thymus of all species examined so far (Van de Velde and Friedman 1970, Toro et al. 1969, Strauss et al. 1966) They are so named because of the myofilaments that they contain. In man they are in evidence in both fetal and adult life (van der Geld et al. 1964, Bockman 1968, Puchtler et al. 1975, Bearman et al. 1978, Henry 1966, 1968, 1972) Whereas in some mammals they may appear only in the mature individual. Two forms have been described, elongate and ovoid. The elongated forms are more common and better developed in reptiles and birds (Raviola and Raviola 1967, Gilmore and Bridges 1974) and in fetal thymi (Strauss et al. 1966, van de Velde and Freidman 1970) while the ovoid forms predominate in postnatal mammals. Their function is as obscure as their developmental appearance is variable. Some authors have speculated that these cells may be actively contractile in some species (Pensa 1904), perhaps expressing lymphocytes from the thymus. Others have considered these cells to be vestigial structures (Paneth 1887). Raviola and Raviola (1967) have postulated that the myoid cell and the thymic epithelial-reticular cell may be of common origin. It has even been suggested

that the myoid cell may be part of the tissue 'library' maintained by the thymus for the instruction of tolerance in developing lymphocytes (Burnet 1962). The ultrastructural features of the myoid cell provide little information on its function.

Puchtler et al. (1975) has postulated that myo-epithelial elements are associated with Hassall's corpuscles. Multicellular Hassall's corpuscles are made up of concentric arrays of epithelial-reticular cells often reaching 100 microns or more in diameter and are readily recognizable (Kater 1971). In some species however, Hassall's corpuscles often consist of only a few epithelial lamellae wrapped around a large central hypertrophic or voluminous epithelial cell. These forms are difficult to distinguish from myoid cells at the light microscopic level, and it is only the presence of tonofilaments, as seen by electron microscopy, that identifies them as epithelial derivatives.

In the present investigation, thymic tissue from the rat and the calf was examined ultrastructurally. A cytochemical technique, specific for acetylcholinesterase (AChE) (Lewis and Schute 1966), was also used in the present study to identify myoid cells in the calf thymus. Myoid cell staining by the periodic acid-Schiff reaction (PAS) was compared to the PAS staining of simple Hassall's corpuscles in both the calf and human. Finally, immunocytochemical techniques were used to examine the human and calf thymus for keratin and myoglobin, two marker proteins for epithelial and muscle cells.

Electron microscopy. Thirty-six thymi were obtained from Sprague-Dawley rats at weekly intervals from birth to weaning and then at two week intervals until nine weeks of age. Some tissue was processed for electron microscopy by fixation in 4% glutaraldehyde, post-fixation in 1% osmium tetroxide, dehydration in a graded ethanol series and embedding in Epon 812. Six calf thymi from animals less than a year old were obtained from a local slaughter house and samples were processed in an identical manner.

Acetylcholinesterase. A histochemical reaction for acetylcholinesterase was performed on parallel samples of calf thymus using the method of Lewis and Schute (1966). For this reaction fixation was accomplished in 2% glutaraldehyde in cacodylate buffer (pH 7.5) for 2 hours. The tissue was rinsed overnight in buffer at 4 degrees C, and then incubated in a mixture of 8mM acetylthiocholine iodide, 12mM copper sulfate and 17mM glycine (pH 4.8) for 2-6 hours. The tissue was again rinsed in buffer and transferred to a solution of buffered sodium sulfate (pH 5.4) for 15 minutes. The tissue was rinsed in buffer a final time, 12-18 hours at 4 degrees C and then processed for electron microscopy. Eserine sulfate (8mM) added to the reaction mixture served as a control (Koelle 1950).

Periodic acid Schiff reaction (PAS). Human and calf thymus was also fixed with 10% buffered formalin and embedded in glycol methacrylate (JB-4, Polysciences) or paraffin, cut at 3-7 microns and stained with toluidine blue or by the PAS reaction. For this staining reaction



sections were incubated with 1% periodic acid, washed in distilled water and then treated with Schiff reagent (decolorized Basic Fuchsin) for one hour for paraffin sections or 2-3 hours for methacrylate sections. Sections were washed again and treated with 0.5% sodium metabisulfite. Some slides were counterstained with hematoxylin. This procedure displayed glycoproteins, glycosaminoglycans and glycogen (Lillie 1951). Control reactions were carried out with elimination of the periodate oxidation procedure.

Immunocytochemistry Thymic tissue from one human infant and six calves was fixed in either 10% buffered formalin or Bouin's solution and embedded in paraffin. Five micron thick sections were mounted on glued slides and heated to 60 degrees C for 30 minutes before being deparaffinized in two changes of xylene. The sections were then rehydrated, treated with 3% hydrogen peroxide to eliminate endogenous peroxidase activity and exposed to a 0.125% solution of trypsin in calcium chloride buffer for 5-10 minutes. This treatment exposed antigenic sites inactivated during fixation and greatly enhanced the staining reaction. The slides were then washed for 15 minutes in phosphate buffered saline (PBS) and exposed to the immunocytochemical staining sequence.

Rabbit antibody to human callus keratin (kindly provided by Dr. K Sheikh) was prepared according to the method of Tien-Sun et al. (1979) and applied to sections for 1 hour at room temperature at a dilution of 1:20 in PBS. Slides were then washed in three changes of PBS and then incubated with peroxidase-labeled goat anti-rabbit IgG for 30 minutes at

room temperature. Slides were again rinsed in three changes of PBS. The preparations were then developed in a 0.05% ethylamino-carbazol-0.1% hydrogen peroxide substrate for 10 minutes and viewed by bright field microscopy.

A second antigen, human myoglobin (rabbit antibody from Immunlok, Carpinteria, Calif.) was immunocytochemically localized by identical methods on parallel sections of the same human thymus.

## Results

Probable myoid cells could be seen in the toluidine blue stained one micron thick sections, as large cells with a circular to oval profile, averaging 30 microns in diameter (Figure 1). Confirmation of myofilaments by electron microscopy was necessary however, for an unequivocal identification of these cells (Figure 2). Both light and dark forms of probable myoid cells were seen in toluidine blue stained sections of the calf thymus (Figure 3). Ultrastructural examination of these cells revealed one type had an eccentric heterochromatic nucleus and a disorganized array of myofilaments possibly representing the dark cell (Figure 4). The myofilaments were quite distinct in size and configuration from the tonofilaments seen in epithelial-reticular cells. The other type of myoid cell had a more centrally placed euchromatic nucleus and myofilaments that were more regularly arranged in recognizable bundles of thin filaments divided into sarcomere-like regions by periodic cross-bars of Z-band-like material (Figure 5). Other cytoplasmic features of these cells included occasional mitochondria, a Golgi complex,

as well as a few inclusions of intermediate electron density. Polyribosomes and glycogen granules were found in the cytoplasm between myofibril bundles. This may have been the ultrastructural equivalent of the light cell. None of the myoid cells were seen to be connected by desmosomes to any thymic epithelial cells.

Two forms of myoid cell were seen in PAS stained methacrylate sections. Both PAS positive and negative cells could be demonstrated although the exact nature of the PAS positive material was unknown.

Both types of myoid cell, as identified by the preceding criteria, were a common feature of the calf thymic medulla. In contrast, none of the sections taken from rat thymi of the neonate to the age of weaning revealed any myoid cells. A few well differentiated or light forms were seen in the adult rat thymus but never in the numbers observed in the calf thymus. Neither species at the ages selected exhibited any elongated myoid cells, but a single example of an elongated myoid cell was seen by light microscopy in the infant human thymus.

Electron microscopic observation of histochemically reacted calf thymic tissue, revealed acetylcholinesterase specific electron dense deposits over the nuclear envelope and cytoplasmic inclusions of myoid cells (Figure 6). Acetylcholinesterase was also close to or in the plasma membrane of myoid cells (Figure 7). This reaction was blocked in tissues treated with eserine sulfate. Occasional examples of acetylcholinesterase positive inclusions were seen in the cytoplasm of cells that contained no myofilaments (Figures 8 and 9). The presence of des-

mosomes on some of the membranes of these cells indicated that they may have been epithelial-reticular cells. Although myelinated nerves were seen in the thymic capsule of the rat, no nerve endings were seen near the myoid cells of either species.

In both the rat and calf, structures that were similar in appearance to ovoid myoid cells at the light microscopic level were revealed by electron microscopic examination to be simple Hassall's corpuscles (Figure 10 ) by the presence of tonofilaments and kerato-hyaline granules in their cytoplasm, rather than myofilaments. These simple Hassall's corpuscles consisted of a central hypertrophic epithelial cell surrounded by a few epithelial lamellae. PAS staining of these structures generally showed only a spotty or focal reaction product rather than the uniform positive or negative staining exhibited by the myoid cells. The simple Hassall's corpuscles were more common in the rat thymus, whereas the multicellular forms, made up of several concentric lamellae of epithelial cells, were more often seen in the calf and human thymus (Figures 11).

Immunostaining of human thymus with antibodies to myoglobin revealed isolated cells in the medulla that contained reaction product. There was no reaction in the calf thymus for the anti-human myoglobin, indicating no interspecies cross-reactivity for this protein.

Hassall's corpuscles in the calf and the human contained immunocytochemically detectible keratins, while none of the myoid cells stained with the anti-keratin antibodies. Only the peripheral epithelial cells

in the corpuscles were keratin positive (Figure 12); the central lamellae were keratin negative. The PAS reaction gave the opposite pattern with the center of the corpuscle intensely positive while the surrounding epithelium contained none of this material (Figure 13).

## Discussion

This study shows that myoid cells are a regular feature of the thymic medulla of three species and that they are quite distinct morphologically and histochemically from thymic epithelium and the cells that form Hassall's corpuscles. The appearance of myoid cells in fetal or early life in most mammalian species had led some investigators to speculate that they were only embryonic remnants of branchial arch musculature that later degenerated (Paneth 1887). In the present study, myoid cells were found in the rat thymus only in the adult, a finding that seems to argue against the concept that these cells are vestigial, at least for this species.

Calf thymus has been examined for myoid cells by Strauss et al. (1966) who noted elongated forms of this cell type in fetal tissue and only the ovoid form in postnatal calves. The present study suggests that cells which stain with PAS may include the ovoid form of myoid cell. Van de Velde and Friedman (1970) utilized the Bodian-silver method and PAS to delineate myoid elements in several species, but did not report how ovoid cells reacted with the stains. Henry (1966) used phosphotungstic acid-hematoxylin to indentify myoid cells and PAS to stain cystic Hassal's corpuscles in the human thymus, but did not identify myoid cell PAS staining.

An approach, more relevant to muscle cell physiology, was reported by Sharp and Woo-Sam (1979), who showed, in the rabbit myoid cells and certain epithelial-reticular cells of the thymus, acetylcholinesterase reactive membranes and inclusions. In the present study calf thymic myoid cells were acetylcholinesterase positive with the reaction product being seen at the periphery of the cell as well as in its cytoplasm. Non-myoid cell acetylcholinesterase reactivity (presumably epithelial cell staining) was seen only infrequently in cytoplasmic vesicles.

The demonstration of the shared acetylcholinesterase marker does not suggest that thymic myoid cells and epithelial-reticulum are embryologically related. A report of a common origin for these cells was based on the finding of occasional desmosomes connecting the two cell types (Raviola and Raviola 1967). In the present study no such connections were seen. Neither human nor calf myoid cell exhibited any immunoreactivity for keratin, an epithelial cell marker protein (Battifora et al. 1980). Puchtler's (1975) finding that all epithelial cell nests and Hassall's corpuscles contain myoid elements, was not born out by the present immunocytochemical findings.

The acetylcholinesterase activity of myoid cells may be consistent with a role for them in T-cell differentiation. Acetylcholine has been shown in vitro to cause an electrical potential change in the T-cell membrane but not in the B-cell (Strom and Shapiro 1980). Thymic lymphocytes have been shown to bear a surface marker which cross reacts with the acetylcholine receptor (Fuchs et al. 1980). Therefore, acetylcho-

line derived from thymic nerve terminals may trigger some part of the thymocyte differentiation cascade.

Thymic stromal cells have long been associated with production of a class of polypeptides known collectively as thymic hormones (Goldstein 1975, Mandi and Glant 1973). How these thymic products are related to the myoid cell, if at all, is at present unclear but one thymic peptide is of particular interest. Thymopoietin was first isolated on the basis of its neuromuscular blocking activity in an experimental autoimmune thymitis preparation, an animal model for myasthenia gravis (Goldstein 1975). Later thymopoietin was found to have a T-cell stimulating capacity as well. Of interest are reports that anti-muscle globulin from the sera of some myasthenic patients reacts with the myoid elements in tissue section (Mackay and Goldstein 1967). Engle et al. (1977) has shown that epithelial- reticular cell islands in the human thymic medulla contain alpha-bungarotoxin sensitive acetylcholine receptors. Wekerle et al. (1978) has found similar receptors on cultured thymic myoid cells. Injection of an animal with purified acetylcholine receptors from the electric organ of the torpedo fish can produce a myasthenic-like condition (Claudio and Rafferty 1980). It seems that the initial autoimmune insult in myasthenia gravis may involve thymic myoid cells. The involution or degeneration of ovoid myoid cells suggested in this and other studies may release muscle-specific antigens such as the acetylcholine receptor protein that sensitize the individual. Antibodies produced then cross-react with somatic musculature, precipitating the degenerative

changes seen in myasthenia gravis. The timing of myoid cell involution during thymic development may determine whether an autoimmune condition is produced. Therefore, it is of some value to understand the normal distribution and appearance of the thymic myoid cell as the individual ages.

### Summary

Myoid cells were consistent features of the calf thymic medulla but absent early in development in the rat. Finding the myoid cell only in the adult rat thymus argues against the suggestion that this cell is vestigial. Only the oval form of myoid cell was apparent in the postnatal thymus of these species. A light and a dark form of myoid cell was displayed by toluidine blue and PAS staining of calf thymus. These two cell types were thought to correspond to involuting and intact myoid cells seen by electron microscopy. Calf thymic myoid cells as well as some thymic epithelial cells were found to possess acetylcholinesterase activity. Human and calf myoid cells were not immunocytochemically reactive for keratin as were Hassall's corpuscles and thymic epithelium. This finding suggests that thymic epithelial cells and myoid cells are not have been derived from the same lineage. However, myoid cells may interact with the epithelial-stromal components of the thymic reticulum; cells known to produce peptides necessary for thymocyte development.



## Legend

Fig. 1 One micron thick section of calf thymic medulla. (500X). Presumed myoid cells (arrows) can be compared to epithelial reticular cells (e).

Fig. 2 Electron micrograph of myoid cell from adult rat thymic medulla. (4,060X) (N) nucleus, (L) lymphocyte, arrows-sarcomere-like collection of myofilaments.

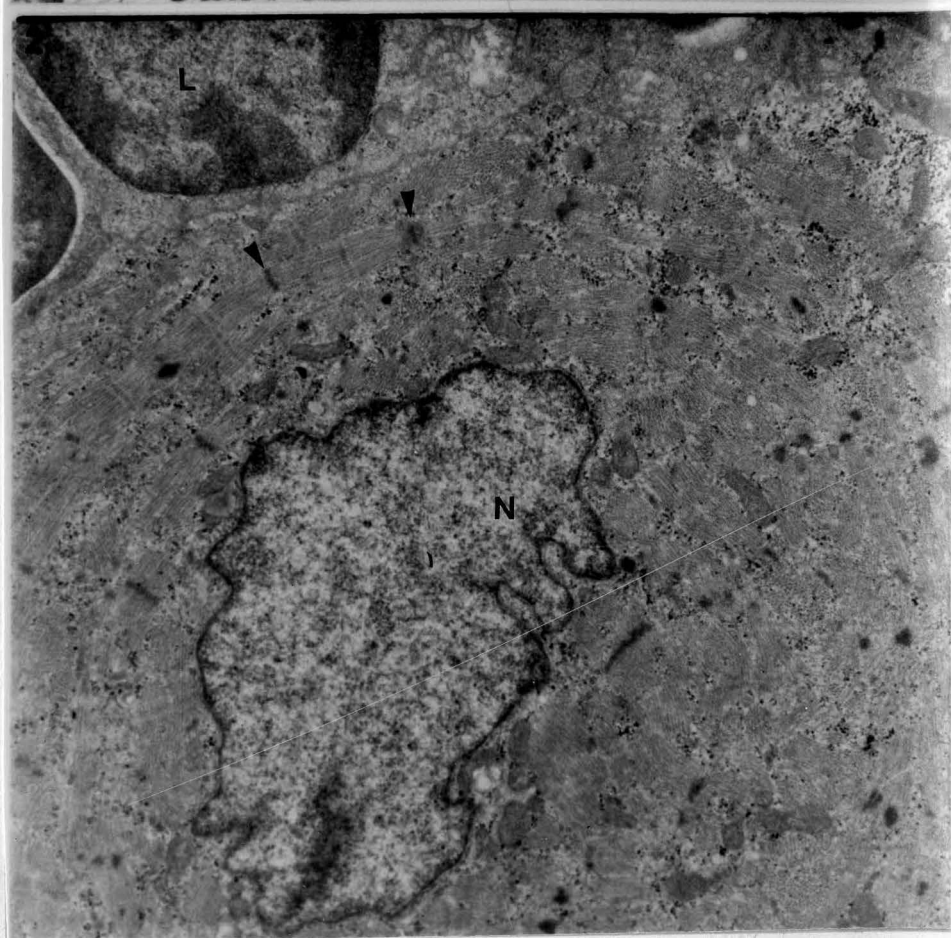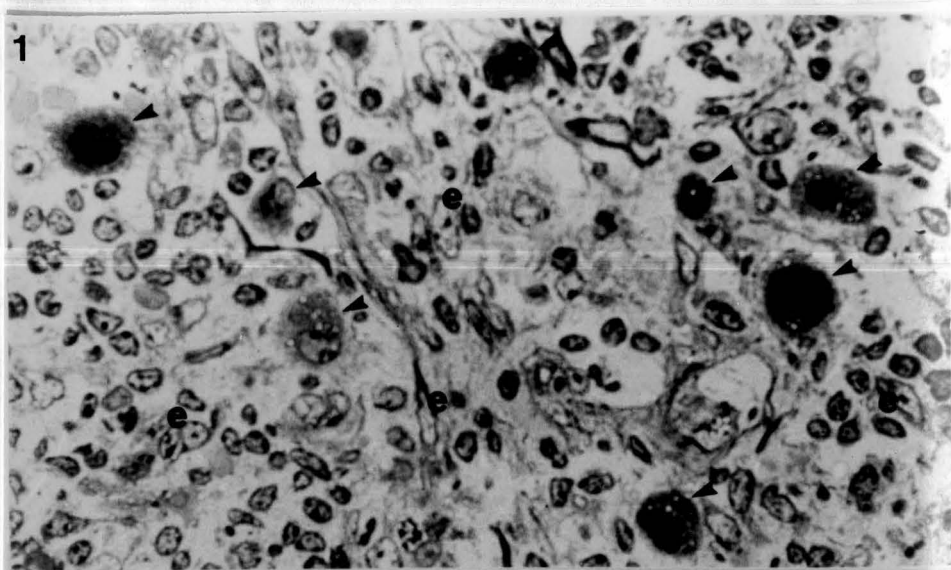


Fig. 3 One micron thick section showing light and dark forms of calf thymic myoid cell (1,280X) Lymphocyte (L), epithelial reticular cell (e).

Fig. 4 Electron micrographic detail of dark myoid cell from calf thymus. Shown are an inclusion body (I), Golgi apparatus (g), glycogen particles (G) and a heterochromatic nucleus (n) in a cytoplasm with a disorganized background of myofilaments.

Fig. 5 Electron micrographic detail of a light myoid cell from rat thymic medulla. (1,400X). Z-band-like material (z), with prominent bundles of myofilaments (f) arranged in a sarcomere-like structure. Shown are myoid cell euchromatic nucleus (n), and adjacent lymphocyte for comparison (L).

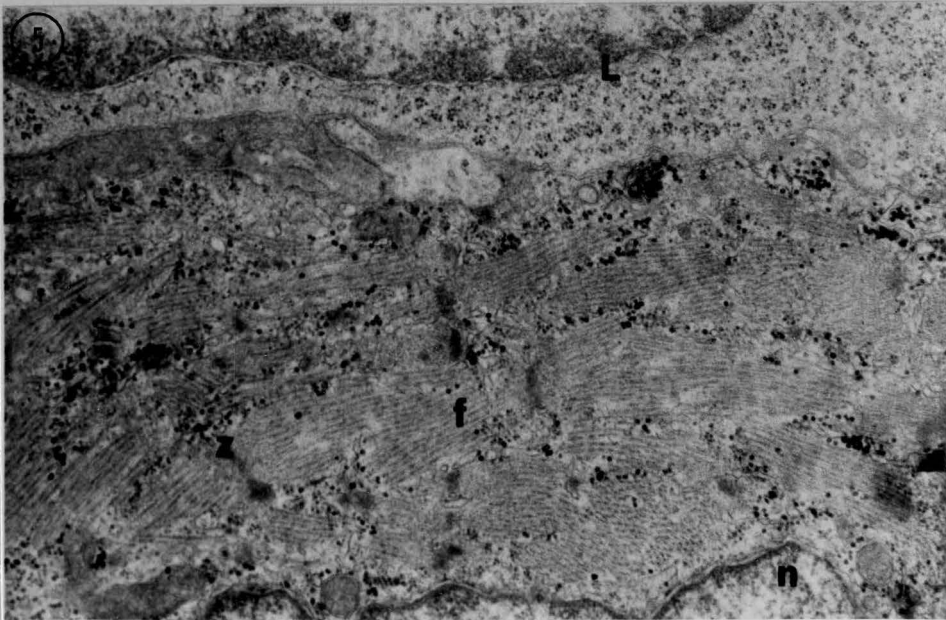
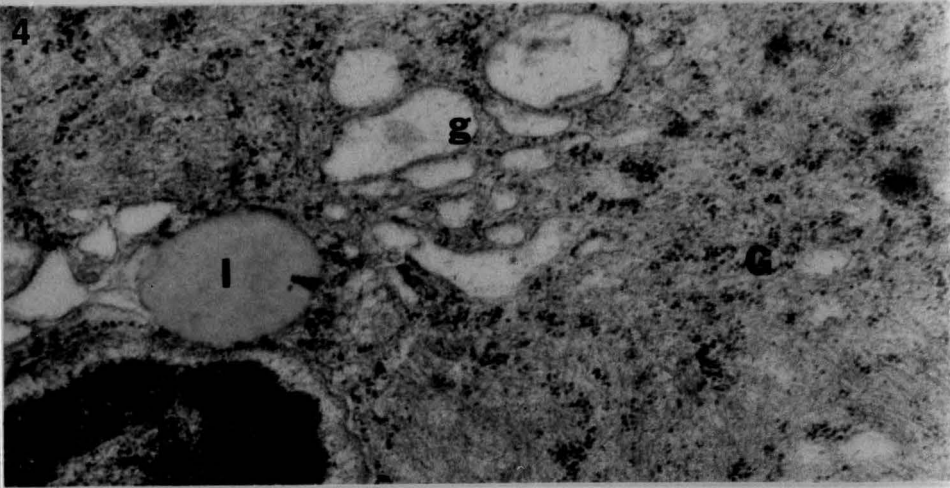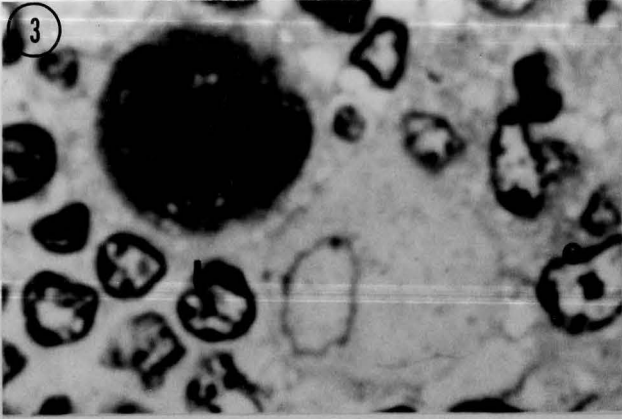


Fig. 6 Electron micrograph of calf thymic myoid cell (13,400X). Myofilaments (f) are seen in the cytoplasm. Acetylcholinesterase reaction product is present in the nuclear envelope and in cytoplasmic vesicles (arrow).

Fig. 7 Electron micrograph of calf thymic myoid cell (3,770X). Myofilaments (f) are seen in the cytoplasm. Acetylcholinesterase reaction delineates the cell membrane.

Fig. 8 Electron micrograph of acetylcholinesterase reaction product in an epithelial cell cytoplasmic vacuole (ev). Desmosome (arrow). (17,100X).

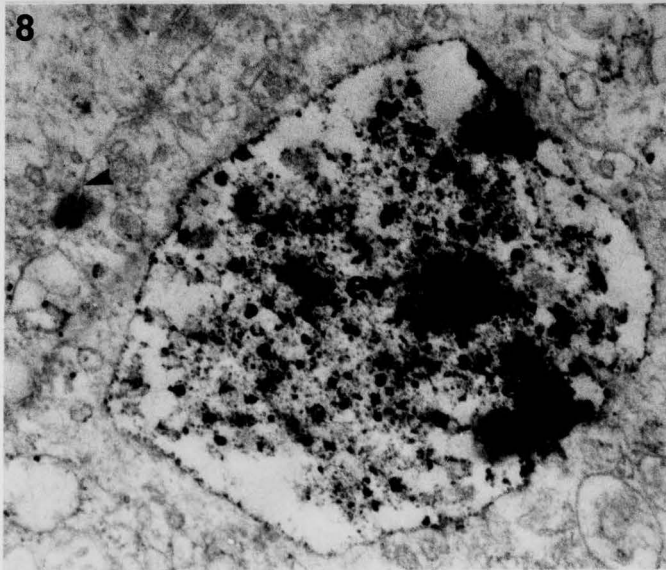
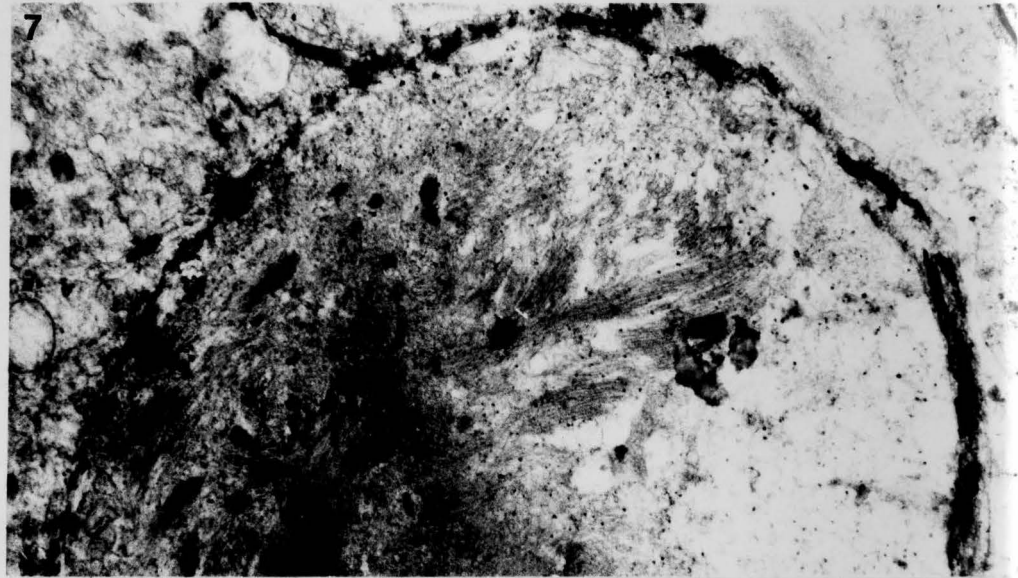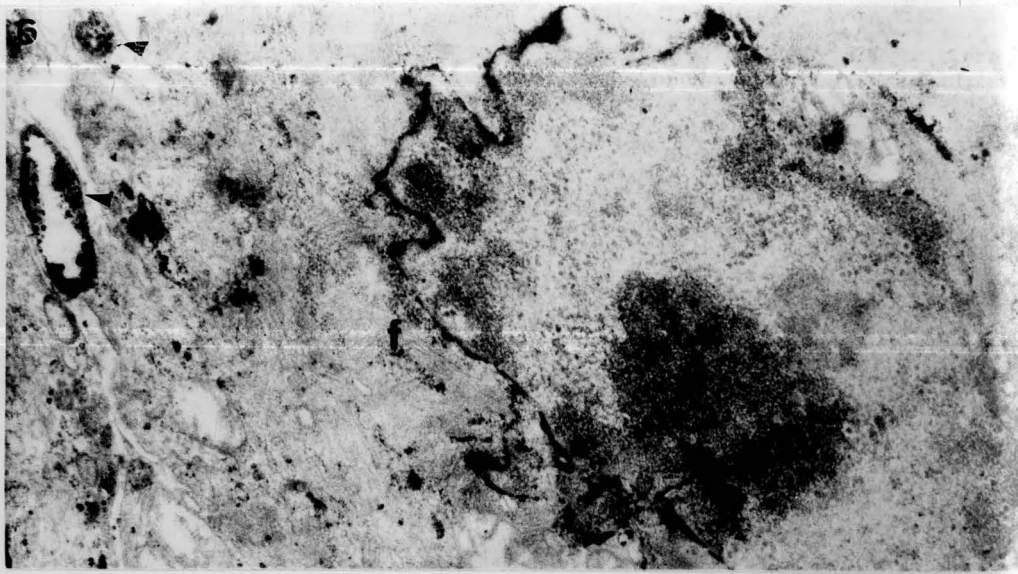


Fig. 9 Electron micrograph rat thymic medulla. (5,850X). The simple Hassall's corpuscle (H) is the dominant form in rat. It consists of a central hypertrophic cell (H) surrounded by a single epithelial lamella (E). arrows-tonofilaments.

Fig. 10 One micron thick section of calf thymic medulla. (1,040X). Showing epithelial cells (e) making up multilaminar Hassall's corpuscle. Note the keratinized or degenerating center.

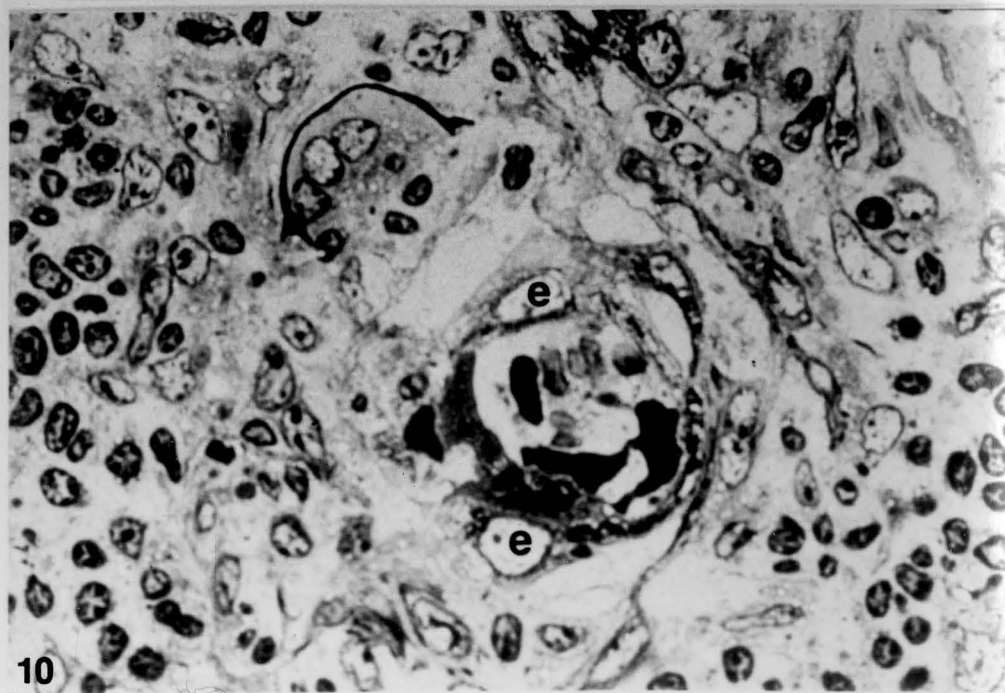
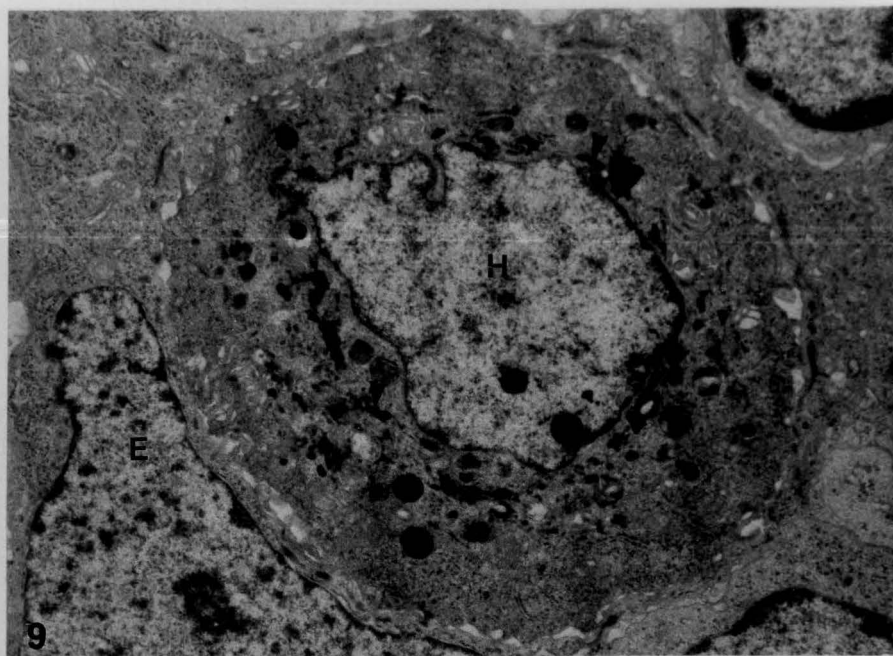
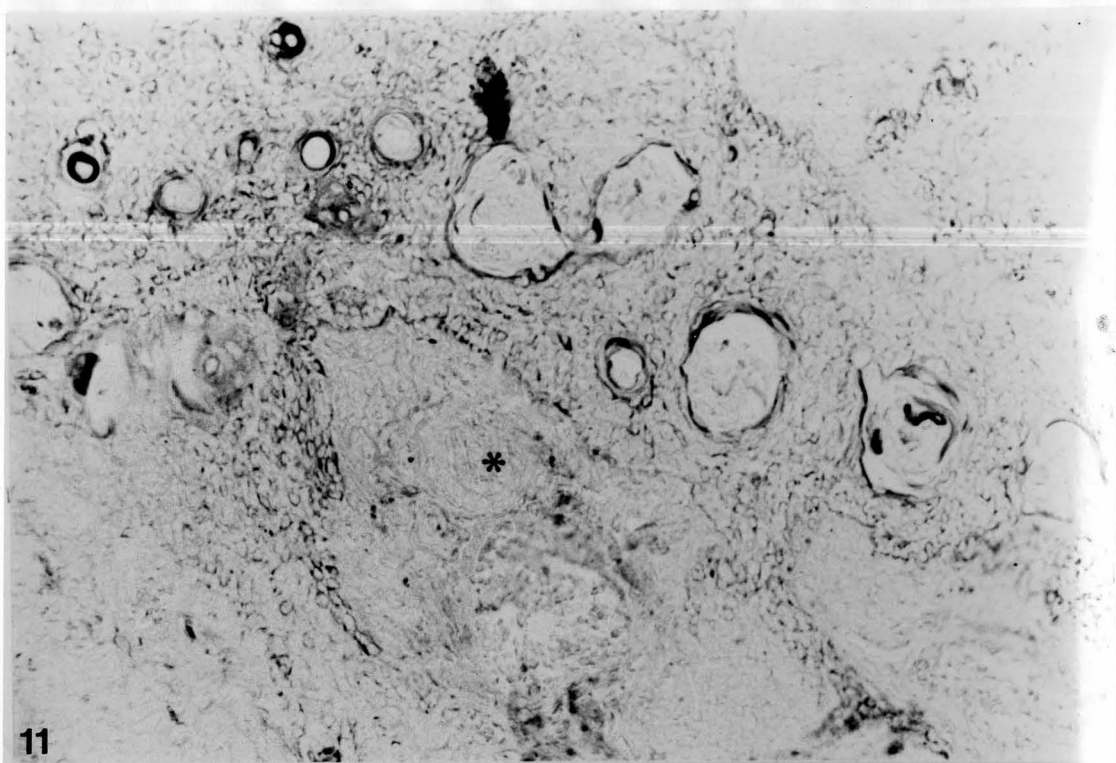


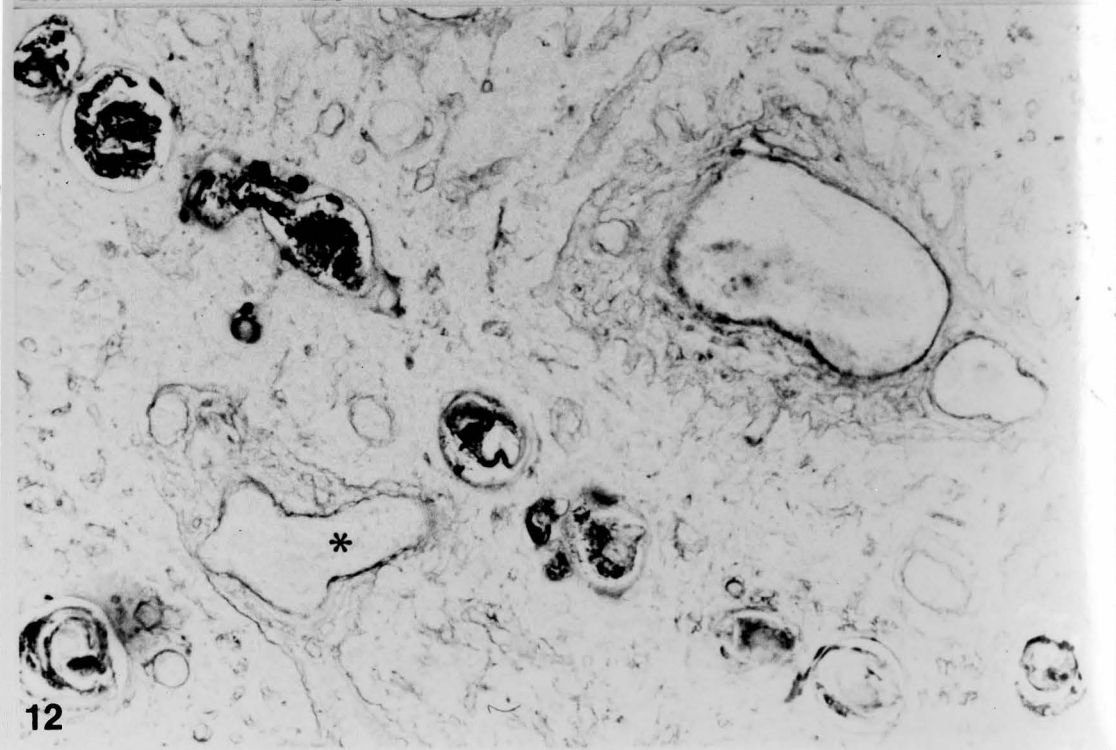


Fig. 11 Medullary zone of human thymus stained for keratin (425X).  
Trypsinized paraffin section, indirect immunoperoxidase. (\*) reference  
artery.

Fig. 12 Medullary zone of human thymus stained by PAS procedure (425X).  
Parallel paraffin section. (\*) reference artery.



11



12

## CHAPTER IV

### IMMUNOCYTOCHEMICAL LOCALIZATION OF THYMIC HORMONES

#### Introduction

A hormonal role for the thymus in the differentiation of T-lymphocytes was suggested by the early thymic extirpation and grafting experiments (Miller and Osoba 1963, Osoba and Miller 1963, 1966). As a consequence a number of protein factors shown to be active in T-cell potentiation have been isolated from the thymus (Goldstein et al. 1966, Goldstein 1975, Bach et al. 1977, Trainin and Small 1970). Although an understanding of the cytological components responsible for this endocrine secretion is still lacking, it has been proposed that the epithelial-reticular cells of the thymus are responsible. Several investigations have utilized immunocytochemical techniques to determine the reactivity of epithelial-reticular cells in tissue section (Mandi and Glant 1973, Goldstein 1975, Teodorczyk et al. 1975, Mandi et al. 1979, van den Tweel et al. 1978, Schmitt et al. 1981). All studies have identified thymic hormone immunoreactivity in stromal cells but identification of the specific subtypes responsible has been hampered by the poor definition available with light microscopic fluorescence immunocytochemistry. Also, interspecies combinations such as rodent tissues and anti-bovine serum have often yielded equivocal results. As stated by Teodorczyk et

al. (1975), " Even if the biological activity of thymic factors is equivalent their antigenicity may be species specific."

Table I. lists the four best characterized thymic hormones (thymosin, thymic humoral factor or THF, thymopoietin and facteur thymique serique or FTS). It can be seen that they are of different molecular weight and amino acid composition and that the assays used to determine their T-cell effects are quite different. The tissue source of choice for the preparation of most of these factors has been calf thymus. Ideally then, it is calf thymus that should be examined for thymic hormone reactivity. Human thymic development is also of obvious interest. In the present study preliminary attempts to localize antibody to thymic hormone in rat thymic sections were unsuccessful. Human or calf thymus was therefore utilized in an attempt to identify the cell or cell types responsible for thymopoietin and thymosin VI production. Both immunofluorescence and immunoperoxidase procedures were employed, the former because of its ease of application and the later because of its superior light microscopic resolution of morphology and potential application to ultrastructural immunocytochemistry.

## Materials and Methods

Immunohistochemical techniques were used to examine the localization of bovine thymosin and thymopoietin in paraffin embedded calf and human thymus. Calf thymus was obtained from a local slaughter house and all animals were less than one year of age. The human thymic tissue was from an infant male who had died of a congenital heart defect.

Light Microscopy Thymic hormone immunoreactivity was best preserved in tissue fixed in 10% phosphate buffered formalin or Bouin's solution and embedded in Paraplast. Sections were cut at 5 microns and mounted on glass slides. Slides were heated to 60 degrees C for 30 minutes then deparaffinized in two changes of xylene and rehydrated. Enhancement or exposure of antigenic sites by a brief trypsinization with 0.125% solution of enzyme for 5 minutes (Curran and Gregory 1977) greatly improved the staining reaction. Endogenous peroxidase activity was eliminated by pretreatment of sections with 3% hydrogen peroxide for 5 minutes. Slides were then washed in phosphate buffer at pH 7.2 for 15 minutes.

Immunocytochemical treatment was carried out as follows:

1) Primary antiserum (rabbit anti-thymosin VI or rabbit anti-thymopoietin was kindly provided by Drs. A Goldstein and G Goldstein. Antiserum against lysozyme (purchased from Immunlok, Carpentaria, Calif.) was diluted 1:20 to 1:50 in phosphate buffer at pH 7.2, was applied to sections for 1 to 2 hours at room temperature and then washed three times in phosphate buffer. It should be pointed out that the rabbit anti-thymosin antiserum used, was to a complex thymic fraction consisting of many peptides and that fraction V, not fraction VI, is now considered to be the more pure preparation for immunologic effects (Goldstein et al 1975). Thymopoietin antiserum was produced by injection of rabbits with a single polypeptide (Schlesinger et al. 1975B).

2) The sections were incubated with goat anti-rabbit IgG peroxidase conjugate (Cappel, Cochranville, Pa. or Polysciences, Warrington, Pa.) at a 1:10 to 1:20 dilution in phosphate buffer for 30 minutes at room temperature.

3) Sections were then treated with the filtered substrate 0.01% hydrogen peroxide + 0.05% diaminobenzidine (Sigma, St. Louis) in 0.05M Tris buffer pH 7.2 or 0.1% hydrogen peroxide + 0.05% ethylaminocarbazol in 0.1 M acetate buffer at pH 5.2 for 10 minutes at room temperature. Sections were then washed and counterstained with hematoxylin and eosin if necessary. Some slides were stained by the PAS reaction performed according to the method of Lillie (1951).

4) Controls: These included: a) deletion of the primary or the bridge antiserum; b) substitution of normal rabbit serum for the specific anti-thymic hormone; c) preabsorption of the antiserum with thymic hormone (for this purpose thymopoietin and thymosin were kindly provided by Dr. John Sharp) and d) staining of non-thymic tissues with the antisera.

Immunofluorescent staining of thymic hormone was attempted by the indirect method. A 1:20 to 1:50 dilution of antiserum to thymopoietin or thymosin VI in phosphate buffered saline was overlaid on a deparaffinized and rehydrated section of calf or human thymus that had been treated with trypsin. The incubation with primary antiserum was performed for 1 hour at room temperature. The sections were then rinsed in several changes of buffer and then fluoroscein-isothiocyanate labeled

goat anti-rabbit IgG (Cappel, Cochranville, Pa.), diluted 1:10 to 1:20, was applied for 30 minutes. The tissue was then rinsed in buffer, mounted in glycerol-phosphate buffer and examined with ultraviolet illumination on a Nikon Ultraphot microscope with barrier filter (650-440 nm) and exciter filter (BG12 or UG1) combination.

Electron microscopy Both calf and rat tissues were used for electron microscopy. Thymi were fixed in a series of fixatives including 1,2,4% glutaraldehyde, 1,2,4% paraformaldehyde and picric acid paraformaldehyde. Some tissues were post-fixed in 1% osmium tetroxide. This tissue was then embedded in Araldite 6005 or Epon 812 and sections were counterstained with uranyl acetate and lead citrate. Thin sections were examined in a Hitachi HU-IIB electron microscope.

## Results

Parallel sections of human or calf thymus stained with the indirect peroxidase or the immunofluorescent technique for thymosin and thymopoietin, showed reaction product in different locations (Figures 1-6). Anti-thymosin VI staining was seen primarily in cortical non-lymphoid stromal cells in the human thymus, some with quite large accumulations of positively stained material suggesting depots or stores of hormone (Figures 1 and 3). While most of these cells were considered to be epithelial cells, some of the thymosin positive cells may have been macrophages, as evidenced by the reaction of similar cells in parallel sections for lysosyme and PAS. A few medullary cells and some Hassall's corpuscles stained slightly with the antiserum to thymosin VI but

these areas stained even with normal rabbit serum controls. Lymphocytes were always negative. Deletion of the bridge antiserum or use of normal rabbit serum produced little or no reaction anywhere in the section. Lymph node sections incubated with anti-thymosin VI also showed some reaction in paracortical macrophage populations, indicating that the thymus specific nature of this fraction was not complete. Preabsorption of the antisera with 10ug of thymosin in phosphate buffered saline for 24 hours at 4 degrees C prior to the immunocytochemical reaction did decrease the staining intensity. Calf thymus immunoreactivity was also cortical, with a band of thymosin VI positive cell also seen at the cortico-medullary boundary.

Immunohistochemical staining of calf or human thymus for thymopoietin revealed a quite different pattern, with the most intense label in the medullary epithelial cells although there was staining of low intensity in the stromal cells of the cortex as well (Figures 2 and 4). For the most part, this staining pattern seemed to delineate the epithelial-stromal network uniformly. But an occasional intensely stained large cell was seen in medullary zones particularly in the calf thymus (Figures 5 and 6). Only some thymic lobules contained these cells. Two populations of morphologically similar cells that reacted differently for thymopoietin were apparent. Unstained (Figure 5) and hematoxylin and eosin counterstained sections (Figure 6) showed some of the hypertrophic cells to be positive for thymopoietin and others that were negative. Lymphocytes were also negative. Hassall's corpuscles



reactivity for thymopoietin was also noted. The reaction was more intense than the non-specific staining of corpuscles seen in normal rabbit serum controls. Lymph node sections incubated with anti-thymopoietin were completely negative. Preabsorption of antiserum with antigen diminished the staining reaction.

Since the non-lymphoid cells from the cortical zones that stained with antibody to thymosin VI in paraffin sections of human thymus, were thought to be both epithelial cells and macrophages, these cells were examined by electron microscopy. These ultrastructural observations were confined to sections of rat and calf thymus. In both the rat and the calf, cortical epithelial cells exhibited an extremely attenuated cytoplasm drawn out into long cytoplasmic processes that surrounded the many lymphocytes seen in the cortex (Figure 7). At the core of these processes were seen bundles of tonofilaments. Stellate cell cytoplasmic organelles were generally concentrated near the nucleus and these included membrane bound bodies (Figure 7) which ranged in appearance from characteristic "clear" vesicles with smaller dense bodies rimming the interior surface of the vesicle, to electron dense bodies that may have been either lysosomal or secretory in nature.

Many inclusion containing cells were seen in the calf and particularly in the neonatal and young rat cortex. Ultrastructural examination revealed these cells to have the internalized apoptotic remains of numerous thymocyte nuclei within their cytoplasm (Figure 8). These cells were considered to be macrophages and not epithelial cells, since they

lacked tonofilaments and desmosomes, and were thought to be the ultrastructural equivalent of the large cortical thymosin VI positive cells seen in the human thymus. Macrophages were also prominent at the cortico-medullary boundary in the rat and calf thymus but this zone was not thymosin VI positive in the human tissue.

By light microscopy the medullary epithelial cells were strongly thymopoietin positive. By electron microscopy, rat and calf medullary epithelial cells were abundant and their prominent nuclei and extensive cytoplasm were readily distinguishable from lymphocyte profiles (Figure 9). These cells were filled with tonofilaments and were connected to the other cells of the epithelial medulla by numerous desmosomes. Dense granules seen within their cytoplasm may have been either kerato-hyaline or secretory granules. Hypertrophic epithelial cells forming the center of simple Hassall's corpuscles and ovoid myoid cells were also seen.

### Discussion

The immunocytochemical observations in the present study indicate thymosin VI reactivity is restricted to the non-lymphoid stromal elements in the cortex of the human and the calf thymus. The complex nature of the antiserum to thymosin VI and its localization in the thymic stroma, permits one to say very little as to the specific cell or cells of origin, at least at the light microscopic level. It can only be suggested that a multicomponent preparation such as thymosin may be produced by more than one stromal elements, for example epithelial cells and macrophages. Alternatively some of the immunoreactive sites

detected by this technique may not be the sites of thymosin production, but merely places of hormonal sequestration.

Mandi and Glant (1973, 1979) with indirect immunofluorescence localized thymosin V in the stromal cells of calf and mouse thymus noted both cortical and medullary staining. Van den Tweel et al. (1978) have identified stromal cells positive for Thymosin V and VI in calf thymus by immunoperoxidase techniques. Both these studies describe patterns of hormone localization similar to those seen in the present investigation, but mention some staining by naturally occurring anti-epithelial antibodies in control sera or with anti-hormone serum on non-thymic (control) tissue.

Recently, Hirokawa et al. (1982) have utilized antisera to thymosin alpha 1 and beta 3 as well as fraction VI, to stain human thymic tissue ranging in age from newborn to 65 years. Thymosin alpha 1 seems to be present in epithelial cells of both the cortex and medulla, while beta 3, an inducer of terminal nucleotidyl transferase in cortical lymphocytes, was found only in the cortex. Cells seen to stain for thymosin VI by Hirokawa et al. (1982) included both epithelial stromal cells and certain macrophages of both the thymus and spleen. This finding may indicate that the complex thymic hormone preparations may be produced in part by mononuclear cells as well as epithelium.

Goldstein (1975) demonstrated a different reactivity for two antisera to thymopoietin in the stromal cells of the guinea pig. One antiserum stained the cells of the cortex exclusively, while the other

highlighted only medullary stromal cells. The antiserum to thymopoietin obtained for the present study, identified regions of immunoreactivity in the calf and human thymic medullary non-lymphoid stromal network. This pattern was reminiscent of the staining produced by the application of anti-keratin to parallel sections of human thymus (See Chapter III) indicating that keratin or tonofilaments (epithelial cell markers) are expressed by at least some of the thymopoietin positive cells of the thymus.

It was also shown in the present study that a prominent anti-thymopoietin reaction is identifiable in some medullary hypertrophic cells of the calf and human thymus. Medullary stromal cell populations are quite heterogeneous however, as shown by the presence of a distinct thymopoietin negative hypertrophic cell population. This light microscopic localization cannot eliminate the possibility that squamous epithelial cells, myoid cells or the various forms of Hassall's corpuscles are all candidates for thymopoietin synthesis or all have receptors for this thymic hormone.

## Summary

The cellular origin of two distinct T-cell differentiating factors has been shown to be different cortical and medullary non-lymphoid stromal cells of the human and calf thymus. Both cortical macrophages and epithelial cells were considered to be immunoreactive for thymosin VI. Thymopoietin staining was largely restricted to the medullary epithelial-stromal network. Both thymopoietin positive and negative hypertrophic

cells of an unknown identity were seen in the medulla. Electron microscopic features of the thymic non-lymphoid cells were correlated with the light microscopic immunocytochemical findings.

Table I


## Known Thymic Hormones, Their Structure and Source

Hormone	MW	AA#	Source
Thymosin alpha 1	3,108	28	Calf thymus
FTS	857	9	Pig blood
Thymopoietin	5,562	49	Calf thymus
THF	3,220?	31?	Calf thymus
		5	
Thymosin alpha 1	Ac-Ser-Asp-Ala-Ala-Val-Asp-Thr-Ser-Ser-		
	10	15	
	Glu-Ile-Thr-Thr-Lys-Asp-Leu-Lys-Glu-Lys		
	20	25	
	Lys-Glu-Val-Val-Glu-Glu-Ala-Glu-Asn		
		5	
FTS	GLX-Ala-Lys-Ser-Glx-Gly-Gly-Ser-Asn		
		5	
Thymopoietin	Ser-Gln-Phe-Leu-Glu-Asp-Pro-Ser-Val-		
	10	15	
	Leu-Thr-Lys-Glu-Lys-Leu-Lys-Ser-Glu-Leu-		
	20	25	
	Val-Ala-Asn-Asn-Val-Thr-Leu-Pro-Ala-Gly-		
	30	35	
	Glu-Gln-Arg-Lys-Asp-Val-Tyr-Val-Gln-Leu-		
	40	45	
	Tyr-Leu-Gln-Thr-Leu-Thr-Ala-Val-Lys-Arg-OH		

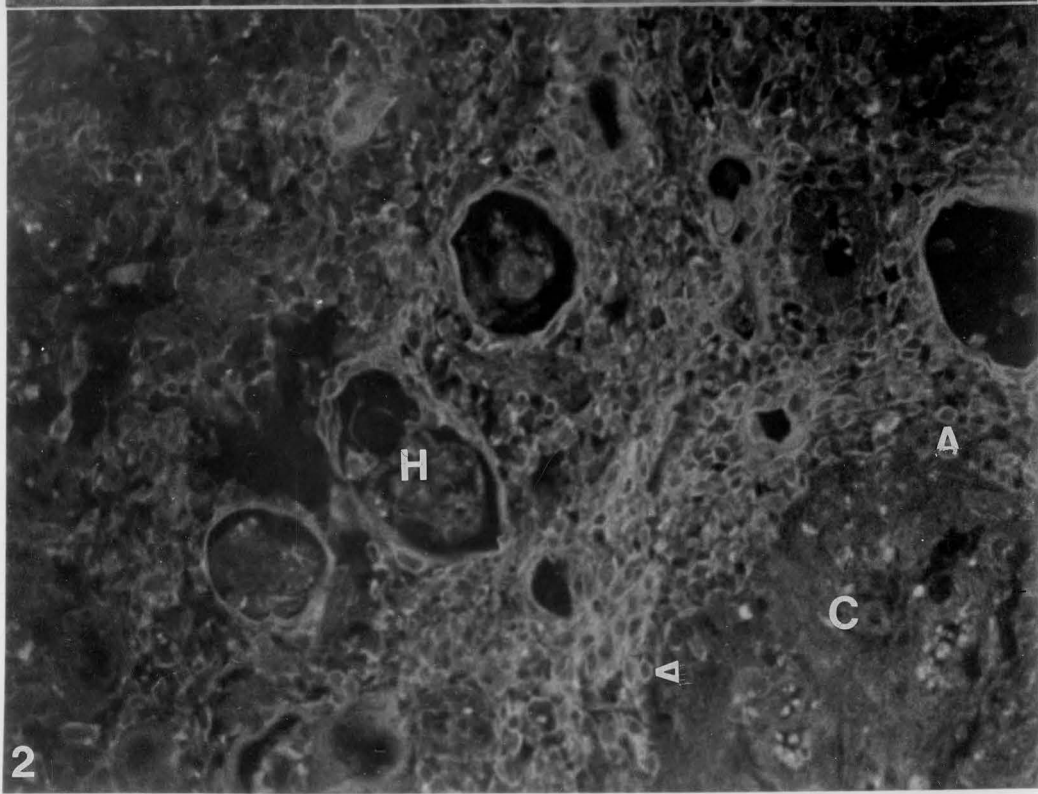
## Legend

Fig. 1 Cortical reaction of human thymus stained for thymosin VI (600X). Trypsinized paraffin section, indirect immunofluorescence. (c) cortex, (H) Hassall's corpuscle, (B) autofluorescent blood vessel, arrows-thymosin VI reactive cells.

Fig. 2 Medullary reaction of human thymus stained for thymopoietin (600X). Trypsinized paraffin section, indirect immunofluorescence. (H) Hassall's corpuscles, (C) cortex, arrows-thymopoietin reactive cells



1

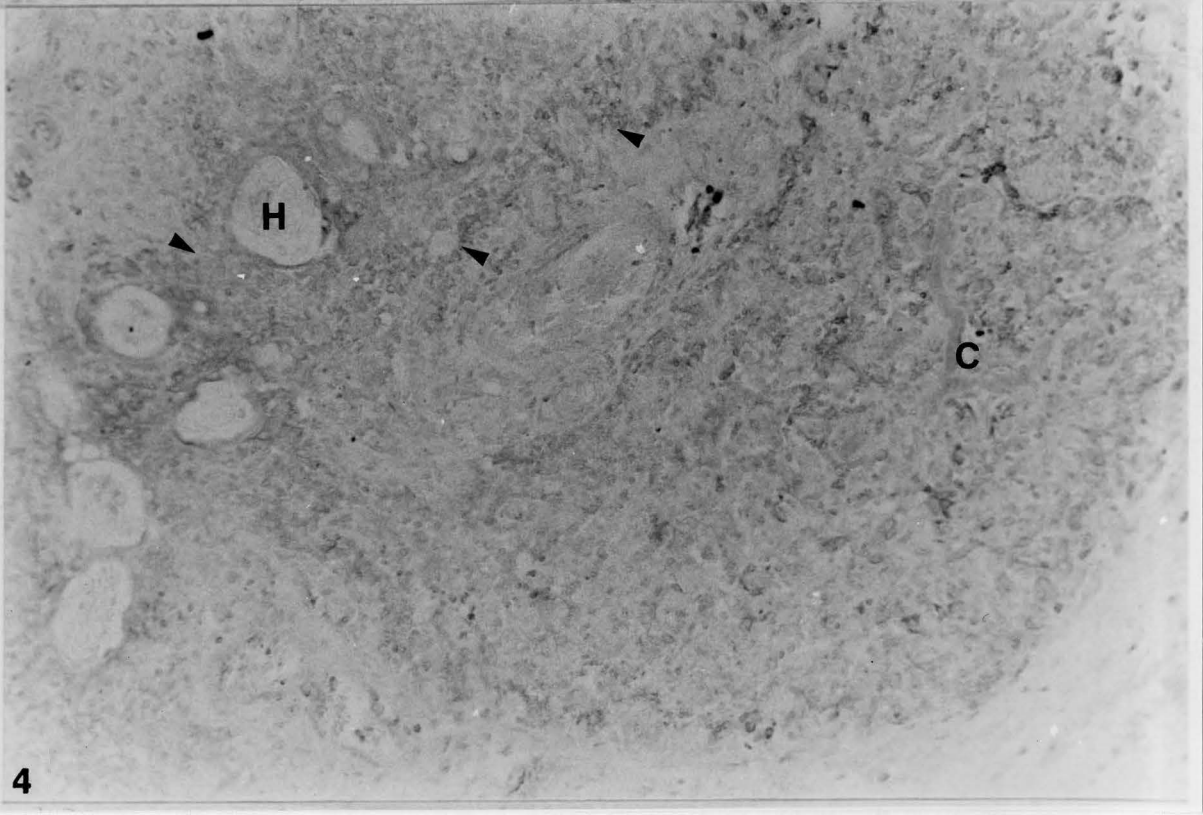
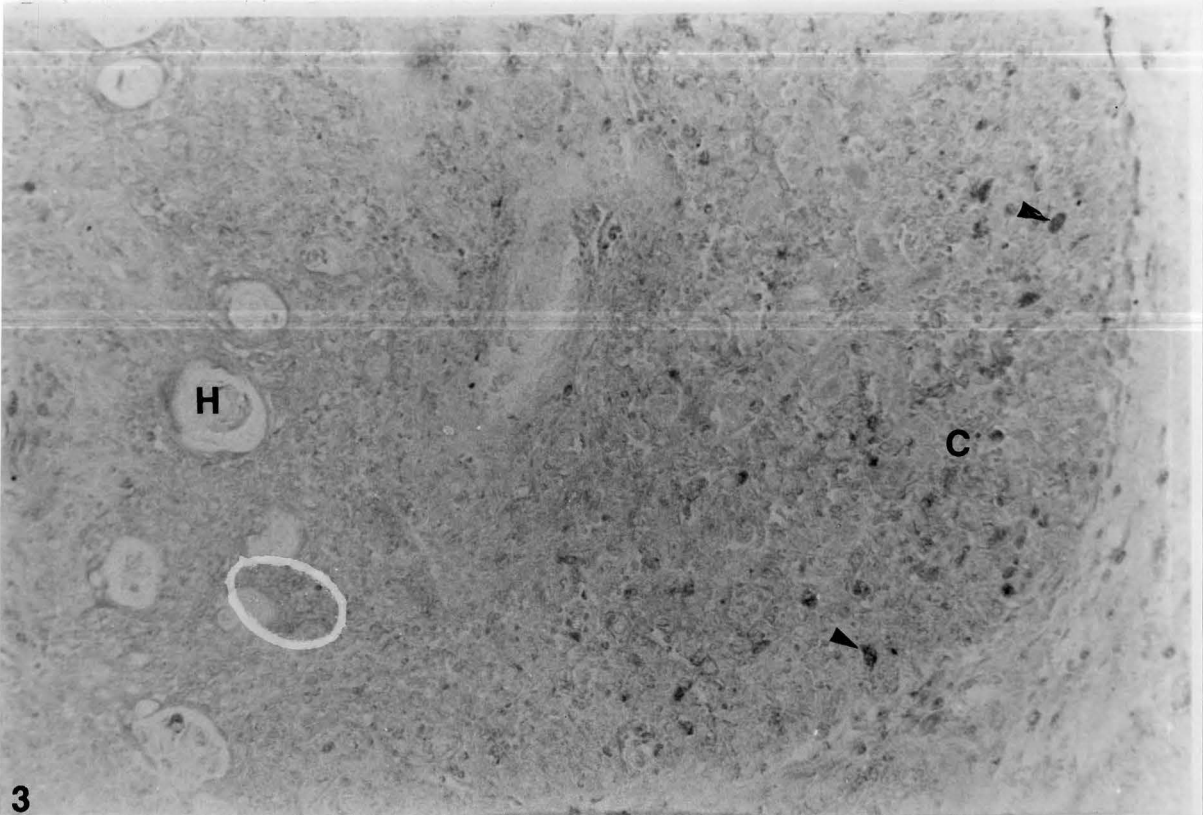


2



Fig. 3 Human thymus stained for thymosin VI (450X). Trypsinized paraffin section, indirect immunoperoxidase. Ethylaminocarbazol substrate. (c) cortex, (H) Hassall's corpuscle, arrows-thymosin VI reactive cortical cells.

Fig. 4 Human thymus stained for thymopoietin (450X). Parallel paraffin section, indirect immunoperoxidase. Ethylaminocarbazol substrate. (c) cortex, (H) Hassall's corpuscle. Thymopoietin reactive medulla delineated by arrows.



3

4

Fig. 5 Paraffin section of formalin fixed calf thymic medulla. Immunostained for thymopoietin by the peroxidase anti-peroxidase technique after trypsinization. Diaminobenzidine substrate. (1,550X). Two types of hypertrophic cell are demonstrated, cells reactive for thymopoietin (s) and unreactive cells (u).

Fig. 6 Paraffin section of formalin fixed calf thymic medulla. Immunostained for thymopoietin by the peroxidase anti-peroxidase technique after trypsinization. Diaminobenzidine substrate. Hematoxylin and eosin counterstain. (1,550X). Two types of hypertrophic cells demonstrated, reactive cells (s) and unreactive cells (u).

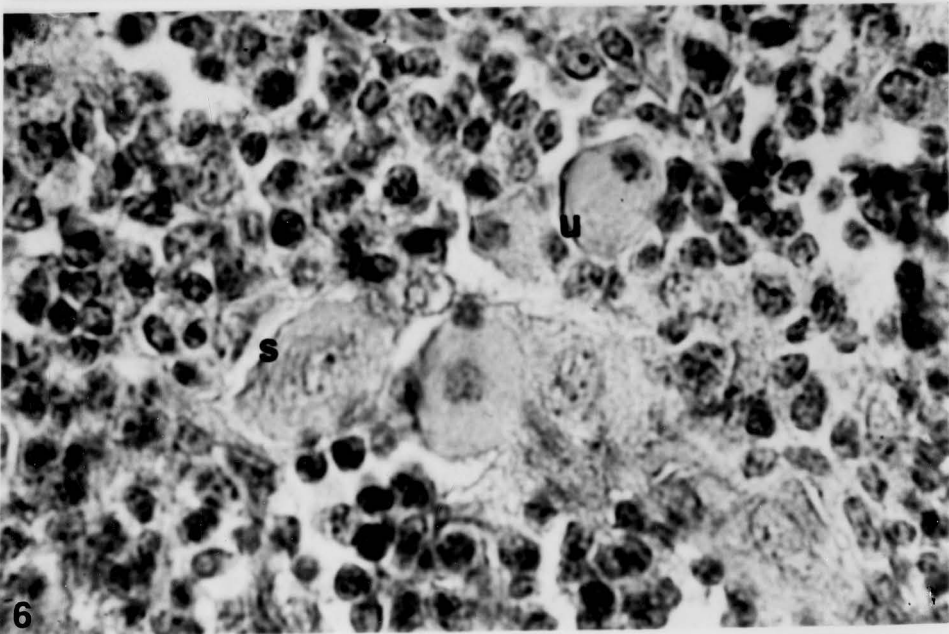
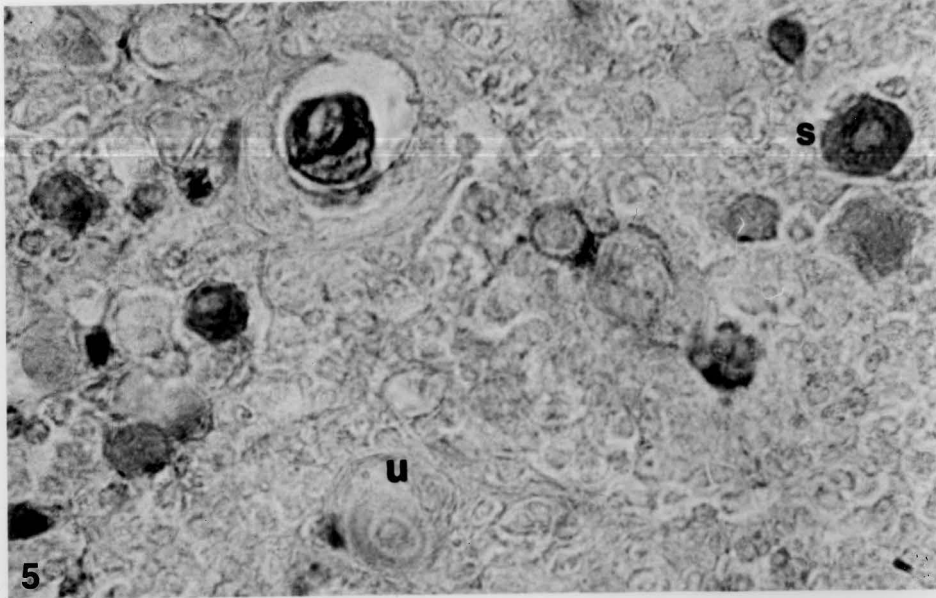
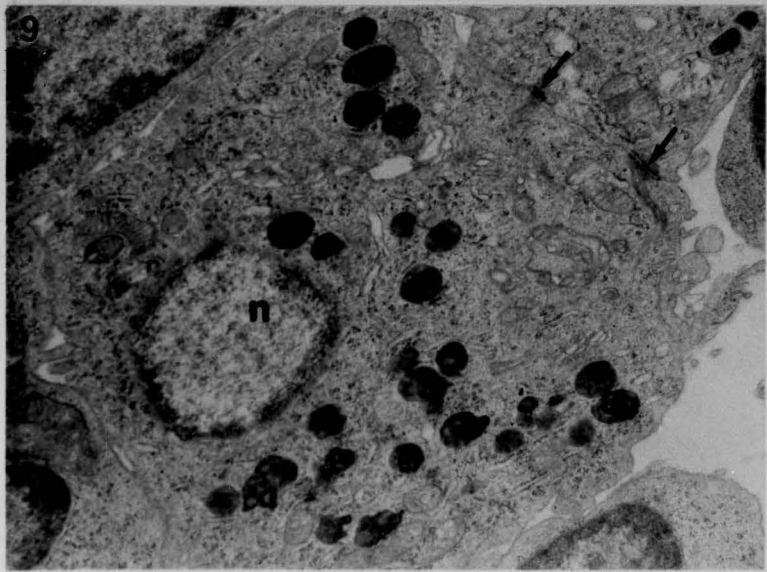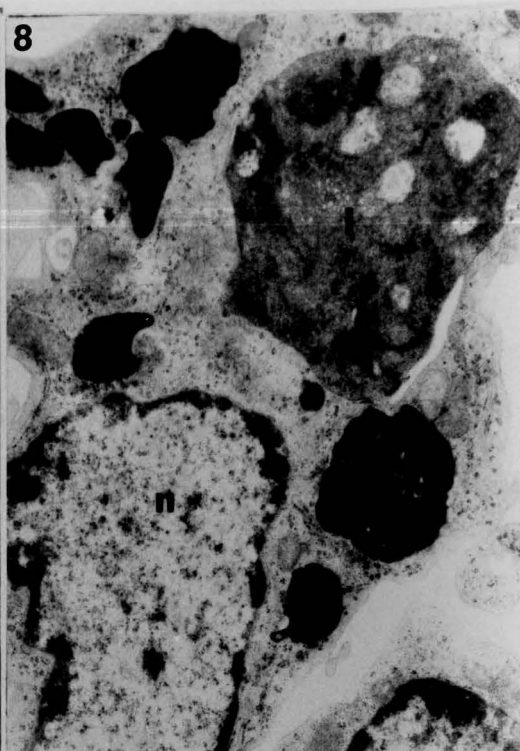
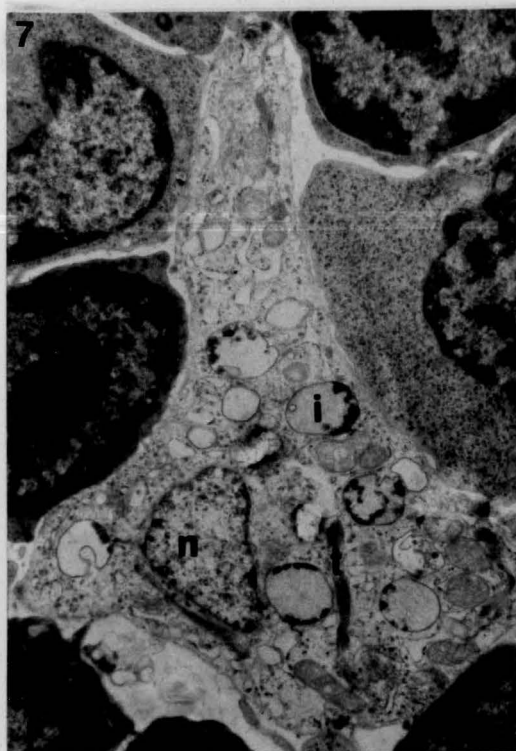


Fig. 7 Electron micrograph of rat thymic cortex. (7,500X). Stellate epithelial cell with clear inclusions (i), nucleus (n), tonofilaments (t), and surrounding lymphocytes (L).

Fig. 8 Electron micrograph of rat thymus. (13,450X) Nucleus of macrophage (N); electron dense inclusions (I) in cytoplasm are pyknotic remains of lymphocyte chromatin and cytoplasm.

Fig. 9 Electron micrograph of rat thymic medulla. Example of numerous electron dense granules in hypertrophic epithelial cell. (16,600X). arrows-desmosomes.

inclusion



## Conclusion

As has been suggested by this study and many of those cited, the stromal components of the thymus have a special inductive influence on the lymphocytes trafficking through the gland. Morphometric analysis showed that different forms of thymic non-lymphoid stromal cells changed in number and relative proportion during developmental periods when thymic endocrine function is critical. Alterations in thymic morphology, such as the change in cortical/medullary index from birth to weaning to sexual maturation may reflect the changing environmental demands placed on the organism's immune system. Alternatively, these changes may result from the course of a developmental program independent of external influence. It has been suggested that non-lymphoid cells produce thymic hormones that mediate steps in the transition from pre-thymocyte to effector T-cell. Several thymic hormone preparations have been isolated, anticipating a pleomorphic secretory process. Epithelial cells are the most obvious candidates for this role, but they often do not exhibit classical endocrine features such as the secretory apparatus evident in such cells as those of the anterior pituitary or the pancreatic islets. Indeed, ultrastructural morphometric analysis of developing thymic medullary epithelial cells performed in this study, showed little change in any one organellar parameter as might be expected during secretion. However, immunocytochemical staining of thymus with two different thymic hormone antibodies, gave some evidence that cortical and medullary epithelial cells do contain T-cell differentiating products.

T-cell differentiation may also be modulated by a variety of mesenchymally derived accessory cells, such as interdigitating cells, macrophages and myoid cells. Several of these cells were shown morphometrically, to vary in number and morphologic appearance as the animal ages. Their putative products include: lysosomal enzymes, polysaccharides, neurotransmitter associated receptors and esterases. Several of these substances were detected in granules, inclusions and vesicles of these cells by immunocytochemical and histochemical procedures. Non-secretory influences, such as cell to cell contact by any or all of these cells may also play a role in thymocyte processing.

Dissection of the stromal cell population of the thymus into its different subtypes by selective tissue culture techniques should aid in answering questions about their individual or concerted activities in T-cell differentiation. There is a possibility that one stromal cell type can be induced to produce endocrine products only by the influence of a second cell type. Co-culture experiments might confirm this phenomenon.

The present investigation supports the suggestion that non-lymphoid stromal cells are critical to proper thymic function in early development. It has been suggested (Bennett 1970) that the decline in cell mediated immunity is responsible for aging in mammals. This postulate maintains that the 'exhaustion of the thymic biological clock' and the decrease in immune surveillance can cause an increase in the diseases of autoimmunity and in cancer. It remains to be elucidated if



non-lymphoid cells play a role in the rate or timing of thymic involution.

## General summary

The following findings were new to this study:

- 1) The thymic medulla was found to increase in volume during maturation of the gland in the rat and the calf.
- 2) Rat thymic cortical non-lymphoid cells declined in absolute number and volume density from birth to 65 days of age, while medullary non-lymphoid cells remained stable in number and volume density.
- 3) Rat medullary squamous epithelial cells declined in relative number from birth to day 65, while mesenchymal non-lymphoid cells, including interdigitating cells and macrophages increased in number. A small, relatively constant number of cystic epithelial cells was found in the medulla.
- 4) No evidence of significant change in volume density of any one organelle was found for rat medullary squamous epithelium during thymic development nor was there any shift in any organelle volume density in interdigitating cells. Medullary macrophages exhibited a decrease in the volume density of dark inclusion bodies from birth to weaning. A significant increase in the volume density of microvillous cysts was noted in cystic epithelium from the first week to 65 days of age.
- 5) Both rat and calf interdigitating cells exhibited ATPase reactivity much like epidermal Langerhans cells. Both human medullary interdigitating cells and Langerhans cells also contained S-100 protein.

6) Rat interdigitating cells were found in the thymic medulla while acid phosphatase positive conventional macrophages were demonstrated in the cortex and cortico-medullary zone of this species. Calf interdigitating cells and histiocytes were both seen in the cortex. Human lysozyme positive histiocytes were seen in both the cortex and in medullary Hassall's corpuscles.

7) Calf thymic myoid cells and certain 'epithelial-like' cells contained acetylcholinesterase.

8) Thymic myoid cells do not appear to be of endodermal origin as they do not possess epithelial cell markers such as keratin nor does myoglobin, a myoid cell protein, delineate epithelial cells or Hassall's corpuscles.

9) Thymosin VI could be demonstrated by immunocytochemistry in cortical epithelial cells and macrophages of the human and calf thymus. Thymopoietin was largely localized in the medullary non-lymphoid cell population. A hypertrophic medullary cell type possessed thymopoietin reactivity.

## References

Abrahamson,

R., Morris, M. and Hendy, R. (1968) Lysosomal changes in epithelial cells of the mouse thymus after hydrocortisone treatment. *Histochemie* 17. 311.

Bach, J.F. (1973) Thymus dependency of rosette forming cells. In: *Contemporary Topics in Immunobiology*. 2. 182. (Carter and Davis, Eds.). Plenum Pub., New York.

Bach, J.F. and Carnaud, C. (1976) Thymic factors. *Prog Allergy*. 21. 342. Karger, Basel.

Bach, J.F., Dardenne, M. and Clot, J. (1975) Evaluation of serum thymus hormone and T-cells in rheumatoid arthritis and systemic lupus erythematosus. In: *Immunologic Aspects of Rheumatoid Arthritis*. 242. Karger, Basel.

Bach, J.F., Dardenne, M., Goldstein, A., Guha, A. and White, A. (1971) Appearance of T-cell markers in bone marrow after incubation with purified thymosin, a thymic hormone. *Proc Nat Acad Sci* 68. 2734.

Bach, J.F., Dardenne, M., Papiernik, M., Barrios, A., Levasseur, P. and LeBrigand, H. (1972) Evidence for a serum factor produced by the human thymus. *Lancet* (ii) 1056.

- Bach, J.F., Dardenne, M. and Pleau, J.M. (1977) Biochemical characterization of serum thymic factor. *Nature* 266. 55.
- Bach, M.A., Fournier, C. and Bach, J.F. (1975) Regulation of the theta antigen expression by agents altering cyclic AMP level and by thymic factor. *Ann NY Acad Sci* 249. 316.
- Barclay, T.J., Weissman, I.L. and Kaplan, H.S. (1964) In: *The Thymus*. 117 (Defendi and Metcalf, Eds.). Wistar Inst Press, Philadelphia.
- Balfour, E., Janossy, G., Thomas, I. and Goldstein, G. (1981) In: *Ciba Found Symp* 84. *Microenvironments in Hematopoiesis*. 238. (Humphry, Ed.). Pitman, London.
- Battifora, H., Sun, T.T., Bahu, R.M. and Rao, S. (1980) The use of anti-keratin antiserum as a diagnostic tool: Thymoma vs Lymphoma. *Human Pathol* 11 (6). 635.
- Bearman, R.M., Levine, G.D. and Bensch, K.G. (1978) The ultrastructure of the normal human thymus; a study of 36 cases. *Anat Rec* 190. 755.
- Bennet, G. (1978) Synthesis and migration of glycoproteins in the cells of the rat thymus, as shown by radioautography after tritiated fucose injection. *Am J Anat* 152. 223.
- Birbeck, M.S., Breathnach, A.S. and Everal, J.D. (1951) An electron microscopic study of the basal melanocytes and high level clear cells (Langerhans cells) in vitiligo. *J Invest Dermatol* 37. 51.

Blankwater, M.J., Levert, L., Swart, A.C.W. and van Bekkum, D. (1978) Effect of various thymic and non-thymic factors on in vitro antibody formation by spleen cells from nude mice. *Cell Immunol* 35. 242.

Blau, J., Jones, R. and Kennedy, L. (1968) Hassall's corpuscles: a measure of the activity in the thymus during involution and restitution. *Immunol* 15. 561.

Bockman, D.E. (1968) Myoid cells in the adult human thymus. *Nature* 218. 73.

Boyd, E. (1932) The weight of the thymus in health and disease. *Am J Dis Child* 43. 1162.

Burnet, F.M. (1962) Role of the thymus and related organs in immunity. *Br Med J* (ii). 807.

Burnet, F.M. (1966) Mast cells in the thymus. in: *The Thymus*. CIBA Foundation Symp 335. Little & Brown.

Burnet, F.M. (1970) An immunologic approach to aging. *Lancet* 1. 358.

Cantor, H. and Boyse, E.A. (1975) Functional subclasses of T-lymphocytes bearing different Ly antigens, I. *J Exp Med* 141. 1370.

Caso, L. (1979) Histochemical analysis of mammalian thymic corpuscles and thymus-derived cell cultures. *Aus J Exp Biol Med* 57(5). 493.

Chapman, W.L. and Allen, J.R. (1971) The fine structure of the thymus of the fetal and neonatal monkey (*Macaca mulatta*). *Z Zellforsch* 114. 220.

Clark, S.L. (1973) The intrathymic environment. In: *Contemporary Topics in Immunobiology* 2. 77. (Defendi V and Metcalf D, Eds.) Plenum Press.

Claudio, T.R. and Rafferty, G. (1980) Is experimental autoimmune myasthenia gravis induced only by acetylcholine receptors? *J Immunol* 124. 3. 1130.

Cocchia, P., Michetti, F. and Donato, R. (1981) Immunochemical and immunocytochemical localization of S-100 antigen in normal human skin. *Nature* 294. 85.

Curran, E. and Gregory, C. (1977) Unmasking antigens in paraffin sections by trypsin. *Experientia* 33. 148.

Dauphinee, M.J, Talal, N., Goldstein, A.L. and White, A. (1974) Thymosin corrects the abnormal DNA synthetic response of NZB mouse thymocytes. *Proc Nat Acad Sci* 71. 2637.

Duijvestijn, A.M. and Hoefsmit, E. (1981) Ultrastructure of the rat thymus. *Cell Tissue Res* 218. 279.

Eikelenbloom, P. (1978) Dendritic cells in the rat spleen follicles: A combined immuno- and enzyme histochemical study. *Cell Tissue Res* 190. 79.

Elliot, E.V. (1977) The persistent PHA responsive population in the mouse thymus. 1: Characterization of the population. *Immunol* 32. 383-393.

Eng, L., Vanderhagen, A., Bignami, A. and Gerstl, B. (1971) An acidic protein isolated from fibrous astrocytes. *Brain Res* 28. 351.

Engle, W.K., Trotter, J.C., McFarlin, D.E. and McIntosh, C.L. (1977) Thymic epithelium cells contain acetylcholine receptors. *Lancet* (i) 1310.

Frazier, J.A. Ultrasturcture of the chick thymus. (1972) *Z Zellforsch* 136. 191.

Frehlinger, J.G., Hood, L., Hills, S. and Frehlinger, J.A. (1979) Mouse epidermal Ia molecules have bone marrow origins. *Nature* 282. 321.

Fuchs, S., Schmidt-Hopfeld, I., Tridente, G., and Tarrab-Hazdi, R. (1980) Thymic lymphocytes bear a cell surface antigen which cross-reacts with the acetylcholine receptor. *Nature* 287. 162.

Gaynor, R., Irie, R., Morton, D. and Hirshmann, H. (1980) S-100 protein is present in cultured human malignant melanomas. *Nature* 286. 400.

Gery, I. and Waksman, B.H. (1972) Potentiation of T-lymphocyte response to mitogens II. *J Exp Med* 136. 143.



Gilmore, R.S. and Bridges, J.B. (1974) Histological and ultrastructural studies on the myoid cells of the domestic fowl. *J Anat* 118(3). 409.

Goldstein, A.L., Slater, F.D. and White, A. (1966) Preparation, assay and partial purification of thymic lymphocytopoietic factor (thymosin). *Proc Nat Acad Sci* 56. 1010.

Goldstein, A.L., Thurman, G.B., Cohen, G.A and Hooper, J.A. (1975) Thymosin: chemistry, biology and clinical applications. In: *The Biological Applications of Thymic Hormones*. 173 (van Bekkum D, Ed.) Kooyker Scientific Pub, Rotterdam.

Goldstein, A.L., Thurman, G.B., Low, T.K., Rosso, J.L. and Trivers, G.E. (1978) Hormonal influences on the reticulo-endothelial system: Current status of the role of thymosin in the regulation and modulation of immunity. *J Ret Endo Soc* 23(4). 253.

Goldstein, G. (1975) The isolation of thymopoietin (thymin) *Ann NY Acad Sci* 249. 177.

Gomori, G. (1956) Histochemical methods for acid phosphatase. *J Histo Cyto* 4. 453.

Gorgollon, P. and Oltone, A.M. (1978) Fine structure of the canine thymus. *Acta Anat* 100(1). 136.

Hakonsen, R., Larsson, L. and Sundler, F. (1974) Peptide and amine producing endocrine-like cells in the chicken thymus. *Histochem* 39. 25.

Hammar, J.A. (1921) The new views as to the morphology of the thymus and their bearing on the problem of the function of the thymus. *Endocrin* 5. 543,731.

Hays, E.F. (1964) Growth and morphology of mouse lymphoma cells in diffusion chambers. *Proc Soc Exp Biol Med* 117. 45.

Hakonson, R., Larsson, L. and Sundler, F. (1974) Peptide and amine producing

Henry, K. (1968) Striated muscle in human thymus. *Lancet* (i) 638.

Henry, K. (1972) An unusual thymic tumor with a striated muscle (myoid) component. *Br J Dis Chest* 66. 291.

Hirokawa, K. (1977) The thymus and aging. In: *Comprehensive Immunology* 1. (Good RA and Day SB, Eds.) Plenum Press.

Hirokawa, K., McClure, J. and Goldstein, A. (1982) Age related changes in localization of thymosin in the human thymus. *Thymus* 4. 19.

Hoessli, D., Bron, C. and Pink, J.R. (1980) T-lymphocyte differentiation is accompanied by increase in sialic acid content of thy-1 antigen. *Nature* 283. 576.

Hoefsmit, E. (1975) Mononuclear phagocytes, reticular cells and dendritic cells in lymphoid tissue. In: *Mononuclear Phagocytes in Immunity, Infection and Pathology*. 129. (VanFurth R, Ed.). Blackwell Scientific Pub, Oxford.

Hoffmann-Frezer, G., Gotze, D., Rodt, H. and Thierfelder, S. (1978) Immunohistochemical localization of xenogeneic antibodies against Ia $\kappa$  lymphocytes on B cells and reticular cells. *Immunogen* 6. 367.

Hong, R., Schulte-Wissermann, H., Horowitz, S., Borzy, M. and Finlay, J. (1978) Cultured thymic epithelium in severe combined immunodeficiency. *Transplant Proc* 10. 201.

Horowitz, S.D., Borcharding, W., Moorthy, A.V., Chessney, R., Schulte-Wissermann, H., Hong, R. and Goldstein, A. (1977) Induction of suppressor T cells in systemic lupus erythematosus by thymosin and cultured thymic epithelium. *Science* 19. 7999.

Hoshino, T. (1963) Electron microscopic studies of the epithelial reticular cells of the mouse thymus. *Z Zellforsch* 59. 513.

Hunter, J.A.A., Fairley, D.J., Priestly, G.C. and Cubie, H.A. (1976) Langerhans cells in the epidermis of athymic mice. *Br J Dermatol* 94. 119-22.

Hwang, W.S., Ho, T.Y., Luk, S.C. and Simon, G.T. (1974) Ultrastructure of the rat thymus. *Lab Invest* 31(5). 423.

Ito, T. and Hoshino, T. (1966) The fine structure of the epithelial-reticular cells of the medulla of the thymus in the golden hamster. *Z. Zellforsch* 69. 311.

Ito, T. (1978) Structure and function of the vitamin A storing cell in the liver - a review. *Acta Anat Nippon* 53. 393.

Izard, J., deHarven, E. (1968) Increased numbers of characteristic type of reticular epithelial cell in the thymus and lymph node of leukemic mice. *Cancer Res* 28. 241.

Jenkinson, E.J., Van Ewijk, W. and Owen, J.J.T. (1981) Major histocompatibility complex antigen expression on epithelium of the developing thymus in normal and nude mice. *J Exp Med* 153. 280.

Jerne, N.K. (1971) The somatic generation of immune recognition. *Eur J Immunol* 1. 1.

Juhlin, L. and Shelly, W.B. (1977) New staining techniques for the Langerhans cell. *Acta Dermatovener (Stockholm)* 57. 289.

Kaiserling, E. (1974) Interdigitating reticulum cells in the human thymus. *Cell Tissue Res* 155(1). 47-55.

Kater, L. (1971) A note on Hassall's Corpuscles. In: *Progress in Immunology*. 1271. Academic Press, New York.

Katz, S.I., Tamaki, K. and Sachs, D.H. (1979) Epidermal Langerhans cells are derived from cells originating in bone marrow. *Nature* 282. 324.

Kindered, E. (1940) A quantitative study of the hemopoietic organs of young albino rats. *Am J Anat* 67. 99.

- Klug, H. and Mager, B. (1979) Ultrastructure and function of interdigitating cells in the guinea pig thymus. *Acta Morph Acad Sci Hung* 27(1-2). 11.
- Koelle, G.B. (1950) The histochemical differentiation of types of cholinesterase and their localizations in the tissues of the rat. *J Pharmacol Exp Ther* 158. 32.
- Kostowieki, M. (1964) Variety of central cells in Hassall's corpuscles of the human thymus. *Z Mikr Anat Forsch* 71. 10.
- Kotani, M., Fukumoto, T., and Brandon, M. (1981) Destruction of Hassall's corpuscles by macrophages in sheep thymus. *Cell Tissue Res* 217. 49.
- Kruger, J., Goldstein, A.L. and Waksman, B.H. (1970) Immunological and anatomical consequences of calf thymosin injection in rats. *Cell Immunol* 1.51.
- Kumoro, K. and Boyse, E.A. (1973) In vitro demonstration of thymic hormone in the mouse by conversion of precursor cells into T-lymphocytes. *Lancet (i)* 740.
- Law, L.W., Trainin, N., Levey, R.H. and Barth, W.F (1964) Humoral thymic factor in mice: further evidence. *Science* 143. 1049.
- Leblond, C.P. and Sainte-Marie, G. (1960) Models for lymphocyte and plasmocyte formation. In: *Haemopoiesis, Cell Production and its Regulation*. 152. Ciba Foundation Symp., London.

Lennert, K., Stein, H., Mohir, N., Kaiserling, E. and Muller-Hermelink, H.K. (1978) Malignant Lymphomas other than Hodgkins disease. Springer-Verlag. New York.

Lewis, R. and Schute, C.L.D. (1966) The distribution of cholinesterase in cholinergic neurons demonstrated with the electron microscope. J Cell Sci 1. 383.

Lillie, R.D. (1951) Simplification of the manufacture of Schiff reagent for use in histochemical procedures. Stain Tech 26. 163.

Lopulchin, Y., Morosov, Y. and Petrov, P. (1973) Transplantation of neonate thymus-sternum complex in ATA. Transplant Proc 5. 823.

Luckey, T.D (1973) Thymic hormones. University Park Press, Baltimore.

Lundwin, S., Kosek, J. and Eng, L. (1976) Topographical distribution of S-100 and GFA proteins in the adult rat brain. J Comp Neurol 165. 197.

Mackay, I.R. and Goldstein, G. (1967) Antibodies from patients with myasthenia gravis react against skeletal and cardiac muscle and thymic cells. Clin Exper Immunol 2. 139.

Mandel, T. (1968) Ultrastructure of the epithelial cells of the cortex of the guinea pig thymus. Z. Zelforsch 92. 159.

Mandel, T. (1970) Differentiation of epithelial cells in the mouse thymus. Z. Zellforsch 106. 498-515.

- Mandi, B. and Glant, T. (1973) Thymosin producing cells of the thymus. *Nature*(New Biol) 246. 25.
- Mandi, B., Holub, M., Rossman, P., Csaba, D. Glant, T. and Olveti, E. (1979) Detection of thymosin V in calf and mouse thymus and in nude mouse dysgenetic thymus. *Folia biologica (Praha)* 25. 49.
- Martinez, D., Field, K.A., Schwam, H., Tytez, A.A. and Hillman, M.R. (1978) failure of thymopoietin, ubiquitin and synthetic serum thymic factor to restore immunocompetance in T-cell deficient mice. *Proc Soc Exp Biol Med* 159. 195.
- Metcalf, D. (1966) Lymphopoiesis in normal and neoplastic tissue. In: *The Thymus*. 242. Ciba Foundation Symp., London.
- Metcalf, D. and Ishidate, M. (1962) PAS positive reticulum cells in the cortex of high and low leukemia strain mice. *Aus J Biol Med Sci* 40. 57.
- Miller, J.F.A.P. and Osoba, D. (1963) Role of the thymus in the origin of immunologic competence. 62. In: *Ciba Found Study Group. Nature and Origin of Immunologically Competent Cells* (16) (Wolstonholme B and Knight T, Eds.) Churchill, London.
- Mitchell, J. and Abbot, A. (1965) Ultrastructure of antigen retaining reticulum of lymph node follicles as shown by high resolution autoradiography. *Nature* 208. 500.

Moore, M.A.S. and Owen, J.J.T. (1967) Experimental studies on the development of the thymus. *J Exp Med* 126. 715.

Muller-Hermelink, H.K., Heusermann, U. and Stutte, H.J. (1974) Enzyme histochemical observations on the localization and structure of the T-cell and B-cell regions in the human spleen. *Cell Tissue Res* 154. 167.

Olah, I., Dunay, C., Rohlich, P. and Toro, I. (1968) A special type of cell in the medulla of the rat thymus. *Acta Biol Acad Sci Hung* 19. 97.

Osoba, D. (1973) Effect of pregnancy on the restoration of the immunologic response in neonatally thymectomized female mice. In: *Contemporary Topics in Immunology* 2. 293. (Carter and Davis, Eds.) Plenum Pub, New York.

Osoba, D. and Miller, J.F.A.P. (1963) Evidence for a humoral factor responsible for the maturation of immunologic faculty. *Nature* 199. 653.

Osoba, D. and Miller, J.F.A.P. (1966) The lymphoid tissues and the immune response of neonatally thymectomized mice bearing thymus tissue in Millipore diffusion chambers. *J Exp Med* 119. 177.

Padykula, H.A. and Hermans, E. (1955) The specificity of the histochemical method for adenosine triphosphatase. *J Histo Cyto* 3. 170.

Pahwa, R., Ikehara, S., Pahwa, S. and Good, R. (1979) Thymic function in man. *Thymus* 1. 27.



Pahwa, R., Pahwa, S., and Good, R. (1978) T-lymphocyte differentiation in severe combined immunodeficiency: defects of the thymus. *Clin Immunol Immunopathol* 11. 437.

Paneth, J. (1887) Zur Frage Nach der Natur der Sarkoplasten. *Anat Anz* 2. 136.

Pease, A.G. (1974) The APUD concept and its implications in pathology. *Path Ann.* 27. Prentice-Hall.

Pensa, A. (1904) Ancora a proposito di una particola distruttura del timo ed osservazioni sullo sviluppo del timo negli anfibuli anuri. *Boll Soc med chir Pavia.* 65.

Pereira, G., and Clermont, Y. (1971) Distribution of cell-web containing epithelial-reticular cells in the rat thymus. *Anat Rec* 169. 613.

Pfoch, M. (1971) Verleichende elektronmikroskopische Untersuchung an entodermalen Thymus-Retikulum zellen neugeborner und alter Wistar-Ratten. *Z Zellforsch* 114. 271.

Puchtler, H.M., Meloan, S.N., Branch, B.W. and Gropp, S. (1975) Myoepithelial cells in the human thymus: Staining, polarization and fluorescence microscopic studies. *Histochem* 45. 176.

Rappay, G., Bukulya, B.M. and Bacsy, E. (1971) Fine structure, distribution and function of the rat thymic reticular cells in perinatal life. *Acta Biol Acad Sci Hung* 22(2). 187.

Rausch, E., Kaiserling, E. and Goos, M. (1977) Langerhans cells and interdigitating reticulum cells in the thymus-dependant region of human dermatopathic lymphadenitis. *Virchows Arch B* 25. 327.

Raviola, E. and Karnovsky, M.J. (1972) Evidence for a blood-thymus barrier using electron-opaque tracers. *J Exp Med* 136. 466.

Raviola, E. and Raviola, G. (1967) Striated muscle cells in the thymus of reptiles and birds, an electron microscopic study. *Am J Anat* 121. 623.

Rouse, R.V., van Ewijk, W., Jones, P.P. and Weissman, I. (1979) Expression of MHC antigens on mouse thymic dendritic cells. *J Immunol* 122. 2508.

Rowden, G., Lewis, M.C. and Sullivan, A.K. (1977) Ia antigen expression of human epidermal Langerhans cells. *Nature* 268. 247.

Rowden, G., Philips, T.M. and Lewis, M.G. (1979) Ia antigen on indeterminate cells of the epidermis: Immunoelectron microscopic studies of surface antigen. *Brit J Dermatol* 100. 531.

Sainte-Marie, G. (1965) The autofluorescent cells of the lymphocytic tissue of the rat. *Anat Rec* 151. 133.

Scheid, M.P., Goldstein, G., Hammerling, U. and Boyse, E.A. (1975) Lymphocyte differentiation from precursor cells in vitro. *Ann NY Acad Sci* 249. 531

Scheinberg, M.A., Cathcart, E.S. and Goldstein, A.L. (1975) Thymosin induced reduction of 'null-cells' in peripheral blood of patients with systemic lupus erythematosus. *Lancet* (i) 424.

Schlesinger, D.H., Goldstein, G. and Niall, H.D. (1975A) The complete amino acid sequence of ubiquitin, an adenyl-cyclase stimulating polypeptide probably universal in all living cells. *Biochem* 14. 2214.

Schlesinger, D.H., Goldstein, G., Scheid, M.P. and Boyse, E.A. (1975B) Chemical synthesis of a peptide fragment of thymopoietin II that induces selective T-cell differentiation. *Cell Immunol* 5. 367.

Schlesinger, M., Israel, E., Chaout, M. and Gery, I. (1975C) The nature and function of T-cell antigens. *Ann N Y Acad Sci* 249. 508.

Schmitt, D., Monier, J.C., Dardenne, M., Pleau, J.M., Deschaux, P. and Bach, J.F. (1981) Cytoplasmic localization of FTS in thymic epithelial cells, an immunoelectronmicroscopical study. *Thymus* 2. 177.

Sharp, J.A. and Woo-Sam, P.C. (1978) Acetylcholinesterase in myoid and epithelial cells of the rabbit thymus. *J Anat* 127. 642.

Silberberg-Sinakin, I., Gigli, I., Baer, R.L. and Thorbecke, G. (1980) Langerhans cells: Role in contact hypersensitivity and relationship to lymphoid dendritic cells and to macrophages. *Immunol Rev* 53. 203.

Small, M. and Trainin, N. (1971) Contribution of a thymic humoral factor to the development of an immunologically competent population from cells of mouse bone marrow. *J Exp Med* 134. 786.

Smith, C. (1961) Studies on the thymus of the mammal XII. J Nat Cancer Inst 26(2). 389.

Steffansson, K., Wollmann, R., Moore, B. and Arnason, B. (1982) S-100 protein and chondrocytes. Nature 295. 63.

Steinman, R.M., Kaplan, G., Witmer, M. and Cohn, Z.A. (1979) Identification of a novel cell in the peripheral lymphoid organs of mice. V. Purification of spleen dendritic cells, new surface markers and maintenance in vivo. J Exp Med 149. 1.

Steinman, R.M., Witmer, M.D., Nussenzweig, M.C., Chen, L.L., Kaplan, G. and Cohn, Z.A. (1980) Dendritic cells, an important new cell type in MHC-linked function. 297. In: Macrophage Regulation of Immunity. (Unanue and Rosenthal, Eds.) Academic Press. New York.

Steinman, R.M. and Witmer, M.D. (1978) Lymphoid dendritic cells are potent stimulators of the primary mixed leukocyte reaction in mice. Proc Nat Acad Sci 75. 5132.

Strauss, A.J.L., Kemp, P.G. and Douglas, S.D. (1966) Myasthenia gravis. Lancet (ii) 772.

Strom, T.B. and Shapiro, J. (1980) Electrophysiology of T-lymphocyte cholinergic receptors. Fed Proc. Abs. No. 3522. 941.

Stutman, O. (1975) Thymic hormones. Ann NY Acad Sci 249. 19.

Stutman, O., Yunis, E.J. and Good, R. (1969) Carcinogen induced tumors of the thymus, III. Restoration of neonatally thymectomized mice with thymomas in cell impenetrable chambers. *J Nat Cancer Inst* 43. 499.

Stutman, O., Yunis, E.J. and Good, R. (1970) Studies on thymus function: Cooperative effect of thymic function and lymphohaemopoietic cells in restoration of neonatally thymectomized mice. *J Exp Med* 132. 583.

Takahashi, K., Yamaguchi, H., Ishizeki, J., Nakajima, T. and Nakazato, Y. (1981) Immunocytochemical and immunoelectron microscopic localization of S-100 protein in interdigitating-reticular cells of the human lymph node. *Virchow's Arch (Cell Pathol)* 37. 125-135.

Teodorczyk, J., Potworowski, E. and Sviculius, A. (1975) Cellular localization and antigenic specificity of thymic factors. *Nature* 258. 617.

Tien-Sun, T., Shih, C. and Green, H. (1979) Keratin cytoskeletons of epithelial cells of internal organs. *Proc Nat Acad Sci* 76(6).2813.

Thorbecke, G.J., Silberberg-Sinakin, I. and Folotte, T.J. (1980) Langerhans cells as macrophages in skin and lymphoid organs. *J Invest Dermatol* 75(1) 32.

Toro, I., Olah, I., Rohlich, P. and Virajh, S.Z. (1969) Electron microscopic observations on the myoid cells of the frog thymus. *Anat Rec* 165. 329.

Touraine, J.L., Incefy, G.S., Touraine, F., Rhoy, M. and Good, R.A. (1974) Differentiation of human bone marrow cells into T-cells by in vitro incubation with thymic extracts. *Clin Exp Immunol* 17. 151.

Trainin, N. (1974) Thymic hormones and the immune response. *Phys Rev* 54(2). 272.

Trainin, N., and Small, M. (1970) Studies on some physicochemical properties of a thymus humoral factor conferring immunocompetence on lymphoid cells. *J Exp Med* 132. 885.

van der Geld, H., Feltkamp, T.E. and Oosterhuis, H.J. (1964) Reactivity of myasthenia gravis serum gamma-globulin with skeletal muscle and thymus demonstrated by immunofluorescence. *Proc Soc Exper Biol Med* 115. 782.

van Haelst, U.J.G. (1969) Light and electron microscopic study of the normal and pathologic thymus of the rat III. *Z Zellforsch* 99. 198.

Van de Velde, R.L. and Friedman, N.B. (1970) Thymic myoid cells and myasthenia gravis. *Am J Path* 59(2). 347.

van den Tweel, J.G. and Walker, W.S. (1977) Macrophage induced thymic lymphocyte maturation. *Immunol* 33. 817.

van den Tweel, J., Taylor, C., McClure, J. and Goldstein, A. (1978) Detection of thymosin in thymic epithelial cells by an immunoperoxidase method. *Proc Int Confer. Germinal Centers & Lymphatic Tis, Kiel.*

Veerman, A.J.P. and Rooijen, N. van (1975) Lymphocyte capping and lymphocyte migration as associated with the in vivo trapping process Cell Tissue Res 161.211.

Veldman, J.E. (1970) Histophysiology and electron microscopy of the immune response. Academic thesis, Groningen, Netherlands State Univ.

Vetters, L. and Macadam, P. (1973) Hormone production in the thymus. J Clin Path 26. 194.

von Gaudecker, B. and Muller-Hermelink, H.K. (1978) Ultrastructure of the age involuted adult thymus. Cell Tissue Res 186(3). 507.

Wachstein, M. and Meisel, E. (1957) Histochemistry of adenosine triphosphatases. Am J Clin Pathol 27. 13.

Wekerle, H., Ketelsen, U.P. and Ernst, M. (1980) Thymic nurse cells. J Exp Med 925.

Wekerle, H., Ketelsen, U.P., Zum, A.D. and Fulpius, B.W. (1978) Intrathymic pathogenesis: Transient expression of acetylcholine receptors in thymic-derived myogenic cells. Eur J Immunol 8. 59.

Weibel, E. (1973) Morphometrics and stereology. 262. In: Techniques for Electron Microscopy; Biological Applications. (Hayat, Ed). Van Nostrand-Reinhold.

Wolff, K. (1972) The Langerhans cell. Current Problems in Dermatology 4. 80.

Zechckson, A.S. and Mottaz, J.H. (1968) Epidermal dendritic cells. A quantitative study. Arch Dermatol 98. 652.

Zinkernagel, R.M., Callahan, G.N., Althage, E., Cooper, S., Klein, P.A. and Klein, J. (1978) On the thymus in the differentiation of H-2 self-recognition by T-cells: Evidence for dual recognition. J Exp Med 147. 882.



APPROVAL SHEET

The dissertation submitted by Howard R. Higley has been read and approved by the following committee:

Dr. Charles C.C. O'Morchoe, Director  
Professor and Chairman, Anatomy, Loyola

Dr. Gwen C. Childs,  
Associate Professor, Anatomy, Univ. of Texas

Dr. Raoul Fresco,  
Professor, Pathology, Loyola


Dr. Charles F. Lange,  
Professor, Microbiology, Loyola

Dr. John A. McNulty,  
Associate Professor, Anatomy, Loyola

Dr. Rajinder P. Nayyar,  
Adjunct Associate Professor, Anatomy, Loyola

The final copies have been examined by the director of the dissertation and the signature which appears below verifies the fact that any necessary changes have been incorporated and that the dissertation is now given final approval by the Committee with reference to content and form.

The dissertation is therefore accepted in partial fulfillment of the requirements for the degree of Ph.D.

A large, stylized handwritten signature in black ink, appearing to read "O'Morchoe", is written over a horizontal line. The signature is highly cursive and loops around itself.

Date

11/18/82

Director's Signature