

Breast calcifications following electrical defibrillation: An unusual mammographic appearance

Steven M. Westphal, MD, Manish Jani, MD, and Sunil Badve, MD

We present a case of a 57-year-old woman with a past medical history of end-stage renal disease and a recent history of electrical defibrillation who arrived for her annual mammogram with no breast-related complaints. The mammogram showed interval development of unusual clusters of heterogeneous calcifications. The patient underwent stereotactic core-needle biopsy for definitive diagnosis. The pathologic evaluation revealed fibrosis, abnormal adipocytes, and calcifications with no evidence of malignancy.

Introduction

Microcalcifications develop in the breast for a number of reasons. Most causes are benign, representing fibrocystic changes, involuting fibroadenomas, post-traumatic fat necrosis, or adenosis. Not uncommonly, however, microcalcifications identified on a mammogram are the result of atypical hyperplasia or frank malignancy such as ductal carcinoma in situ (DCIS). Ideally, mammographers would biopsy only malignant calcifications and not the benign ones. Frequently, however, the distinction between malignant and benign is not easily made. In order to make this distinction, we scrutinize the morphology, distribution, and stability of the calcifications. Calcifications that are layering, have central lucency, are popcorn-like, or follow along arterial walls are benign and require no additional evaluation. Calcifications that are pleomorphic or fine linear and branching in nature are concerning for malignancy, and the need for biopsy is clear. In most cases, calcifications that are not clearly benign must undergo tissue sampling to exclude malignancy.

We discuss a woman who developed regions of heterogeneous calcifications in her left breast six months after transthoracic electrical cardiac defibrillation. Stereotactic vacuum-assisted biopsy of the calcifications revealed fibrosis and fat necrosis, and no evidence of malignancy. Correlation between the imaging and pathologic findings led us to believe that electrical defibrillation was the cause of the patient's unusual breast calcifications. While calcifications induced by electrical defibrillation may mimic those of carcinoma, knowledge of this as a potential cause of breast calcifications may help to avoid biopsy in some patients.

Case report

A 57-year-old white female presented to the emergency department with chest discomfort. Shortly after her arrival, advanced cardiac life support was initiated for cardiac arrest related to hyperkalemia. Her past medical history was significant for end-stage renal disease that developed as a result of retroperitoneal fibrosis. She routinely underwent peritoneal dialysis.

During resuscitative efforts, the patient developed ventricular tachycardia and became hemodynamically unstable. She underwent transthoracic electrical defibrillation with five countershocks, delivering energies up to 360 Joules. She was stabilized and, after 30 minutes of advanced cardiac life support, was admitted to the hospital for supportive care.

The patient was discharged one week later with two large burns on the lower aspects of both breasts, worse on the left, where the defibrillator pads had been placed. A follow-up office visit two months later revealed large ulcerations with granulation tissue, but no signs of infection. Prophylactic bacitracin ointment was prescribed, and the skin burns healed over the next two months.

Citation: Puri AS, Westphal SM, Jani M, Badve S. Breast calcifications following electrical defibrillation: An unusual mammographic appearance. *Radiology Case Reports*. [Online] 2010;5:346.

Copyright: © 2010 The Authors. This is an open-access article distributed under the terms of the Creative Commons Attribution-NonCommercial-NoDerivs 2.5 License, which permits reproduction and distribution, provided the original work is properly cited. Commercial use and derivative works are not permitted.

Drs. Westphal and Jani are in the Department of Radiology and Imaging Sciences, and Dr. Badve is in the Department of Pathology, all at Indiana University School of Medicine, Indianapolis IN, USA. Contact Dr. Westphal at smwestph@iupui.edu.

Competing Interests: The authors have declared that no competing interests exist.

DOI: 10.2484/rcr.v5i2.346

Breast calcifications following electrical defibrillation: An unusual mammographic appearance

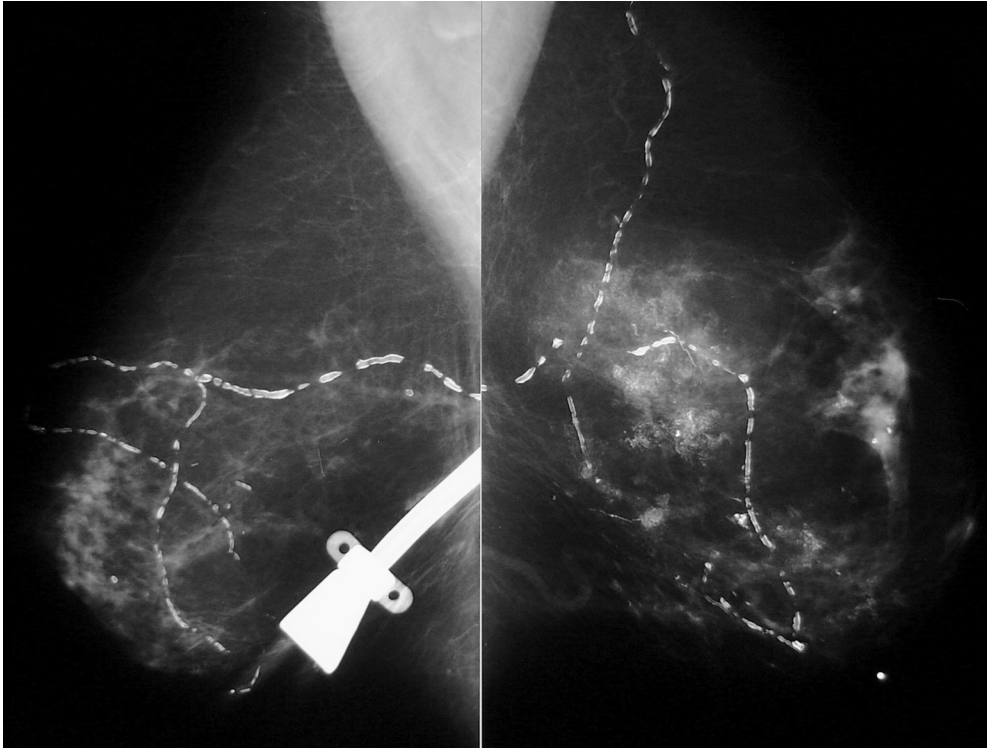

Figure 1A. 57-year-old female with breast calcifications. MLO images from the patient's screening mammogram demonstrate regions of abnormal-appearing calcifications in the left breast. Note the dialysis catheter over the right breast.

firm area of thickening corresponding to the area of previous defibrillation. The mammograms revealed predominantly fatty breast parenchyma. When this mammogram was compared to the previous ones, it was clear that there had been interval development of several regions of heterogeneous macrocalcifications and microcalcifications in the left breast (Fig. 1).

The patient was called back for additional mammographic views of the left breast, which included spot magnification views in the craniocaudal (CC) and mediolateral (ML) projections, in order to further character-

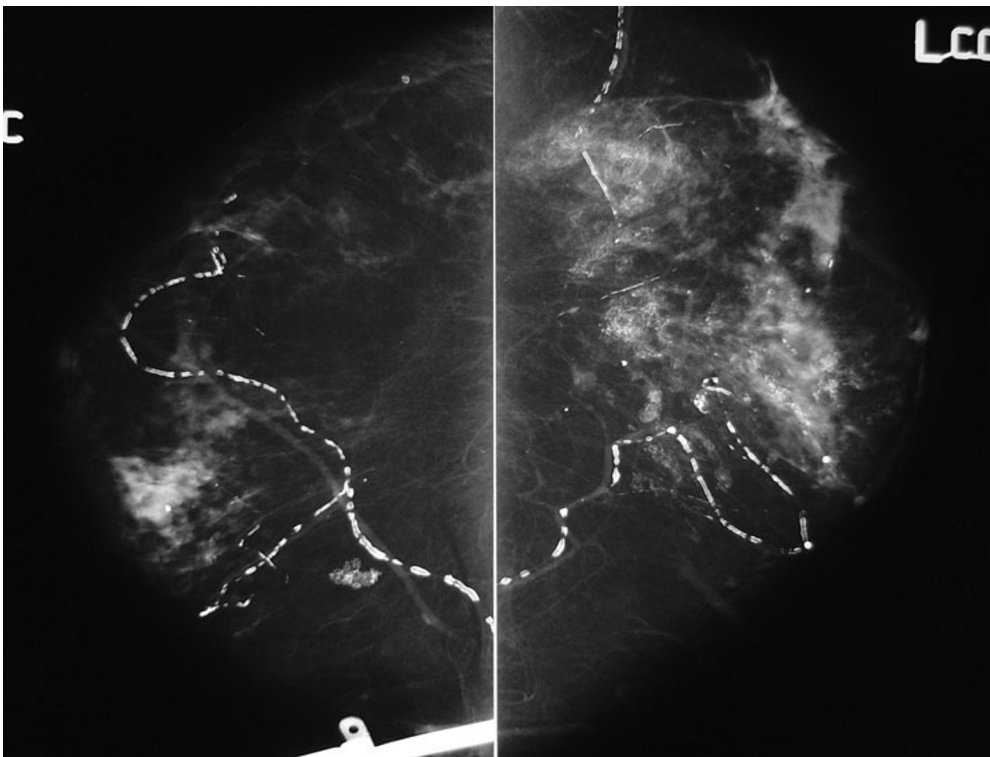


Figure 1B. 57-year-old female with breast calcifications. CC images from the patient's screening mammogram demonstrate regions of abnormal-appearing calcifications in the left breast. Note the dialysis catheter over the right breast.

ize the calcifications (Fig. 2). The most suspect group of calcifications was in the posterior third of the central left breast. These had a clumped, reticular appearance, likened to steel wool. There were no suspect findings in the right breast. A final BI-RADS assessment

Six months after her initial visit to the emergency department, the patient presented for a routine screening mammogram. The mammography technologist noted a

category 4 was assigned based on the distribution, morphology, and interval development of the calcifications. A stereotactic-guided, vacuum-assisted core-needle biopsy

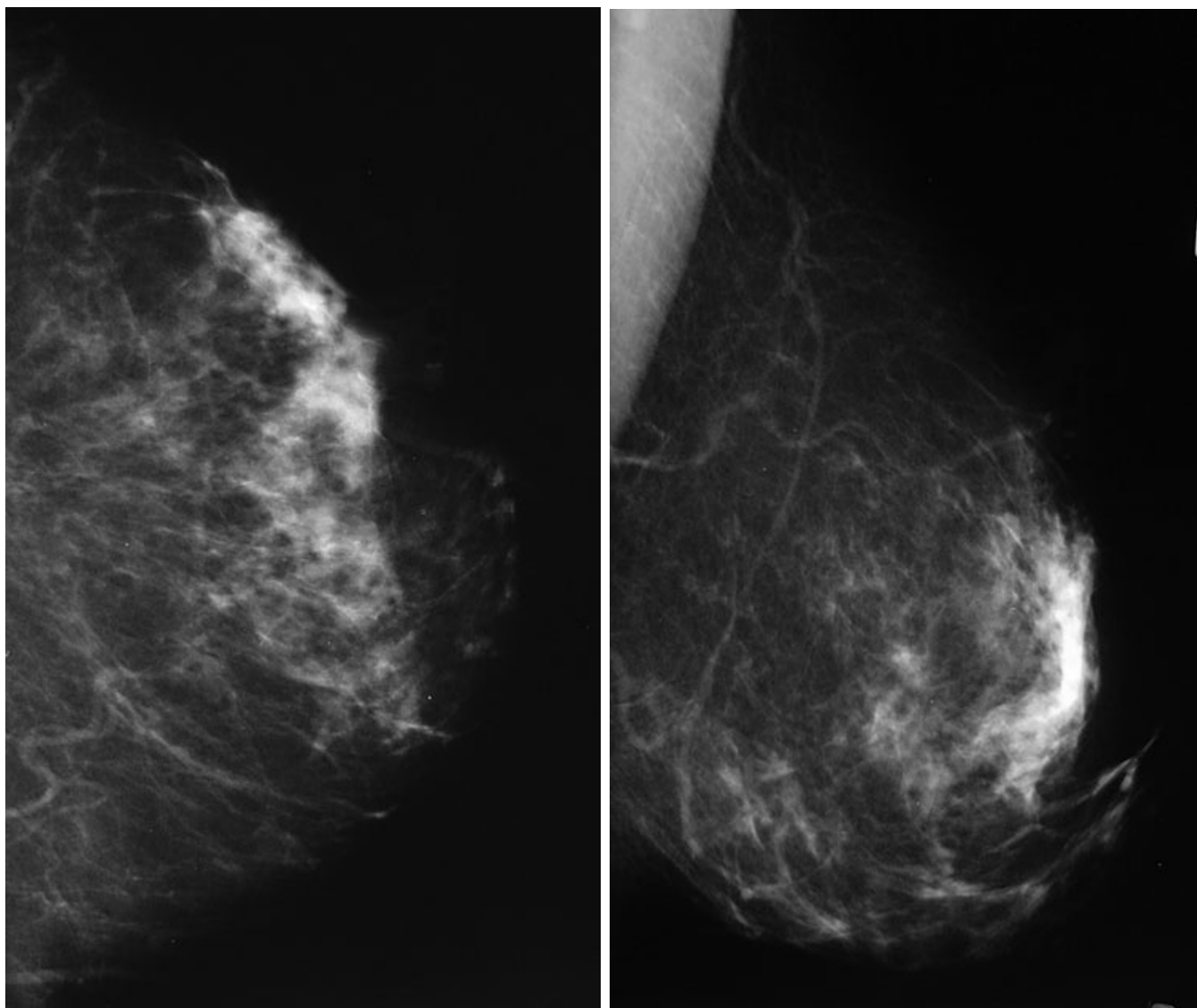


Figure 1C. 57-year-old female with breast calcifications. Left breast CC (left) and MLO (right) images from the patient's prior screening mammogram demonstrate no abnormal calcifications.

was performed 18 days later. Eight 11-gauge core-biopsy samples were submitted to pathology for interpretation (Fig. 3).

Pathologic evaluation of the eight yellow-gray fibrofatty core specimens revealed fibrosis with extensive nonrefractive microcalcifications, with no evidence of malignancy. More specifically, the samples demonstrated nonuniform adipocytes, fibrosis, large lipid vacuoles, and calcifications (Fig. 4), a pattern typical of fat necrosis.

Given the histologic appearance of the tissue and the history of severe skin burns, the calcifications were considered concordant with our imaging findings, and routine annual followup was recommended.

Discussion

Fat necrosis was first described by Lee and Adair in 1920 (1). Since then, the clinical, pathologic, and mammographic findings of fat necrosis have been described in detail. Clinically, fat necrosis can be completely asymptomatic or may present with pain or as a mass (1). The mammographic features of fat necrosis are varied. The spectrum of fat necrosis on mammograms includes lipid-filled cysts with or without calcified walls; a spiculated mass with or without associated skin changes; and branching, rodlike, or angular microcalcifications (2, 3). Many of these characteristics overlap with the characteristics of carcinoma.

Breast calcifications following electrical defibrillation: An unusual mammographic appearance

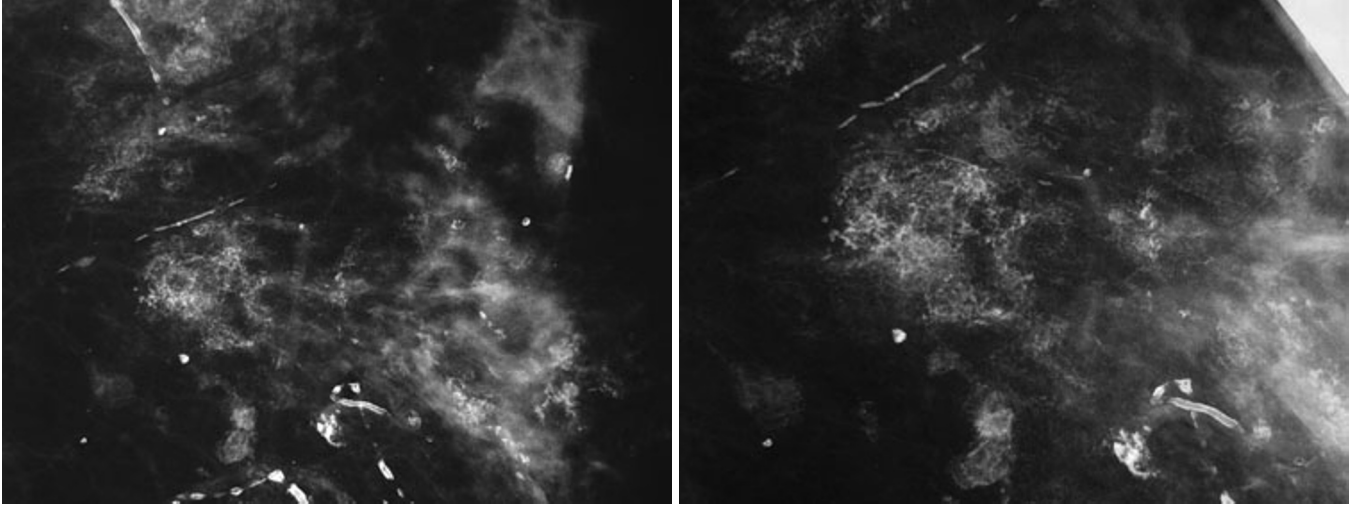


Figure 2. 57-year-old female with breast calcifications. Left breast spot magnification CC (left) and spot magnification ML (right) images from the patient's diagnostic mammogram demonstrate the reticular appearance of the calcifications.

Fat necrosis is characterized histologically by the presence of coalescent lipid-containing vacuoles that can range in size from less than one millimeter to several centimeters (3). Multinucleated giant cells and aggregates of foamy phagocytic histiocytes proliferate around the lipid vacuole. Fibro-

be related to a known traumatic event. One example would be the breast injury caused by the shoulder restraint during a motor vehicle collision (4). In one series, for approximately 40% of cases of fat necrosis, trauma was the inciting cause (4). To our knowledge, fat necrosis of the breast

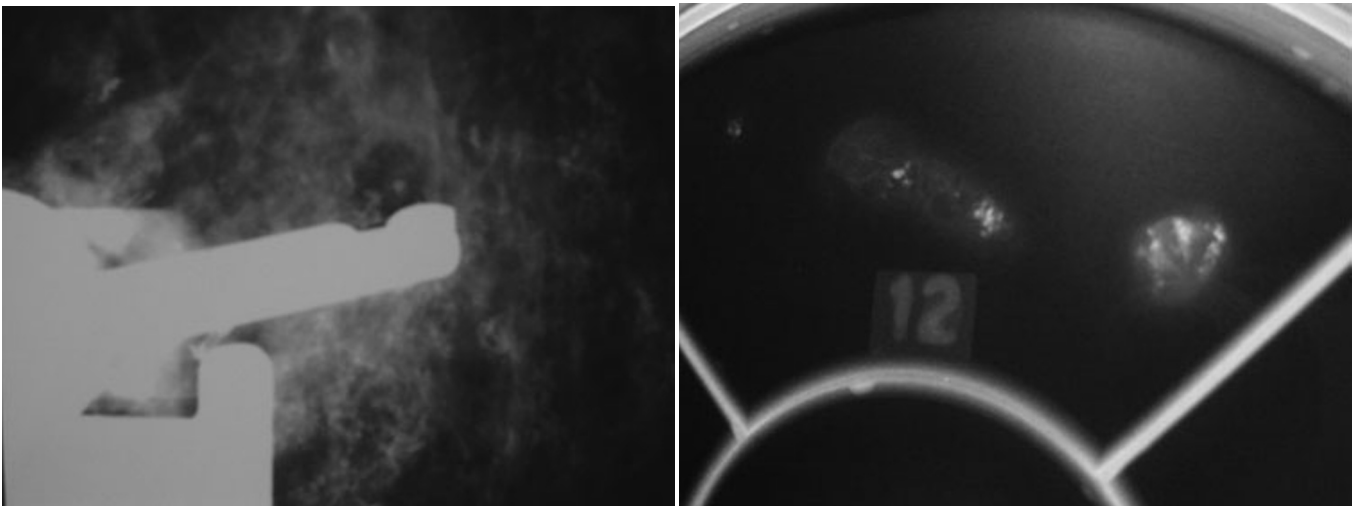


Figure 3. 57-year-old female with breast calcifications. Images from the stereotactic core-needle biopsy. The image on the left shows the position of the vacuum-assisted biopsy device before collection of the calcifications. Note the calcifications adjacent to the bowl of the needle. The specimen radiograph (right) demonstrates that calcifications are present within the tissue samples.

blasts infiltrate the area and form fibrous tissue around the central lipid vacuole. Calcification may occur in these areas of fibrosis.

In many cases, fat necrosis is related to breast trauma, which can be accidental or iatrogenic (1). The cause of the traumatic injury to the breast may remain unknown or may

as the result of transthoracic defibrillation has not been previously described.

Little has been published regarding adipose tissue damage from defibrillation. The pathophysiology of dermal and skeletal muscle damage after transthoracic cardioversion has been documented (5, 6). Skin biopsies 24 hours

Breast calcifications following electrical defibrillation: An unusual mammographic appearance

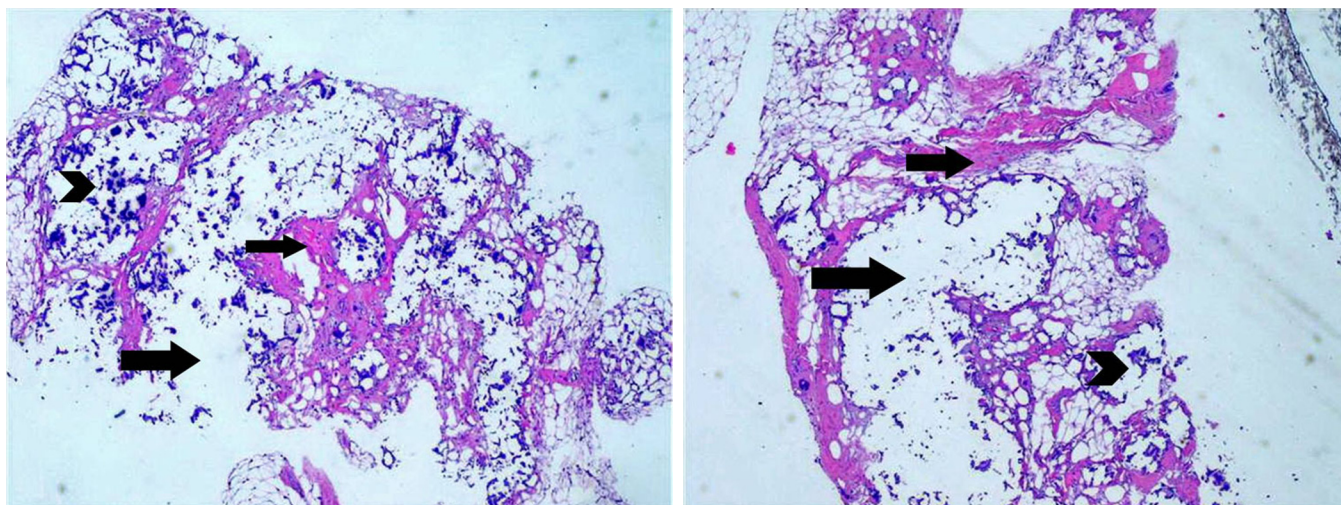


Figure 4. 57-year-old female with breast calcifications. Photomicrographs of the tissue samples demonstrating nonuniform adipocytes, fibrosis (small arrow), large lipid vacuoles (large arrow), and calcifications (arrowheads).

after cardioversion reveal focal epidermal necrosis, multinucleated keratinocytes, and perivascular lymphoid inflammation (5). Neutrophils and eosinophils are often present. These findings essentially represent a first-degree burn. Histopathology shows that muscle damage is significantly greater when high peak energy and cumulative shocks are given (5). This has been attributed to Joule heating or electrochemical reaction related to high skin impedance (5).

Thermal injury, however, cannot fully explain the pattern of injury seen in some electrical injuries. Skeletal muscle and nerve damage has been shown to occur through electroporation (6). This term describes the formation of enlarging gaps in a cell's membrane induced by electrical forces driving polar water molecules into such defects. When the size of the gap exceeds a critical value, the membrane ruptures. This causes an influx of calcium ions, leading to vacuolization and contracted myofilaments (6).

Little data is available regarding the development of fat necrosis or calcifications in the breast related to transthoracic defibrillation. It is likely the combined result of both thermally mediated damage and electroporation. Whatever the underlying mechanism, it is clear that electrical defibrillation, especially when repeated high-peak voltages are applied, can result in tissue damage. The damaged tissue then undergoes repair or fibrosis, and calcium may be deposited. The manner in which the calcification is laid down can lead to the atypical pattern of calcifications seen in our patient. It is unclear whether the patient's history of end-stage renal disease may have also contributed to the development of the unusual calcifications.

After histopathologic correlation, the unusual calcifications in this case were felt to be the result of tissue damage sustained during repeated cardiac defibrillation and the subsequent healing of that damage. The patient has not

developed a breast malignancy in two years following the biopsy.

In women undergoing mammography who develop a large area of abnormal microcalcifications, it is important to keep in mind that external factors such as trauma may explain the appearance of calcifications in the breast, and careful history-taking may elucidate the cause. In these cases, short-interval followup examination may supplant the need for biopsy. In many cases, however, even if there is an appropriate history, abnormal microcalcifications will still require biopsy to exclude malignancy.

References

1. Adair FE, Munzer JT: Fat necrosis of the female breast: report of 110 cases. *Am J Surg.* 1947; 74(2):117-128. [[PubMed](#)]
2. Bassett LW, Gold RH, Cove HC. Mammographic spectrum of traumatic fat necrosis: the fallibility of "pathognomonic" signs of carcinoma. *Am J Roentgenol.* 1978 Jan; 130(1):119-122. [[PubMed](#)]
3. Hogge JP, Robinson RE, Magnant CM, Zuurbier RA. The mammographic spectrum of fat necrosis of the breast. *Radiographics.* 1995 Nov; 15(6): 1347-1356. [[PubMed](#)]
4. DiPiro PJ, Meyer JE, Frenna TH, Denison CM. Seat belt injuries of the breast: findings on mammography and sonography. *AJR.* 1995 Feb; 164(2): 317-320. [[PubMed](#)]
5. Pagan-Carlo LA, Stone MS, Kerber RE. Nature and determinants of skin "burns" after transthoracic cardioversion. *Am J Cardiol.* 1997 Mar; 79(5):689-691. [[PubMed](#)]
6. Block TA, Aarsvold JN, Matthews KL, et al. Nonthermally mediated muscle injury and necrosis in electrical trauma. *J Burn Care Rehabil.* 1995 Nov; 16(6):581-588. [[PubMed](#)]