



# An Uncommon Presentation of Breast Implant Rupture

Eugene Koh, MBBS, MSc\*  
David I. Watson, MD, FRACS†  
Nicola R. Dean, MBChB,  
PhD, FRACS(Plas)\*

**Summary:** Late periprosthetic seroma has lately been concerning for breast implant-associated anaplastic large cell lymphoma. The authors present an uncommon presentation of breast implant rupture with a seroma and skin rash forming 2 years after insertion of the implant. (*Plast Reconstr Surg Glob Open* 2016;4:e719; doi: 10.1097/GOX.0000000000000699; Published online 26 May 2016.)

**B**reast implant-associated anaplastic large-cell lymphoma (ALCL) is a concerning clinical entity that has been observed in recent years. A well-known mode of presentation for ALCL is late periprosthetic seroma. We present a case of late seroma occurring in the context of implant rupture, with no detectable ALCL.

## CASE REPORT

A 69-year-old woman presented in late December 2014 with gross swelling of her reconstructed left breast and a maculopapular rash. She had undergone delayed bilateral implant based reconstruction 2 years previously, after right therapeutic and left prophylactic mastectomy. The reconstruction was performed in 2 stages with textured surface tissue expanders (PMT Integra, PMT Corporation, Minn.), followed by imprint-textured surface, cohesive gel implants (Mentor Contour Profile Gel, Mentor Worldwide LLC, Calif.). There were no immediate postoperative complications, and all was well at a follow-up appointment 24 months after

surgery, and follow-up photographs were obtained (Fig. 1).

The patient then presented 3 weeks later with marked swelling of the reconstructed left breast and a maculopapular rash developed around the reconstructive scar on the same side over the previous week (Fig. 2). For the rash, she had previously seen a dermatologist, who prescribed steroid cream and tablets, with no improvement. Ultrasound and magnetic resonance imaging were obtained. Ultrasonography revealed a large volume of fluid surrounding the left breast implant, and 840 ml of viscous straw-colored fluid was aspirated under ultrasound guidance, and sent for cytology. Magnetic resonance imaging of the reconstructed breast revealed a rupture of the left breast implant, with a tear in the silicone rubber shell visible on its deep aspect, at the shell patch juncture (Fig. 3). There were no systemic signs of infection, and the white cell count was normal. However, C-reactive protein was increased to 120 mg/l.

Surgery was undertaken, and an obvious tear was seen at the interface of the smooth and textured parts of the posterior surface of the implant (Fig. 4). The likely cause at that stage was considered to be implant rupture due to either mechanical forces or a one-off manufacturing fault. As the patient had not had any problems with the contralateral identical implant, a new implant of the same size and brand was inserted. Postoperatively, there was <20 ml of output in the surgical drain across the first 12 hours after surgery, and the rash resolved

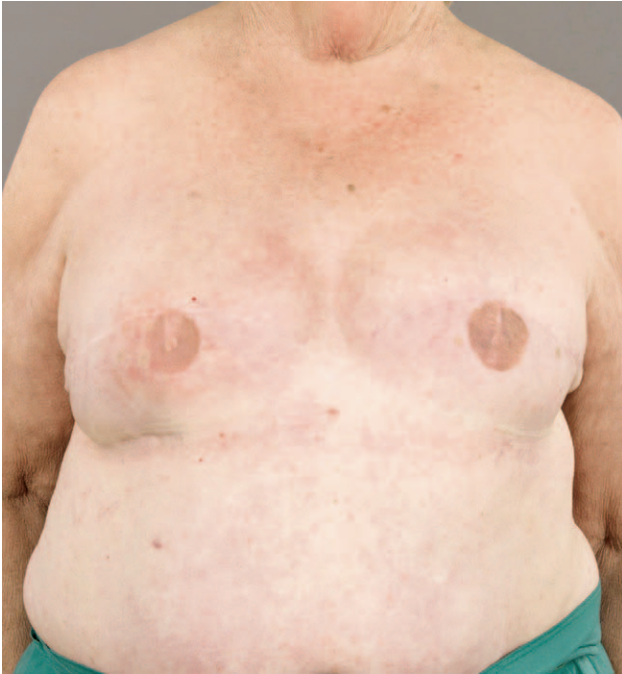From the \*Department of Plastic and Reconstructive Surgery, Flinders Medical Centre, Bedford Park, South Australia, Australia; and †Department of Surgery, Flinders University, Bedford Park, South Australia, Australia.

Received for publication January 28, 2016; accepted March 9, 2016.

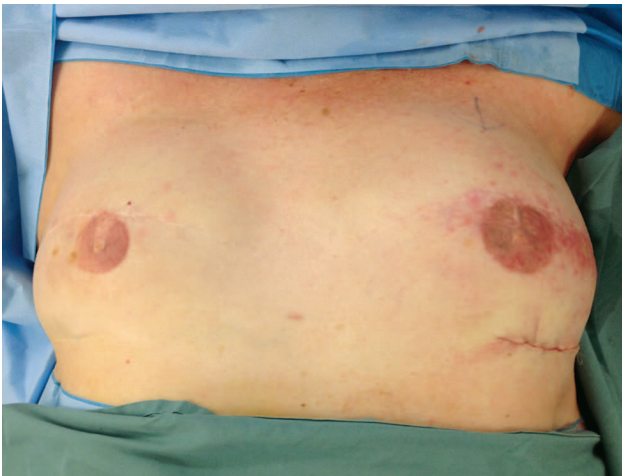
Copyright © 2016 The Authors. Published by Wolters Kluwer Health, Inc. on behalf of The American Society of Plastic Surgeons. All rights reserved. This is an open-access article distributed under the terms of the Creative Commons Attribution-Non Commercial-No Derivatives License 4.0 (CCBY-NC-ND), where it is permissible to download and share the work provided it is properly cited. The work cannot be changed in any way or used commercially.

DOI: 10.1097/GOX.0000000000000699

**Disclosure:** The authors have no financial interest to declare in relation to the content of this article. The Article Processing Charge was paid for by the Department of Plastic and Reconstructive Surgery, Flinders University, South Australia.



**Fig. 1.** Follow-up picture obtained weeks before the onset of symptoms.



**Fig. 2.** Picture obtained at the time of replacement of the left breast implant shows the maculopapular rash around the scar of the previous incision.

within days of having the implant replaced. The ruptured implant was also returned to the manufacturer for testing, which did not reveal any manufacturing defects.

Analysis of the seroma fluid revealed an inflammatory exudate, and flow cytometry did not reveal any evidence of lymphoma or neoplasia. A skin biopsy at that time showed tinea incognito and no neoplasia. There were no postoperative complications, and 12 months later, there has not been any recurrence of the swelling or rash.

## DISCUSSION

Our patient developed a late seroma in a reconstructed breast after rupture of a silicone breast implant. Silicone has long been thought to be an inert material, which can be safely be implanted in the human body. However, in the 1970s and 1980s, there was significant focus on the possibility of severe immune reactions to silicone gel. Ojo-Amaize et al<sup>1</sup> found that 25% of women with silicone breast implants who were experiencing symptoms, such as muscle weakness and chronic fatigue, developed abnormal T-cell responses to silicone. Narini et al<sup>2</sup> found, in animal models, that injection of silicone gel induced an antigen-specific lymphocyte-mediated response in the animal, thereby causing a delayed type hypersensitivity. Dargan et al reported a delayed hypersensitivity reaction to a textured silicone implant within weeks of insertion, in a woman who had undergone removal of a prosthesis 3 years earlier, after wound dehiscence. Capsule biopsies demonstrated a large lymphoid cell reaction, consistent with a delayed type hypersensitivity reaction.<sup>3</sup> It is this hypersensitivity reaction that can lead to the release of inflammatory mediators like histamine and prostaglandins, causing the formation of a seroma.

Late periprosthetic seroma is rare, with 1 series of 47,028 patients reporting an incidence of 0.13% of seroma formation occurring  $\geq 1$  year after implantation.<sup>4</sup>

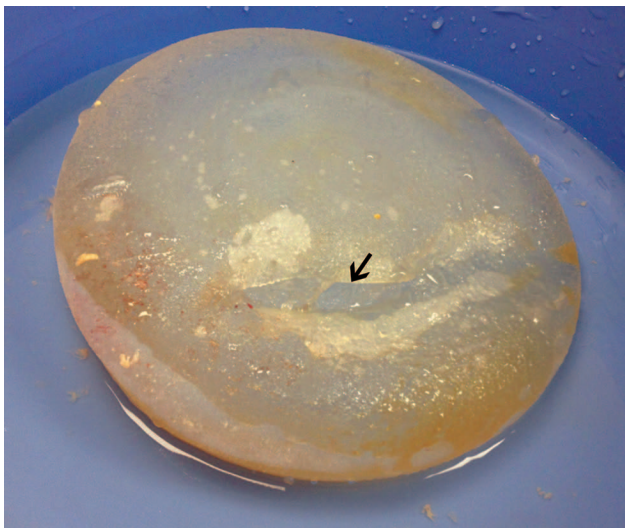
ALCL is a rare disease; making up only 2% of all newly diagnosed non-Hodgkin's lymphomas worldwide. Despite that, multiple cases of ALCL developing next to breast implants have been reported.<sup>5</sup> According to the World Health Organization, it can be classified into 2 types: the systemic type, affecting lymph nodes and extranodal sites (causing systemic symptoms), and the cutaneous type (causing skin lesions).<sup>6</sup> When a woman presents with a seroma or mass  $>6$  months after insertion of a breast implant, the possibility of ALCL is of great concern. There has been a great deal of focus on ALCL more recently, but no work looking at possible links with previous immune reactions. It may be that understanding the broad areas of immune reactions to silicone gel and to late seromas in those without ALCL will be helpful in expanding the understanding of ALCL itself.

Ruptured breast implants can commonly cause a change in the breast shape, lumpiness, localized skin redness, tenderness, and sensitivity. Clinical examination has a reported 30% sensitivity of detecting a ruptured breast implant, whereas magnetic resonance imaging has the highest sensitivity at 90%.<sup>7,8</sup>

There is only 1 other reported case of rash arising from a ruptured breast implant; however, this was involving rupture of Poly Implant Prothèse implants (Poly Implant Prothèse, France), whose silicone did not meet appropriate standards.<sup>8</sup>



**Fig. 3.** Magnetic resonance imaging showing breach of the envelope at the deep aspect of the implant. Multiple areas of water signal content are noted within the silicone in the implant.



**Fig. 4.** Arrow indicating 5-cm rupture of the deep surface of the implant at the shell patch juncture.

### CONCLUSIONS

We report an uncommon presentation of breast implant rupture, with a skin rash and seroma forming 2 years after insertion of the implant. Although silicone has been thought to be inert and safe for implantation into the human body, several studies have shown an immune response to silicone in a proportion of patients, even with intact implants. Careful evaluation is needed, and given the growing concern of a link between ALCL and breast implants,

this must also be considered when surgeons are confronted with such a problem.

*Eugene Koh, MBBS, MSc*  
 Flinders Medical Centre  
 Flinders Drive, Bedford Park  
 SA 5042, Australia  
 E-mail: Eugene.Koh@sa.gov.au

### REFERENCES

1. Ojo-Amaize EA, Conte V, Lin HC, et al. Silicone-specific blood lymphocyte response in women with silicone breast implants. *Clin Diagn Lab Immunol.* 1994;1:689–695.
2. Narini PP, Semple JL, Hay JB. Repeated exposure to silicone gel can induce delayed hypersensitivity. *Plast Reconstr Surg.* 1995;96:371–380.
3. Dargan D, McGoldrick C, Khan K. Type IV hypersensitivity to a textured silicone breast implant. *J Plast Reconstr Aesthet Surg.* 2012;65:969–972.
4. Bengtson B, Brody GS, Brown MH, et al.; Late Periprosthetic Fluid Collection after Breast Implant Working Group. Managing late periprosthetic fluid collections (seroma) in patients with breast implants: a consensus panel recommendation and review of the literature. *Plast Reconstr Surg.* 2011;128:1–7.
5. Kim B, Roth C, Chung KC, et al. Anaplastic large cell lymphoma and breast implants: a systematic review. *Plast Reconstr Surg.* 2011;127:2141–2150.
6. Taylor KO, Webster HR, Prince HM. Anaplastic large cell lymphoma and breast implants: five Australian cases. *Plast Reconstr Surg.* 2012;129:610e–617e.
7. Institute of Medicine. *Safety of Silicone Breast Implants.* WA, DC: The National Academies Press; 1999.
8. Mallon P, Ganachaud F, Malhaire C, et al. Bilateral poly implant prosthesis implant rupture: an uncommon presentation. *Plast Reconstr Surg Glob Open* 2013;1:e29.