

IMMUNOEXPRESSION OF HOXB7 AND HOXB9 IN SALIVARY GLAND TUMOURS

Felipe Paiva Fonseca^{1,2}, Lynne Bingle², Alan Roger Santos-Silva¹, Márcio Ajudarte Lopes¹, Ricardo D. Coletta¹, Bruno Augusto Benevenuto de Andrade³, Fernanda Viviane Mariano¹, Luiz Paulo Kowalski⁴, Ana Lúcia Carrinho Ayroza Rangel⁵, Manoela Domingues Martins⁶, Luise Meurer⁶, Keith D. Hunter^{2,7}, Paul M. Speight² and Pablo Agustin Vargas^{1,7}

1. Piracicaba Dental School and Faculty of Medicine – University of Campinas – Brazil.
2. Department of Oral and Maxillofacial Pathology – School of Clinical Dentistry – The University of Sheffield – UK.
3. Dental School – Federal University of Rio de Janeiro – Brazil.
4. Department of Otorhinolaryngology and Head and Neck Surgery – A.C. Camargo Cancer Center – Brazil.
5. Dental School – State University of Western Paraná – Brazil.
6. Medical and Dental Schools – Federal University of Rio Grande do Sul – Brazil.
7. Extraordinary Professor, Department of Oral Pathology and Oral Biology, School of Dentistry, Faculty of Health Sciences, University of Pretoria, South Africa.

Corresponding Author:

Prof. Dr. Pablo Agustin Vargas

Piracicaba Dental School – University of Campinas (UNICAMP)

Department of Oral Diagnosis – Pathology

Av. Limeira, 901 ZipCode: 13414-903 Piracicaba – São Paulo – Brazil

Tel.: +55 19 21065319 E-mail: pavargas@fop.unicamp.br

Keywords: HOXB7, HOXB9, salivary gland tumours, adenoid cystic carcinoma, mucoepidermoid carcinoma.

Abstract

Background: Salivary gland carcinomas are uncommon neoplasms and the identification of new prognostic indicators could improve their management. HOXB7 and HOXB9 are members of the class I homeobox-containing genes important for normal embryogenesis and that are dysregulated in several human neoplasms. This study investigated HOXB7 and HOXB9 expression in salivary gland tumourigenesis, their correlation with neoplastic proliferative and angiogenic features, and their importance as prognostic markers.

Methods: A hundred and fifty salivary gland tumours were organized in tissue microarray and expression of CD105, Ki67, HOXB7 and HOXB9 were determined through immunohistochemistry. Reactions were quantified and correlated with clinicopathological parameters.

Results: In normal glands HOXB7 was found in basal cells, whereas HOXB9 was seen in serous acinar and scattered ductal cells. Malignancies exhibited an increased vascular density, proliferative index, HOXB7 and HOXB9 expression when compared with pleomorphic adenoma and Warthin tumour. Significant correlation was found between HOXB7 and CD105 ($p = 0.004$) in adenoid cystic carcinomas, and HOXB7 higher expression significantly correlated with the presence of paresthesia ($p = 0.02$). No marker exhibited a significant association with survival rates ($p > 0.05$).

Conclusion: HOXB7 and HOXB9 were expressed in normal salivary gland and were present in benign and malignant tumours derived from these structures, and HOXB7 significantly correlated with neoangiogenesis in AdCC. These findings suggest that both proteins might play a role in salivary gland tumourigenesis, but they were not significant prognostic determinants in this sample.

Introduction

Salivary gland tumours (SGT) are uncommon lesions that account for 5% of all head and neck neoplasms (1). Due to their biological heterogeneity, SGT clinical behavior is also highly variable and five-year survival rates of patients affected by malignant subtypes can vary from over 90% in cases of low grade adenocarcinomas to as low as 37% in high grade neoplasms (2,3). Hence, the identification of new biomarkers working as prognostic indicators in SGT context would provide a better understanding of the biological basis of these lesions, potentially leading to an improvement in their clinical management and consequent increase of survival rates.

Homeobox-containing (*HOX*) genes are evolutionarily conserved family of genes that play important roles during embryogenesis (4). *HOX* genes are classified in two main groups as class I and class II genes (5). In mammals, class I *HOX* genes contain 39 members with a shared, highly conserved 61-amino acid homeodomain motif that are organized in four paralogous clusters (A, B, C and D) arranged in chromosomes 7, 17, 12 and 2, respectively (4,6,7). Each cluster contains 9 to 11 genes arranged in 13 groups based on homeobox sequence and the position within the cluster. In addition to the well known role played by *HOX* genes in normal development process, an increasing number of studies have recently demonstrated that these genes seem to be dysregulated in a variety of human cancers (4).

HOXB7 is known to control the proliferation and survival of progenitor cells, as well as other biological processes like DNA repair and angiogenesis (8). Its inappropriate expression has been reported in different human malignancies, contributing to neoplastic properties including cell invasion and metastasis (8). Moreover, HOXB7 overexpression was shown to be a determinant of worse prognosis for patients affected by colorectal (9), oral (8,10), pancreatic (11), esophageal (12), breast (13) and lung (14) cancers.

Expression of HOXB9 regulates cell proliferation and embryonic segmentation, also determining normal regulation of renin transcription (15). It induces the expression of several angiogenic factors and promotes cell motility and the acquisition of mesenchymal phenotype. Different authors have shown HOXB9 to be dysregulated in several human neoplasms like gliomas (15), lymphoma (5), breast (6,16), colon (17), hepatocellular (18), lung (19,20), head and neck (21), thyroid (22) and gastric cancers (23), determining a poor prognosis in most of these tumour types.

Despite HOXB7 and HOXB9 have been demonstrated to be prognostic determinants in different human neoplasms, their participation in salivary gland tumourigenesis has not been investigated. Therefore, in the current study we aimed to evaluate the biological and clinical importance of both proteins in benign and malignant SGT, also investigating their association with the neoplastic proliferative and neoangiogenic potentials by correlating their expression with Ki67 and CD105 immunostaining.

Material and methods

Samples

A total of 150 SGT were used in this study. Three oral pathologists reviewed the original haematoxylin-eosin stained slides to confirm the diagnoses of all cases following the World Health Organization's 2005 guidelines (24). Clinical data regarding patient's age, sex, tumour location, presence of pain and paresthesia, tumour stage, treatment employed, tumour recurrence, clinical status and follow-up was retrieved from patient's medical files. The disease-free survival time was calculated by the time difference between the date of treatment and the date of recurrence or last follow-up, whereas disease-specific survival time was determined by the difference between the date of treatment and either the date of death due to the tumour or last follow-up. Survival analyses and correlations between proteins expression

and the presence of pain, paresthesia, stage and recurrences were employed for malignant tumours only.

Tissue microarray construction

Tissue microarray (TMA) construction was carried out as previously described and validated (25,26). Briefly, tumour areas were selected from central and cellular regions of the neoplasms and marked on H&E-stained sections using an objective marker (Nikon Corp, Tokyo, Japan). The slides were overlaid on the original paraffin blocks to determine the corresponding areas to be used. TMAs were constructed using a manual tissue arrayer (Sakura Co., Tokyo, Japan) and 2 representative cylindrical cores of 2.0mm diameter were taken from each tissue block and arranged sequentially into a recipient ready-to-use paraffin block (Sakura Co., Tokyo, Japan). Two cores of normal parotid gland and one of oral squamous cell carcinoma were inserted in the left upper corner of each recipient block for orientation. A map specifying the exact position of each case facilitated the interpretation of the immunohistochemical results.

Immunohistochemistry

Immunohistochemical reactions were done as described before (27). Briefly, 3µm histological sections were de-waxed with xylene and then hydrated in an ethanol series. Endogenous peroxidase activity was blocked using 3% hydrogen peroxide in methanol and antigen retrieval for all antibodies was performed by heating the sections in a microwave in 0.01M citrate buffer (pH 6.0) for 10 min on high power. Normal goat serum was used to block all sections and for dilution of the primary antibodies against human CD105 (dilution 1:30; clone SN6h; Dako, Carpentia, USA), Ki67 (dilution 1:100, clone MIB-1, Dako, Carpentia, USA), HOXB7 (dilution 1:200, clone 4c6; Novus Biologicals, Littleton, USA) and

HOXB9 (dilution 1:200, polyclonal; Sigma-Aldrich, Gillingham, UK). A standard horseradish peroxidase staining procedure was followed using an appropriate biotinylated secondary antibody (Vector Laboratories, Peterborough, UK), and the Elite avidin–biotinylated enzyme complex (ABC) kit (Vector Laboratories). Positive reactions were detected using the chromogen substrates 3,3' diaminobenzidine (DAB) (Vector Laboratories). All sections were counterstained with Harris's haematoxylin (Sigma Aldrich, Gillingham, UK). Sections of oral squamous cell carcinoma were used as positive control for all markers and negative controls were achieved by omission of the primary antibody. Glass slides were then digitized using an Aperio Scancope CS slide scanner (Aperio Technologies, Vista, USA) and, ImageJ (National Institutes of Health, USA) and ImageScope (Aperio Technologies, Vista, USA) softwares were used for quantification. One observer performed the analysis by counting the percentage of positive nuclei in 1000 cells per case for HOXB7, HOXB9 and Ki67 reactions, and the number of vessels (morphologically consistent with a vessel, no matter the presence or not of a central lumen) per unit of area (μm^2) for CD105 reactions. Cases were categorized as demonstrating high and low expression of each marker by using their median values as reference.

Statistical analysis

One-way ANOVA with Tukey's post-hoc test allowed differences in expression of the proteins among histological subtypes to be assessed and Mann-Whitney test was used to compare the immunoexpression of all markers with clinical parameters (pain, paresthesia, tumor stage and recurrence) of malignant tumors. Spearman correlation test was carried out to identify possible correlations among the biomarkers. Log-rank test and Cox regression model were used to evaluate the prognostic significance of clinicopathological features and proteins expression. Cox model construction included all variables that achieved a p value < 0.10 .

Survival curves were acquired using the Kaplan-Meyer method. MedCalc software bvba (Ostend, Belgium) was employed for data analyses and a p value < 0.05 was considered statistically significant.

The current study was carried out in accordance with the ethical guidelines of Piracicaba Dental School ethical committee (process number CEP/FOP 002/2013 – February 06, 2013).

Results

Sample data

This study included 50 pleomorphic adenomas (33%), 24 Warthin tumours (16%), 36 adenoid cystic carcinomas of cribriform subtype (24%) and 40 low-grade mucoepidermoid carcinomas (27%). Detailed clinicopathological data of each tumour subtype is depicted in **Table 1**. Analysis of the total sample demonstrated a slight male predominance (ratio 1.17:1.0 – 67 female and 79 males) with a mean age of 47.5 years (range of 8 to 86 years). Parotid gland was the most affected site (73 cases – 48.7%), followed by minor glands of the oral cavity (47 cases - 31.3%), submandibular gland (22 cases - 14.7%) and sublingual glands (3 cases – 2.0%). Pain and paresthesia were found in 21.1% (16 cases) and 7.9% (6 cases) of malignant cases, respectively, but in no benign lesion. Stage I/II neoplasms accounted for 31.6% (24 cases) of the malignancies, whereas stages III/IV represented 40.8% (31 cases) of them.

Regarding treatment approaches, all patients affected by benign tumours were treated with surgery only, whereas 35.5% of those affected by malignant tumours received adjuvant radiotherapy following surgical management. There was no recurrence in benign tumours group, whereas 22.4% (17 cases) of the malignant neoplasms recurred. Follow-up data was available for 75.0% of the patients affected by malignancies (57 cases), with a mean follow-

Table 1. Clinicopathological data and results of CD105, Ki67, HOXB7 and HOXB9 immunoexpression in the studied sample.

Parameter	PA (n=50)		WT (n=24)		AdCC (n=36)		MEC (n=40)	
	n	(%)	n	(%)	n	(%)	n	(%)
Mean age (yrs)	38.7 (8 – 78)		60.9 (42 – 84)		49.5 (18 – 76)		49.0 (10 – 86)	
Sex								
Male	26	52.0	19	79.0	14	39.0	20	50.0
Female	24	48.0	5	21.0	21	58.0	17	42.5
NS	0	0.0	0	0.0	1	3.0	3	7.5
Site								
Parotid	16	32.0	21	87.5	13	36.0	23	57.5
Submandibular	7	14.0	3	12.5	8	22.2	4	10.0
Sublingual	0	0.0	0	0.0	2	5.5	1	2.5
Minor glands	26	52.0	0	0.0	12	33.3	9	22.5
NS	1	2.0	0	0.0	1	3.0	3	7.5
Pain								
Yes	0	0.0	0	0.0	9	25.0	7	17.5
No	50	100.0	24	100.0	20	55.5	20	50.0
NS	0	0.0	0	0.0	7	19.5	13	32.5
Paresthesia								
Yes	0	0.0	0	0.0	5	13.9	1	2.5
No	50	100.0	24	100.0	23	63.9	26	65.0
NS	0	0.0	0	0.0	8	22.2	13	32.5
Stage								
I/II	NA	NA	NA	NA	15	41.7	9	22.5
III/IV	NA	NA	NA	NA	14	38.9	17	42.5
NS	NA	NA	NA	NA	7	19.4	14	35.0
Treatment								
Surgery	50	100.0	24	100.0	16	44.4	11	27.5
Surg. + Rad.	0	0.0	0	0.0	14	38.9	13	32.5
Other	0	0.0	0	0.0	0	0.0	4	10.0
NS	0	0.0	0	0.0	6	16.7	12	30.0
Recurrence								
Yes	0	0.0	0	0.0	10	27.8	7	17.5
No	50	100.0	24	100.0	20	55.5	20	50.0
NS	0	0.0	0	0.0	6	16.7	13	32.5
Follow-up								
Alive	NA	NA	NA	NA	24	66.7	19	47.5
Dead	NA	NA	NA	NA	5	13.9	9	22.5
NS	NA	NA	NA	NA	7	19.4	12	30.0
CD105 (vessels/area)	0.22 (±0.5)		9.85 (±7.1)		6.40 (±5.9)		8.93 (±14.0)	
Ki67 (%)*	0.86 (±0.7)		1.82 (±1.2)**		6.20 (±9.8)		4.82 (±7.3)	
HOXB7 (%)*	26.95 (±20.7)		4.50 (±4.3)**		29.12 (±26.2)		10.09 (±12.8)	
HOXB9 (%)*	14.33 (±21.2)		0.0 [†]		73.10 (±25.3)		36.25 (±23.7)	

PA: pleomorphic adenoma; WT: Whartin tumor; AdCC: Adenoid cystic carcinoma; MEC: Mucoepidermoid carcinoma; yrs: Years; NS: not specified; Surg.: Surgery; Rad.: Radiotherapy; NA: Not applied; * number of positive nuclei per 1000 cells counted; ** only epithelial cells considered, in the lymphoid component the cells were negative; † only epithelial cells considered, in the lymphoid cells a mean positivity of 81.9% (±14.2) was found.

up time of 107.9 months (range from 1 to 516 months) (AdCC: 83.4 months (1 – 204 months) and MEC: 132.4 months (2 – 516 months)). Considering only malignant tumours, by the time

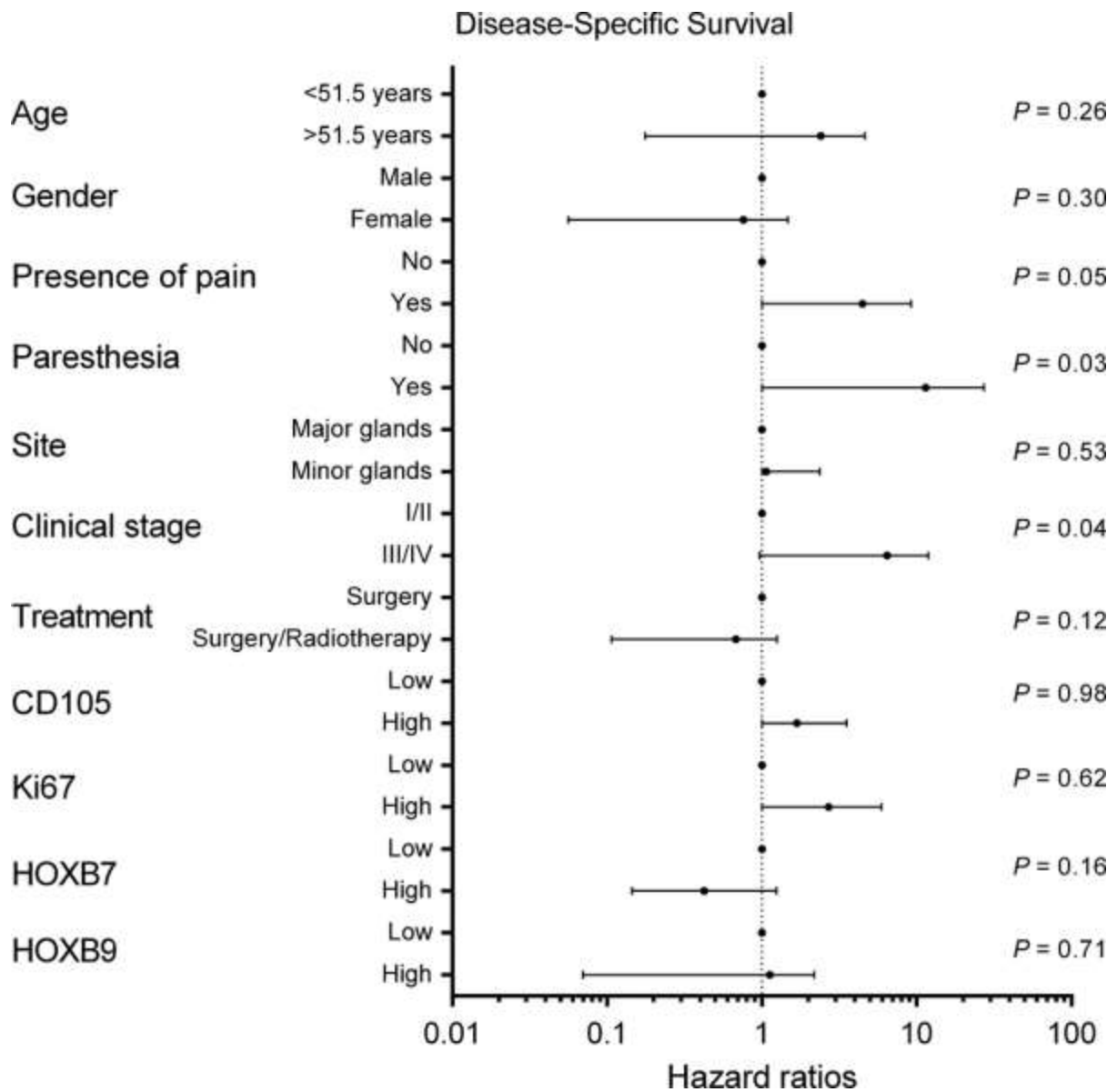


Figure 1. Univariate results (Hazard ratios, 95% confidence interval and *P* values) obtained by comparing clinicopathological parameters and molecular markers with disease-specific survival rate.

of their last appointment, 56.6% of the patients were alive (43 cases), whereas 18.4% had died as a result of their tumour (14 cases). No patient affected by benign tumours had died of their neoplasia. Patients affected by malignant tumours presented 5-year and 10-year disease-specific survivals of 77.9% and 74.0%, respectively, whereas 5-year and 10-year disease-free survival rates were 79.8% and 69.4%, respectively. There was no significant difference in the survival rates of those affected by AdCC and MEC ($p > 0.05$). Results obtained with

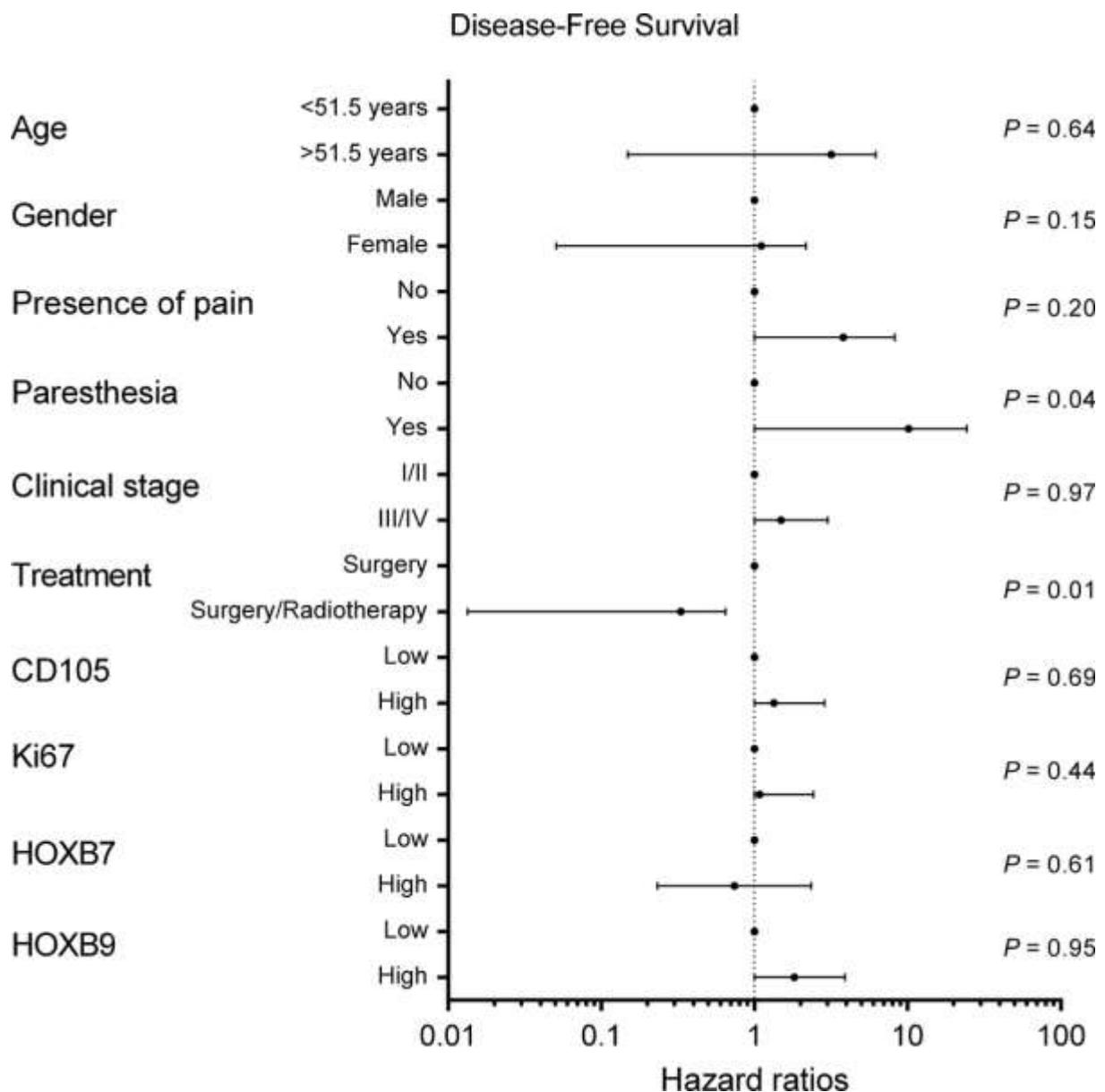


Figure 2. Univariate results (Hazard ratios, 95% confidence interval and *P* values) obtained by comparing clinicopathological parameters and molecular markers with disease-free survival rate. Site was not included due to data limitation.

univariate analysis (Hazard ratios, confidence interval and *p* values) are summarized in **Figure 1** and **Figure 2**. Patients with grade III/IV tumours ($p = 0.04$) and with paresthesia ($p = 0.03$) demonstrated a significant inferior disease-specific survival rate, whereas those with paresthesia ($p = 0.04$) and those submitted only to surgery ($p = 0.01$) demonstrated a significant inferior disease-free survival rate. Under multivariate analyses no

clinicopathological variable significantly correlated with specific survival rate, but both paresthesia (Hazard ratio: 4,48; 95% confidence interval: 1,14 – 17,61 and p -value = 0.03) and treatment (Hazard ratio: 4,51; 95% confidence interval: 1,20 – 16,94 and p -value = 0.02) were demonstrated to be independent determinants for disease-free survival.

CD105, Ki67, HOXB7 and HOXB9 expression

Reactions against CD105 protein evidenced newly formed blood vessels in normal salivary gland tissues and in benign and malignant tumours. Most of the vessels were thin-wall, small diameter structures. Vascular density was significantly higher in malignant neoplasms than in pleomorphic adenoma ($p < 0.05$), but Warthin tumours presented the highest vascular density among histologic subtypes (in their lymphoid component) (**Table 1** and **Figure 3**). There was no significant correlation between CD105 expression and clinicopathological parameters ($p > 0.05$) (**Table 2**); and the vascular density did not correlate with survival rates of patients affected by malignant SGT ($p > 0.05$) (**Figure 1** and **Figure 2**).

Proliferative potential of the tumours measured by Ki67 expression demonstrated a significantly higher index in malignant tumours than in pleomorphic adenoma and Warthin tumour ($p < 0.05$). Adenoid cystic carcinoma revealed the highest proliferative index, followed by mucoepidermoid carcinoma, Warthin tumour and pleomorphic adenoma. Warthin tumour had a low proliferative index in its epithelium lining, but a higher index in its lymphoid component especially in germinal centers (**Table 1** and **Figure 4**). Proliferative index did not correlate with clinicopathological parameters (**Table 2**) and did not influence survival rates in this sample ($p > 0.05$) (**Figure 1** and **Figure 2**).

In normal salivary glands, HOXB7 strong nuclear and mild cytoplasmic stain was present in basal cells of normal ducts and in scattered acinar cells. AdCC demonstrated the highest expression, followed by pleomorphic adenoma and MEC. HOXB7 expression was

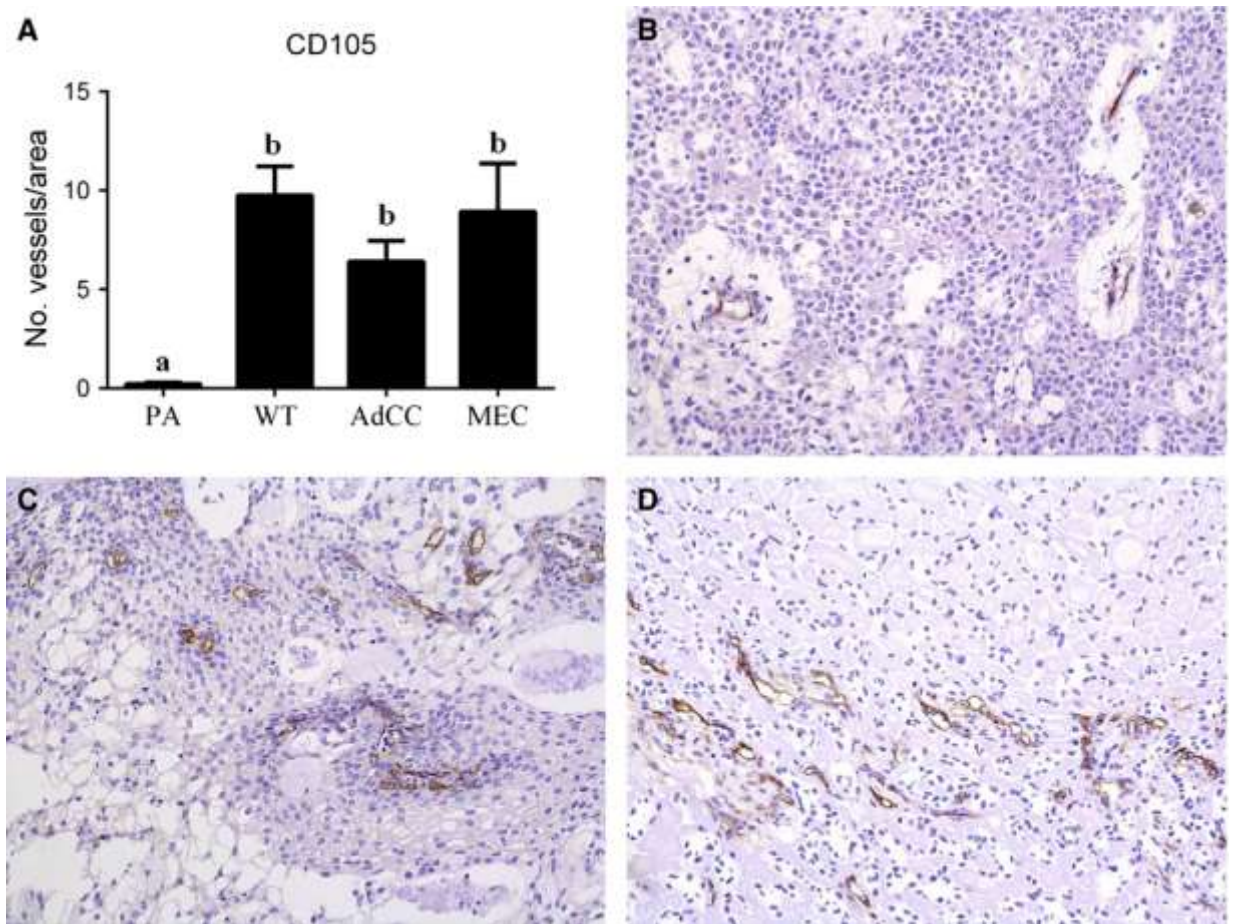


Figure 3. CD105 expression in salivary gland tumours. (A) The number of newly formed blood vessels was significantly higher in malignant tumours than in pleomorphic adenoma, but Warthin's tumour demonstrated the highest density. Statistically significant difference is present when letters are different (Mean value \pm SD). (B) Immunorexpression of CD105 in pleomorphic adenoma (3,3' diaminobenzidine - DAB; 200X), (C) mucoepidermoid carcinoma (3,3' diaminobenzidine - DAB; 200X) and (D) adenoid cystic carcinoma (3,3' diaminobenzidine - DAB; 200X). PA: Pleomorphic adenoma; WT: Warthin's tumour; AdCC: Adenoid cystic carcinoma; MEC: Mucoepidermoid carcinoma.

present in neoplastic cells with both luminal and myoepithelial morphology. Warthin tumour showed scarce positive cells only in the epithelial lining, whereas lymphoid cells revealed no reactivity. Epithelial cells of Warthin tumor also showed a strong cytoplasmic staining, but because of its granular feature (full of mitochondria) and the unknown function and disposal of HOX proteins in the cellular cytoplasm this staining was not considered specific (**Table 1** and **Figure 5**). Higher expression of HOXB7 significantly correlated with the presence of

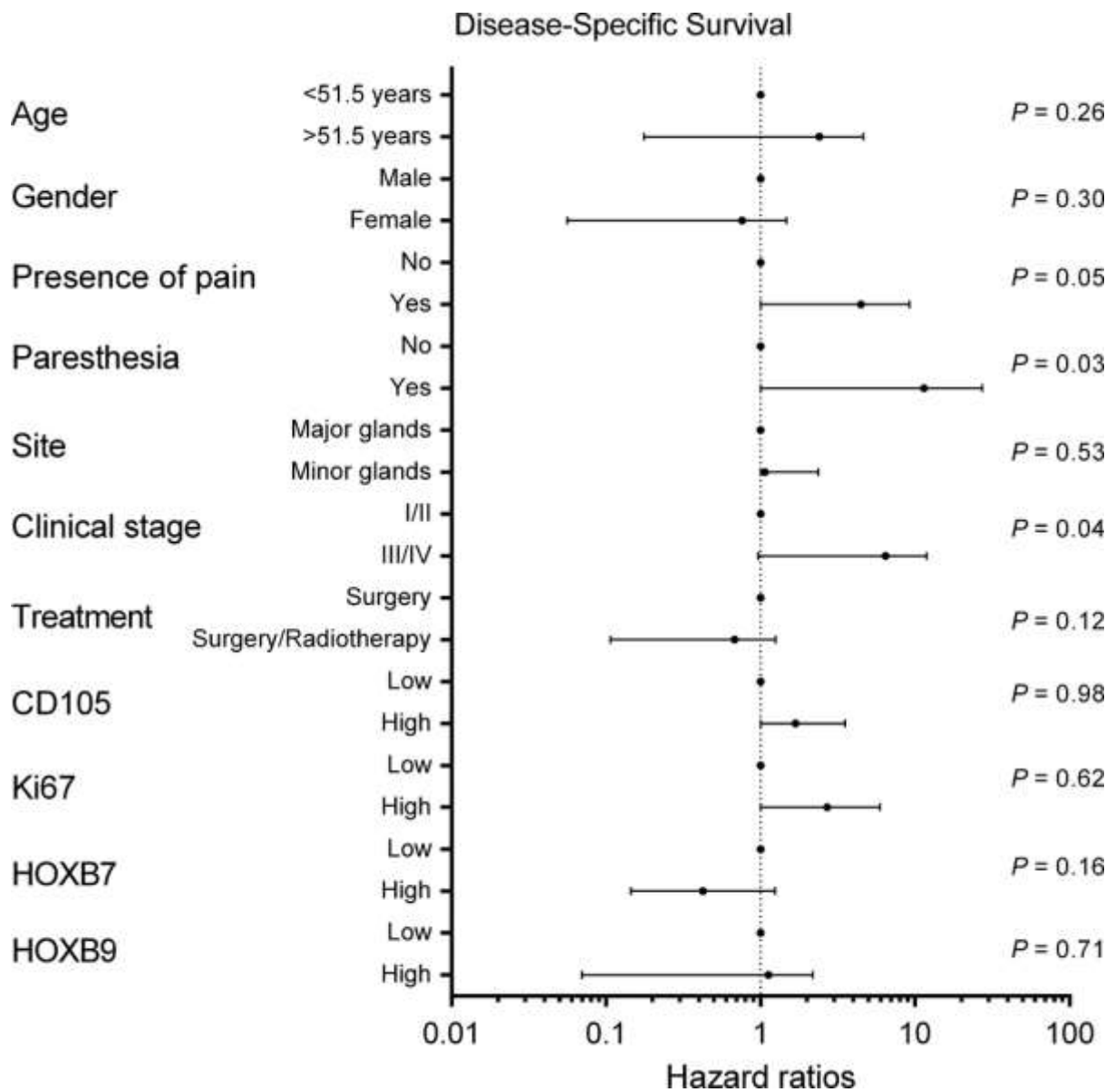


Figure 4. Ki67 expression in salivary gland tumours. (A) Proliferative index was significantly higher in malignant tumours than in benign lesions. Statistically significant difference is present when letters are different. Ki67 was quantified in the epithelial lining of Warthin's tumour (Mean value \pm SD). (B) Immunorexpression of Ki67 in pleomorphic adenoma (3,3' diaminobenzidine - DAB; 400X), (C) mucoepidermoid carcinoma (3,3' diaminobenzidine - DAB; 400X) and (D) adenoid cystic carcinoma (3,3' diaminobenzidine - DAB; 400X). PA: Pleomorphic adenoma; WT: Warthin's tumour; AdCC: Adenoid cystic carcinoma; MEC: Mucoepidermoid carcinoma.

paresthesia (**Table 2**), but it did not correlate with survival rates ($p > 0.05$) (**Figure 1** and **Figure 2**).

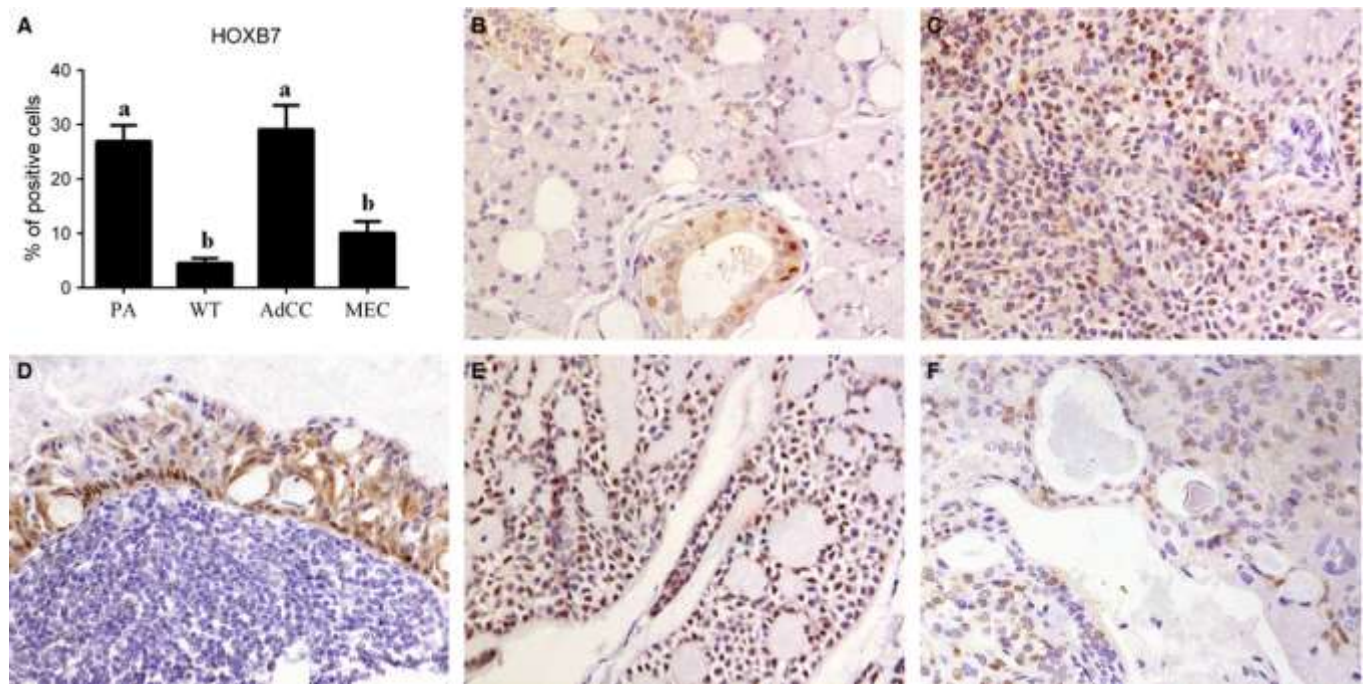


Figure 5. HOXB7 expression in salivary gland tumours. (A) HOXB7 expression was similar between pleomorphic adenoma and AdCC, but much lower in the epithelial lining of Warthin's tumour (negative in its lymphoid component) and in MEC. Statistically significant difference is present when letters are different (Mean value \pm SD). (B) Immunoexpression of HOXB7 in normal salivary gland (3,3' diaminobenzidine - DAB; 400X), (C) pleomorphic adenoma (3,3' diaminobenzidine - DAB; 400X), (D) in the nuclei of the epithelial lining of Warthin's tumour (the cytoplasmic staining in the epithelium was considered unspecific and the lymphoid component was negative) (3,3' diaminobenzidine - DAB; 400X), (E) adenoid cystic carcinoma (3,3' diaminobenzidine - DAB; 400X) and (F) Mucoepidermoid carcinoma (3,3' diaminobenzidine - DAB; 400X). PA: Pleomorphic adenoma; WT: Warthin's tumour; AdCC: Adenoid cystic carcinoma; MEC: Mucoepidermoid carcinoma.

Table 2. Correlation of CD105, Ki67, HOXB9 and HOXB7 expression with clinicopathological parameters (pain, paresthesia, tumor stage and recurrence) in malignant salivary gland tumors.

	CD105		Ki67		HOXB7		HOXB9	
	Mean (SD)	<i>p</i> value	Mean (SD)	<i>p</i> value	Mean (SD)	<i>p</i> value	Mean (SD)	<i>p</i> value
Pain								
Yes	7.20 (\pm 6.80)	0.95	4.13 (\pm 5.54)	0.76	20.7 (\pm 15.2)	0.10	56.5 (\pm 32.3)	0.46
No	9.23 (\pm 13.4)		6.08 (\pm 10.5)		17.3 (\pm 25.1)		60.8 (\pm 33.2)	
Paresthesia								
Yes	6.97 (\pm 5.48)	0.80	10.69 (\pm 22.06)	0.38	28.1 (\pm 12.5)	0.02*	51.4 (\pm 24.2)	0.34
No	9.18 (\pm 12.8)		5.05 (\pm 6.87)		16.4 (\pm 23.4)		60.0 (\pm 34.3)	
Stage								
I/II	9.84 (\pm 15.6)	0.63	3.13 (2.84)	0.81	19.1 (\pm 19.9)	0.31	62.1 (\pm 29.7)	1.00
III/IV	8.65 (\pm 8.39)		7.68 (12.7)		18.0 (\pm 24.8)		59.0 (\pm 34.7)	
Recurrence								
Yes	5.98 (\pm 5.85)	0.46	9.29 (\pm 15.39)	0.49	18.2 (\pm 23.6)	0.90	63.5 (\pm 34.0)	0.50
No	10.12 (\pm 13.5)		4.54 (\pm 6.82)		18.2 (\pm 22.3)		56.0 (\pm 32.2)	

Mann-Whitney test. * *p* value was considered significant when *p* < 0.05. SD: Standard deviation.

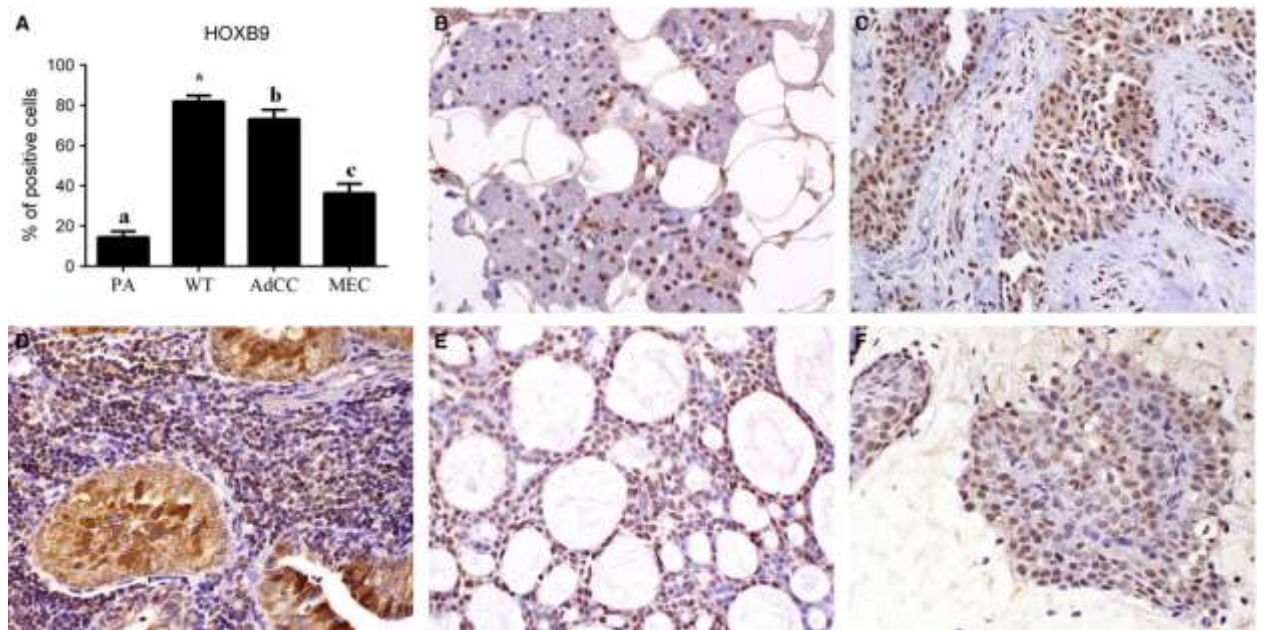


Figure 6. HOXB9 expression in salivary gland tumours. (A) HOXB9 expression was significantly higher in malignant neoplasms than in pleomorphic adenoma. *HOXB9 was negative in Warthin's tumour epithelial lining, but strongly positive in its lymphoid component. Statistically significant difference is present when letters are different (Mean value \pm SD). (B) Immunoeexpression of HOXB9 in normal salivary gland (3,3' diaminobenzidine – DAB; 400X), (C) pleomorphic adenoma (3,3' diaminobenzidine – DAB; 400X), (D) in the lymphoid component of Warthin's tumour (the cytoplasmic staining found in the epithelial lining was considered unspecific) (3,3' diaminobenzidine – DAB; 400X), (E) adenoid cystic carcinoma (3,3' diaminobenzidine – DAB; 400X) and (F) Mucoepidermoid carcinoma (3,3' diaminobenzidine – DAB; 400X). PA: pleomorphic adenoma; WT: Warthin's tumour; AdCC: Adenoid cystic carcinoma; MEC: Mucoepidermoid carcinoma.

A predominantly nuclear, but also mild cytoplasmic HOXB9 expression was evident in acinar and occasional ductal cells of normal salivary glands. The protein presented the same staining pattern in all tumour subtypes analyzed, but in Warthin tumour HOXB9 nuclear expression was observed to be restricted to the lymphoid component of the lesion with no expression in its epithelial lining (cytoplasmic staining was not considered positive because of the granular aspect of the cells and the unknown disposal and function of HOX proteins in the cytoplasm). It was not possible to identify HOXB9 to be restricted to either luminal or myoepithelial cells of tumors. A strong difference was found by comparing pleomorphic adenoma and malignant neoplasms ($p < 0.05$), as well as between AdCC and MEC ($p < 0.05$) (Table 1 and Figure 6). HOXB9 expression did not correlate with clinical parameters (Table 2) and with survival rates (Figure 1 and Figure 2).

Spearman correlation test only demonstrated a significant association between CD105 and HOXB7 ($p = 0.004$ / $\rho = 0.50$) in AdCC (**Figure 7**), whereas no other correlation achieved statistical significance ($p > 0.05$).

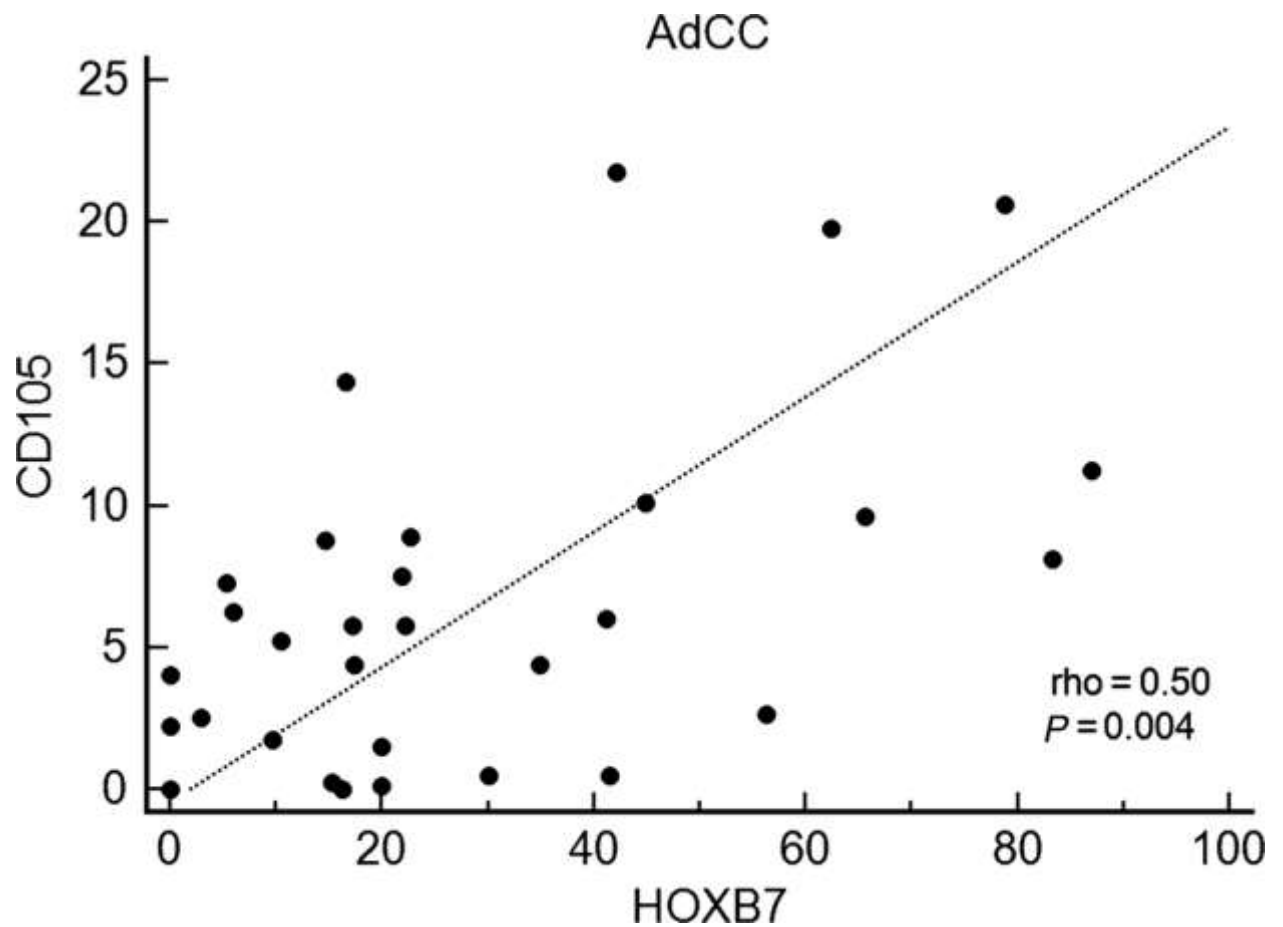


Figure 7. Spearman's correlation test demonstrated a significant correlation between HOXB7 and CD105 in adenoid cystic carcinoma.

Discussion

HOX genes are known to be involved in cell proliferation and differentiation, with critical roles during embryonic segmentation and limb patterning. HOXB7 and HOXB9 are two members of the Class I *HOX* family with important roles during physiological organogenesis (7). Because their dysregulation has been implicated in human cancer development, the current study investigated the role of these proteins in the salivary gland tumourigenesis context and their possible utility as prognostic determinants. However, despite

both markers were overexpressed in AdCC and MEC when compared to pleomorphic adenoma and the epithelial component of Warthin tumour, the proteins failed to demonstrate a significant prognostic potential.

Different groups have investigated the importance of HOXB7 and HOXB9 in human oncogenesis. HOXB7 was shown to present a high expression in malignant neoplasms of lung, breast, oral cavity, esophagus and pancreas, also increasing the metastatic and proliferative potential of many cancer types, being implicated in neoplastic processes like angiogenesis, epithelial-mesenchymal transition and tumour invasion (8,11,12,14). Similarly, the over-expression of HOXB9 determined a worse survival for patients affected by gliomas, breast, lung and colonic cancers (15-17,20), enhancing competence of lung adenocarcinoma to promote brain and bone metastases (19), leading to a higher number of lymph node and distant dissemination of colon cancer (17) and increasing radiation resistance of breast cancer cell lines (28). On the other hand, Chen et al., (2008) (13) showed that HOXB7 dysregulation could not promote breast carcinogenesis by itself, whereas Sha et al. (2013) (23) demonstrated that HOXB9 level decreased from well-differentiated to poorly differentiated gastric cancer and that its downregulation was a significant and independent indicator of a poor prognosis for patients with gastric carcinoma. Moreover, Kim et al. (2012) (22) showed that a reduced nuclear expression of HOXB9 was more common in papillary thyroid carcinoma cases with more advanced pathologic stage, whilst Zhan et al (2014) (29) demonstrated that elevated HOXB9 expression was identified in well-differentiated colon adenocarcinoma patients and was associated with a better overall survival, also inhibiting colon adenocarcinoma cell growth, migration and invasion *in vitro*.

These controversial results suggest that HOXB7 and HOXB9 may play divergent roles during cancer progression, and despite we know that these proteins work through many cellular pathways, with different functions under different cellular environments, it is still

difficult to explain such discrepancies in their expression significance (13,22). In contrast to the previously described clinical relevance of HOXB7 and HOXB9 in other human cancers (8,12,23), in the current study the expression of both proteins failed to reach a statistically significant correlation with survival rates and the only significant clinical association was obtained with HOXB7 higher expression and presence of paresthesia in patients affected by malignant tumours.

HOX genes encode transcription factors that contain a characteristic homeodomain through which they recognize the promoters of target genes and regulate their expression (7). Consistent with this transactivation function, in the current study HOXB7 and HOXB9 proteins were predominantly localized in the nuclei of both normal and neoplastic cells; however, a cytoplasm immunoreactivity was also frequently noted in different proportions, (especially in the epithelial lining of Warthin tumors) what has also been described previously in thyroid, breast, hepatocellular and gastric cancers for HOXB9 (16,18,22,23) and illustrated in colorectal, pancreatic and esophageal malignant neoplasms for HOXB7 (9,11,12). Because of the granular features of the epithelial cells of Warthin tumor that is more susceptible to present unspecific immunostaining and also because literature is currently unable to explain the biological significance of this possible cytoplasmic reactivity of HOX proteins and to more appropriately compare our results with those previously described, we opted to consider only the nuclear localization as positivity for both proteins.

It is known that multiple HOXB7 and HOXB9 binding sites are present in the promoters of genes associated to normal and pathologic angiogenic and proliferative processes including angiopoietin-like 2, IL-8, TGF- β 2, VEGF, bFGF, PI3K/AKT and Ras-MAPK (7,12,16,30). Therefore, the increased HOXB7 and HOXB9 expression has been demonstrated to be associated with an increased vascular density and cellular proliferation in different human neoplasias (7,12). Such observation is only partially in accordance to the

observed in the current study that evidenced a positive correlation between HOXB7 expression and the neoangiogenic marker CD105 in AdCC, but we did not obtain a significant association between HOX proteins and the proliferative marker Ki67, in contrast to previous results (15,18). Interestingly, HOXB9 demonstrated a strong positivity in the normal lymphoid component of Warthin tumour, but not in the nuclei of the epithelial lining (the component statistically analyzed), which is in accordance to its lymphogenic and hematogenic properties. In contrast, HOXB7 exhibited a weak staining in the epithelial cells and no reaction in the lymphoid area of the tumour.

CD105 represents a suitable angiogenic marker, because it is preferentially associated with recently formed blood vessels (31-34). In the current study we observed that the great majority of stained vessels were small and thin-walled structures and the expression of this protein was increased in malignancies than in pleomorphic adenoma. These results are similar to the reported previously by Tadbir et al. (2015) (35), but in contrast to our findings these authors demonstrated a higher expression of CD105 in MEC than in AdCC, what may have been influenced by tumour microscopic subtypes since in this study only low-grade MEC and cribriform AdCC were used. However, in contrast to the results of Cardoso et al. (2009) (36) that correlated CD105 expression with an increased risk of metastasis in AdCC, we could not correlate CD105 expression with clinicopathological parameters. Similarly, this study also failed to identify any significant correlation between Ki67 expression and clinicopathological parameters and survival rates, what is in contrast to previous reports (37,38).

Some limitations of the current investigation include the relatively small sample size analyzed, possibly precluding the acquisition of further statistically significant results, and despite a multicenter collaborative study allows the inclusion of a higher number of cases for investigation, it also provides patients who have been subjected to different therapeutic protocols, which could influence the survival rates of the studied sample.

In conclusion, HOXB7 and HOXB9 are expressed in normal salivary gland tissue and are strongly present in benign and malignant tumours derived from these structures, and HOXB7 significantly correlates with the neoangiogenic potential of AdCC. These findings suggest that these proteins might play a role in salivary gland tumourigenesis, but in contrast to the reported for other human cancers, they were not significant prognostic determinants in the sample studied.

Conflict of interest statement

We declare that we have no conflict of interest.

Acknowledgment

The authors state that they have no potential conflict of interest that could bias the results obtained in this study and that the current research was supported by grants from the São Paulo State Research Foundation (Brazil), processes numbers 2009/53839-2, 2012/07519-9 and 2012/10781-7, and from the Brazilian Coordination of Higher Education (CAPES/PDSE 2892/13-8).

References

1. Fonseca FP, Carvalho MV, Almeida OP, et al. Clinicopathologic analysis of 493 cases of salivary gland tumours in a Southern Brazilian population. *Oral Surg Oral Med Oral Pathol Oral Radiol* 2012; 114: 230-9.
2. Bell RB, Dierks EJ, Homer L, Potter BE. Management and outcome of patients with malignant salivary gland tumours. *J Oral Maxillofac Surg* 2005; 63: 917-28.
3. Lima RA, Tavares MR, Dias FL, et al. Clinical prognostic factors in malignant parotid gland tumours. *Otolaryngol Head Neck Surg* 2005; 133: 702-8.

4. Hoshino Y, Hayashida T, Hirata A, et al. Bevacizumab terminates homeobox B9-induced tumour proliferation by silencing microenvironmental communication. *Mol Cancer* 2014; 13: 102-16.
5. Nagel S, Burek C, Venturini L, et al. Comprehensive analysis of homeobox genes in Hodgkin lymphoma cell lines identifies dysregulated expression of HOXB9 mediated via ERK5 signaling and BMI1. *Blood* 2007; 109: 3015-23.
6. Hayashida T, Takahashi F, Chiba N, et al. HOXB9, a gene overexpressed in breast cancer, promotes tumorigenicity and lung metastasis. *Proc Natl Acad Sci U S A* 2010; 107: 1100-5.
7. Shrestha B, Ansari KI, Bhan A, Kasiri S, Hussain I, Mandal SS. Homeodomain-containing protein HOXB9 regulates expression of growth and angiogenic factors, facilitates tumour growth in vitro and is overexpressed in breast cancer tissue. *FEBS J* 2012; 279: 3715-26.
8. Bitu CC, Carrera M, Lopes MA, Kowalski LP, Soares FA, Coletta RD. HOXB7 expression is a prognostic factor for oral squamous cell carcinoma. *Histopathology* 2012; 60: 653-74.
9. Liao WT, Jiang D, Yuan J et al. HOXB7 as a prognostic factor and mediator of colorectal cancer progression. *Clin Cancer Res* 2011; 17: 3569-78.
10. Destro MFS, Bitu CC, Zecchin KG et al. Overexpression of HOXB7 homeobox gene in oral cancer induces cellular proliferation and is associated with poor prognosis. *Int J Oncol* 2010; 36: 141-9.
11. Kovochich AN, Arensman M, Lay AR, Rao NP, Donahue T, Li X. HOXB7 promotes invasion and predicts survival in pancreatic adenocarcinoma. *Cancer* 2013; 119: 529-39.

12. Li H, Shen LY, Yan WP, et al. Deregulated HOXB7 expression predicts poor prognosis of patients with esophageal squamous cell carcinoma and regulates cancer cell proliferation in vitro and in vivo. *PLoS ONE* 2015; 10: e0130551.
13. Chen H, Lee JS, Liang X, et al. Hoxb7 inhibits transgenic HER-2/neu-induced mouse mammary tumour onset but promotes progression and lung metastasis. *Cancer Res* 2008; 68: 3637-44.
14. Yuan W, Zhang X, Xu Y, Li S, Hu Y, Wu S. Role of HOXB7 in regulation of progression and metastasis of human lung adenocarcinoma. *Mol Carcinog* 2014; 53: 49-57.
15. Fang L, Xu Y, Zou L. Overexpressed homeobox B9 regulates oncogenic activities by transforming growth factor-b1 in gliomas. *Biochem Biophys Res Commun* 2014; 446: 272-9.
16. Seki H, Hayashida T, Jinno H, et al. HOXB9 expression promoting tumour cell proliferation and angiogenesis is associated with clinical outcomes in breast cancer patients. *Ann Surg Oncol* 2012; 19: 1831-40.
17. Huang K, Yuan R, Wang K, et al. Overexpression of HOXB9 promotes metastasis and indicates poor prognosis in colon cancer. *Chin J Cancer Res* 2014; 26: 72-80.
18. Li F, Dong L, Xing R, et al. Homeobox B9 is overexpressed in hepatocellular carcinomas and promotes tumour cell proliferation both in vitro and in vivo. *Biochem Biophys Res Commun* 2014; 444: 241-7.
19. Nguyen DX, Chiang AC, Zhang XHF, et al. WNT/TCF signaling through LEF1 and HOXB9 mediates lung adenocarcinoma metastasis. *Cell* 2009; 138: 51–62.
20. Zhan J, Wang P, Niu M, et al. High expression of transcriptional factor hoxb9 predicts poor prognosis in patients with lung adenocarcinoma. *Histopathology* 2015; 66: 955-65.

21. Darda L, Hakami F, Morgan R, Murdoch C, Lambert DW, Hunter KD. The role of HOXB9 and miR-196a in head and neck squamous cell carcinoma. *PLoS ONE* 2015; 10: e0122285.
22. Kim JH, Kim YH, Han JH, et al. Silencing of homeobox B9 is associated with down-regulation of CD56 and extrathyroidal extension of tumour in papillary thyroid carcinoma. *Human Pathol* 2012; 43: 1221-8.
23. Sha S, Gu Y, Xu B, et al. Decreased expression of HOXB9 is related to poor overall survival in patients with gastric carcinoma. *Dig Liver Dis* 2013; 45: 422-9.
24. Barnes L, Eveson JW, Reichart PA, Sidranskiy D. Tumors of Salivary Gland. In: *World Health Organization Classification of Tumours. Pathology and Genetics of Head and Neck Tumours*. IARC Press, Lyon, 2005; 209-281.
25. Paiva-Fonseca F, de-Almeida OP, Ayroza-Rangel ALC, Agustin-Vargas P. Tissue microarray construction for salivary gland tumours study. *Med Oral Patol Oral Cir Bucal* 2013; 18: e1-e6.
26. Fonseca FP, Andrade BAB, Rangel ALCA, et al. Tissue microarray is a reliable method for immunohistochemical analysis of pleomorphic adenoma. *Oral Surg Oral Med Oral Pathol Oral Radiol* 2014; 117: 81-8.
27. Gonzalez-Arriagada WA, Santos-Silva AR, Ito FA, et al. Expression pattern of PLUNC proteins as an auxiliary tool for the diagnosis of high-grade mucoepidermoid carcinoma of the salivary gland. *J Oral Pathol Med* 2012; 41: 589-97.
28. Chiba N, Comaills V, Shiotani B, et al. Homeobox B9 induces epithelial-to-mesenchymal transition-associated radioresistance by accelerating DNA damage responses. *Proc Natl Acad Sci U S A* 2012; 109: 2760-5.

29. Zhan J, Niu M, Wang P, et al. Elevated HOXB9 expression promotes differentiation and predicts a favourable outcome in colon adenocarcinoma patients. *Br J Cancer* 2014; 111: 883-93.
30. Wu X, Chen H, Parker B, et al. HOXB7, a homeodomain protein, is overexpressed in breast cancer and confers epithelial-mesenchymal transition. *Cancer Res* 2006; 66: 9527-34.
31. Fonsatti E, Sigalotti L, Arslan P, Altomonte M, Maio M. Emerging role of endoglin (CD105) as a marker of angiogenesis with clinical potential in human malignancies. *Curr Cancer Drug Targets* 2003; 3: 427-32.
32. Dhanuthai K, Sappayatosok K, Yodsanga S, Rojanawatsirivej S, Pausch NC, Pitak-Arnnop P. An analysis of microvessel density in salivary gland tumours: A single centre study. *Surgeon* 2013; 11: 147-52.
33. Theocharis S, Gribilas G, Giaginis C, Patsouris E, Klijanienko J. Angiogenesis in salivary gland tumours: from clinical significance to treatment. *Expert Opin Ther Targets* 2015; 19: 807-19.
34. Soares AB, Juliano PB, Araújo VC, Metze K, Altemani A. Angiogenic switch during tumour progression of carcinoma ex-pleomorphic adenoma. *Virchows Arch* 2007; 451: 65-71.
35. Tadbir AA, Pardis S, Ashkavandi ZJ, et al. Expression of Ki67 and CD105 as proliferation and angiogenesis markers in salivary gland tumours. *Asian Pacific J Cancer Prev* 2015; 13: 5155-9.
36. Cardoso SV, Souza KCN, Faria PR, Eisenberg LA, Dias FL, Loyola AM. Assessment of angiogenesis by CD105 antigen in epithelial salivary gland neoplasms with diverse metastatic behavior. *BMC Cancer* 2009; 9: 391-8.

37. Vargas PA, Cheng Y, Barrett AW, Craig GT, Speight PM. Expression of Mcm-2, Ki-67 and geminin in benign and malignant salivary gland tumours. *J Oral Pathol Med* 2008; 37: 309–18.
38. Yamazaki M, Fujii S, Murata Y, Hayashi R, Ochiai A. High expression level of geminin predicts a poor clinical outcome in salivary gland carcinomas. *Histopathology* 2010; 56: 883-92.