

The importance of record keeping in Forensic Odontology: A case discussion and general medico-legal guidelines for all practitioners.

SADJ June 2016, Vol 71 no 5 p224 - p227

L M Sykes¹, A Uys², H Bernitz³

BACKGROUND

Forensic Odontologists may be called upon to help identify deceased individuals in situations such as: criminal cases, where victim identification is needed before official investigations can take place; marriages, where confirmation of the death of a spouse is required before the partner can remarry; for monetary purposes, such as paying out of pensions and life insurance policies; for completion of death certificates prior to burial; for social reasons such as closure for family members; for unclaimed bodies; for unidentified bodies in mass disasters; and in cases of fires, drowning, violent crimes, and motor vehicle accidents where the bodies may be so badly disfigured, decomposed or physically altered, that identification by family members would be psychologically traumatic.¹⁻³

Although many regions of the body have been used for identification purposes, the teeth remain one of the most ideal sources as they have a number of distinctive features and are able to withstand many chemical and physical insults that would destroy other body tissues.¹ Radiographs taken at the time of autopsy should replicate the type and angles of the any existing records as closely as possible.² It is routine that a thorough, systematic, clinical and radiological examination is carried out on each tooth as well as the surrounding oral tissues. The list of features examined is extensive, especially in cases with little or no restorative work, as these are much more difficult to positively identify.⁴

Following the examination, the ante-mortem records are compared with the post-mortem findings taking note of all similarities and discrepancies. Enough clear similarities, and

no inconsistencies, will help determine a positive diagnosis. Radiographic features are the most reliable measures, but those used must be unique to the individual as well as stable over time. Skeletal radiographic identification requires a recommended minimum of eight concordant features.³ In contrast, there is no specified number of concordant features needed for a positive identification when using dental images. Even one single tooth with unique concordant features and no discrepancies may be considered adequate for a conclusive decision.¹ A single discrepancy would, however, cast doubt on the verdict and needs to be explained, failing which an exclusion decision would have to be made. Examples of explicable discrepancies would be replaced or enlarged restorations, or extracted teeth. An inexplicable discrepancy would be a tooth present at the post-mortem examination that was not evident in the ante-mortem records.² Following the comparison, a conclusion needs to be drawn. The American Board of Forensic Odontology has suggested narrowing the options down to one of the following four possibilities: Positive identification, (sufficient matching features and no discrepancies); Possible identification, (consistent features but the quality of records or remains prevents a definitive conclusion being drawn); Insufficient evidence, (not enough evidence to substantiate a definitive conclusion), and Exclusion, (lack of similarity or unexplainable discrepancies between ante-mortem and post-mortem data).⁵

This paper presents a case of a young accident victim whose body was too badly mutilated for identification by the family, and the case was thus referred to the forensic odontologists to try to confirm his identity. A seemingly obvious positive identification was hampered by the presence of a single confounding feature, and the crucial lack of accurate dental records to substantiate or refute any conclusion.

CASE REPORT

A 23-year old jogger was fatally injured after being knocked down and subsequently run over by a truck. The only possessions he carried were his gym clothing. The body was too badly disfigured to allow family members to view, but a positive identification was needed before it could be released for burial. Tissue samples were taken and sent for DNA analysis; however, this is a costly and tedious

1. **Leanne M Sykes:** BSc, BDS, MDent (Pros), Department of Prosthodontics, University of Pretoria.
2. **Andre Uys:** BSc, BChD, Dip Odont (Materials), Dip Odont (Endo), MSc (Odont), Department of Radiology, University of Pretoria.
3. **Herman Bernitz:** BChD, Dip Odont, MSc (Odont), PhD, Manager of Forensic Dental Research, Department of Oral Pathology and Oral Biology, University of Pretoria.

Corresponding author

Leanne M Sykes:

Department of Prosthodontics, University of Pretoria.
E-mail: Leanne.sykes@up.ac.za

process and could take up to six weeks for results. The family were anxious to have their son positively identified to allow them bury his remains as soon as possible. They sought the help of the forensic odontologists to try to speed up the process.

The father provided a recent photograph of the victim. From this a mild class III malocclusion was evident,

but given the state of the body, it was impossible to make any correlations with the photograph. The family dentist was able to provide a panoramic radiograph dating back to when the boy was 17 years old (Figure 1). Forensic dental identification involves comparing features on old records with those taken at the time of the autopsy – including photographs, manual visualization and charting of all teeth and surrounding structures, and full mouth peri-apical radiographs. The forensic team were hampered by the victim having a perfectly healthy dentition, with no dental restorations to aid their processes. The panoramic radiograph did however reveal some characteristic features. All four of his third molars were still in the bud stage of tooth development, as would be expected at his age of 17, and showed a tendency towards becoming horizontally impacted. The 37 and 47 were slightly supra-erupted compared with the 36 and 46, a feature that was confirmed clinically. All four of these teeth also had characteristically pointed pulp horns, which was also evident on the post mortem radiographs. A further interesting and distinctive feature was the width of the 32 and 42 compared with the mandibular centrals. The former were seen to be much larger clinically, and on both the ante-mortem panoramic radiograph and post-mortem peri-apical radiographs.

These characteristic features alone may have led to a positive identification; however, the case was complicated by one discordant observation. All four third molars had been removed. The peri-apical radiographs revealed a remaining fractured root of the 38 lying horizontally about 5mm deep in the mandibular bone (Figure 2). However, the dentist had not provided any records stating these teeth had been removed, and without further evidence, a positive identification could not be made at this stage.

The dentist was contacted and he confirmed that he had referred the patient for surgical removal of the teeth when he was 18 years old. He also gave the name of the maxillo-facial surgeon, who, unfortunately, was not reachable at that time. Sadly, this meant that a positive identification of the

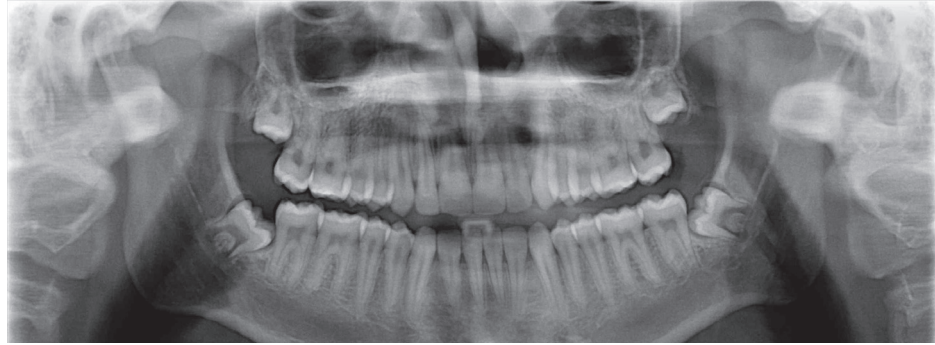


Figure 1: Panoramic radiograph taken when the boy was 17 years old.

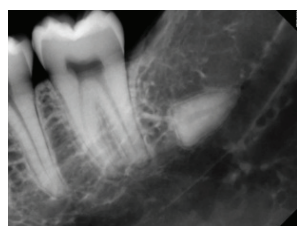

Figure 2: Peri-apical radiograph of fractured root (38) taken at the time of the post mortem (age 23 years).

individual could not be made because of this otherwise unexplainable discrepancy. This led to a lot of anguish for the boy's family, as the body could not be released for burial. Identification was finally confirmed through DNA analysis, a process requiring a further six weeks.

DISCUSSION

With no further dental records to go by there were a number of unanswered questions and many issues to consider, which would each impact differently on the identification process. Based on the radiographs provided by the family dentist, and the evidence at hand, there were five possible scenarios to consider. The discussion below explores these and highlights two relevant questions that arose as a result of this investigation.

1.1. No extraction of the third molars and a positive identification

Had the boy's wisdom teeth not been extracted, they would still be evident on the postmortem forensics radiographs and may even have been visible in the mouth (which would have been explainable given that he was then at that time 23 years old). There would have been no conflicting evidence and a positive identification could have been made based on three distinctive concordant features, namely: the pointed shape of the pulp horns (36, 37, 46, 47), the supra-erupted molars (37, 47), and the relatively larger mandibular lateral incisors. The family would have been informed and the body released for burial.

1.2. Uncomplicated extraction of the third molars, supported with well documented records of the procedure, and positive identification

If the third molars had been extracted uneventfully, and the procedure was correctly documented with supporting pre- extraction radiographs, there would have been no conflicting evidence between the ante-mortem records and post-mortem findings. A positive identification would have been made based on the above-mentioned features as well as the missing third molars. (Note, this is presuming the 38 root had not been fractured, which was not the case.) This highlights the importance of conducting a thorough post-mortem investigation, with full mouth radiographs in every case, despite any seemingly obvious concordant features noted on the clinical examination. In this case, the retained root would never have been discovered without these radiographs.

1.3. Complicated extraction of the third molars, supported by well documented records of the procedure, and a positive identification

If the third molars had been extracted and the surgeon was aware of fracturing the 38 root, this should have been documented in the patient's records, along with supporting pre- and post-extraction radiographs. The incident should also have been mentioned to the patient and his parents, alerting them to the possibility that it

could cause problems in the future. Once again, there would have been no conflicting evidence, and a positive identification could have been made based on the above-mentioned features, the missing third molars, and the retained root fragment.

1.4. Uncomplicated extraction of the third molars, supported by well-documented records of the procedure, and a negative identification

If the teeth had been extracted uneventfully, and the procedure was correctly documented with supporting pre- and post-extraction radiographs showing NO retained root, there would have been an unexplainable discrepancy between ante-mortem and post-mortem records, and a negative identification would have been made. This would mean instituting a new search for the victim's identity, and informing the awaiting family that the body being examined was not their son. They too would then have had to begin a new search for the missing lad.

1.5. Complicated extraction of the third molars, with no supporting records of this, and a delayed positive or negative identification

If the teeth had been extracted and the root had fractured, but there were no records of this event, (as indeed was the situation), a definitive positive identification could not be made due to this one discordant anomaly. The family would then have to wait at least six weeks for the results of the DNA analysis to confirm or refute their son's identity. If positive, they could indict the dentist and / surgeon for many issues. Firstly, for poor record keeping; Secondly, for failing to inform them of the fractured root and warn them of possible future complications; Thirdly, for putting the family through the anguish of waiting six weeks before knowing whether this was their son; Fourthly, for delaying the funeral, and their having to endure the knowledge that their son's body was lying in the mortuary all of this time, and finally, for delaying a new search for their son, which could already have begun six weeks ago.

Two further pertinent considerations arose during this investigation.

2.1 Justification for extraction of unerupted, asymptomatic third molars

Based on the panoramic radiograph, all of the teeth, with the exception of the third molars, were fully formed and erupted. The third molar is the most developmentally variable tooth, but is still a relatively reliable biological indicator of age in adolescents and young adults.⁶ In this case, the boy's age was known to be 17 years at that time of the radiograph. However, Demirjian's classification rated the third molars between stages E and F,⁷ and Moorrees's system as between 8 and 9 (C1 and R1/4). In males this usually corresponds to average ages of between 13.6 and 14.6 years,⁸ indicating that in this case development of the third molars was delayed by at least three years. As such, it was unlikely that they could have fully matured into stage Ac a year later, when they had been extracted. This led to the question of why these teeth had been surgically removed before they were fully developed, as there were no radiographs or notes in the file to justify this decision.

Millions of asymptomatic teeth classified as "impactions", are "prophylactically" removed from healthy young people

with no medical evidence to justify this procedure.⁹ Only 12% of truly impacted teeth have associated pathology such as cysts or damage to adjacent teeth.¹⁰ Considering all the potential complications that could arise from third molar extraction, (pain, swelling, trismus, haemorrhage, alveolar osteitis, periodontal damage, soft-tissue infection, injury to the temporomandibular joint, malaise, temporary or permanent paraesthesia of the lips, tongue, and cheek, fracture of adjacent teeth or surrounding bone, sinus exposure or infection, and anaesthetic complications), makes it difficult to justify the procedure.¹¹ However, if there is insufficient anatomical space to accommodate normal eruption, removal of such teeth at an early age may be considered a valid and scientifically sound treatment.¹² (It was later discovered that in the case under consideration, the third molars had in fact been extracted at the request of his orthodontist to facilitate future management).

2.2. Fractured root-germ development

Another issue relates to the stages of root development. In the panoramic radiograph, the roots of all the third molars were relatively immature (Demirjian stages E-F). The referring surgeon could not remember breaking off any root and had no records of this in the patient's file. Given that the body was eventually identified as being the boy in question, it is clear that the root definitely originated from some residual fragment left by the surgeon. If this fractured segment had been acknowledged and documented with post-extraction radiographs at the time of extraction, it would have been possible to compare its size and shape with the image seen on the current radiograph, where the root appears to be fully formed. Based on the original panoramic radiograph and average developmental charts, it is highly unlikely that it could have matured that much in one year. This leads one to speculate on whether a retained root has any potential for further growth. Chrcanovic found that tooth buds in early stages of calcification as well as teeth widely displaced due to mandibular fractures, continued to develop and erupt.¹³ However, in a similar study by Swei *et al.*, it was noted that in at least 45% of these teeth, there were developmental abnormalities.¹⁴ In both of these studies, the coronal sections of the affected teeth were still present, albeit slightly displaced. No studies were found on development of fractured root portions left behind when immature teeth were extracted. That possibility has led to a research question that is presently being investigated.

CONCLUSION

The case highlights the complexities of victim identification and emphasises the need for caution against making a hasty positive decision based on a few concordant features, without conducting a thorough clinical and radiographic examination. Considering that most positive identification decisions depend on matching ante-mortem records with post-mortem findings, it should also serve as a strong reminder to clinicians on the importance of good record keeping and retention, as prescribed by the HPCSA and the laws of the country. Clinicians are advised to familiarise themselves with the guidelines on record keeping as set out in the HPCSA Regulations, Booklet 14 of 2008). This covers the important issues of what constitutes a health record, the required time for retention of health records, the records that are compulsory to keep and describes the characteristics of good records.¹⁵

References

1. Kahana, T, Hiss, J. Identification of human remains: forensic radiology. *J Clin Forensic Med* 1997; 4:7-15.
2. Pretty, I.A., Sweet, D., A look at forensic entistry - Part 1: The role of the teeth in the determination of human identity. *Br Dent J* 2001; 190:359-66.
3. Holobinko, A. Forensic human identification in the United States and Canada: A review of the law, admissible techniques, and the legal implications of their application in forensic cases. *Forensic Sci Int* 2012; 222:394.e1-394.e13.
4. Sweet, D. Forensic dental identification. *Forensic Sci Int* 2010; 201:3-4.
5. ABOF. Body Identification guidelines. *J Am Dent Assoc* 1994; 125:1244-54.
6. Lewis, JM, Senn, DR. Dental age estimation utilizing third molar development: A review of principles, methods, and population studies used in the United States. *Forensic Sci Int* 2010; 10(201):79-83.
7. Demirjian, A GH, Tanner, JM. A new system of dental age assessment. *Hum Biol* 1973; 45:211-27.
8. Moorrees, CFA, Fanning, EA, Hunt, EE. Age variation of formation stages for ten permanent teeth. *J Dent Res* 1963; 42:1490-502.
9. Friedman, JW. The prophylactic extraction of third molars: A public health hazard. *Am J Public Health* 2007; 97(9):1554-9.
10. Stanley, HR, Alattar, M, Collett, WK, Stringfellow, HR, Spiegel, EH. Pathological sequelae of "neglected" impacted third molars. *J Oral Path* 1988; 17:113-7.
11. Osborn, TP, Frederickson, G, Small, IA, Torgerson, TS. A prospective study of complications related to mandibular third molar surgery. *J Oral Maxillofac Surg* 1985; 45:767-9.
12. AAOMS. The Management of Impacted Third Molar Teeth, Editor. 2007: Rosemont, Ill.
13. Chrcanovic, BR. Teeth in the line of mandibular fractures. *Oral Maxillofac Surg* 2014; 18(1):7-24.
14. Suei, Y, Malick, PC, Nagasaki, T, Taguchi, A, Fujita, M, Tanimoto, K. Radiographic evaluation of the fate of developing tooth buds on the fracture line of mandibular fractures. *J Oral Maxillofac Surg* 2006; 64(1):94-9.
15. HPCSA. Guidelines for Good Practice in the Health Care Professions. Guidelines on the keeping of patient records. Booklet 14, HPCSA, Editor. 2008, Accessed on 06-11-2015 at: http://www.hpcs.co.za/downloads/conduct_ethics/rules/generic_ethical_rules/booklet_14_keeping_of_patience_records.pdf.: South Africa.