

## LYMPH NODE PATHOLOGY IN *TRYPANOSOMA BRUCEI*-INFECTED SHEEP

P. R. BARROWMAN and J. A. ROOS, Veterinary Research Institute, Onderstepoort, 0110

### ABSTRACT

BARROWMAN, P. R. & ROOS, J. A., 1979. Lymph node pathology in *Trypanosoma brucei*-infected sheep. *Onderstepoort Journal of Veterinary Research*, 46, 9-17 (1979).

The temporal sequence of morphological changes occurring in the prefemoral lymph nodes of sheep experimentally infected with *Trypanosoma brucei* was studied at weekly intervals during the course of infection.

Histopathological changes started with lymphoid stimulation which was soon overtaken and masked by intense proliferation of reticulo-endothelial cells. Reticulo-endothelial proliferation resulted in macrophage accumulation, some vascular damage and lymph stasis, varying from insidious to extensive. Reticulo-endothelial activity subsequently decreased and there was an upsurge of proliferative activity in lymphoid tissue. Lymphoid stimulation resulted in increased numbers of primary follicles with active germinal centres and produced cells primarily lymphoblast/plasmablast in type. The response appeared to involve blast cells of the germinal centres rather than thymus-dependent paracortical areas. Both reticulo-endothelial and lymphoid components exhibited marked cellular necrosis which increased throughout the course of infection. Intense lymphopoiesis was not correlated with lymphocytosis but was associated with lymphopaenia.

### Résumé

#### *PATHOLOGIE DES GANGLIONS LYMPHATIQUES CHEZ LE MOUTON INFECTÉ PAR TRYPANOSOMA BRUCEI*

On a étudié de semaine en semaine la séquence temporelle des modifications morphologiques qui se produisent dans les ganglions lymphatiques préfémoraux de moutons infectés expérimentalement par *Trypanosoma brucei*.

Les modifications histopathologiques ont débuté par une stimulation lymphoïde qui a été rapidement dépassée et masquée par une prolifération marquée des cellules réticulo-endothéliales. Cette prolifération a eu pour résultat une accumulation de macrophages, quelques dégâts vasculaires et une stase lymphatique, variant d'insidieuse à étendue. Subséquemment, l'activité réticulo-endothéliale a diminué et il y a eu une poussée de la prolifération des tissus lymphoïdes. La stimulation lymphoïde a eu pour résultat des quantités accrues de follicules primaires aux centres germinaux actifs et la production de cellules de type primairement lymphoblaste/plasmoblaste. La réaction semble avoir intéressé les lymphoblastes des centres germinaux plutôt que les zones paracorticales qui dépendent du thymus. Tant les cellules réticulo-endothéliales que les cellules lymphoïdes ont manifesté une nécrose marquée qui a augmenté pendant toute la durée de l'infection. Une lymphopoïèse intense n'était pas en corrélation avec une lymphocytose mais était liée à une lymphopénie.

### INTRODUCTION

Pathological changes of lymph nodes are a constant finding in sub-acute and chronic trypanosomiasis in man (Ormerod, 1970) and animals (Losos & Ikede, 1972). They are most pronounced with infections of the *Trypanozoon* subgenus (Peruzzi, 1928; Ormerod, 1970; Ikede & Losos, 1972) but also occur with *Trypanosoma (Nannomonas) congolense* (Fiennes, 1970), *T. (N.) simiae* (Stephen, 1966) and *T. (Duttonella) vivax* (Fiennes, 1953). With the last-named 3 "haematic" species, changes are general, but haemolymph nodes are more consistently affected.

Most reports are based on the changes found terminally at necropsy of trypanosome-infected animals. The temporal events occurring in the lymph nodes of *T. brucei*-infected rodents have been described by Hu (1931, cited by Losos & Ikede, 1972), by Murray, Murray, Jennings, Fisher & Urquhart (1974c) and in *T. brucei*-infected rabbits by Van den Ingh (1976).

It is apparent that the presence of pathogenic Salivarian trypanosome infections has a profound effect on the immune system in many mammalian hosts. In addition to the pathomorphological changes involving lymphoid tissue, there are raised levels of IgM present at certain stages of infection (Mattern, 1962), immunosuppression of both humoral and cell-mediated systems *in vivo* (Goodwin, Green, Guy & Voller, 1972; Mansfield & Wallace, 1974) and the susceptibility of trypanosome-infected hosts to a variety of secondary infections.

In this paper an attempt is made to describe the temporal sequence of morphological changes occurring in the lymph nodes of sheep experimentally infected with *T. brucei*.

### MATERIALS AND METHODS

#### *Trypanosome strain*

The strain of *T. brucei* (OP. 1) used for infecting sheep originated from an ox in Rhodesia and was maintained by syringe passage in rats and guinea pigs for 25 generations before being stored as a stabilate at  $-196^{\circ}\text{C}$ . Each experimental animal was infected by intravenous injection with 1 ml of rat blood of high parasitaemia containing  $2 \times 10^6$  viable trypanosomes (counted in a Neubauer chamber) immediately after thawing.

#### *Experimental animals*

Five adult female Dorper sheep, 2 years old and of uniform size, were infected simultaneously with *T. brucei*.

#### *Lymph nodes*

Sheep were selected at random at weekly intervals from the 1st to the 8th week of infection for removal of prefemoral lymph nodes. The nodes were removed aseptically under chloral hydrate anaesthesia, using the surgical approach described by Hall (1967), measured and weighed, then immediately fixed in 10% formalin. After fixation, blocks of tissue were embedded in paraffin wax and 5-6  $\mu\text{m}$  sections were cut with a sliding microtome, stained with haematoxylin and eosin and mounted for examination by light microscopy.

#### *Haematology*

Blood samples in heparin were collected from 3 sheep every 2-3 days during infection for total white blood cell counts, using a Neubauer chamber. Differential leucocyte counts were performed on Giemsa-stained thin blood smears.



To investigate possible changes from small to large lymphocytes, or vice versa, in the blood lymphocyte population, the diameters of 50 lymphocytes were measured with an ocular micrometer in Giemsa-stained thin blood smears prepared daily from 3 sheep during the course of infection, and the mean and standard deviation calculated.

RESULTS

A quantitative assessment of the gross enlargement occurring in prefemoral lymph nodes during the progression of infection is presented in Table 1.

TABLE 1 Quantitative changes in prefemoral lymph nodes during the course of *T. brucei* infection

| Stage of infection (weeks) | Sheep No. | Mass of node (gm) | Dimensions of node (mm) |
|----------------------------|-----------|-------------------|-------------------------|
| 0.....                     | 3091      | 0,75              | 31×7×4                  |
| 1.....                     | 3086      | 0,7               | 42×7×5                  |
| 2.....                     | 2723      | 0,5               | 30×5×3                  |
| 3.....                     | 2234      | 2,36              | 35×8×9                  |
| 4.....                     | 3086      | 3,7               | 47×13×11                |
| 5.....                     | 2723      | 3,5               | 54×14×12                |
| 6.....                     | 2234      | 10,18             | 55×23×14                |
| 7.....                     | 2497      | 6                 | 30×23×16                |
| 8.....                     | 1467      | 6,3               | 58×15×10                |

The mass of the node began to increase during the 3rd week of infection, at the end of which it had increased fourfold. The enlargement continued progressively until the 6th week by which time a fourteenfold increase in mass had occurred. Subsequent measurements showed a slight reduction in this size but there was a persistent enlargement of 8-9 times the comparable mass of the node in non-infected sheep.

The sequence of histopathological changes occurring in these nodes was as follows:

Week 1

Normal lymph node morphology was found. A normal number of large primary lymphoid follicles with small, well-defined germinal centres were present in the cortex. The cortical and subcapsular sinuses were narrow and compact, the medulla small, while the lymph sinuses, narrow and well-defined, contained small numbers of evenly scattered cells.

Very few germinal centres showed evidence of increased mitotic activity. All primary follicles were well populated with undifferentiated lymphoblasts and small lymphocytes, and most had small germinal centres. The few primary follicles showing increased activity had large germinal centres containing many stem cells (Fig. 1) In these centres, up to 5% of the cells exhibited karyorrhexis or pyknosis (Fig. 1), and a smaller number were in active mitosis. The paracortical area of these follicles was composed of large and small lymphocytes and very few mature plasma cells.

The cortical sinuses contained predominantly primitive reticulo-endothelial (r-e) cells and evenly scattered small lymphocytes.

The medullary cords revealed the presence of many small lymphocytes but few plasma cells. The medullary sinuses contained a loose meshwork of reticular cells and r-e cells with a scattering of small and large lymphocytes. The medullary trabeculae were narrow, with normal, well-defined morphology.

Neutrophils were not present in the medullary or cortical sinuses.

Week 2

No gross enlargement of the node was observed.

The germinal centres showed an increase in size in some areas and contained a very slightly increased number of mitotic cells, but only a few degenerative or necrotic cells. The germinal centres were generally more basophilic and the outer follicles less distinct, indicating activity in the follicles.

The cortical sinuses contained small numbers of necrotic cells and there was an overall increase in the number of neutrophils both in the cortical matrix and in the lumina of arterioles running through it.

The medullary cords remained loosely packed with small and large lymphocytes but showed an increase in the number of plasma cells. The medullary sinuses were densely packed with macrophages and small numbers of pyknotic cells, and polymorphs were also present in increased numbers.

Week 3

There was a general increase in the size of the cortex and medulla throughout the node.

The thickness of the cortex was increased by many new, small, germinal centres and by follicles containing cells of equal staining intensity which were an indication of markedly increased activity. The cortical sinuses were distended and pale, with irregular intensity of cellular distribution, and there was evidence of lymph stasis and small patches of localized oedema extending into adjacent tissue. In many areas, r-e cells proliferated and distorted the normal configuration of the primary follicles.

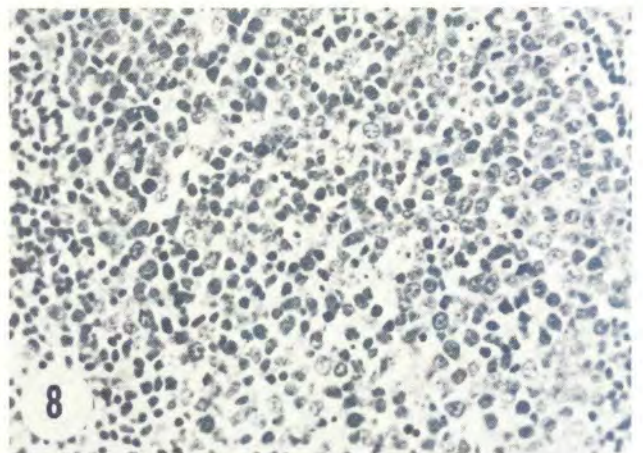
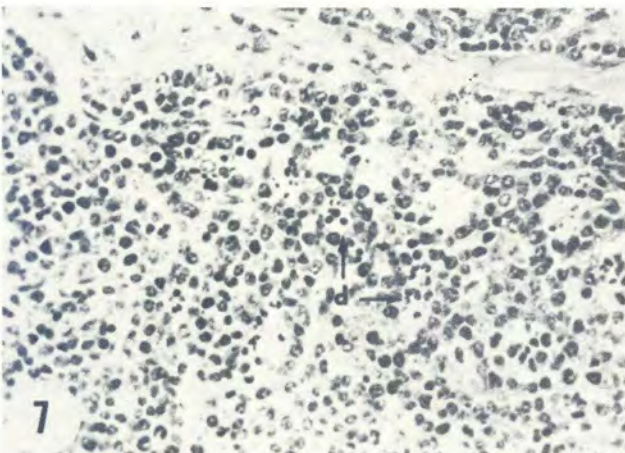
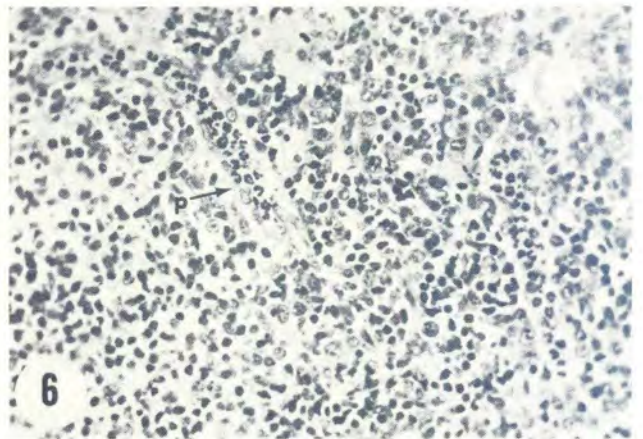
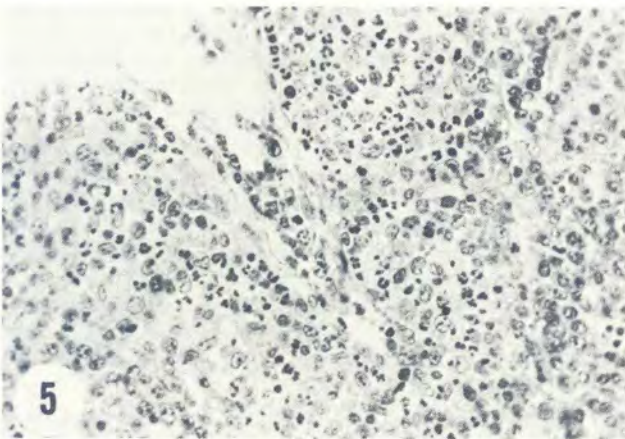
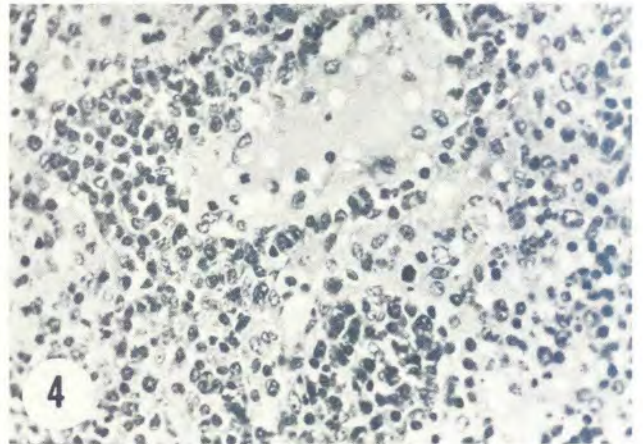
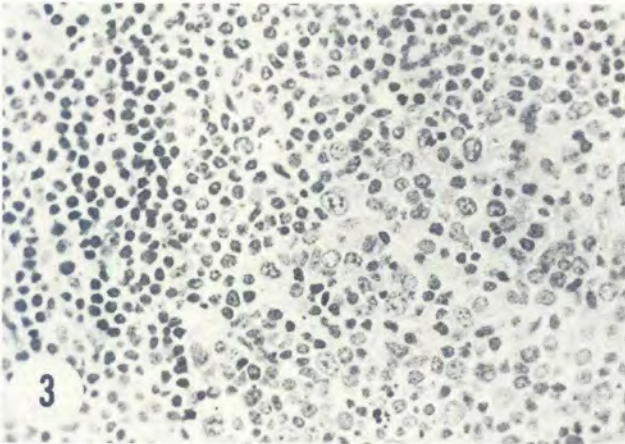
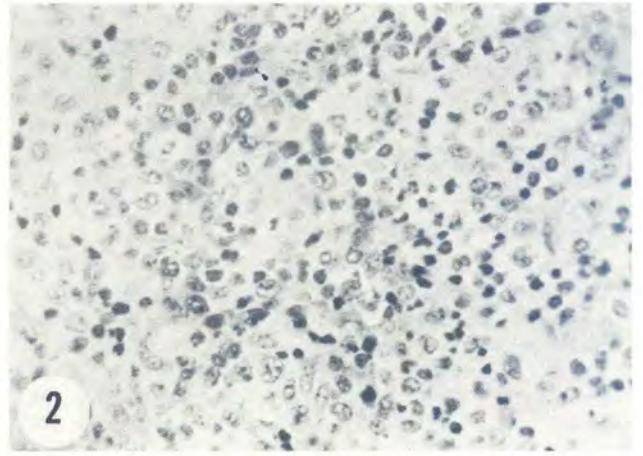
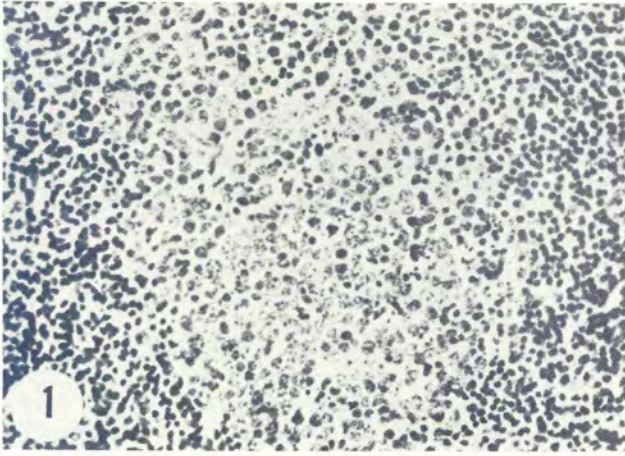
The medullary cords, in which small lymphocytes predominated, were enlarged and tortuous and extended throughout the medulla to the hilus. They were extensively disrupted by r-e proliferation from the medullary sinuses. Only a few mature plasma cells were identifiable.

The medullary sinuses were loosely packed, greatly dilated and extensively tortuous, with many cells showing increased cytoplasm. The medullary trabeculae were fragmentary and often swollen with lymph.

Very small numbers of trypanosomes were identifiable in the capsular fibrous tissue and peripheral areas of the cortex.

- FIG. 1 Week 1. Small germinal centre showing mitosis and cellular necrosis. ×300
- FIG. 2 Week 3. Oedema, r-e activation and extensive cellular necrosis in cortical sinus. ×300
- FIG. 3 Week 3. Part of germinal centre showing karyorrhexis, cell necrosis and macrophages migrating in. ×300
- FIG. 4 Week 4. Medullary sinus. R-e proliferation and oedema. ×300
- FIG. 5 Week 4. Cortical sinus. Vascular damage with associated extensive neutrophil infiltration. ×300
- FIG. 6 Week 4. Subcapsular cortical sinus. Packing of neutrophils (p) in vessels. ×300
- FIG. 7 Week 5. Cortical sinus. Nests and tracts of necrotic cells (d). ×300
- FIG. 8 Week 5. Germinal centre showing cellular necrosis. ×300







The primary follicles occurred as many small centres, their morphology often being disrupted by the impinging reaction of r-e cells in the cortical sinuses (Fig. 3). Although the numbers of centres present in the cortex indicated an apparent increase in follicular activity, there were very few mitotic figures in the germinal centres. Far more pronounced was an increase in the number of necrotic cells in the germinal centres. The paracortical areas in most cases were neither densely packed nor did they reveal any indication of cell proliferation.

The most pronounced change at this time occurred in the cortical and medullary sinuses where extensive r-e proliferation and macrophage activation were found, together with evidence of cellular degeneration (Fig. 2). The erythrocytic extravasation present in many parts of the node was associated with the presence of numbers of neutrophils extending far into the cortex.

#### Week 4

There was a considerable increase in the overall size of the node.

The morphology of the node was very abnormal, the overall picture being a massive r-e proliferation in the sinus tissues at the expense of the primary follicles.

The primary follicles, although fairly numerous, were small and scattered unevenly in a matrix of cortical proliferation. The number of mitotic figures, however, indicated that these centres were active, but cell necrosis continued and was more pronounced both in the germinal centres and the narrow paracortical areas than in the preceding weeks. The paracortical areas were confluent with the adjacent cortical r-e proliferation, rarely forming well-defined margins.

The cells of the cortical and subcapsular sinuses, and particularly those near to blood vessels were hyperactive. Some of the vessels showed endothelial damage with extravasation of erythrocytes and fluid. Of singular note was the large accumulation of neutrophils in the lumina of small blood vessels (Fig. 6) and their leakage into the cortex at sites of vascular damage (Fig. 5). The r-e cells of the cortical sinus were hyperplastic and increased numbers of mitotic figures were in evidence. The cell types present were predominantly primitive reticular cells and macrophages, while cell necrosis was widespread. Small lymphocytes and an increased number of plasma cells were scattered in the sinus. Trypanosomes were not encountered in the cortical substance.

Medullary sinuses were likewise hyperplastic (Fig. 4). There were small patches of lymph stasis and an overall infiltrative oedema of the medulla (Fig. 4).

The trabeculae were poorly defined and showed lymph infiltrations and macrophage replacement. Although it was not easy to distinguish, there appeared to be adventitial vascular proliferation of the large arterioles of the medulla.

#### Week 5

The overall enlargement of the node persisted.

Although this particular node was less oedematous and was more normal morphologically than that of Week 4, the changes occurring within it were qualitatively similar.

The cortical r-e proliferation again impinged very markedly on follicular tissue and the follicles themselves were fairly numerous and small. The germinal

centres contained necrotic cells (Fig. 8), but few mitotic figures were found.

Many necrotic cells were present in the cortical sinuses, often in foci of up to 10 cells (Fig. 7), and large macrophages were also found adjacent to these foci. The distribution of degenerative cells was fairly general and they often appeared in tracts. Fewer lymphocytes and plasma cells were present in the sinuses, though these were densely packed with r-e cells. The small blood vessels again contained many neutrophils.

The medullary sinuses in this node were not as active as those of Week 4, and the enlargement of the medulla, which was considerable, resulted from the combined increase in size of both medullary cords and sinuses whilst retaining relatively normal morphology (Fig. 9). Much less breakdown of trabecular fibrous tissue was observed. Dilatation of the sinuses close to the hilus was found to be due to lymph stasis.

The medullary cords contained lymphoblasts, small lymphocytes and a definite increase in the number of plasma cells. Cells in mitosis were found in moderate numbers and there was a large number of pyknotic and karyorrhectic cells.

Peri-nodal adipose tissue was found to contain tracts of mononuclear cell infiltration (Fig. 10).

#### Week 6

The lymph node was greatly enlarged.

The cortex contained many well-formed primary follicles, particularly in the thinner parts of the gland, but they were again well dispersed by the cortical sinus r-e reaction.

Germinal centres showed considerably increased activity with 2 or more mitotic divisions taking place in each centre, but they continued to show a simultaneous necrosis of numbers of cells. The paracortical areas showed an increase in density and were better defined than was the case in Weeks 4 and 5. The predominant cell was lymphoblast in type.

The cortical r-e cells showed continued general activity and there were frequent small patches of lymph stasis (Fig. 11). Diffuse lymph stasis, however, was present in much of the cortical sinus. The cellular reaction was again fundamentally r-e proliferation but there were very large numbers of necrotic cells as well (Fig. 11). Accumulations of neutrophils were still to be found in the lumina of smaller blood vessels but appeared less frequent, and a few of these cells had migrated into the matrix.

The medullary cords contained lymphoblasts, large lymphocytes and some small lymphocytes, with relatively fewer mature plasma cells and far fewer necrotic cells. There was less r-e cellular activity in the medullary sinuses and in many areas the medullary cords were more prominent. Throughout the medullary sinuses there was a diffuse lymph stasis which extended into the trabeculae, the latter being fragmentary and often swollen.

#### Week 7

The node continued to increase in size and there was some evidence of a return to more normal morphology. Many large, well-defined, primary follicles were present, often containing mitotic or binucleated cells in the germinal centres. The centres still contained necrotic cells, while the paracortical areas contained lymphoblasts, some in mitosis, and small lymphocytes.



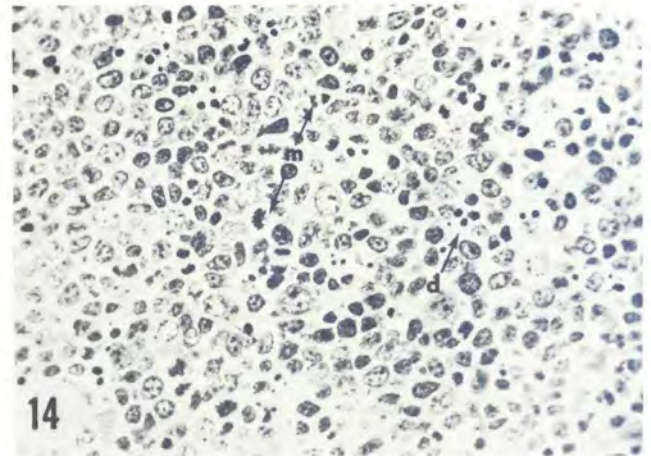
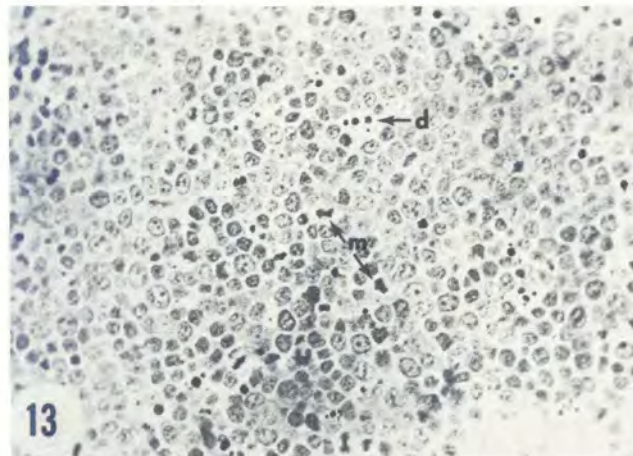
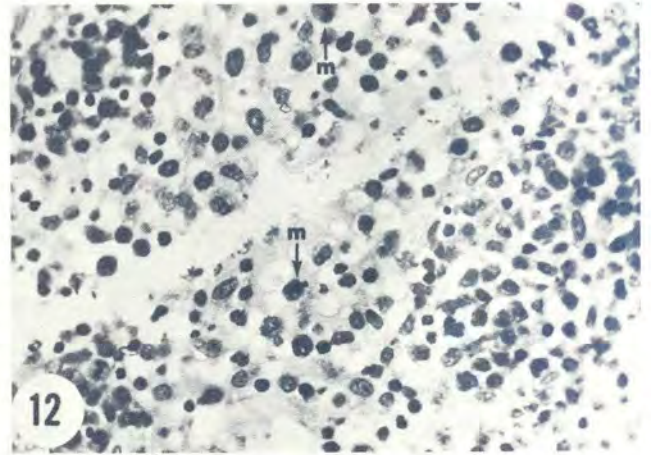
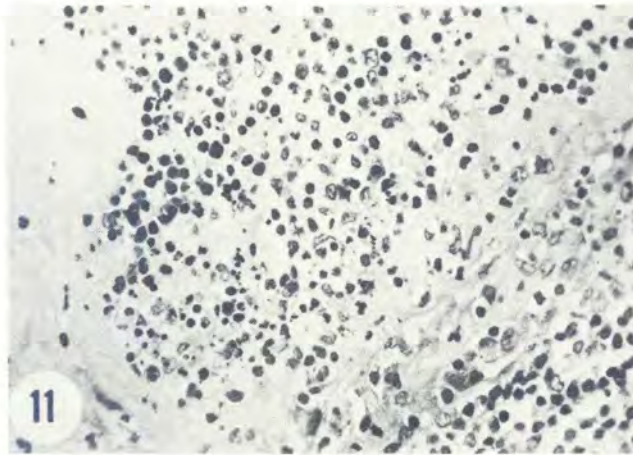
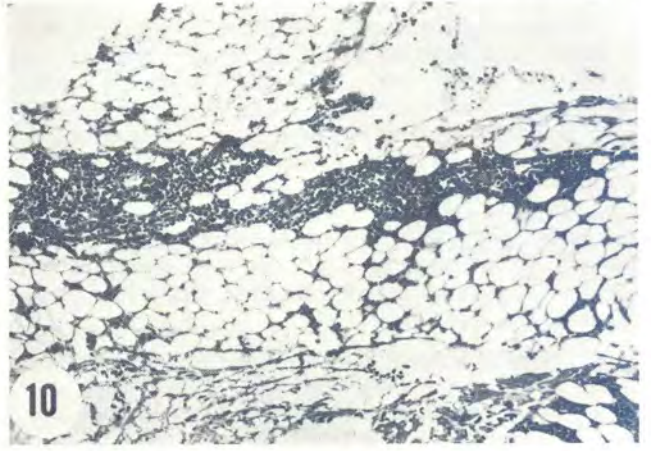
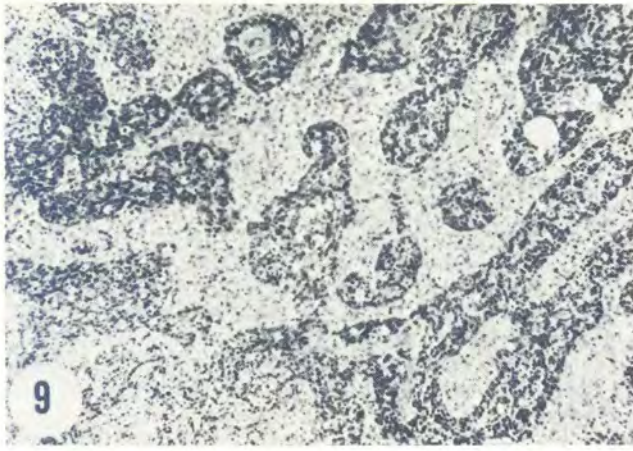


FIG. 9 Week 5. Morphology of medulla, increased sinus r-e activity and well developed cords.  $\times 63$   
 FIG. 10 Week 5. Peri-nodal adipose tissue, mononuclear cell infiltration.  $\times 200$   
 FIG. 11 Week 6. Subcapsular cortical sinus, lymph stasis and cellular necrosis.  $\times 300$   
 FIG. 12 Week 7. Lymph stasis of medullary sinus near hilus with mitotic cells (m).  $\times 300$   
 FIG. 13 Week 8. Large germinal centre showing mitosis (m) and extensive cellular necrosis (d).  $\times 350$   
 FIG. 14 Week 8. Part of large germinal centre showing mitosis (m) and cellular necrosis (d).  $\times 300$

The cortical sinuses appeared fairly normal morphologically. They contained a few dead cells, a compact r-e cell component and a large number of small diffusely scattered lymphocytes. Damage to the trabecular fibres with fragmentation was still in evidence.

The medullary sinuses were fairly normal in the deeper parts of the gland, with loosely packed r-e cells and little evidence of lymph stasis. Numbers of small lymphocytes were scattered through the matrix and only a few necrotic cells were present. Towards the hilus, however, there was marked lymph stasis in

the sinuses which contained very loosely dispersed r-e cells, many activated macrophages and numbers of mitotic figures (Fig. 12). The outer layer of the medullary cords adjacent to this reaction showed a very marked increase in the numbers of mitotic divisions.

*Week 8*

There was an overall increase in the size of the node.

Although the cortical tissue was hyperplastic, the changes which contributed most to the enlargement occurred in the medulla.



LYMPH NODE PATHOLOGY IN *TRYPANOSOMA BRUCEI*-INFECTED SHEEP

The cortex contained numerous very large primary follicles and almost as many small follicles of apparently recent origin. All germinal centres were very highly reactive and contained abundant mitotic figures (Fig. 13 & 14). There was, in addition, a disproportionately large number of necrotic cells in these centres (Fig. 13 & 14). The paracortical areas of most follicles were narrow and irregular, the primitive stem cells often forming the outer margin of the follicle. Lymphoblasts were the predominant cell type in the narrow peripheral zones, but a few small lymphocytes were present.

The cortical sinuses were enlarged and irregular in contour. Many r-e cells were present, but there was evidence of fibroblast proliferation between primary

follicles. Necrotic cells were abundant in the sinuses and few mitotic figures were found. The trabeculae were stretched and distorted in many parts.

The medullary cords were very well developed, the almost exclusive cell type being the lymphoblast, with a few small lymphocytes and mature plasma cells. Numerous pyknotic cells were present and a few mitotic figures.

The medullary sinuses occupied relatively less space than in previous weeks and contained frequent cell-free pockets of lymph and an overall loosely packed r-e cell mesh. Small numbers of mitotic figures were scattered in the cell population. Many trabeculae were disrupted by fragmentation of the fibres.

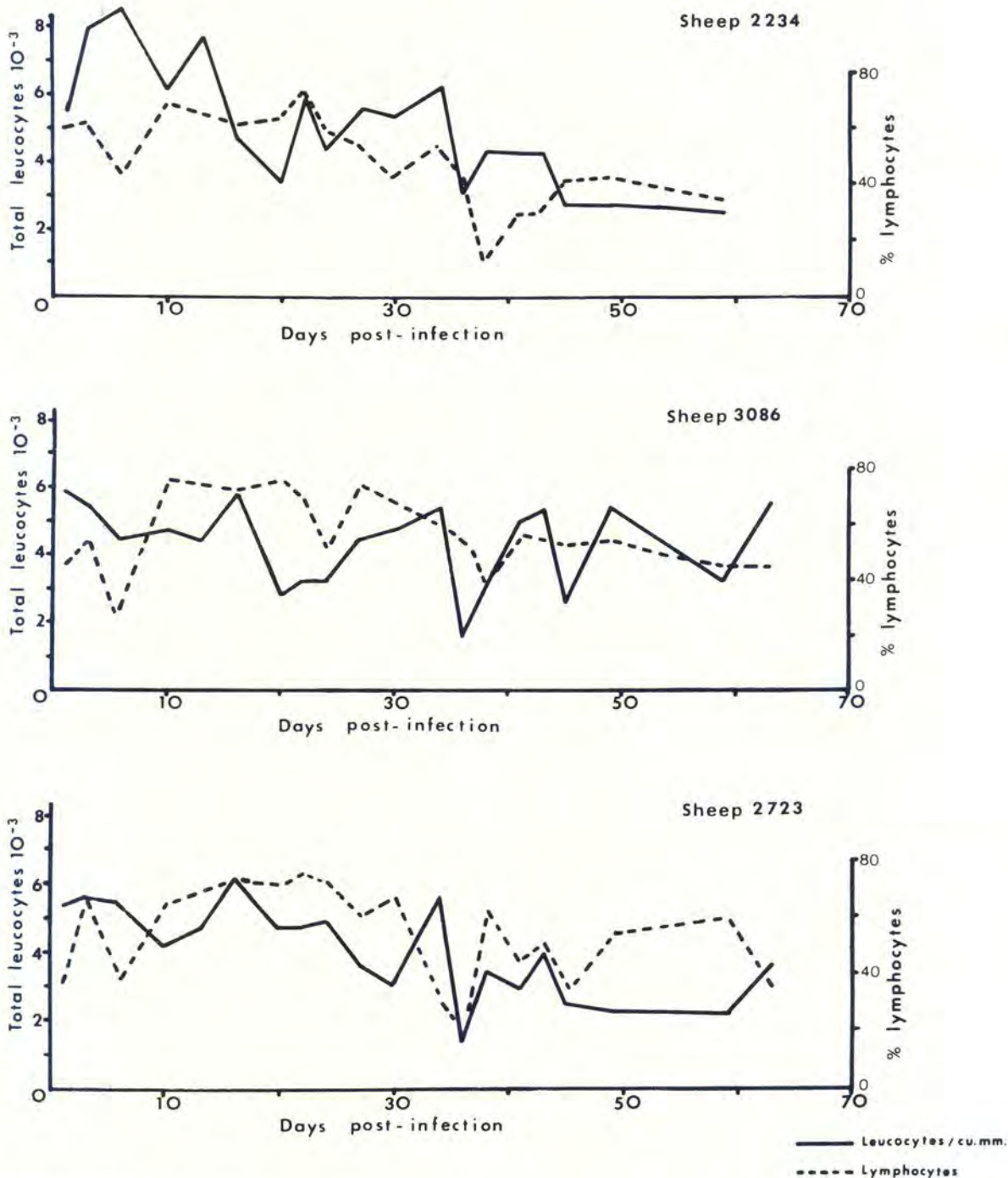


FIG. 15 Haematology of 3 *T. brucei*-infected sheep

*Haematology*

Total leucocyte counts measured in 3 sheep (Fig. 15) fluctuated during the course of infection and the general pattern was one of progressive leucopaenia, with cell counts falling to as low as 30% of normal values. This fall was particularly evident during the last 2 weeks of infection.

Differential leucocyte counts (Fig. 15) showed a progressive depression in the number of circulating lymphocytes. In all 3 sheep there was an initial increase in the relative numbers of lymphocytes to the higher levels of the normal range during the first 18 days of infection and the levels then fell to the middle or lower values of the normal range. There was a corresponding initial fall in the relative numbers of

neutrophils which were later found at higher levels. Monocytes occurred at low levels in sheep before infection and in the early stages of infection, but during the latter half of infection they were scant and frequently absent during differential counts. Eosinophils and basophils (not illustrated) occurred in very low numbers throughout infection, just as in non-infected sheep.

The mean and standard deviation of 50 lymphocyte diameters in the blood of 3 sheep measured at intervals during infection are recorded in Fig. 16. The mean size of the cells showed a slight increase, as did the mean numbers of large lymphocytes during middle and late infection. A slight shift in cell population towards large lymphocytes thus occurred at some stages of infection.

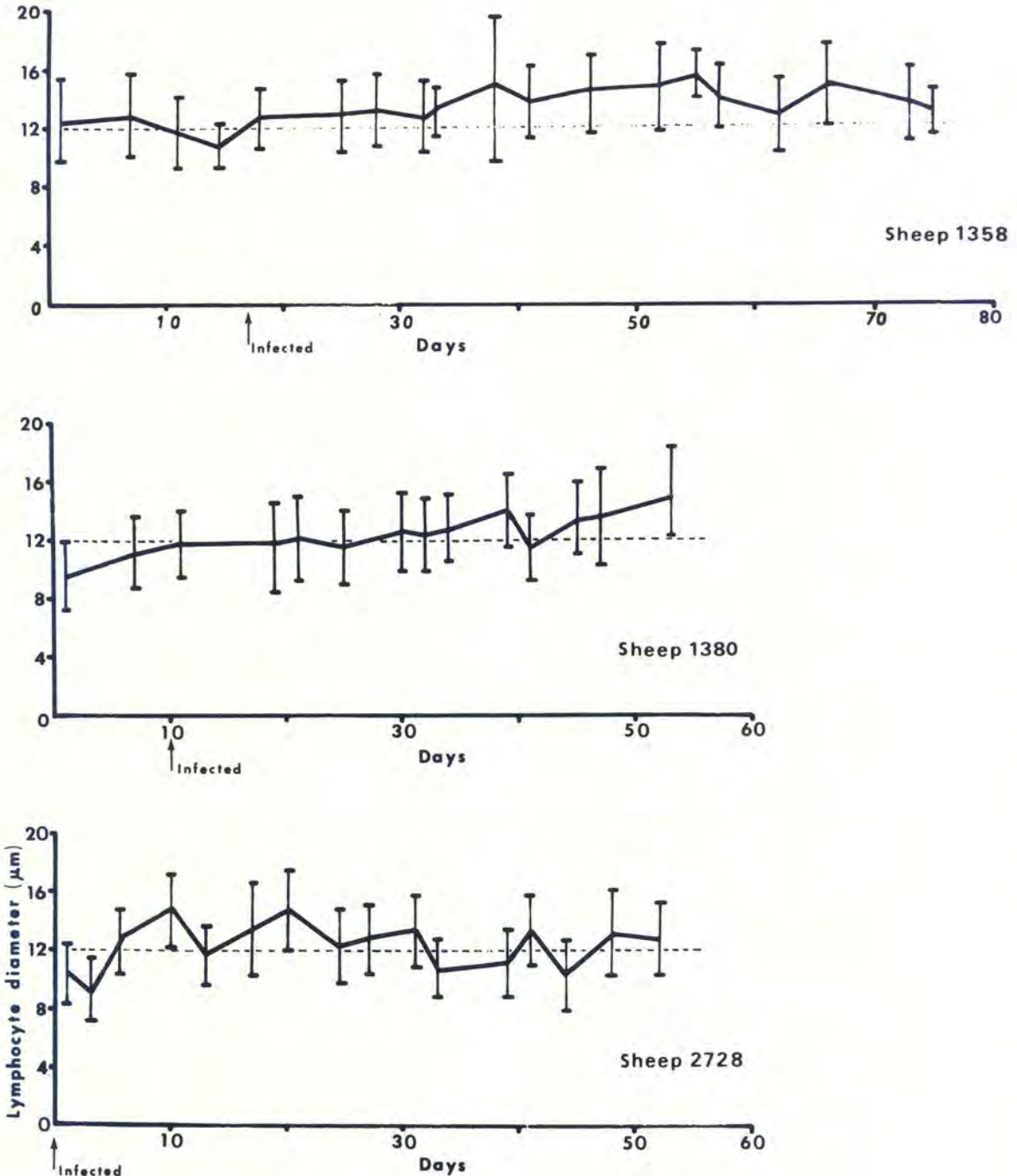


FIG. 16 Mean and standard deviation of blood lymphocyte diameters of 3 *T. brucei*-infected sheep



## DISCUSSION

The sequence of changes observed in the lymph nodes of *T. brucei*-infected sheep appears to start with lymphoid stimulation which is soon overtaken and masked by intense stimulation and proliferation of the r-e cells. R-e proliferation results in macrophage accumulation which is associated with some vascular damage, neutrophil infiltration and lymph stasis in the sinuses, which varies from insidious to extensive. Later, the r-e activity diminishes, although not completely, and there is an upsurge of proliferative activity in lymphoid tissue. The proliferative sinus tissues at this stage show evidence of extensive degeneration and cell death in the r-e cells.

Lymphoid stimulation resulted in increasing numbers of primary follicles with increased activity in their germinal centres and led to the production primarily of cells of the lymphoblast/plasmablast type and sometimes of small lymphocytes. Mature plasma cells, although found in increased numbers on some occasions, were not recognized as a predominant cell type. The response appeared principally to involve the blast cells of the germinal centres rather than of the thymus-dependent paracortical areas. As with the r-e component, proliferation of lymphopoietic tissue was associated with cellular necrosis which increased through the course of infection. It is not clear whether the presence of so many dead or dying cells is the natural consequence of a highly proliferative cell population or the result of the direct cytotoxic effect of soluble trypanosomal proteins on lymphocytes which can be demonstrated *in vitro* (Barrowman, 1978, in preparation).

Lymphoid tissue may be expected to respond to infection by increased lymphopoiesis and the production of increased numbers of lymphocytes and plasma cells and, in trypanosomiasis, this would be predictably intense and prolonged in response to a succession of antigenic variants. Although this would explain some of the lymphoid response, the enlargement in trypanosome infections was considerable and, in the case of *T. brucei*-infected sheep, did not appear to be directed at the production of plasma cells. In contrast, Murray *et al.* (1974c) found a marked increase in plasma cell reproduction in *T. brucei*-infected rats, as did Mönckeberg & Simons (1918) in dogs. The intense lymphoid proliferative activity in infected sheep was not correlated with increased numbers of lymphocytes circulating in the blood; in fact, the opposite occurred with a fall in both total leucocytes and the lymphocyte fraction. It is evident that some lymphocytes may be removed from the circulation into the cellular infiltrates of infected tissues and equally apparent that there was retention and degeneration of large numbers of lymphoid cells within the lymph nodes. The events occurring are therefore not entirely what would be expected from a series of antigenic challenges and the gross histological expansion of blast cells may be explained, in part, by the non-specific mitogenic activity of trypanosome components demonstrated *in vitro* (Esuruoso, 1976; Mansfield, Craig & Stelzer, 1976). The pathogenic effects of trypanosomes on lymphoid tissue have been the focus of recent attention (Murray, Jennings, Murray & Urquhart, 1974b; Mansfield *et al.*, 1976; Hudson, Byner, Freeman & Terry, 1976; Jayawardena & Waksman, 1977; Corsini, Clayton, Askonas & Ogilvie, 1977). The underlying mechanism and significance of r-e cell expansion, however, remain unexplained. Murray, Jennings, Murray & Urquhart (1974a) concluded that in mice the immuno-

genic potential of macrophages appeared to be unimpaired, although there might be a dilution of antigen concentration in expanded tissues below levels necessary to initiate antibody formation.

The changes found in these sheep were qualitatively similar to those described from the rat (Murray *et al.*, 1974c) and from the rabbit (Van den Ingh, 1976), but they varied in temporal sequence. Lymphoid and r-e proliferation occurred in all cases, but the rat and rabbit showed an earlier and more intense lymphopoietic response directed at plasma cell production. Lymphocytolysis and cell necrosis were observed in all 3 species.

The production of multi-nucleated giant cells in lymph nodes of *T. brucei*-infected animals has been reported in the horse (McCully & Neitz, 1971), the donkey (Ikede, Akpokodje, Hill & Ajidagba, 1977) and the dog (Mönckeberg & Simons, 1918). Large epitheloid-type macrophages have also been found in rabbits (Van den Ingh, 1976). Similar cell types were not observed in sheep in the present study and have not been reported from other ruminants (Losos & Ikede, 1972) or from rodents (Murray *et al.*, 1974c).

In the present study trypanosomes could very rarely be recognized in lymphoid tissue and, when they were found, their numbers were small. Ikede & Losos (1972), on the other hand, found either no parasites or moderate numbers of them in *T. brucei*-infected sheep; Van den Ingh (1976) found moderate numbers in the rabbit and Murray *et al.* (1974c) found parasites in the lymph nodes of the rat throughout infection.

## ACKNOWLEDGEMENTS

The authors wish to thank Mr A. du Bruyn for helping with the production of the photographic material, Messrs M. J. Ferreira and R. Bessenger for their technical assistance and Prof. R. C. Tustin for criticism of the manuscript.

## REFERENCES

- CORSINI, A. C., CLAYTON, C., ASKONAS, B. A. & OGILVIE, B. M., 1977. Suppressor cells and loss of B-cell potential in mice infected with *Trypanosoma brucei*. *Clinical and Experimental Immunology*, 29, 122-131.
- ESURUOSO, G. O., 1976. The demonstration *in vitro* of the mitogenic effects of trypanosomal antigen on the spleen cells of normal, athymic and cyclophosphamide treated mice. *Clinical and Experimental Immunology*, 23, 314-317.
- FIENNES, R. N., T-W., 1953. The result of autopsies on trypanosome-infected cattle. *British Veterinary Journal*, 109, 511-520.
- FIENNES, R. N., T-W., 1970. Pathogenesis and pathology of animal trypanosomiasis. In: *The African Trypanosomiasis*. Ed. MULLIGAN, H. W., London: George Allen & Unwin.
- GOODWIN, L. G., GREEN, D. G., GUY, M. W. & VOLLER, A., 1972. Immunosuppression during trypanosomiasis. *British Journal of Experimental Pathology*, 53, 40.
- HALL, J. G., 1967. A new method of collecting lymph from the prefemoral lymph node of unanaesthetised sheep. *Quarterly Journal of Experimental Physiology*, 52, 200-205.
- HUDSON, K. M., BYNER, C., FREEMAN, J., TERRY, R. J., 1976. Immunodepression, high IgM levels and evasion of the immune response in murine trypanosomiasis. *Nature (London)*, 264, 256-258.
- IKEDE, B. O., AKPOKODJE, J. U., HILL, D. H. & AJIDAGBA, P. O. A., 1977. Clinical haematological and pathological studies in donkeys experimentally infected with *Trypanosoma brucei*. *Tropical Animal Health and Production*, 9, 93-98.
- IKEDE, B. O. & LOSOS, G. J., 1972. Pathology of the disease in sheep produced experimentally by *Trypanosoma brucei*. *Veterinary Pathology*, 9, 278-289.
- JAYAWARDENA, A. N. & WAKSMAN, B. H., 1977. Suppressor cells in experimental trypanosomiasis. *Nature (London)*, 265, 539-541.



- LOSOS, G. J. & IKEDE, B. O., 1972. Review of pathology of diseases in domestic and laboratory animals caused by *Trypanosoma congolense*, *T. vivax*, *T. brucei*, *T. rhodesiense* and *T. gambiense*. *Veterinary Pathology*, Supplement to Volume 9.
- MANSFIELD, J. M., CRAIG, S. A. & STELZER, G. T., 1976. Lymphocyte function in experimental African trypanosomiasis: Mitogenic effects of trypanosome extracts *in vitro*. *Infection and Immunity*, 14, 976-981.
- MANSFIELD, J. M. & WALLACE, J. H., 1974. Suppression of cell-mediated immunity in African trypanosomiasis. *Infection and Immunity*, 10, 335.
- MATTERN, P., 1962. B<sub>2</sub>-macroglobulinrachie importante chez des malades atteints de trypanosomiase africaine. *Annales de l'institut Pasteur*, 102, 64-68.
- MCCULLY, R. M. & NEITZ, W. O., 1971. Clinicopathological study on experimental *Trypanosoma brucei* infections in horses. Part 2. Histopathological findings in the nervous system of treated and untreated horses reacting to nagana. *Onderstepoort Journal of Veterinary Research* 38, 141-176.
- MÖNCKEBERG, J. G. & SIMONS, H. C. R., 1918. Zur pathologischen Anatomie der experimentellen Nagana bei Hunden. *Zeitschrift für Hygiene und Infektionskrankheiten*, 87, 77-118.
- MURRAY, P. K., JENNINGS, F. W., MURRAY, M. & URQUHART, G. M., 1974 (a). The nature of immunosuppression in *Trypanosoma brucei* infections in mice. 1. The role of the macrophage. *Immunology*, 27, 815-824.
- MURRAY, P. K., JENNINGS, F. W., MURRAY, M. & URQUHART, G. M., 1974 (b). The nature of immunosuppression in *Trypanosoma brucei* infections in mice. 2. The role of T and B lymphocytes. *Immunology*, 27, 825-840.
- MURRAY, M., MURRAY, P. K., JENNINGS, F. W., FISHER, E. W. & URQUHART, G. M., 1974 (c). The pathology of *Trypanosoma brucei* infection in the rat. *Research in Veterinary Science*, 16, 77-84.
- ORMEROD, W. E., 1970. Pathogenesis and pathology of trypanosomiasis in man. In: *The African Trypanosomiasis*. Ed. MULLIGAN, H. W., London: George Allen & Unwin.
- PERUZZI, M. R. I., 1928. Pathologico-anatomical and serological observations on the trypanosomiasis. Final report, League of Nations International Committee on Human Trypanosomiasis, 3, 245-328.
- STEPHEN, L. E., 1966. Pig trypanosomiasis in tropical Africa. Commonwealth Agricultural Bureaux: England.
- VAN DEN INGH, T. S. G. A. M., 1976. Pathology and pathogenesis of *Trypanosoma brucei brucei* infection in the rabbit. D.V.Sc. Thesis. University of Utrecht, Holland