

A fatal outcome of pica

Donovan P. Loots^{1*} and Lorraine du Toit-Prinsloo¹

¹Department of Forensic Medicine, University of Pretoria, Private Bag X323, Arcadia 0007, South Africa

*correspondence author: Donovan P. Loots : donovan.loots@up.ac.za

Case report

A previously healthy 31 year old African male was assisting friends with the repair of the roof of a neighboring house. That evening at a social gathering the man complained of an apparent headache and went home early where he later died suddenly and unexpectedly. No history indicating the possibility of an underlying psychiatric illness was obtained. Due to the nature and circumstances surrounding the sudden unexpected death the body was referred for a medico-legal investigation in terms of the Inquests Act 58 of 1959.

A postmortem full-body scan using the LODOX[®] Statscan was performed prior to the commencement of the autopsy and confirmed the presence of multiple sharp radio-opaque foreign objects in the region of the stomach, small bowel, descending colon, and sigmoid colon (Fig. 1).

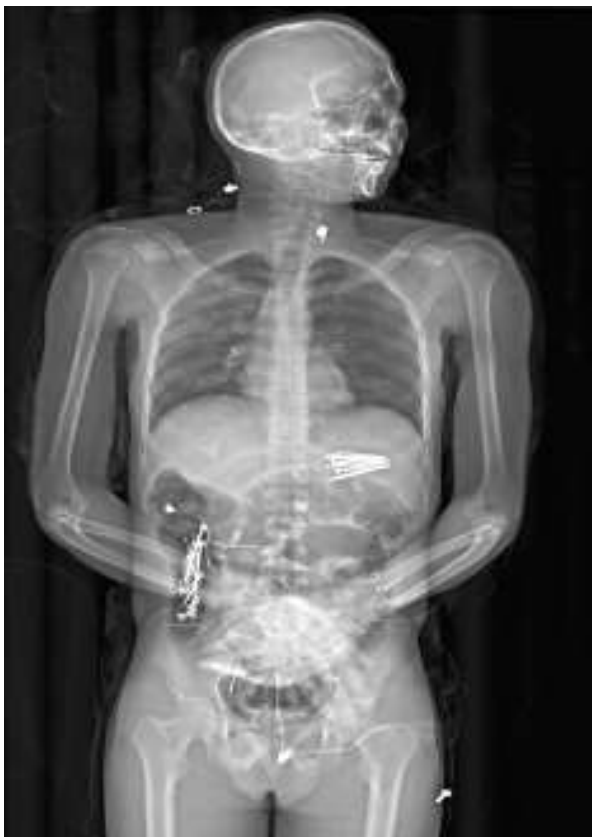

Fig. 1 A full body LODOX[®] Statscan depicting the presence of the foreign metal objects throughout the gastrointestinal tract—the razor blade is not visible in the esophagus

At autopsy, examination of the clothing revealed blood stains on the shirt and trousers. Further inspection of the clothing revealed a box of “LION” double edge razor blades, a triangular piece of glass mirror and a single screw in the pockets of the shirt and trousers. No injuries were identified on

external examination and the deceased was well nourished and of average build. Internal examination showed superficial incisional wounds to the tongue and blood was present in the mouth. No injuries were present in the neck structures and there were no fluid collections in the thoracic or abdominal cavities. Removal of the thoracic organs revealed an extensive posterior hemomediastinum and upon opening of the esophagus a single razor blade was found lodged within the esophageal lumen. Multiple incised wounds were present in the posterolateral wall of the esophagus, with associated signs of hemorrhage (Fig. 2). The trachea contained blood and upon sectioning, the lungs showed patchy hyperemic areas suggestive of aspiration of blood. There was an incised wound in the anterior wall of the descending thoracic aorta subjacent/immediately posterior to the injuries described in the esophagus.

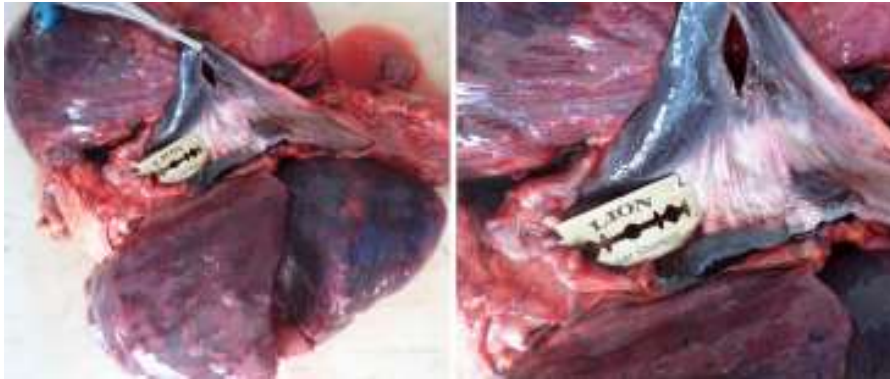

Fig. 2 The posterior aspect of the esophagus showing the perforating defect through the posterior wall

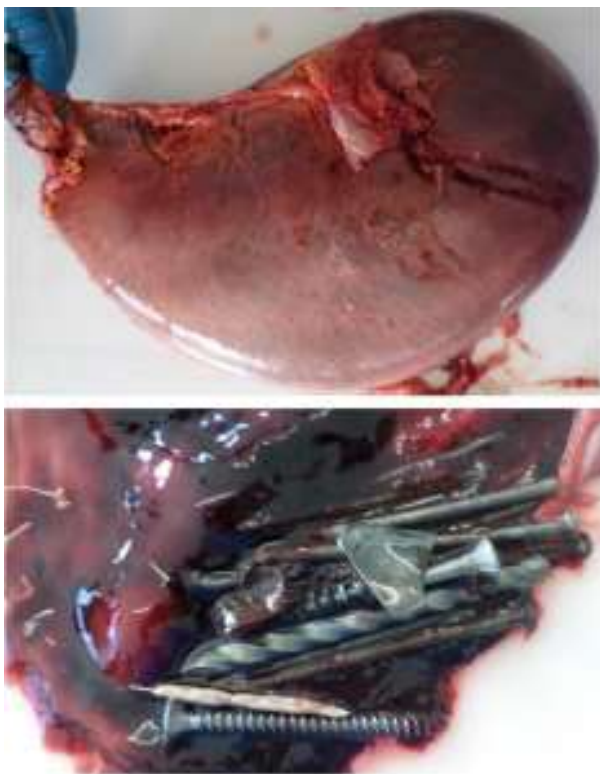


Fig. 3 The stomach showing multiple ingested metal objects

The stomach was large and over distended. Upon opening, 1600 ml fresh blood was noted within the stomach. The mucosa was hyperemic and hemorrhagic. Approximately 15 metallic foreign objects in the form of screws, nails, and pieces of metal wire were present within the stomach in the pre-pyloric region (Fig. 3). No serosal abnormalities or injuries were noted on the intestines. Upon opening of the

intestines approximately 21 mixed foreign objects including nails, screws, pieces of metal wire, and a triangular piece of metal were present within the cecum, the largest of which measured approximately 7.5 cm in length (Figs. 4, 5). A single metallic nail was noted in the ileum and multiple small pieces of metal wire/staples were present in the descending colon and sigmoid colon. No perforations or hemorrhages were noted within the intestinal lumen. A total of 49 foreign objects were retrieved from the gastrointestinal tract (Fig. 6).

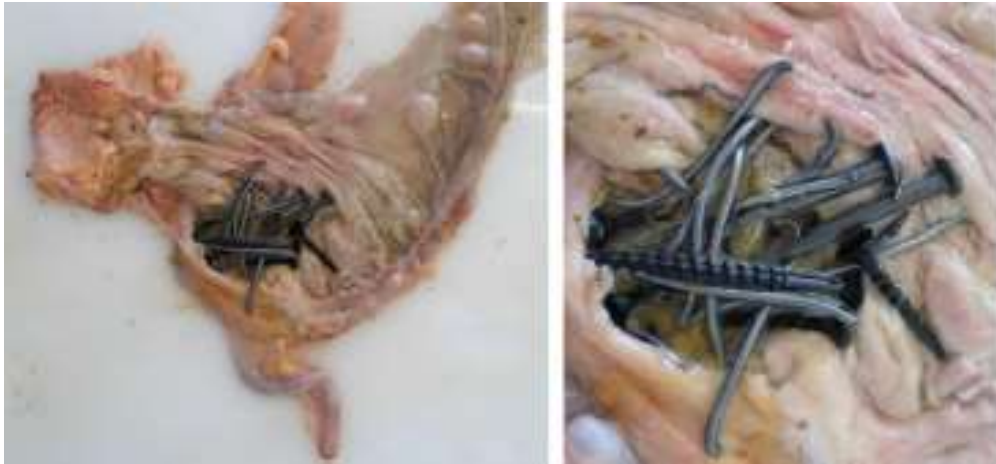

Fig. 4 The cecum showing multiple ingested metal objects at the ileocecal junction



Fig. 5 The items retrieved from the cecum, including the largest item measuring approximately 7.5 cm in length



Fig. 6 All foreign objects retrieved from the gastrointestinal tract and clothing

The visceral organs (liver, spleen, and kidney) were pale. The cause of death was ascertained to be hemorrhage secondary to foreign body (razor blade) ingestion.

Discussion

Pica is defined as the “compulsive eating of non-nutritional substances,” such as ice (pagophagia), dirt (geophagia), gravel, paint flakes, clay, hair (trichophagia), or laundry starch (amylophagia) [1]. The term was derived from the Latin word for a magpie (*pica pica*) [1, 2]. The classification of pica (according to the fifth edition of *The Diagnostic And Statistical Manual Of Mental Disorders*) has changed from a disorder with onset in childhood and adolescence, to a feeding and eating disorder with no age specification for its onset [3]. The ingestion of foreign objects can either be accidental or intentional [3, 4]. Foreign body ingestion is a common occurrence in children and specific high-risk adult groups such as alcoholics, the elderly with dentures, prison inmates, and psychiatric patients [3–8]. The most commonly ingested foreign objects retrieved from the esophagus include food-related objects such as chicken and fish bones, a bolus of meat, nuts/seeds and shells [5, 7, 9].

Intentional ingestion of foreign objects is seen most commonly in prison inmates and psychiatric patients [10]. In 1991, Barros et al. [11] indicated that approximately 1500 people died in the United States of America annually due to intentional ingestion of foreign objects.

Grimes et al. [12] investigated certain predictors for recurrent ingestion of foreign bodies. The authors identified 159 cases of foreign body ingestion with 45 cases (23 %) having multiple episodes of foreign body ingestion (as similarly observed in our case) [12]. In their study most patients had recurrent ingestion of food-related objects with impaction (27 cases—60 %) although in 18 cases (40 % of the patients) ingestion of other non-nutritive foreign bodies was reported. Risk factors associated with the recurrent ingestion of foreign objects included male gender, incarceration (the average number of recurrent episodes in prisoners were 4.1 per person), and psychiatric diseases (the average number of recurrent episodes in psychiatric patients were 3.9 per person) [12]. The location of the foreign objects within the gastrointestinal tract, as described in our case report, suggests that multiple episodes of foreign body ingestion occurred over a period of time prior to the terminal event.

Gastrointestinal tract complications, such as perforation following the ingestion of foreign bodies, is said to be rare, occurring in less than 1 % of cases [8]. Perforations are more commonly encountered when sharp pointed objects such as toothpicks and needles are ingested and become lodged at

normal anatomical narrowings within the gastrointestinal tract [4]. Goh et al. [5] reviewed 62 patients who required surgical intervention following gastrointestinal tract perforation after ingestion of foreign bodies. They reported the terminal ileum to be the anatomical location most frequently perforated by the foreign body (38.6 % of the cases).

Velitchkov et al. [8] reviewed 542 patients with 1203 ingestions (1973–1993). The authors indicated in their study that objects 6 cm long were found retained in the stomach and objects 6 cm in length had the tendency to impact in the ileocecal region. In our case, the longest ingested item was found in the cecum and was approximately 7.5 cm in length. In a study by Grimes et al. [12] 117 endoscopic procedures were conducted in 45 cases of recurrent ingestions. The locations where the foreign bodies were most frequently found were in the esophagus (59 procedures), followed by the stomach (53 procedures), with only five foreign bodies retrieved from other locations (duodenum, rectum, and sig-moid colon). Surgery was needed in only 4 cases. Dalal et al. [10] reviewed 141 incidents of intentional ingestion of foreign bodies (2004–2012). The majority of foreign bodies were lodged in the stomach, the mean number of items ingested per episode was 4.6, and the majority of the ingested objects were larger than 5 cm.

Many of the studies on gastrointestinal foreign body ingestion exclude cases with foreign bodies in the esophagus due to the difference in the clinical management of these cases [8, 13]. Razor blade ingestions were present in 4 of the cases in the study by Grimes et al. [12]. Velitchkov et al. [8] had 16 razor blade ingestions in 542 patients and Dalal et al. [10] found ingested razor blades in 24 of the 141 incidents of intentional foreign body ingestions in their study.

Fatalities following pica include complications such as intestinal obstruction and perforation, airway obstruction, poisoning, infections, and electrolyte disturbances [2]. There would appear to be a paucity of scientific data indicating the mortality associated specifically with ingestion of razor blades. Velitchkov et al. [8] had no recorded deaths in their study. The authors excluded foreign objects in the esophagus but did encounter razor blade ingestions in the rest of the gastrointestinal tract.

Radiographic imaging is still regarded as the best diagnostic tool in identifying the type and location of ingested foreign bodies. In the clinical setting this would also assist in the planning of the appropriate therapy and management of the patients [14, 15]. All cases admitted to the Pretoria Medico-Legal Laboratory receive a LODOX[®] Statscan (low-dose radiography) prior to commencement of an autopsy. Mantokoudis et al. [15] compared the reliability of LODOX[®] Statscan with digital X-rays in locating ingested foreign objects. They indicated that the LODOX[®] Statscan was more sensitive and specific in locating ingested foreign bodies than both traditional digital chest X-rays and CT scans. The authors indicated that the advantage of the LODOX[®] Statscan was that the full body image obtained assisted in locating foreign bodies which passed further down the gastrointestinal tract and were thus not visible on the normal digital chest X-ray. Furthermore, radiolucent objects were detected in 8 of the 16 patients [15]. In the study by Dalal et al. [10] radiographic imaging did not identify the foreign body in 36 % of cases where objects were later identified endoscopically.

In our case the LODOX[®] Statscan revealed all the foreign objects (metallic nails, screws, and pieces of wire as seen in Fig. 1) in the gastrointestinal tract with the exception of the razor blade lodged in the esophagus. The presence of the razor blade in the esophagus was only discovered during the autopsy. The presence of an unexpected sharp object in the esophagus may pose additional health and safety risks to the pathologist at the time of the autopsy. We propose that the reason why the razor blade was not identified with the LODOX[®] Statscan could be due to the position of the blade in relation to the surrounding mediastinal soft tissue structures. Marketing websites/lay publications indicate the standard measurements of a double edged razor blade to be 43.922 mm with a maximal thickness of 0.1 mm. The size and thickness of the blade in addition to the overlying mediastinal soft tissues could have contributed to the blade not being visualized during the full-body low-dose imaging.

We described a case of pica characterized by the ingestion of numerous metallic foreign objects on different occasions over an undetermined period of time. The terminal event in our case was the ingestion of a razor blade with subsequent perforation of the esophagus and aorta. Postmortem imaging prior to the commencement of the autopsy failed to reveal the razor blade in the esophagus despite still being considered the modality of choice in identifying ingested foreign bodies. It is advised that pathologists should pay special attention to the mediastinal region when foreign bodies are identified in the gastroin-testinal tract with postmortem imaging, as some objects may not be evident.

References

1. Dorland's illustrated medical dictionary. 31st ed. Philadelphia: Saunders Elsevier; 2007. p. 1466.
2. Byard RW. A review of the forensic implications of pica. *J Forensic Sci.* 2014;59(5):1413–6.
3. Yamaguchi Y, Terashima M, Nakao A, et al. To remove or not remove? Twenty or more sewing needles in the gastrointestinal tract. *Acute Med Surg.* 2014;1:250–1.
4. Zouros E, Oikonomou D, Theoharis G, Bantias C, Papadimitropoulos K. Perforation of the cecum by a toothpick: report of a case and review of the literature. *J Emerg Med.* 2014;47(6): e133–7.
5. Goh BK, Chow PK, Quah HM, Ong HS, Eu KW, Ooi LL, et al. Perforation of the gastrointestinal tract secondary to ingestion of foreign bodies. *World J Surg.* 2006;30(3):372–7.
6. Baraka A, Bikhazi G. Oesophageal foreign bodies. *Br Med J.* 1975;1(5957):561–3.
7. Cangir AK, Tug T, Okten I. An unusual foreign body in the esophagus: report of a case. *Surg Today.* 2002;32(6):523–4.
8. Velitchkov NG, Grigorov GI, Losanoff JE, Kjossev KT. Ingested foreign bodies of the gastrointestinal tract: retrospective analysis of 542 cases. *World J Surg.* 1996;20(8):1001–5.
9. Hong KH, Kim YJ, Kim JH, Chun SW, Kim HM, Cho JH. Risk factors for complications associated with upper gastrointestinal foreign bodies. *World J Gastroenterol.* 2015;21(26):8125–31.
10. Dalal PP, Otey AJ, McGonagle EA, Whitmill ML, Levine EJ, McKimmie RL, et al. Intentional foreign object ingestions: need for endoscopy and surgery. *J Surg Res.* 2013;184(1):145–9.
11. Barros JL, Caballero A Jr, Rueda JC, Monturiol JM. Foreign body ingestion: management of 167 cases. *World J Surg.* 1991;15(6):783–8.
12. Grimes IC, Spier BJ, Swize LR, Lindstrom MJ, Pfau PR. Predictors of recurrent ingestion of gastrointestinal foreign bodies. *Can J Gastroenterol.* 2013;27(1):e1–4.
13. Gracia C, Frey CF, Bodai BI. Diagnosis and management of ingested foreign bodies: a ten-year experience. *Ann Emerg Med.* 1984;13(1):30–4.
14. Eisen GM, Baron TH, Dominitz JA, Faigel DO, Goldstein JL, Johanson JF, et al. Guideline for the management of ingested foreign bodies. *Gastrointest Endosc.* 2002;55(7):802–6.
15. Mantokoudis G, Hegner S, Dubach P, Bonel HM, Senn P, Caversaccio MD, et al. How reliable and safe is full-body low-dose radiography (LODOX[®] Statscan) in detecting foreign bodies ingested by adults? *Emerg Med J.* 2013;30(7):559–64.