

## Case report of sudden death in a child with Williams syndrome following administration of anaesthesia

L du Toit-Prinsloo<sup>a\*</sup>, JM Dippenaar<sup>b</sup> and EM Honey<sup>c</sup>

<sup>a</sup>Department of Forensic Medicine, University of Pretoria, Arcadia, South Africa

<sup>b</sup>Department of Maxillo-Facial-Oral-Surgery, Oral and Dental Hospital, University of Pretoria, Arcadia, South Africa

<sup>c</sup>Department of Genetics, University of Pretoria, Arcadia, South Africa

\*Corresponding author, email: [lorraine.dutoit@up.ac.za](mailto:lorraine.dutoit@up.ac.za)

Williams syndrome is a neurodevelopmental disorder characterized by distinctive personality traits, facial features (so called “elfin face”) and cardiac abnormalities, of which supra-ventricular aortic stenosis is the most common lesion found. The cause is a deletion of a group of genes on chromosome 7q11.23. Administration of anaesthesia to these patients carries a higher risk for sudden death due to the cardiac defects. The purpose of this case study is to demonstrate the entity in the South African population, to review the literature, to put emphasis on the multi-disciplinary approach in the pre-operative management, and to review the medico-legal investigation of intra-operative deaths. Furthermore, administration of anaesthesia in the remote location and to syndromic children will also be discussed.

**Keywords:** deletion of genes on chromosome 7q11.23, intra-operative deaths, sudden death, supra-ventricular aortic stenosis, Williams syndrome

### Case report

A two-year-old child, confirmed with Williams syndrome (WS) presented with severe dental caries. Extraction of carious teeth under general anaesthesia was recommended because of the increased risk for developing infective endocarditis.

The male child was admitted as an outpatient to the hospital on the morning of surgery. He weighed 13 kg and had a height of 85 cm. He had no positive history for allergies or medication, and no relevant cardiac history such as chest pain or episodes of fainting. The patient displayed typical personality traits and facial features associated with Williams syndrome namely the typical elfin face (periorbital fullness, medial eyebrow flair, a flat nasal bridge and full lips), arrest of intellectual development, and an overfriendly and amiable nature. Cardiovascular examination revealed no murmurs, abnormal heart sounds, or cardiomegaly. Both the liver and spleen were palpable below the costal margin. Pre-operative echocardiography demonstrated a supra-ventricular stenosis of the right ventricular outflow tract. The rest of the cardiac anatomy was reported as normal. Electrolytes, urea, creatinine and full blood count were normal.

After induction of anaesthesia by means of stepwise increase in the concentration of sevoflurane to 4%, intravenous access was achieved. Tracheal intubation was facilitated with the administration of alfentanil (100 µg) and propofol (10 mg). Immediately after intubation, the child developed a bradycardia and severe ST segment elevation on electrocardiogram (ECG). This was followed by cardiac arrest as signified by absence of central pulses, sudden decrease in end tidal CO<sub>2</sub>, and ventricular fibrillation. Cardio pulmonary resuscitation (CPR) was instituted according to the advanced paediatric life support protocols, including numerous defibrillation attempts by automated external defibrillator. CPR failed and the child was declared dead 110 min after the diagnosis of cardiac arrest.

This case was referred for a medico-legal post mortem examination in accordance to section 48 of the Health Professions Amendment

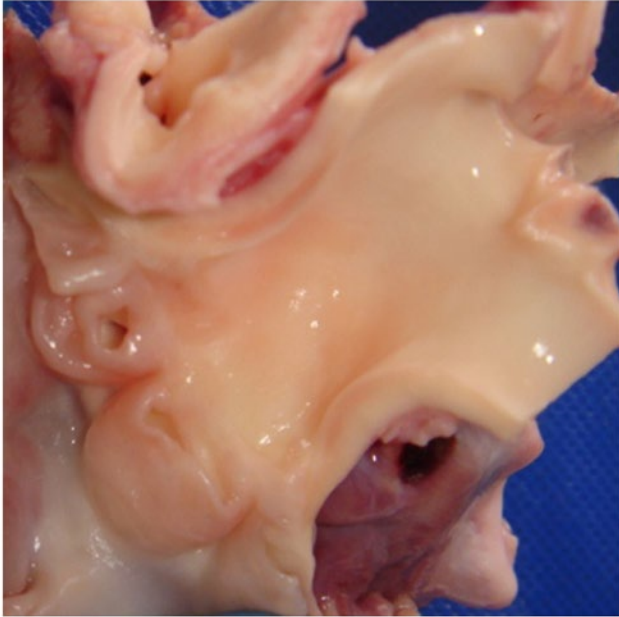
Act 29 of 2007. The latter act prescribes that, if a patient dies during a therapeutic, diagnostic or palliative procedure, the death will not be deemed as being due to natural causes and that a medico-legal post mortem needs to be conducted according to the prescriptions of the Inquests Act 58 of 1959.

At autopsy, the child displayed facial features of Williams syndrome, consisting of periorbital fullness, medial eyebrow flair, a flat nasal bridge and full lips. The height and mass of the deceased was 85 cm (0 to 2 SD) and 13 kg (0 to -2 SD) respectively. The extensive dental caries were evident. No macroscopic or histological abnormalities were noted to the brain, abdominal and pelvic organ blocks. The lungs were markedly enlarged and oedematous with no features of an underlying disease process.

The heart was markedly enlarged macroscopically with a mass of 104 g (normal mass for height = 58 g).<sup>1</sup> Biventricular hypertrophy was present. The left ventricular wall measured 1.1 cm in thickness (normal thickness for age = 0.72 cm)<sup>1</sup> and the right ventricular wall 0.6 cm (normal thickness for age = 0.24 cm).<sup>1</sup> The right coronary cusp of the aortic valve showed fibrotic thickening of the free edges with near complete occlusion of the ostium of the coronary artery (Figure 1). Macroscopically, the coronary arteries were patent with no areas of stenosis. Histological examination of tissue slides showed no areas of fibrosis or recent myocardial ischaemia.

Although no histological evidence of acute myocardial ischaemia was present, this was postulated as the mechanism of death in view of the clinical changes in the ECG pattern and the structural abnormality of the right cusp of the aortic valve. A second possible mechanism of death is an arrhythmia due to the biventricular hypertrophy.

The purpose of this case study is to demonstrate the entity in the South African population, to review the literature, to emphasize the multi-disciplinary approach in the pre-operative management, and to review the medico-legal investigation of deaths under anaesthesia / during procedures. The administration of anaesthesia



**Figure 1:** The heart showing the aortic valve and near complete occlusion of the ostium of the coronary artery

in the remote location as well as to syndromic children will also be discussed.

### Discussion

The incidence of WS is reported to be 1 in 20 000 live births.<sup>2</sup> It was first described by Williams, Barratt-Boyes, and Lowe in 1961.<sup>3</sup> They described the presence of supravalvular aortic stenosis (SVAS), mental retardation and characteristic facial features which included a broad forehead, wide-set eyes, a wide mouth and a pointed chin.<sup>3</sup> Patients also suffer from other types of cardiovascular disease and behavioural and emotional abnormalities.<sup>4,5</sup> Intermittent hypercalcaemia and renal abnormalities, including nephrocalcinosis and renal artery stenosis are also commonly seen.<sup>6</sup>

The SVAS phenotype is due to abnormalities in elastin (ELN) on the long arm of chromosome 7.<sup>7</sup> This can be an isolated autosomal dominant condition or be part of the WS spectrum. Ewart et al. identified hemizygoty at the elastin locus on chromosome 7q11.23 in four familial and five sporadic cases.<sup>8</sup> This was confirmed by Lowery who evaluated 235 patients and detected a submicroscopic deletion of ELN with fluorescent *in situ* hybridization (FISH) in 96% of patients with "classic" WS.<sup>9</sup> Studies subsequently showed that the deletion of approximately 28 genes is responsible for the phenotypic characteristics.<sup>10</sup> The diagnosis can be confirmed with FISH using commercial probes but currently quantitative real-time polymerase chain reaction (PCR) or multiplex ligation-dependent probe amplification (MLPA) is becoming more useful to predict the phenotype in an individual affected with the syndrome.

The abnormalities in the cardiovascular system include SVAS which is regarded as the most common cardiac abnormality and present in 37% to 73% of cases.<sup>11</sup> Mitral valve lesions, pulmonary artery abnormalities, intracardiac lesions, such as ventricular septal defect, as well as tetralogy of Fallot have also been described.<sup>2,3,12–15</sup> Isolated lesions of the coronary arteries are very rare in WS.<sup>11</sup>

Eronen et al. conducted a study reviewing the cardiac manifestation in 75 patients with Williams syndrome.<sup>16</sup> Their study showed that 35 patients out of 75 (47%) of neonates had symptoms of cardiovascular disease, which included cardiac murmurs, cyanosis

and signs of heart failure.<sup>16</sup> Of the symptomatic neonates, 77% had structural cardiac defects.<sup>16</sup>

SVAS was diagnosed in 79% of children aged 1 to 15 years.<sup>16</sup> The infant group also had the most complicated elastin vasculopathy and most surgical interventions were conducted in this group. They concluded that cardiovascular disease, which is diagnosed in infancy, frequently requires surgery, but also emphasised that these patients need to be followed up closely as SVAS tends to progress along with the risk of developing vasculopathy or arterial hypertension.<sup>16</sup>

Van Pelt et al. described the risk of severe coronary artery disease in the absence of SVAS in a case report of a 6 year old.<sup>11</sup> This case indicated that in the majority of cases, abnormalities of the coronary arteries are present in conjunction with SVAS and that both of these abnormalities can be attributed to elastin defects. The authors concluded that coronary artery anomalies in WS should be considered in patients who present with heart failure and ECG abnormalities that are indicative of ischaemic heart disease.<sup>11</sup> The majority of patients with WS live until adulthood and the incidence of coronary artery disease is stated as less than 1%.<sup>2</sup>

Wessel et al. reported sudden death in five patients. The rate of sudden death was estimated to be 1 per 1 000 patient years, which is the same as death following surgery for congenital cardiac disease, but 25 to 100 fold higher compared to age-matched general population.<sup>17</sup> The cause of sudden cardiac death can be related to the presence of coronary artery stenosis and in patients without coronary artery abnormalities, lethal arrhythmias can be considered.<sup>17,18</sup> Gupta et al. indicated that in many of these patients, post mortem examination does not find an underlying anatomical abnormality to explain the sudden cardiac death.<sup>5</sup> The aetiology for myocardial ischaemia in WS can be due to anatomical occlusion of the coronary ostia or as a result of stenosis of the coronary arteries.<sup>5</sup> The latter mentioned abnormalities in the presence of reduced afterload during the anaesthesia can further lead to coronary insufficiency.<sup>5</sup> Furthermore, in the patients with SVAS, the coronary ostia can be occluded by distorted cusps of the aortic valve (proposed in the case we present).<sup>5</sup> There might also be intimal fibrosis in the coronary arteries as a result of the increased pressure transmitted to the vessels.<sup>5</sup> Both Wessel et al.<sup>17</sup> and Bird et al.<sup>19</sup> indicated that the severity of the SVAS is not a predictor for sudden death.

The association between sudden death following the administration of anaesthesia has also been well documented.<sup>5,19,20</sup> Wessel et al. made the distinction in their study and excluded the deaths during anaesthesia from the sudden-death group.<sup>17</sup> In the study by Bird et al. pathological findings in two of the seven patients showed anatomic abnormalities that predisposed the individuals to sudden death (coronary artery stenosis and biventricular outflow tract obstruction).<sup>19</sup> Left ventricular outflow obstruction due to a stenotic valve or subvalvular stenosis/hypertrophy will compromise coronary perfusion. Anaesthetic agents such as propofol or sevoflurane are well known for their vasodilatory properties, which will decrease afterload and worsen the effects on myocardial oxygen supply. The biventricular hypertrophy associated with SVAS will lead to an increase myocardial oxygen consumption and compromised oxygen delivery, which can progress to myocardial ischaemia.<sup>20</sup> Therefore, the induction of anaesthesia with sevoflurane in this patient was not the optimal choice. Likewise, the addition of propofol depressed cardiac output even more. The loss in afterload decreased coronary perfusion to an already compromised right coronary artery (due to the adhesion of the right coronary cusp

occluding the underlying ostium). Oxygen supply to a hypertrophic myocardium was impaired, resulting in myocardial ischemia and cardiac arrest.

Considerations before the administration of anaesthesia in patients with WS should include the risk of sudden death as well as the possibility of underlying involvement of the coronary arteries.<sup>5</sup> It is advised that the pre-anaesthetic workup of these patients should be meticulous and include ECG, transthoracic echocardiogram, and in some cases, even a Holter ECG monitoring and coronary angiography.<sup>5</sup> These investigations attempt to diagnose underlying structural cardiac and coronary artery abnormalities.<sup>5</sup> Some publications also suggest stress echocardiography or stress electrocardiography.<sup>19</sup> "Even with appropriate care, sudden cardiac arrest and death have been reported".<sup>5</sup> In the majority of cases where death followed the administration of anaesthesia, myocardial ischaemia was considered to be the cause of death.<sup>1,19</sup> Monafred et al. postulated arrhythmias as to be the cause of death.<sup>21</sup>

In the case that is presented here, the toddler had severe dental disease. Franco et al. indicated that in children with congenital cardiac abnormalities, dental caries were present in moderately high levels and the amount of untreated dental disease was more.<sup>22</sup> This places children at an increased risk for developing infective endocarditis – a potentially life threatening disease.<sup>22</sup>

In this case, the risk for the toddler of developing infective endocarditis was deemed higher than the possible risk of the procedure. Pre-operative workup of this case included a comprehensive examination by a cardiologist. We postulated that the mechanism of death was the occlusion of the coronary ostia due to the deformed cusp of the aortic valve with subsequent myocardial ischaemia. The fact that a case is referred for medico-legal investigation does not mean that medical negligence was considered a possibility – unless that was the primary reason for referral.

The administration of anaesthesia in a remote location away from a fully functional operating theatre complex presents a number of challenges. These challenges are centred on the facility itself (location, equipment and staffing),<sup>23</sup> the needs of the surgeon and the typical patient requiring the service. The facility is often far removed from the operating complex (on a different floor, in a different building) and thus far from senior specialised help. It was not designed with the needs of anaesthesia in mind, and anaesthetists often find themselves in an icy cold, dark corner far from the patient.<sup>24</sup> Clinical interaction is restricted, forcing increased vigilance and reliance on information displayed via essential monitors. The inattentive anaesthetist may miss the early warning signs of impending disaster should his or her attention be somewhere else. It is well known that adverse events arising during anaesthesia in remote locations are associated with a higher severity in injury and unfavourable outcome.<sup>25</sup> These procedures are done on an outpatient basis, mandating short acting agents and the availability of reversal agents for drugs used. Proper venous access is mandatory, in spite of the assumed triviality of the procedure.

The child with a rare syndrome maybe encountered on the elective or emergency list. The two most frequent problems encountered by the anaesthetist are difficulty in airway management as well as associated cardiovascular complications. The pre-operative examination must therefore take into consideration the impact of the phenotypic features and underlying systemic manifestations on the anaesthetic conduct.

When the abovementioned aspects are considered together, it becomes increasingly difficult to justify anaesthetising the syndromic child in a remote location. Patients with an underlying disease or syndrome that is known to have a high risk of death on induction should be anaesthetised in a unit skilled in and equipped for the management of children with congenital cardiac disease. The process of obtaining informed consent from the parents prior to the procedure should also be multi-disciplinary and carefully outline the expected risks of the underlying disease process against the benefits of the potential high risk of sudden death.

## References

- Scholz DG, Kitzman DW, Hagen PT, et al. Age-related changes in normal human hearts during the first 10 decades of life. Part I (Growth): a quantitative anatomic study of 200 specimens from subjects from birth to 19 years old. *Mayo Clin Proc.* 1988;63:126–36. [http://dx.doi.org/10.1016/S0025-6196\(12\)64945-3](http://dx.doi.org/10.1016/S0025-6196(12)64945-3)
- Horowitz PE, Akhtar S, Wulff JA, et al. Coronary artery disease and anesthesia-related death in children with Williams syndrome. *J Cardiothorac Vasc Anesth.* 2002 Dec;16(6):739–41. <http://dx.doi.org/10.1053/jcan.2002.128407>
- Williams JCP, Barratt-Boyes BG, Lowe JB. Supravalvular Aortic Stenosis. *Circulation.* 1961 Dec;24:1311–8. <http://dx.doi.org/10.1161/01.CIR.24.6.1311>
- Imashuku S, Hayashi S, Kuriyama K, et al. Sudden death of a 21-year-old female with Williams syndrome showing rare complications. *Pediatr Int.* 2000 Jun;42:322–4. <http://dx.doi.org/10.1046/j.1442-200x.2000.01213.x>
- Gupta P, Tobias JD, Goyal S, et al. Sudden cardiac death under anesthesia in pediatric patient with Williams syndrome: a case report and review of literature. *Annals Card Anaesth.* 2010 Jan–Apr;13(1):44–8. <http://dx.doi.org/10.4103/0971-9784.58834>
- Sammour ZM, Gomes CM, de Bessa J et al. Congenital genitourinary abnormalities in children with Williams–Beuren syndrome. *J Pediatr Urol.* 2014 Feb 13; pii: S1477-5131(14)00043-6. [Epub ahead of print]. Available from: <http://dx.doi.org/10.1016/j.jpuro.2014.01.013>
- Ewart AK, Morris CA, Ensing GJ, et al. A human vascular disorder, supravalvular aortic stenosis, maps to chromosome 7. *Proc Natl Acad Sci USA.* 1993 April;90(8):3226–30. <http://dx.doi.org/10.1073/pnas.90.8.3226>
- Ewart AK, Morris CA, Atkinson D, et al. Hemizygoty at the elastin locus in a developmental disorder, Williams syndrome. *Nat Genet.* 1993 Sep;5(1):11–6. <http://dx.doi.org/10.1038/ng0993-11>
- Lowery MC, Morris CA, Ewart A, et al. Strong correlation of elastin deletions, detected by FISH, with Williams syndrome: evaluation of 235 patients. *Am J Hum Genet.* 1995 Jul;57(1):49–53.
- Schubert C. The genomic basis of the Williams–Beuren syndrome. *Cell Mol Life Sci.* 2009 Apr;66(7):1178–97. <http://dx.doi.org/10.1007/s00018-008-8401-y>
- van Pelt NC, Wilson NJ, Lear G. Severe coronary artery disease in the absence of supravalvular stenosis in a patient with Williams syndrome. *Pediatr Cardiol.* 2005 Sep–Oct;26(5):665–7. <http://dx.doi.org/10.1007/s00246-004-0845-8>
- Beuren AJ, Schulze C, Eberle P, et al. Syndrome of supravalvular aortic stenosis, peripheral pulmonary stenosis, mental retardation, and similar facial appearance. *Am J Cardiol.* 1964 Apr;13:471–83. [http://dx.doi.org/10.1016/0002-9149\(64\)90154-7](http://dx.doi.org/10.1016/0002-9149(64)90154-7)
- Becker AE, Becker MJ, Edwards JE. Mitral valvular abnormalities associated with supravalvular aortic stenosis. *Am J Cardiol.* 1972 Jan;29(1):90–4. [http://dx.doi.org/10.1016/0002-9149\(72\)90421-3](http://dx.doi.org/10.1016/0002-9149(72)90421-3)
- Ino T, Nishimoto K, Iwahara M, et al. Progressive vascular lesions in Williams–Beuren syndrome. *Pediatr Cardiol.* 1988;9(1):55–8. <http://dx.doi.org/10.1007/BF02279886>
- Conway EE, Noonan J, Marion RW, et al. Myocardial infarction leading to sudden death in the Williams syndrome: report of three cases. *J Pediatr.* 1990 Oct;117(4):593–5. [http://dx.doi.org/10.1016/S0022-3476\(05\)80696-1](http://dx.doi.org/10.1016/S0022-3476(05)80696-1)
- Eronen M, Peippo M, Hiippala A, et al. Cardiovascular manifestations in 75 patients with Williams syndrome. *J Med Genet.* 2002 Aug;39(8):554–8. <http://dx.doi.org/10.1136/jmg.39.8.554>

17. Wessel A, Gravenhorst V, Buchhorn R, et al. Risk of sudden death in the Williams–Beuren syndrome. *Am J Med Genet A*. 2004 Jun;127A(3):234–7. [http://dx.doi.org/10.1002/\(ISSN\)1096-8628](http://dx.doi.org/10.1002/(ISSN)1096-8628)
18. Kantharia B, Mittleman RS. Concomitant reentrant tachycardias from concealed accessory atrioventricular bypass tract and atrioventricular nodal reentry in a patient with Williams syndrome. *Cardiology*. 1999;91:264–7. <http://dx.doi.org/10.1159/000006921>
19. Bird LM, Billman GF, Lacro RV, et al. Sudden death in Williams syndrome: report of ten cases. *J Pediatr*. 1996 Dec;129(6):926–31. [http://dx.doi.org/10.1016/S0022-3476\(96\)70042-2](http://dx.doi.org/10.1016/S0022-3476(96)70042-2)
20. Burch TM, McGowan FX Jr, Kussman BD, et al. Congenital supravalvular aortic stenosis and sudden death associated with anesthesia: what's the mystery? *Anesth Analg*. 2008 Dec;107(6):1848–54. <http://dx.doi.org/10.1213/ane.0b013e3181875a4d>
21. Monfared A, Messner A. Death following tonsillectomy in a child with Williams syndrome. *Int J Pediatr Otorhinolaryngol*. 2006 Jun;70(6):1133–5. <http://dx.doi.org/10.1016/j.ijporl.2005.11.009>
22. Franco E, Saunders CP, Roberts GJ, et al. Dental disease, caries related microflora and salivary IgA of children with severe congenital cardiac disease: an epidemiological and oral microbial study. *Pediatr Dentistry*. 1996 May–Jun;18(3):228–35.
23. Dexter F, Macario A, Cowen DS. Staffing and case scheduling for anesthesia in geographically dispersed locations outside of operating rooms. *Curr Opin Anesthesiol*. 2006 Aug;19:453–8. <http://dx.doi.org/10.1097/01.aco.0000236149.90988.7f>
24. Bryson EO, Frost EAM. Anesthesia in remote locations: MRI, CT and beyond. *Int Anesthesiol Clinics*. 2009 Spring;47(2):11–9. <http://dx.doi.org/10.1097/AIA.0b013e3181939b0b>
25. Robbertze R, Posner KL, Domino KB. Closed claims review of anesthesia for procedures outside the operating room. *Curr Opin Anesthesiol*. 2006 Aug;19:436–42. <http://dx.doi.org/10.1097/01.aco.0000236146.46346.fe>

Received: 07-08-2014 Accepted: 04-11-2014