

NOTE

# Herpesvirus-like respiratory infection in African penguins *Spheniscus demersus* admitted to a rehabilitation centre

Nola J. Parsons<sup>1,\*</sup>, Tertius A. Gous<sup>2</sup>, Erna van Wilpe<sup>3</sup>, Venessa Strauss<sup>1</sup>,  
Ralph Eric Thijl Vanstreels<sup>4</sup>

<sup>1</sup>Southern African Foundation for the Conservation of Coastal Birds (SANCCOB), PO Box 11116, Bloubergrant, Cape Town, 7443, South Africa

<sup>2</sup>PO Box 5371, Helderberg, 7135, South Africa

<sup>3</sup>Electron Microscope Unit, Faculty of Veterinary Science, University of Pretoria, Private Bag X04, Onderstepoort 0110, South Africa

<sup>4</sup>Laboratory of Wildlife Comparative Pathology (LAPCOM), University of São Paulo, Avenida Professor Orlando Marques de Paiva, 87, São Paulo, SP 05508-270, Brazil

**ABSTRACT:** Rehabilitation is an important strategy for the conservation of the Endangered African penguin *Spheniscus demersus*, and disease has been raised as a concern in the management of the species, both in the wild and in rehabilitation centres. We report 8 cases of herpesvirus-like respiratory infection in African penguin chicks undergoing rehabilitation between 2010 and 2013 at a facility in Cape Town, South Africa. Infection was confirmed through the identification of viral inclusions in the tracheal epithelium and demonstration of particles consistent with herpesvirus by electron microscopy, whereas virus isolation in eggs, serology and PCR testing failed to detect the virus. Only penguin chicks were affected; they were in poor body condition, and in 2 cases infection occurred prior to admission to the rehabilitation centre. The role played by the herpesvirus-like infection in the overall respiratory disease syndrome is uncertain, due to identification of lesions in only a small proportion of the chicks as well as to the occurrence of other concurrent pathological processes. Further studies are advised to characterise the specific virus involved through the development of sensitive diagnostic methods and to clarify the epidemiology and significance of these infections in wild African penguins.

**KEY WORDS:** Herpesvirales · Laryngotracheitis · Sphenisciformes · South Africa · Conservation

— Resale or republication not permitted without written consent of the publisher —

## INTRODUCTION

Rehabilitation has a beneficial impact on the population of the Endangered African penguin *Spheniscus demersus* (Ryan 2003, Barham et al. 2008, www.iucnredlist.org), although disease has been raised as a concern in the management of the species (Brossy et al. 1999). It is important to do some disease monitoring

of animals admitted for rehabilitation in order to establish the occurrence of particular pathogens within a wild population and to prevent the possibility of introducing new pathogens into a susceptible wild population (OIE 2010). Many pathogens will never be detected in wild penguins due to constraints of sampling, feasibility of laboratory analyses and the difficulty of finding sick or recently deceased birds in the wild.

Herpesviruses are large DNA viruses, and most species have a narrow host range (Hansen 1999, Davison 2002, Kaleta & Docherty 2007). Herpesviruses cause a broad variety of diseases with distinct clinical presentations and lesions in birds (Kaleta 1990, Hansen 1999, Kaleta & Docherty 2007). Many avian herpesviruses have not yet been classified due to lack of gene sequencing information (Kaleta & Docherty 2007, Davison 2010), and this is further complicated by the fact that in many cases concurrent diseases obscure the primary effects of the herpesvirus on the host (Kaleta 1990). Horizontal transmission of herpesviruses can occur through inhalation of viral particles and is the predominant method of transmission (Kaleta & Docherty 2007). Concomitant infections, environmental factors and stress often contribute to morbidity and mortality of infections (Davison 2002, Kaleta & Docherty 2007). As a result, captive wild birds are more likely to have outbreaks than are free-living populations due to the high density and suboptimal environment that are intrinsic to captivity (Kaleta & Docherty 2007).

Little is known on the prevalence and intensity of herpesvirus infections in wild birds (Kaleta & Docherty 2007). There is only 1 record of a herpesvirus-like infection in penguins, namely *S. demersus* from a zoo in the USA (Kincaid et al. 1988). Serological surveys in wild penguin populations have not reported evidence of herpesviruses while testing for either gallid herpesvirus 1 (GaHV-1 or infectious laryngotracheitis virus) or gallid herpesvirus 2 (Marek's disease virus), both of which infect predominantly galliform birds (Clarke & Kerry 1993, Karesh et al. 1999, Duignan 2001, Miller et al. 2001, Travis et al. 2006, Smith et al. 2008, Barbosa & Palacios 2009). Lesions suggestive of herpesvirus have also not been recorded in studies on mortality of wild penguins (Crockett & Kearns 1975, Obendorf & McColl 1980, Gill & Darby 1993, Keymer et al. 2001, Uhart et al. 2004).

Here we report a herpesvirus-like infection diagnosed in African penguins admitted to a rehabilitation centre in South Africa.

## MATERIALS AND METHODS

Oiled, sick and injured marine and coastal birds and abandoned chicks are frequently recovered and sent to the Southern African Foundation for the Conservation of Coastal Birds (SANCCOB) for rehabilitation back into the wild (Parsons & Underhill 2005). Here we consider data from African penguins ad-

mitted to the Table View facility (33° 50' 02" S, 18° 29' 29" E) in the Western Cape, South Africa, between 2010 and 2013. All African penguins undergo rehabilitation following standardised protocols (Parsons & Underhill 2005, Sherley et al. 2014).

The following data were collected: individual number, date and location of capture, chick stage at admission on a scale from P0 (newly hatched) to P4 (close to Fledging) (Sherley et al. 2014), outcome of rehabilitation (release to the wild, death, euthanasia), body mass on admission (floor-standing scale with precision  $\pm 20$  g) and head length on admission (measured with a Vernier calliper from the back of the head to the tip of the beak). A body condition index was calculated using a modified Veen index method (BCI4) that uses the head and mass measurements (Lubbe et al. 2014).

Whenever possible, birds deceased during rehabilitation were subjected to necropsy (Hocken 2002) to evaluate gross lesions and to establish cause of death. For histological examination, samples were collected from multiple organs and preserved in 10% buffered formalin. For bacterial culture, a swab or fragment of organ to be cultured was placed in a sterile transport medium and refrigerated (4°C). For viral culture, samples of organs were placed in a sterile container (no viral transport medium was used) and refrigerated (4°C). All sampling procedures for bacterial and viral cultures were conducted aseptically and with sterilised instruments.

An additional sampling effort was conducted in 2010. Serum samples were obtained from 37 apparently healthy, wild, adult African penguins at the Stony Point (34° 21' 56" S, 18° 54' 08" E) and Dyer Island (34° 40' 58" S, 19° 25' 03" E) colonies in August 2010. Additionally, tracheal swabs and serum samples were obtained from 36 African penguin chicks admitted for hand-rearing at SANCCOB from the same colonies between October and December 2010. Serum samples were frozen ( $-20^{\circ}\text{C}$ ). Swabs were preserved in phosphate-buffered saline and refrigerated (4°C).

Bacteriological and virological tests were performed at the Provincial Veterinary Laboratory at Stellenbosch. The samples submitted for bacteriology were routinely inoculated on Columbia blood agar with 5% sheep blood (CBA; Oxoid), MacConkey agar (McC; Oxoid) and Rappaport-Vassiladis medium (RV; Oxoid). The CBA was incubated overnight at 37°C in 5% CO<sub>2</sub>, the McC at 37°C in normal air and the RV at 42°C in normal air. The next day, the CBA and McC plates were examined, any significant growth was identified or sub-cultured,

and the CBA plates and subcultures were re-incubated. After about 20 h of incubation, the RV was plated onto xylose lysine deoxycolate medium (XLD; Oxoid), and this was incubated overnight at 37°C in normal air. On the following day, the XLD was examined for *Salmonella* sp. CBA plates were incubated for another 48 h and checked for additional growth every 24 h. Any subcultures were identified by means of morphological and biochemical characteristics (Holt 1994, Quinn et al. 2008).

For virology, tracheal samples were ground with sterile mortar and pestle, mixed with virus transport medium (buffered lactose peptone medium, sterilised through filtration with added gentamycin sulphate and amphotericin B) and centrifuged at 1200 × *g* (10 min); the supernatant was used as the inoculum. Chicken eggs from hens testing negative for antibodies to Newcastle disease virus, avian influenza virus, infectious bronchitis virus and infectious laryngotracheitis virus were used for the inoculation. The eggs were incubated at 35–38°C, candled on Day 10 to check viability and, if suitable, inoculated in a safety cabinet and replaced in the incubator. All samples were inoculated using the allantoic sac and chorio-allantoic routes with 5 eggs per passage and route. Both samples went through 1 passage (incubation period of 7–8 d) using the allantoic sac route and 5–6 passages (incubation period of 6–8 d) using the chorio-allantoic route. Egg deaths and pathology were recorded and evaluated (Purchase et al. 1989).

Formalin-fixed tissue was embedded in paraffin wax, sectioned at 5 µm, stained with haematoxylin and eosin and examined under light microscopy. Wax-embedded tissue from 1 case was prepared for transmission electron microscopy using standard techniques (Van den Bergh Weerman & Dingemans 1984) and examined in a Philips CM 10 transmission electron microscope (FEI) operated at 80 kV. Areas with intra-nuclear inclusions seen with light microscopy were marked on the slide and correlated with the areas in the wax block processed for electron microscopy.

All serum samples were sent to Agrilabs Pioneerfoods Pty Ltd (Malmesbury, South Africa) for an indirect enzyme-linked immunosorbent assay (ELISA) targeting antibodies against GaHV-1 (Poultry Immunoassays Infectious Laryngotracheitis Antibody Test Kit – CK124, BioCheck).

Tracheal swabs were sent to Molecular Diagnostic Services Pty Ltd (Durban, South Africa). Samples were subjected to basic Chelex extraction for DNA isolation. A PCR targeting a 1.1 kb *Bam*HI restriction

enzyme fragment of GaHV-1 was performed following the protocol provided by Alexander & Nagy (1997); positive and negative controls were used in each batch as well as the amplification of a house-keeping gene to monitor for sample quality and the presence of PCR inhibitors. Nineteen of these samples were also subjected to a PCR test targeting the DNA polymerase gene of large DNA viruses (LDVs) following the protocols provided by Hanson et al. (2006). In addition, a tracheal swab collected on post-mortem examination from a chick of which subsequent histopathology was suggestive for herpesvirus, was also subjected to PCR testing for GaHV-1 and LDV.

## RESULTS

Between 2011 and 2013, a total of 797 African penguins (of which 554 were chicks) died or were euthanised during rehabilitation; of these, 680 (460 chicks) were necropsied (approximately 85% of deaths) and 122 (109 chicks) were examined with histopathology (approximately 15% of deaths). Unfortunately, histopathology records were incomplete in 2010 and therefore this year could not be included in the analysis. Of the chicks that died between 2010 and 2013, approximately 40% were assigned to a general diagnosis of respiratory disease, but an aetiological agent was not determined in approximately 70% of these cases.

Lesions consistent with herpesvirus infections were identified through histopathology in 8 African penguins (Table 1). The cases were all large downy chicks or those mostly covered with fledging plumage (>36 d old; Sherley et al. 2014). Body condition of these chicks was poor (less than Mean – SD) or mediocre (within Mean ± SD) in relation to all chicks admitted to the centre during the same period. In all 8 cases, the values were less than Mean – SD of the parent-reared chicks on Robben Island that fledged in 2004 (the data on which the body condition index was formulated; Lubbe et al. 2014). Gross lesions in these 8 cases were varied, with most cases showing some degree of airsacculitis and pneumonia. Severe lesions showed considerable caseous plaques of up to 1 cm thick in airways affecting multiple airsacs. Lungs were congested, oedematous and firm.

Histological lesions consistent with herpesvirus infection were seen in all 8 cases. The lesions consisted of segmental and multifocal necrosis of the tracheal epithelium and sloughing of respiratory epithelial cells. Many of the affected epithelial cells contained large eosinophilic to basophilic intra-

Table 1. Clinical history and necropsy results of African penguin *Spheniscus demersus* chicks with lesions consistent with herpesvirus on histopathology. Stony Point is at 34° 21' 56" S, 18° 54' 8" E, Robben Island is at 33° 21' 56" S, 18° 21' 58" E, Dyer Island is at 34° 40' 58" S, 19° 25' 3" E; BCI: body condition index (calculated following Lubbe et al. 2014); EM: electron microscopy; nt: not tested; ni: virus not isolated

Case no.	Capture location	Admission date	Death date	Duration in care (d)	Stage	Clinical findings (on admission)		Gross pathology	Necropsy findings				
						Body mass (g)	BCI		Signs	Preliminary diagnosis	Bacteriology	Virology	EM
1	Stony Point	16 Nov 10	26 Nov 10	10	P3	2200	0.21	Regurgitation, lethargy	Severe airsaccultitis, pericarditis, congestion	Multiple infection	<i>Escherichia coli</i>	nt	nt
2	Stony Point	16 Nov 10	26 Nov 10	10	P3	1980	0.04	Anorexia	Severe airsaccultitis, pericarditis, congestion	Multiple infection	<i>Actinobacillus</i> sp.	nt	nt
3	Stony Point	5 Dec 10	15 Dec 10	10	P4	1060	-0.6	Lethargy	Emaciation, anaemia, moderate airsaccultitis, aspiration pneumonia, pericarditis, bursitis	Aspiration pneumonia	nt	ni	nt
4	Stony Point	25 Dec 10	25 Dec 10	<0.5	P4	780	-1.11	Lethargy	Emaciation, anaemia, blood in trachea, splenic congestion	Emaciation	nt	ni	Herpesvirus
5	Robben Island	6 Jul 11	9 Jul 11	3	P4	980	-1.02	None	Emaciation, anaemia, severe airsaccultitis, lung and splenic congestion	Airsaccultitis, pneumonia	nt	nt	nt
6	Stony Point	7 Nov 11	24 Nov 11	17	P3	1780	0.00	Regurgitation, laboured breathing	Mild airsaccultitis, congestion	Pneumonia, septicaemia	nt	nt	nt
7	Dyer Island	1 Dec 11	2 Dec 11	1	P4	1100	-1.23	Lethargy, laboured breathing	Emaciation, anaemia, moderate airsaccultitis, aspiration pneumonia, congestion	Aspiration pneumonia	nt	nt	nt
8	Dyer Island	1 Dec 11	1 Dec 11	<0.5	P4	1020	-0.89	None	Emaciation, anaemia	Emaciation	nt	nt	nt

nuclear inclusion bodies resembling herpesvirus inclusions (Fig. 1). Sloughed cells often formed syncytia that occurred in rafts in the lumen. In some areas, the epithelium was completely absent or there was a single layer of squamous epithelium visible, with only the lamina propria remaining. The inflammatory reaction in the lamina propria was generally mild and consisted of lymphocytes and plasma cells, with smaller numbers of heterophils. Small numbers of bacilli-form bacteria were occasionally visible in the necrotic exudate or attached to the epithelium, indicating a secondary bacterial infection.

Other histological lesions seen in the 8 cases were severe, acute, multifocal, necrotic bronchitis; severe, acute to sub-acute, multifocal, necrogranulomatous, bacterial pneumonia; severe, acute, focally extensive, fibrinopurulent, foreign body pneumonia; moderate, diffuse, sub-acute, lymphoplasmacytic pericarditis; acute segmental, necrotic, bacterial enteritis and suspected septicaemia. Although the viral tracheitis lesions in all cases were severe, it was not possible to always determine whether these were primary or secondary lesions, and cause of death may have been from multiple factors including emaciation, viral infection and bacterial infection. In 2 cases, the cause of death was determined to be aspiration pneumonia.

Electron microscopy of 1 case revealed numerous nuclear and cytoplasmic virus particles in the tracheal ciliated epithelial cells. Hexagonal intranuclear nucleocapsids of medium electron density (90 nm in diameter, n = 40) were seen (Fig. 2). Viral capsids with electron-dense cores surrounded by a tegument and an outer envelope (120 nm in diameter, n = 40), acquired when budding through the nuclear membrane, were present in the cytoplasm and at the surfaces of cells. These features are consistent with herpesvirus particles (Doane & Anderson 1987, Granzow et al. 2001).

ELISA tests did not detect antibodies against GaHV-1 in the sera of adult wild penguins and chicks admitted for reha-



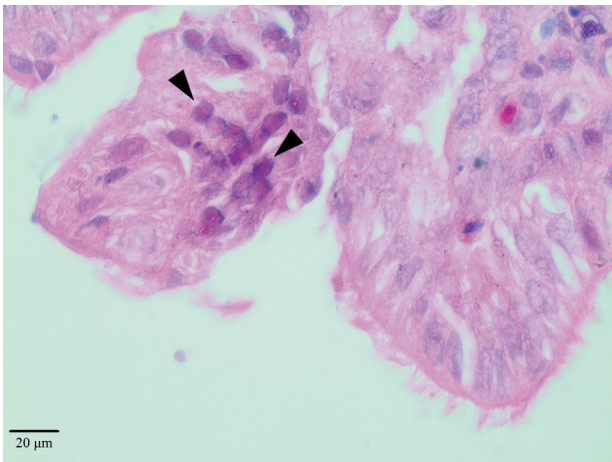


Fig. 1. Intranuclear inclusion bodies (arrowheads) consistent with a herpesvirus infection in the respiratory epithelial cells of the trachea of *Spheniscus demersus* (haematoxylin-eosin stain, 1000×)

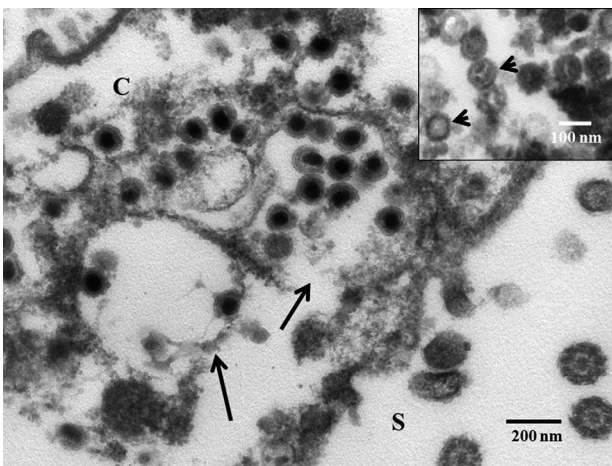


Fig. 2. Transmission electron microscopy of herpesvirus-like infected cells in *Spheniscus demersus*. Enveloped mature virions displaying capsids with electron-dense cores, surrounded by a tegument and outer envelopes in the cytoplasm (C). Note virions in probable cell surface (S) invaginations or cytoplasmic vacuoles (arrows). Inset: Intranuclear icosahedral nucleocapsids with hexagonal outlines (arrowheads)

bilitation in 2010. The PCR tests targeting GaHV-1 and LDV in swabs from penguin chicks in 2010 were all negative, including the sample that was suggestive of herpesvirus.

## DISCUSSION

Based on the characteristics of the viral inclusions in the tracheal epithelium and the presence of particles morphologically consistent with herpesvirus on

electron microscopy, we conclude that the penguins studied were infected by a herpesvirus-like pathogen. However, because viral isolation in chicken eggs was unsuccessful and all PCR tests were negative, we were unable to obtain gene sequences that would allow further identification of the virus involved.

To our knowledge, the only herpesvirus-like infection recorded in any penguin species was a herpesvirus-like infection in African penguins at a North American zoo (Kincaid et al. 1988). In that case, 3 penguins died, presenting with clinical signs and necropsy lesions similar to those observed in our study. Two penguins showed intranuclear inclusion bodies in respiratory epithelial cells suggestive of herpesvirus infection, and 1 showed polyhedral viral particles on electron microscopy (Kincaid et al. 1988). The histological lesions closely resemble those observed in infectious laryngotracheitis (caused by GaHV-1) in chickens and in Pacheco's disease (caused by the psittacid herpesvirus 1) in psittacine birds (Kincaid et al. 1988, Bagust et al. 2000, Kaleta & Docherty 2007). In our study, in 2 cases, death occurred within 12 h of admission. In other avian respiratory herpesviruses, the inclusion bodies take longer to develop in cell culture (Reynolds et al. 1968, Prideaux et al. 1992), hence we consider this as evidence that infection occurred in the wild.

Our failure to isolate the virus in chicken embryos suggests that either viable virus particles were not present in sufficient quantity, which is unlikely based on the abundance of viral inclusions observed in histopathology, or that the virus could not grow in the chicken embryo tissue. It is possible that virus isolation would be more successful if African penguin embryos were inoculated; however, this is unlikely to be actioned since African penguins are an Endangered species.

The detection of serum antibodies is possible for all herpesviruses and confirms previous exposure or vaccination, although negative results should be interpreted with caution (Kaleta & Docherty 2007). Our results suggest that it may not be valuable using ELISA targeting GaHV-1 to test penguin samples as was done in previous studies on wild penguins. Herpesvirus-like infection was identified only in a small proportion of the chicks that died; however, diagnosis based on histopathology and electron microscopy has low sensitivity compared to PCR and virus isolation methods (Williams et al. 1994).

The role that the herpesvirus-like infection played as a cause of respiratory disease in the studied cases is uncertain. All cases with herpesvirus-like lesions

also showed other significant pathological processes that contributed to mortality. However, because of the significant tracheal epithelium lesions, it is probable that the herpesvirus-like pathogen was important in the development of respiratory disease in these 8 cases. This is not dissimilar to other avian respiratory herpesviruses, in which lethality is often due to secondary complications, such as bacterial respiratory infections (Bagust et al. 2000, Kaleta & Docherty 2007).

More research is needed to determine the significance of herpesvirus-like infection in hand-rearing African penguin chicks showing symptoms of respiratory disease as well as the prevalence in the wild population. These studies, however, will require the development of effective and reliable diagnostic tools for the detection and characterisation of this pathogen.

*Acknowledgements.* The Western Cape Provincial Veterinary Laboratory, Stellenbosch, prepared all histological slides and performed the bacterial and viral cultures. Magdeline Dreyer, Belinda Peyrot and Annelize Jonker were very helpful in the preparation of the manuscript. Dave Allright gave valuable advice when the first diagnosis was made. Lauren Waller and Kevin Shaw from CapeNature and Rob Crawford from the Department of Environmental Affairs were very supportive during the decision-making process in 2010. This research was supported by the Sea Research Foundation (Mystic Aquarium), the Georgia Aquarium and the Leiden Conservation Foundation. In addition, the African Penguin Chick Bolstering Project is a collaboration between SANCCOB, Bristol Conservation and Science Foundation, Department of Environmental Affairs (Oceans and Coasts), Animal Demography Unit (University of Cape Town), CapeNature and Robben Island Museum, with global support from zoos, aquaria and other funding bodies.

#### LITERATURE CITED

- Alexander HS, Nagy E (1997) Polymerase chain reaction to detect infectious laryngotracheitis virus in conjunctival swabs from experimentally infected chickens. *Avian Dis* 41:646–653
- Bagust TJ, Jones RC, Guy JS (2000) Avian infectious laryngotracheitis. *Rev Sci Tech Off Int Epizoot* 19:483–492
- Barbosa A, Palacios MJ (2009) Health of Antarctic birds: a review of their parasites, pathogens and diseases. *Polar Biol* 32:1095–1115
- Barham PJ, Underhill LG, Crawford RJM, Altwegg R and others (2008) The efficacy of hand-rearing penguin chicks: evidence from African penguins (*Spheniscus demersus*) orphaned in the *Treasure* oil spill in 2000. *Bird Conserv Int* 18:144–152
- Brossy JJ, Pl s AL, Blackbeard JM, Kline A (1999) Diseases acquired by captive penguins: What happens when they are released into the wild? *Mar Ornithol* 27:185–186
- Clarke J, Kerry K (1993) Diseases and parasites of penguins. *Korean J Polar Res* 4:79–96
- Crockett DE, Kearns MP (1975) Northern little blue penguin mortality in Northland. *Notornis* 22:69–72
- Davison AJ (2002) Evolution of the herpesviruses. *Vet Microbiol* 86:69–88
- Davison AJ (2010) Herpesvirus systematics. *Vet Microbiol* 143:52–69
- Doane FW, Anderson N (1987) Herpesviridae. In: Doane FW, Anderson N (eds) *Electron microscopy in diagnostic virology. A practical guide and atlas*. Cambridge University Press, New York, NY, p 75–83
- Duignan PJ (2001) Diseases of penguins. *Surveillance* 28: 5–11
- Gill JM, Darby JT (1993) Deaths in yellow-eyed penguins (*Megadyptes antipodes*) on the Otago Peninsula during the summer of 1990. *NZ Vet J* 41:39–42
- Granzow H, Klupp BG, Fuchs W, Veits J, Osterrieder N (2001) Egress of Alphaherpesviruses: comparative ultrastructural study. *J Virol* 75:3675–3684
- Hansen W (1999) Miscellaneous herpesviruses of birds. In: Friend M, Fransen JC (eds) *Field manual of wildlife diseases. General field procedures and diseases of birds*. United States Geological Survey, Biological Resources Division, Madison, WI, p 157–161
- Hanson LA, Rudis MR, Vasquez-Lee M, Montgomery RD (2006) A broadly applicable method to characterize large DNA viruses and adenoviruses based on the DNA polymerase gene. *Virology* 3:28
- Hocken AG (2002) Post-mortem examination of penguins. DOC Science Internal Series 65. New Zealand Department of Conservation, Wellington
- Holt JG (1994) *Bergey's manual of determinative bacteriology*, 9<sup>th</sup> edn. Williams and Wilkins, Baltimore, MD
- Kaleta EF (1990) Herpesviruses of birds—a review. *Avian Pathol* 19:193–211
- Kaleta EF, Docherty DE (2007) Avian herpesviruses. In: Thomas NJ, Hunter B, Atkinson CT (eds) *Infectious diseases of wild birds*. Blackwell Publishing, Oxford, p 63–107
- Karesh WB, Uhart MM, Frere E, Gandini P, Braselton WE, Puche H, Cook RA (1999) Health evaluation of free-ranging rockhopper penguins (*Eudyptes chrysocomes*) in Argentina. *J Zoo Wildl Med* 30:25–31
- Keymer IF, Malcolm HM, Hunt A, Horsley DT (2001) Health evaluation of penguins (Sphenisciformes) following mortality in the Falklands (South Atlantic). *Dis Aquat Org* 45: 159–169
- Kincaid AL, Bunton TE, Cranfield M (1988) Herpesvirus-like infection in black-footed penguins (*Spheniscus demersus*). *J Wildl Dis* 24:173–175
- Lubbe A, Underhill LG, Waller LJ, Veen J (2014) A condition index for African penguin *Spheniscus demersus* chicks. *Afr J Mar Sci* 36:143–154
- Miller GD, Hofkin BV, Snell H, Hahn A, Miller RD (2001) Avian malaria and Marek's disease: potential threats to Galápagos penguins *Spheniscus mendiculus*. *Mar Ornithol* 29:43–46
- Obendorf DL, McColl K (1980) Mortality in little penguins (*Eudyptula minor*) along the coast of Victoria, Australia. *J Wildl Dis* 16:251–259
- OIE (World Organisation for Animal Health) (2010) *Training manual on wildlife diseases and surveillance – workshop for OIE National Focal Points for Wildlife*. OIE, Paris
- Parsons NJ, Underhill LG (2005) Oiled and injured African penguins *Spheniscus demersus* and other seabirds admitted for rehabilitation in the Western Cape, South

- Africa, 2001 and 2002. *Afr J Mar Sci* 27:289–296
- Prideaux CT, Kongsuwan K, Johnson MA, Sheppard M, Fahey KJ (1992) Infectious laryngotracheitis virus growth, DNA replication, and protein synthesis. *Arch Virol* 123:181–192
  - Purchase HG, Arp LH, Domermuth CH, Pearson JE (1989) A laboratory manual for the isolation and identification of avian pathogens, 3<sup>rd</sup> edn. American Association of Avian Pathologists, Philadelphia, PA
  - Quinn PJ, Markey BK, Leonard FC, FitzPatrick ES, Fanning S, Hartigan PJ (2008) *Veterinary microbiology and microbial disease*. Wiley-Blackwell, Oxford
  - Reynolds HA, Watrach AM, Hanson LE (1968) Development of the nuclear inclusion bodies of infectious laryngotracheitis. *Avian Dis* 12:332–347
  - Ryan PG (2003) Estimating the demographic benefits of rehabilitating oiled African penguins. In: Nel DC, Whittington PA (eds) *Rehabilitation of oiled African penguins: a conservation success story*. BirdLife South Africa and the Avian Demography Unit, Cape Town, p 25–29
  - Sherley RB, Waller LJ, Strauss V, Geldenhuys D, Underhill LG, Parsons NJ (2014) Hand-rearing, release and survival of African penguin chicks abandoned before independence by moulting parents. *PLoS ONE* 9:e110794
  - Smith KM, Karesh WB, Majluf P, Paredes R and others (2008) Health evaluation of free-ranging Humboldt penguins (*Spheniscus humboldti*) in Peru. *Avian Dis* 52: 130–135
  - Travis EK, Vargas FH, Merkel J, Gottdenker N, Miller RE, Parker PG (2006) Hematology, serum chemistry, and serology of Galápagos penguins (*Spheniscus mendiculus*) in the Galápagos Islands, Ecuador. *J Wildl Dis* 42: 625–632
  - Uhart M, Karesh W, Cook R, Huin N and others (2004) Paralytic shellfish poisoning in Gentoo penguins (*Pygoscelis papua*) from the Falkland (Malvinas) Islands. *Proceedings of the American Association of Zoo Veterinarians, American Association of Wildlife Veterinarians, Wildlife Disease Association joint conference*, San Diego, CA, p 477–482
  - Van den Bergh Weerman MA, Dingemans KP (1984) Rapid deparaffinization for electron microscopy. *Ultrastruct Pathol* 7:55–57
  - Williams RA, Savage CE, Jones RC (1994) A comparison of direct electron microscopy, virus isolation and a DNA amplification method for the detection of avian infectious laryngotracheitis virus in field material. *Avian Pathol* 23: 709–720

*Editorial responsibility: Alex Hyatt,  
Geelong, Victoria, Australia*

*Submitted: January 29, 2015; Accepted: July 19, 2015  
Proofs received from author(s): September 9, 2015*