

Hand-foot-and-mouth disease caused by coxsackievirus A6 in a patient infected with HIV

Simnikiwe Mayaphi, Walda van Zyl, Tinah Sono, Donovan Loots, Maureen Taylor

Simnikiwe Mayaphi,^{1,2} Walda van Zyl,¹ Tinah Sono,³ Donovan Loots,³ Maureen Taylor¹

¹Department of Medical Virology, University of Pretoria, Pretoria, South Africa

²National Health Laboratory Service Tshwane Academic Division, Pretoria, South Africa

³HIV clinic, Tshwane District Hospital, Pretoria, South Africa

*Corresponding author, email: sim.mayaphi@up.ac.za

Keywords: hand, foot and mouth disease; HFMD; coxsackievirus A6; enterovirus 71; CVA6, EV71; HIV; rash

Hand, foot and mouth disease (HFMD) is common in children ≤ 5 years of age, and is mainly caused by enterovirus 71 and coxsackievirus A16 (CVA6). A 12-year-old boy on treatment for human immunodeficiency virus (HIV) presented to an HIV clinic with fever and a rash on the palms and soles. The syphilis test were negative. Enterovirus was identified from a stool sample by PCR and characterised as as coxsackievirus A6(CVA6). The patient completely recovered a week later. CVA6 has recently been associated with HFMD. This case highlights the significance of the laboratory confirmation of suspected HFMD cases and phylogenetic analysis of the identified virus.

Peer reviewed. (Submitted: 2014-07-25. Accepted: 2014-09-18.) © SAJID

South Afr J Infect Dis 2015;30(2):67-69

Case study

In August 2013, a 12-year-old boy infected with human immunodeficiency virus (HIV), who has been on antiretroviral therapy for more than two years, presented to the Tshwane District Hospital HIV clinic with fever and a rash. His symptoms had started two days ago. The rash was mainly on the palms and soles, and was sometimes itchy. His antiretroviral (ARV) drug regimen consisted of zidovudine, lamivudine and nevirapine. He was no longer receiving prophylaxis for pneumocystis pneumonia at the time of consultation.

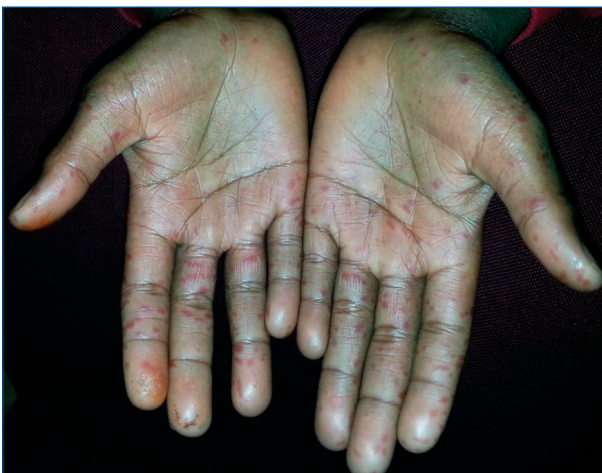

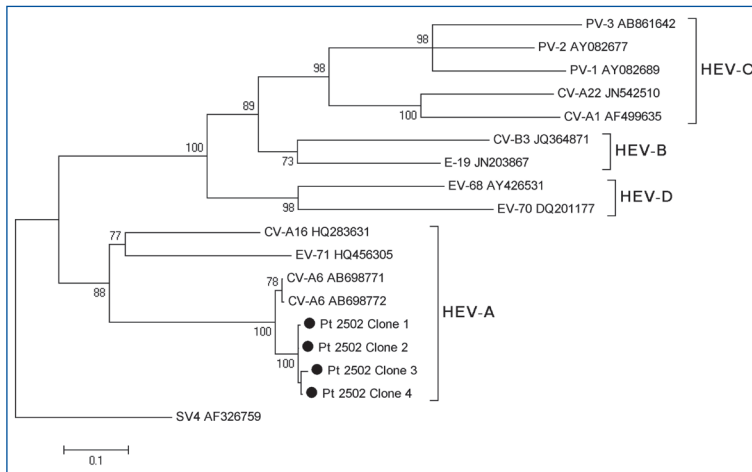
Figure 1: A macular rash on the palms of the patient. A similar rash was also noted on his soles

On examination, he was clinically stable and pyrexial (37.6 °C). The boy had a macular rash on his palms and soles (Figure 1), and a vesicular rash at the right corner of his mouth. There were dark streaks on his palate, and no other lesions. In addition to his ARV drugs, he was also prescribed mupirocin ointment and oral acyclovir. A blood sample for syphilis tests was taken on the day of consultation, and a stool sample was submitted a day later for enterovirus testing.

Blood taken a month before this consultation revealed that the patient's HIV viral load was undetectable, and the CD4 count was 929 cells/ μ l (30.9%). The syphilis tests, rapid plasma reagin and the *Treponema pallidum* haemagglutination assay were all negative. Enterovirus real-time reverse transcription polymerase chain reaction (RT-PCR), carried out on a stool sample, tested positive. A leftover serum sample (after the syphilis testing) tested negative on enterovirus real-time RT-PCR. However, this sample was slightly haemolysed and was tested five days after collection. Nucleotide sequence analysis of the nested enterovirus RT-PCR products from the stool sample showed that the patient was infected with the coxsackievirus A6 (CVA6) strain. At the follow-up visit, the patient and his guardian reported that the rash had disappeared completely without any complications, roughly a week after the consultation.

Method

Ethical approval for this investigation was obtained from the University of Pretoria's Faculty of Health Science Research Ethics committee (protocol number 44/2014). Approval to take photographs of the patient



Reference strains representing all the groups (A–D) of enteroviruses were used

CV: coxsackievirus, E: echovirus, EV: enterovirus, HEV: human enteroviruses, PV: poliovirus, SV: simian virus

Figure 2: Phylogenetic analysis of the patient's isolates (labelled with solid black dots) using partial VP1 gene nucleotide sequences

was granted by the Tshwane District Hospital's superintendent. Written assent and consent to take photographs were also obtained from the patient and his legal guardian, respectively.

An aliquot of 140 µl of a 10% (weight/volume) stool suspension was used for the RNA extraction using the QIAamp® RNA Viral Mini Kit (Qiagen, Hilden, Germany) according to the manufacturer's instructions. The RNA was eluted in 60 µl and stored at –70 °C until use.

The QuantiTect® Probe RT-PCR Kit (Qiagen) was used for the detection of enteroviruses, targeting the 5' noncoding region (NCR) region, in a one-step, real-time RT-PCR assay. The primers and TaqMan® probes, described by Fuhrman et al.,¹ were added to the master mix as follows: primer EV1 and EV2 (5 pmol of each) and probe EV (2 pmol). Five µl of RNA was added to the master mix and the final reaction volume was 20 µl. The RNA was reverse transcribed into cDNA at 50 °C for 45 minutes, which was followed by enzyme activation at 95 °C for 10 minutes. The cDNA was amplified for 50 cycles at 94 °C for 15 seconds, 60 °C for one minute and 65 °C for one minute. The patient's sample tested positive.

Typing of enteroviruses was carried out using conventional nested RT-PCR of the VP1 region, followed by nucleotide sequence analysis, as described by Wolfaardt et al.² The reverse transcription reaction consisted of the following: 1 x reaction buffer (Thermo Scientific, Waltham, USA), 0.5 mM deoxyribonucleotide triphosphates (dNTPs) (Thermo Scientific), 600 pmol random hexamers (Roche Diagnostics GmbH, Mannheim, Germany), 20 units RiboLock® RNase inhibitor (Thermo Scientific), 50 units RevertAid® Premium reverse transcriptase (Thermo Scientific) and 5 µl of RNA. The reaction was incubated at 25 °C for 10 minutes, 50 °C for 60 minutes and 85 °C for 5 minutes.

The first-round and second-round PCRs were performed using the following primers: CICCIGGIGGIAYRWACAT (EV222) and GCIATGYTIGGIACICAYRT (EV224) for the first-round PCR, and TACTGGACCACCTGGNGGNAYRWACAT (AN88) and CCAGCACTGACAGCAGYNGARAYNGG (AN89) for the second-round PCR, as previously described by Nix et al.³ One microlitre of the cDNA was used as a template for the first-round PCR, which consisted of the following: 1 x reaction buffer, 2 mM MgCl₂ (Promega corp, Madison,

USA), 0.2 mM dNTPs (Promega), 50 pmol primer EV 222, 50 pmol primer EV 224 and 1.25 U AmpliTaq® Gold DNA Polymerase (Applied Biosystems, Foster City, USA).

The expected product size of the first-round PCR was 992 base pairs. The first round PCR (1 µl) was used as a template for the nested PCR, which consisted of the following: 1 x reaction buffer, 2 mM MgCl₂ (Promega), 0.2 mM dNTPs (Promega), 40 pmol primer AN88, 40 pmol primer AN89 and 1.25 U AmpliTaq® Gold DNA Polymerase.

The expected product size of the second-round PCR was 375 base pairs. PCR products (10 µl) from both rounds of PCR analysis were analysed on 2% agarose gel under ultraviolet illumination.

The nested PCR products were purified using the DNA Clean & Concentrator™ kit (Zymo Research, Irvine, USA) and eluted in 30 µl. Three microlitres of the product were cloned using the CloneJET® PCR Cloning Kit (Thermo Scientific, Waltham, USA) according to the manufacturer's instructions. Four positive clones were randomly selected for nucleotide sequencing using the ABI PRISM® BigDye Terminator v3.1 Cycle Sequencing Kit (Applied Biosystems) on an ABI automated analyser (Applied Biosystems).

Nucleotide consensus sequences were generated and edited using Sequencher® 4.7. Multiple-sequence alignments were generated using Clustal W in BioEdit® version 7.0.9.0. The sequences from the four clones were compared to the EV sequences in GenBank® using BLAST®. Phylogenetic trees were constructed with the Kimura® 2-parameter model in Molecular Evolutionary Genetics Analysis® version 4 using 1000 bootstrap replicates.

Nucleotide sequencing data were obtained from four clones. All showed 99% identity and were clustered with CVA6 (Figure 2).

Discussion

Enteroviruses belong to a *Picornaviridae* family. The enterovirus genus of this family consists of many viruses, which include coxsackieviruses A and B, echoviruses, polioviruses, rhinoviruses and numbered enteroviruses.⁴ Enteroviruses are mainly transmitted via the faeco-oral route, through consumption of contaminated food and water, direct contact with infected persons, and vertical spread during the intrapartum period.^{5,6} These viruses are shed in high quantities in stools, and can have prolonged shedding of up to 11 weeks in some settings, such as preschool environments.⁵ Immunosuppressive conditions, such as agammaglobulinaemia, can lead to considerably prolonged shedding and disseminated enteroviral infection.⁶ However, this prolonged shedding or increased disease severity has not been noticed in patients infected with HIV.^{7,8}

A wide spectrum of disease is associated with enteroviruses, which can be mild to severe in nature. Some of the diseases associated with enteroviruses include meningitis, encephalitis, common cold, bronchiolitis, conjunctivitis, myocarditis, hepatitis and HFMD.^{4,9} Even though enteroviruses primarily replicate in the gastrointestinal tract,

they rarely cause disease at this site.⁴ Some EVs have a predilection for certain diseases in the body, e.g. polioviruses are mainly associated with acute flaccid paralysis.⁹ However, there is a considerable overlap of the diseases caused by enteroviruses. For instance, enterovirus 71 (EV71) and CVA16, which are commonly associated with HFMD, also cause meningitis,⁴ and EV71 has also emerged as an important cause of polio-like paralysis.⁹

HFMD is a common childhood disease, mainly affecting children aged five years or younger, and is usually associated with EV71 and CVA16.^{10,11} These viruses have been associated with outbreaks of HFMD in many parts of the world,¹¹ which commonly occur in summer and autumn in temperate regions.¹² A literature review has revealed that laboratory confirmation of suspected HFMD outbreaks is not often performed in South Africa.¹³⁻¹⁵

CVA6, a common cause of herpangina,⁴ has recently been associated with HFMD.^{12,16-18} It has been noted to have an atypical presentation with regard to seasonality, affected age group and clinical presentation. This virus is often associated with cases of HFMD in the winter season, in adults or older children, and is commonly associated with onychomadesis.^{12,17} Ehlers et al previously reported on the presence of CVA6 in treated and untreated water supplies in South Africa.¹⁹ The patient in this case study was a teenager who presented with HFMD in winter. The CVA6 strains most closely related to the strain detected in this patient were previously identified in a throat swab from a patient with HFMD in Japan in 2009 (GenBank, AB698771 and AB698772) (Figure 2).

An enteroviral rash can mimic any rash, making the diagnosis of a childhood exanthem difficult. Viral infections, such as measles and rubella, which are associated with childhood exanthems do not cause a rash on the palms and soles.¹⁰ Caution should be exercised when assessing a rash on the palms and soles as a macular rash can appear brighter on these light-skinned parts, and can easily be confused with a petechial rash, which has a different aetiology. Enteroviruses can also cause a vesicular rash.¹⁰ Vesicular lesions at the corner of the mouth, thought to relate to the herpes simplex virus, could have been part of the enteroviral infection in our patient.

Laboratory diagnosis of enteroviruses consists of PCR, cell culture and serology. PCR is commonly used as it has higher sensitivity and a better turnaround time than cell culture. Serology has a limited role in the diagnosis owing to the large number of enterovirus serotypes.⁹ Primers used during PCR target a more conserved region of enteroviruses, thus maximising the chances of detecting all of the different enteroviruses during PCR testing.^{9,20} Vesicular fluid (in the case of a vesicular rash), cerebrospinal fluid, blood, a throat swab and a stool sample should be considered for enterovirus PCR. The advantage of stool testing is that these viruses are shed in high quantities in stools and for a longer period.^{21,22} However, PCR results obtained from stool samples should be interpreted with caution as asymptomatic shedding without disease is possible. The negative enterovirus PCR in the serum could have been due to the poor quality of the serum sample tested (slightly haemolysed and old), or because there was no longer viraemia at the time of testing.

Currently, there are no approved drugs for enteroviruses.⁹ Good sanitation and hygiene, as well as health education, are important aspects in preventing the further spread of enteroviruses during outbreaks.⁵

This case highlights an uncomplicated course of HFMD caused by CVA6 in a patient who was on HIV treatment. This is the first reported case in South Africa in which CVA6 was identified in a patient with HFMD. This underscores the significance of laboratory confirmation of suspected HFMD cases and phylogenetic analysis. The benefit of laboratory diagnosis of an enterovirus is that a correct diagnosis is made, and unnecessary use of antibiotics or antiviral drugs avoided. Correct diagnosis and phylogenetic analysis are also important for epidemiological purposes. More data are needed to understand the prevalence of CVA6 in South Africa and its clinical course in patients who are infected with HIV.

Declaration: This investigation was not funded.

Conflict of interest: There is no conflict of interest to declare.

Acknowledgements: We would like to thank the patient and his family for their willingness to participate in this investigation.

References

- Fuhrman JA, Liang X, Noble RT. Rapid detection of enteroviruses in small volumes of natural waters by real-time quantitative reverse transcriptase PCR. *Appl Environ Microb*. 2005;71(8):4523-4530.
- Wolfaardt M, Büchner A, Myburgh M, et al. Molecular characterisation of enteroviruses and clinical findings from a cluster of paediatric viral meningitis cases in Tshwane, South Africa 2010-2011. *J Clin Virol*. 2014;61(3):400-405.
- Nix WA, Oberste MS, Pallansch MA. Sensitive, semi-nested PCR amplification of VP1 sequences for direct identification of all enterovirus serotypes from original clinical specimens. *J Clin Microbiol*. 2006;44(8):2698-2704.
- Tapparel C, Siegrist F, Petty TJ, Kaiser L. Picornavirus and enterovirus diversity with associated human diseases. *Infect Genet Evol*. 2013;14:282-293.
- Wu P, Huang L, Kao C, et al. An outbreak of coxsackievirus A16 infection: comparison with other enteroviruses in a preschool in Taipei. *J Microbiol Immunol Infect*. 2010;43(4):271-277.
- Abzug MJ. The enteroviruses: problems in need of treatments. *J Infect*. 2014;68 Suppl 1:S108-S114.
- Chakraborty R, Iturriza-Gomara M, Musoke R, et al. An epidemic of enterovirus 71 infection among HIV-1 infected orphans in Nairobi. *AIDS*. 2004;18(14):1968-1969.
- Khetsuriani N, Helfand R, Pallansch M, et al. Limited duration of vaccine poliovirus and other enterovirus excretion among human immunodeficiency virus infected children in Kenya. *BMC Infect Dis*. 2009;9:136.
- Muir P. Enteroviruses. *Medicine*. 2014;42(1):57-59.
- Bryant PA, Sharland M. Acute childhood exanthems. *Medicine*. 2009;37(12):686-690.
- He S, Han J, Ding X, et al. Characterization of enterovirus 71 and coxsackievirus A16 isolated in hand, foot, and mouth disease patients in Guangdong, 2010. *Int J Infect Dis*. 2013;17(11):e1025-e1030.
- Ben-Chetrit E, Wiener-Well Y, Shulman LM, et al. Coxsackievirus A6-related hand foot and mouth disease: skin manifestations in a cluster of adult patients. *J Clin Virol*. 2014;59(3):201-203.
- National Institute for Communicable Diseases. Hand, foot and mouth disease. *Communicable Diseases Communiqué*. 2006;5(11):1-3.
- Hand, foot and mouth disease. National Institute for Communicable Diseases [homepage on the Internet]. c2009. Available from: http://www.nicd.ac.za/assets/files/NICDCommMar09Vol08_03.pdf
- Hand, foot and mouth disease outbreak. National Institute for Communicable Diseases [homepage on the Internet]. c2009. Available from: http://www.nicd.ac.za/assets/files/NICDCommJune09Vol08_06.pdf
- Blomqvist S, Klemola P, Kaijalainen S, et al. Co-circulation of coxsackieviruses A6 and A10 in hand, foot and mouth disease outbreak in Finland. *J Clin Virol*. 2010;48(1):49-54.
- Feder Jr HM, Bennett N, Modlin JF. Atypical hand, foot, and mouth disease: a vesiculobullous eruption caused by Coxsackie virus A6. *Lancet Infect Dis*. 2014;14(1):83-86.
- Hayman R, Shepherd M, Tarring C, Best E. Outbreak of variant hand-foot-and-mouth disease caused by coxsackievirus A6 in Auckland, New Zealand. *J Paediatr Child Health*. 2014;50(10):751-755.
- Ehlers MM, Grabow WOK, Pavlov DN. Detection of enteroviruses in untreated and treated drinking water supplies in South Africa. *Water Res*. 2005;39(11):2253-2258.
- Ge S, Yan Q, He S, et al. Specific primer amplification of the VP1 region directed by 5' UTR sequence analysis: enterovirus testing and identification in clinical samples from hand-foot-and-mouth disease patients. *J Virol Methods*. 2013;193(2):463-469.
- Bolanaki E, Kottaridi C, Dedepsidis E, et al. Direct extraction and molecular characterization of enteroviruses genomes from human faecal samples. *Mol Cell Probes*. 2008;22(3):156-161.
- Solomon T, Lewthwaite P, Perera D, et al. Irology, epidemiology, pathogenesis, and control of enterovirus 71. *Lancet Infect Dis*. 2010;10(11):778-790.