

A comparison of the leaf gel extracts of *Aloe ferox* and *Aloe vera* in the topical treatment of atopic dermatitis in Balb/c mice

M. J. Finberg¹ ; G. L. Muntingh¹ ; C. E. J. van Rensburg^{2*}

* C. E. J. van Rensburg
connie.medlen@up.ac.za

¹Department of Pharmacology, School of Medicine, Faculty of Health Science, University of Pretoria, Private Bag X323, Arcadia, Pretoria 0007, South Africa

²Office of the Dean, Faculty of Health Science, University of Pretoria, Private Bag X323, Arcadia, Pretoria 0007, South Africa

Abstract *Aloe vera* gel is widely used in the treatment of an array of disturbances, especially skin disorders. The wound-healing effects have been attributed to its moisturizing and anti-inflammatory effects as well as its beneficial effect on the maturation of collagen. The aim of the present study is to compare the effects of topically applied extracts of *Aloe ferox* with that of *Aloe vera* on the symptoms as well as IgE levels of a mouse model of atopic dermatitis (AD). Mice were sensitized and challenged with 2,4-dinitrochlorobenzene and treated afterwards for 10 consecutive days with the gels of either *A. ferox* or *A. vera* applied topically to the affected areas. A placebo gel was used for the control mice. Blood was collected at the beginning and end of the treatment period to measure serum IgE levels. Although the gels of both the *Aloe* species inhibited the cutaneous inflammatory response as well as serum IgE levels in the rats, the extracts of *A. ferox* were superior to that of *A. vera* in reducing IgE levels. The gels of *A. ferox* and *A. vera*, applied topically, may be a safe and useful alternative to antihistamines and topical corticosteroids, for the treatment of patients suffering from recurring chronic AD.

Keywords Atopic dermatitis · Topical treatment · *Aloe ferox* · *Aloe vera*

Introduction

Atopic dermatitis (AD) is a chronic relapsing cutaneous disease characterized by dry and scaly skin, inflammation, and intense itching (Ellis et al. 2003). It affects up to 20 % of children in developed countries (Ashcroft 2005). A worldwide increase in the incidence of atopic diseases has been documented as far back as 1999 (Beltrani 1999). AD is associated with early IgE (immunoglobulin E) production and allergen/IgE reactivity and is characterized with itching, inflammation, and an exudation (Ellis et al. 2003). It has been suggested that there is a link between atopic dermatitis, asthma and allergic rhinitis (Ellis et al. 2003). Current topical and systemic treatments for AD are reasonably effective but are associated with inconvenient side effects. The first-line treatments for the symptoms of AD are antihistamines and topical corticosteroids. However, antihistamines are associated with various side effects, the most serious of which is their sedative potential (Kay 2000). Topical corticosteroids, on the other hand, are associated with side effects such as atrophy, rosacea, acne, purpura, hyperglycaemia, glaucoma, perioral dermatitis and purpura (Arellano et al. 2007; Henge et al. 2006). Systemic application of corticosteroids is effective in relieving the symptoms of AD but can only be administered once or twice annually because of long-term side effects such as osteopenia and cataracts (Sidbury and Hanifin 2000). There is therefore an urgent need for the development of effective but safer treatments for atopic dermatitis.

The genus *Aloe* is used traditionally for the treatment of an array of disturbances ranging from anorexia, dyspepsia, constipation and diseases of the liver, hypochondria and mania (Capasso et al. 1998). It is a tropical/subtropical plant and has been used in the cosmetic as well as

pharmaceutical industry for skin disorders such as wounds and radiation damage and as moisturizing and antiseptic agent for many years (Eshun and He 2004). The clinical use of the gel began in the 1930s, with reports of successful treatment of X-ray and radium burns, which led to further experimental studies using laboratory animals in the following decades. Kim et al. (2010) compared the effects of oral extracts of *Scutellariae radix* and *Aloe vera* on AD-induced NC/Nga mice. Both these treatments suppressed IL-5 and IL-10 levels in mice. On the other hand, the extracts of *A. vera* caused an increase in IgE levels.

Aloe ferox is indigenous to South Africa. The medicinal properties of *A. ferox* have been extensively reviewed by Chen et al. (2012) and Eshun and He (2004). It has been described as an anti-oxidant with anti-inflammatory, anti-fungal, anti-cancer, anti-bacterial, anti-malarial and wound-healing properties (Reynolds and Dweck 1999). The inner leaf pulp or leaf gel contains polysaccharides and various phenolic phytochemicals such as alkaloids, coumarins, anthrones, and phenolic phytochemicals (Cock 2015). It is used as an oral treatment for infections, inflammation, cancer and malaria as well as topically applied for skin ailments. The extracts contain carboxypeptidase, bradykinase and aloeresin-I, all of which have been shown to relieve pain and decrease inflammation and swelling (Duke 1997). The leaves and roots have been applied topically to treat dermatitis and eczema as well as skin cancer, psoriasis and burns. The wound-healing effects have been attributed to its moisturizing and anti-inflammatory effects as well as its beneficial effect on the maturation of collagen (Chen et al. 2012).

Kim et al. (2010) studied the effects of extracts of *A. ferox* and *S. radix*, applied systemically, on AD mice. Although both these extracts had no effect on the symptoms of the disease, extracts of *A. ferox* caused an increase in serum IgE levels and a decrease in IL-5 and IL-10 levels.

Up till now, no research has been done to determine the effects of the gels of *A. vera* and *A. ferox*, applied topically, on AD. In this study, AD was induced in mice with the topical application of 2,4 dinitrofluorobenzene (DNFB) on their right ears after which they were treated topically with either a placebo gel or with the gels of either *A. vera* or *A. ferox*. These products are on the market as topical treatment for skin diseases.

Materials

A 97 % *A. ferox* gel and a placebo gel were supplied by Alcare Aloe, 39 Industrial Avenue, Albertinia, Western Cape, South Africa, and *A. vera* gel was purchased from PharmaNatura, Wynberg, South Africa containing 96 %

pure extract. Both products were used at the dosages that are presently on the market.

Both products were dissolved in a small volume of acetone and made up to a concentration of 0.25 % in sesame oil. This dilution was decided on as mice could be more sensitive to treatment than human beings. Male BALB/c mice weighing between 20 and 40 g were obtained at 4 weeks of age from the Centre of Animal Services at the University of the Witwatersrand, Johannesburg.

Methods

This study was done as a double-blind, randomized, parallel-group comparative study over a 15-day treatment period. All mice were coded.

Scientific procedures were strictly adhered to according to the Code of Practice for the Housing and Care of Animals (Acts 1986 and 1989, respectively). Approval was obtained from the Animal Use and Care Committee (animal ethics committee) of the University of Pretoria, South Africa. The mice were housed in plastic containers, 5 per cage, at the University of Pretoria's Biomedical Research Centre in a controlled environment with a temperature and humidity of 23 ± 2 °C and 55 ± 5 %, respectively, under 12-h light/dark cycles. They were fed a conventional rodent diet obtained from Epol (Pty) Ltd (Randburg, South Africa) and had an unlimited supply of drinking water. They were allowed to acclimatize for 1 week.

This study was done as a double-blind, randomized, parallel-group comparative study over a 15-day treatment period. All mice were coded. To induce atopic dermatitis-like skin lesions, a method described by Lee et al. (2007) was followed.

For this study 60 BALB/c mice were coded and sensitized. Sensitization was done by spreading a 20- μ l application of 2,4 dinitrofluorobenzene (DNFB) (purchased from Tocris Japan), dissolved in a small volume of acetone and made up to a concentration of 0.25 % in sesame oil over the right ears of the mice. At the same time 20 μ l of sesame oil was applied in the same manner to the left ears of the mice. They were then divided into three groups and challenged by repeating the above-mentioned procedure after 7 days and every second day afterwards for the duration of the experiment.

Treatment commenced on day 16. Both ears of the mice were treated topically by spreading 10 μ l of either *A. vera* gel, *A. ferox* gel or placebo gel over the affected areas on a daily basis for 10 days.

Mice were monitored for any signs of pain or distress by a qualified veterinarian on a daily basis and would have

been euthanized if necessary. Ear thickness was measured every second day with an electronic calibre.

Mice were euthanized on day 10 of the treatment procedure by isoflurane overdose and blood was collected by cardiac puncture for serum IgE measurement. Macroscopic photos were taken of the affected areas with a Canon Cu250 camera. The dorsal skin of each mouse was dissected, carefully removed and placed in 10 % buffered formalin overnight. The sections were progressed according to standard pathological procedures. The section (3 μ m thick) were cut, dewaxed and stained with haematoxylin and eosin for histopathological analysis.

IgE levels

Serum IgE levels were determined by a sandwich enzyme-linked immunosorbent assay (ELISA) using a BioLegend's ELISA MAXTM Deluxe kit.

Statistical analysis

Results are expressed as mean \pm SEM. Specific differences between study groups, following significance in the ANOVA were obtained using two-group *t* tests employing the pooled standard deviation determined from within group mean squares. These pair-wise comparisons were done at the Bonferroni adjusted 0.017 ($=0.05/3$) level of significance.

Results

Macroscopic results

Macroscopic photographs were obtained with a Canon Cu250 camera and an example thereof is presented in Fig. 1. Clear signs of DNFB induced dermatitis can be seen

in a placebo-treated mouse (Fig. 1a). Regarding the two treatment procedures (Fig. 1b, c) there were no signs of the disease in the *A. ferox* treatment arm whereas the mice in the *A. vera* treatment arm still showed traces of the disease.

Histological results

Histological findings showed an absence of skin structures such as hair follicles, sweat glands and ulceration in the placebo group, whereas the two treatments resulted in an increase of sub-epithelial stromal cells (Fig. 2).

IgE results

Serum IgE levels are presented in Table 1. The results indicated that both the active treatments decreased the IgE levels of the experimental mice significantly, compared to the placebo group [using one-way ANOVA ($p < 0.0001$)]. The results obtained with the *A. ferox* gel treatment were also significantly lower compared to the *A. vera* gel treatment using a pair-wise *t* test ($p = 0.002$).

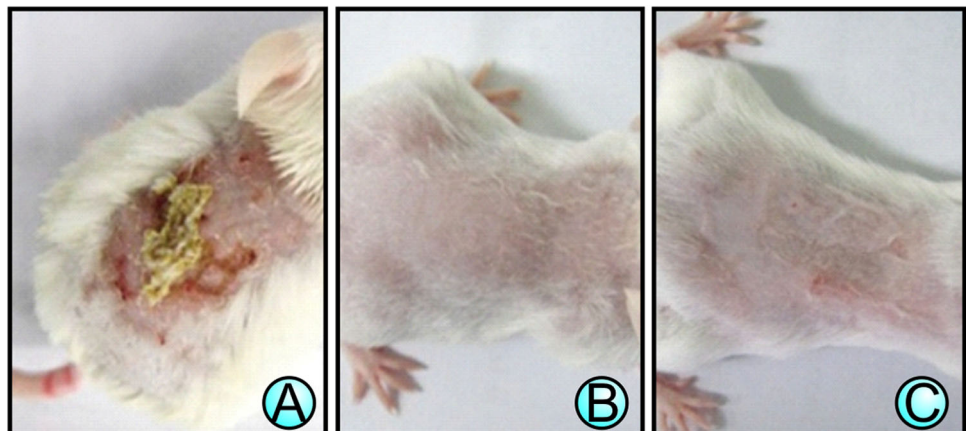
Adverse events

Four mice died during the study. Two were from the placebo group and died because of a severe reaction to the DNFB application and two from the *A. ferox* group due to fighting.

Discussion

Atopic dermatitis is a chronic disease that is difficult to define because of its variable morphology and distribution and its intermittent nature. Within the last several decades, there has been enough evidence to support the concept that AD has an immunologic basis (Leund 1997) and is associated with an increase in IgE levels (Stephen et al. 1973).

Fig. 1 Macroscopic photographs of 2,4-dinitrochlorobenzene (DNFB)-induced skin lesions of atopic dermatitis on mice after a 15-day treatment with **a** a placebo gel, **b** *Aloe ferox* gel and **c** *Aloe vera* gel



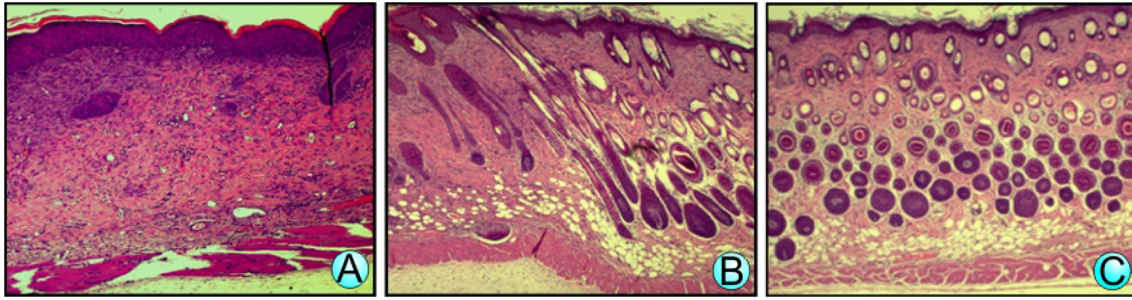


Fig. 2 Microscopic photographs of haematoxylin/eosin-stained sections of skin lesions on mice with 2,4-dinitrochlorobenzene (DNCB)-induced atopic dermatitis after a 15-day treatment with **a** a placebo gel, **b** *Aloe ferox* gel and **c** *Aloe vera* gel

Table 1 Effects of topical application of *A. vera* and *A. ferox* on IgE levels in mice suffering from atopic dermatitis

Treatment	Number of mice on treatment	Mean IgE concentration (ng/ml)	Standard deviation IgE concentration
Placebo	18	4356.183	361.186
<i>Aloe ferox</i>	18	4356.183*	361.186
<i>Aloe vera</i>	20	4105.793*	294.297

* $p < 0.0001$

Although the majority of AD patient are still being treated with topical corticosteroids as the first line of treatment, there is still an pressing requirement for other anti-inflammatory drugs that can be used as an alternative to, or as an intermittent or alternating therapy during long-term treatment with topical corticosteroids because of the concern regarding long-term side effects of corticosteroid therapy (Charman et al. 2000; Henge et al. 2006).

The use of *A. vera* as an herbal medicine has long been documented to have anti-inflammatory, anti-oxidant, anti-cancer, wound-healing, anti-ageing and anti-diabetic properties, whereas *A. ferox* extracts have been described to possess anti-inflammatory, anti-bacterial and anti-fungal properties (Reynolds and Dweck 1999). Cock (2015) concluded that the anti-inflammatory effects of the Aloe species are possible due to their anti-oxidant properties. Kim et al. (2010) investigated the effects of extracts of *A. ferox* and *S. radix*, administered p.o. at either 0.8 or 50 mg/kg in AD induced in mice. Both these treatments suppressed Il-5 levels but had no effect on IgE levels.

The present study was undertaken to assess the efficacy of the topical application of *A. ferox* and *A. vera* gel in 2,4-dinitrochlorobenzene (DNCB)-induced AD in mice. Macroscopic evaluation indicated that this model responded favourably to both *A. ferox* and *A. vera* treatments, with *A. ferox* treatment slightly superior to *A. vera* treatment. Furthermore, it was also found that these two treatments decreased the levels of IgE, possibly due to an inhibition of Th2 cell activation.

Histological analysis of the control group indicated abnormalities associated with AD such as ulceration as well as hyperkeratosis of the skin and an absence of skin structures such as hair follicles and sweat glands. This was also observed in the *A. ferox* and *A. vera* treatment groups, but to a lesser extent.

Further investigations need to be directed towards identifying target immune cells for *Aloe*-mediated alleviation of atopic dermatitis-like immunologic and skin alterations.

Conclusion

In this study, we identified the inhibitory effects of the gels of both *A. ferox* and *A. vera*, applied topically, on the symptoms as well as IgE levels of a mouse model of AD indicating that these gels may suppress chronic AD by a selective reduction of the Th2 response. This is in contrast with findings by Kim et al. (2010) who found that systemically applied *A. vera* gel had no effect on either IgE levels or the symptoms of spontaneous atopic dermatitis in mice. Furthermore, it was shown that the gel of *A. ferox* is superior to that of *A. vera* in this regard. These gels may be safe and useful alternatives for the treatment of patients suffering from recurring chronic AD.

Acknowledgments This study was supported by a Grant from the House of Aloes, Albertinia, South Africa.

References

- Arellano FM, Wentworth CE, Arana A, Fernandez C et al (2007) Risk of lymphoma following exposure to calcineurin inhibitors and topical steroids in patients with atopic dermatitis. *J Invest Dermatol* 127:808–816
- Ashcroft DM (2005) Efficacy and tolerability of topical pimecrolimus and tacrolimus in the treatment of atopic dermatitis: meta-analysis of randomised controlled trials. *Brit Med J* 330:516–522
- Beltrani VS (1999) The clinical spectrum of atopic dermatitis. *J Allergy Clin Immun* 104:587–598

- Capasso F, Borrelli F, Capasso R (1998) Aloe and its therapeutic use. *Phytother Res* 12:124–127
- Charman CR, Morris AD, Williams HC (2000) Topical corticosteroid phobia in patients with atopic eczema. *Brit J Dermatol* 142:931–936
- Chen W, Van Wyk B-E, Vermaak I et al (2012) Cape aloes: a review of the phytochemistry, pharmacology and commercialisation of *Aloe ferox*. *Phytochem Lett* 5:1–12
- Cock IE (2015) The genus aloe: phytochemistry and therapeutic uses including treatments for gastrointestinal conditions and chronic inflammation. *Drug Res* 70:179–235
- Duke JA (1997) *The green pharmacy*. Rodale Press, Emmaus
- Ellis C, Luger T, Abeck D et al (2003) International consensus conference on atopic dermatitis II (ICCAD II): clinical update and current treatment strategies. *Brit J Dermatol* 148:3–10
- Eshun K, He Q (2004) *Aloe vera*: a valuable ingredient for the food, pharmaceutical and cosmetic industries—a review. *Crit Rev Food Sci* 44:91–96
- Henge UR, Ruszicka T, Schwartz RA et al (2006) Adverse effects of topical glucocorticosteroids. *J Am Acad Dermatol* 54:1–15
- Kay GG (2000) The effects of antihistamines on cognition and performance. *J Allergy Clin Immunol* 105(6):S622–S625
- Kim J, Lee I, Park S, Choue R (2010) Effects of *Scutellariae radix* and *Aloe vera* gel extracts on immunoglobulin E and cytokine levels in atopic dermatitis NC/Nga mice. *J Ethnopharmacol* 132(2):529–532
- Lee S-J, Oh S-G, Seo S-W et al (2007) Oral administration of *Astragalus membranaceus* inhibits the development of DNFB-induced dermatitis in NC/Nga mice. *Biol Pharm Bull* 30:1468–1471
- Leund DY (1997) Atopic dermatitis: immunobiology and treatment with immune modulators. *Clin Exp Immunol* 107(1):25–30
- Reynolds T, Dweck AC (1999) *A ferox* extracts have been described to possess anti-inflammatory, anti-bacterial and anti-fungal properties plus increased wound healing. *J Ethnopharmacol* 28(1–3):3–37
- Sidbury R, Hanifin JM (2000) Systemic therapy of atopic dermatitis. *Clin Exp Dermatol* 25:559–566
- Stephen P, Stone SP, Muller SA, Muller MD, Gerald J, Gleich MD (1973) IgE levels in atopic dermatitis. *Arch Dermatol* 108(6):806–811