

Dynamic upper respiratory abnormalities in Thoroughbred racehorses in South Africa

Authors:

Javier E. Mirazo¹
Patrick Page¹
Luis Rubio-Martinez¹
Hendrick J. Marais¹
Catriona Lyle¹

Affiliations:

¹Department of Companion Animal Clinical Studies, University of Pretoria, South Africa

Correspondence to:

Javier Mirazo

Email:

javier.mirazo@gmail.com

Postal address:

Alejandro Chucarro 1218 apto. 901, CP 11300, Montevideo, Uruguay

Dates:

Received: 18 Nov. 2013

Accepted: 03 April 2014

Published: 14 Nov. 2014

How to cite this article:

Mirazo, J.E., Page, P., Rubio-Martinez, L., Marais, H.J. & Lyle, C., 2014, 'Dynamic upper respiratory abnormalities in Thoroughbred racehorses in South Africa', *Journal of the South African Veterinary Association* 85(1), Art. #1140, 6 pages. <http://dx.doi.org/10.4102/jsava.v85i1.1140>

Copyright:

© 2014. The Authors.
Licensee: AOSIS
OpenJournals. This work is licensed under the Creative Commons Attribution License.

Read online:

Scan this QR code with your smart phone or mobile device to read online.

Upper airway endoscopy at rest has been the diagnostic method of choice for equine upper respiratory tract (URT) conditions. Development of high-speed treadmill endoscopy improved the sensitivity of URT endoscopy by allowing observation of the horse's nasopharynx and larynx during exercise. However, treadmill exercise may not always accurately represent the horse's normal exercise as track surface, rider, tack and environmental variables are altered. Recently, the development of dynamic overground endoscopy (DOE) has addressed some of these shortcomings. A retrospective study was undertaken to describe the URT abnormalities detected during DOE in racehorses presenting with poor performance and/or abnormal respiratory noise. Patient records of Thoroughbred racehorses undergoing DOE from November 2011 to August 2012 were reviewed. Data collected included signalment, primary complaint, distance exercised, maximum speed and dynamic airway abnormalities detected. Fifty-two horses underwent DOE for investigation of poor performance and/or abnormal respiratory noise. The main abnormalities detected included axial deviation of the aryepiglottic folds (40%), vocal cord collapse (35%), abnormal arytenoid function (33%) and dorsal displacement of the soft palate (25%). A total of 40 horses were diagnosed with one or more abnormalities of the URT (77%). Fifteen horses (29%) had a single abnormality and 25 horses (48%) had multiple abnormalities. This study showed that DOE is a useful technique for investigating dynamic disorders of the URT in racehorses in South Africa. The total number and type of dynamic pathological conditions were comparable with those identified in similar populations in other geographical locations.

Introduction

Upper airway respiratory endoscopy has been the diagnostic method of choice for equine upper respiratory tract (URT) conditions since it was developed in the 1970s (Lane *et al.* 2006). Initially, URT endoscopy could only be performed with the horse standing at rest. Abnormal conditions detectable during resting URT endoscopy include recurrent laryngeal neuropathy (RLN), dorsal displacement of the soft palate (DDSP), epiglottic abnormalities, arytenoid chondritis and pharyngeal lymphoid hyperplasia (Barakzai & Dixon 2011; Desmaizieres *et al.* 2009; Perkins *et al.* 2009; Pollock *et al.* 2009). These conditions are often associated with poor performance and/or respiratory noise at work (Martin *et al.* 2000).

The subsequent development of high-speed treadmill endoscopy (HSTE) improved the accuracy of upper airway endoscopy as a diagnostic tool. It allowed detection of conditions that are not apparent during resting examinations such as palatal instability (PI) (Lane *et al.* 2006), intermittent DDSP (Barakzai & Dixon 2011; Desmaizieres *et al.* 2009; Lane *et al.* 2006; Pollock *et al.* 2009), left corniculate process collapse (LCPC) (Barakzai & Dixon 2011), axial deviation of aryepiglottic folds (ADAF) (King *et al.* 2001), vocal cord collapse (VCC) (Barakzai & Dixon 2011) and nasopharyngeal collapse (NPC) (Boyle *et al.* 2006; Strand & Staempfli 1993). In addition, it provided more information about arytenoid function at exercise (Barakzai & Dixon 2011; Desmaizieres *et al.* 2009; Franklin 2008; Pollock *et al.* 2009). Although HSTE allows the examiner to identify dynamic conditions, it may not replicate exercise during field conditions because surface, rider, tack and environmental variables are altered (Desmaizieres *et al.* 2009; Franklin, Burnt & Allen 2008). Financial costs, time to train the horse on the treadmill, transport requirements and misconceptions regarding the safety of the technique are recognised as other disadvantages of HSTE (Franklin *et al.* 2008).

The recent development of dynamic overground endoscopy (DOE) has addressed some of the shortcomings of HSTE. This procedure can be conducted without training the horse specifically for the examination and fewer personnel are required. The equipment can be transported to the patient and the horse can exercise in its normal environment with its usual tack and rider. Allowing the horse to exercise in its normal environment may result in more accurate

diagnosis of the cause of exercise intolerance (Desmaizieres *et al.* 2009; Franklin *et al.* 2008; Pollock *et al.* 2009). Potential disadvantages of DOE are that the examiner has less control of the exact exercise protocol and equipment-related problems (Barakzai 2012). Several studies have reported findings of DOE in populations of horses in Europe (Allen & Franklin 2010; Desmaizieres *et al.* 2009; Franklin *et al.* 2008; Pollock *et al.* 2009; Witte *et al.* 2011). To date, there are no studies reporting on the use of DOE in Thoroughbred racehorses in South Africa.

The aims of the present study were to describe the upper airway abnormalities detected by DOE in Thoroughbred racehorses presented with poor performance and/or abnormal respiratory noise at exercise in South Africa. It was hypothesised that the major abnormalities detected during DOE would be similar to those detected in other populations of Thoroughbred racehorses presented for poor performance and/or respiratory noise.

Research method and design

This was a retrospective study of data previously collected during clinical assessments. Patient records of Thoroughbred racehorses that had been referred to the Equine Clinic, Onderstepoort Veterinary Academic Hospital for DOE investigation of poor performance and/or respiratory noise from November 2011 to August 2012 were reviewed. Each horse had been examined once at a racetrack or training centre in South Africa (Figure 1). Overground endoscopy had been performed using the Videomed Mobile Laryngoscope system (Videomed GmbH, Munich, Germany) (Figure 2), whilst the exercise speed, distance and incline were recorded using a GPS monitor (Garmin Forerunner® 310XT; Garmin, Kansas City, USA).

Data analysis


Data collected from the patient records included signalment, primary complaint, track surface, distance exercised, maximum speed attained and dynamic airway abnormalities detected. The number of horses with single or multiple abnormalities detected was recorded and the relationships of those abnormalities to the primary complaint were also recorded. Arytenoid function at exercise was graded as either full abduction (Grade A), partial abduction, between full abduction and the resting position (Grade B), or less than resting position, including collapsing to the contralateral side (Grade C) (Rakestraw *et al.* 1991). Data were captured in an MS Office 2010 Excel spreadsheet.

Results

Fifty-two Thoroughbred racehorses that had undergone DOE were identified: 22 colts (43%), 9 geldings (17%) and 21 females (40%). The DOE examinations were performed at various racecourses and training centres around South Africa (Clairwood, Drakenstein, Durbanville, Randjiesfontein, Summerveld, Turffontein, Vaal) (Figure 3). The median age of horses examined was 3.6 years (range:

2–9 years). The horses were exercised over a mean distance of 1146 m (range: 600 m – 1600 m) and the mean maximum speed attained was 58.4 km/h (range 43.4 km/h – 66.5 km/h). Track surfaces used included grass (31 horses), sand (12 horses) and synthetic (9 horses).

The primary complaints for horses presented for DOE were abnormal respiratory noise at exercise only (34 of 52 horses, 66%), poor performance only (9 of 52 horses, 17%) and a combination of abnormal respiratory noise and poor performance (9 of 52 horses, 17%) (Table 1).



Source: Photographed by Luis Rubio-Martinez

FIGURE 1: Placement of the endoscope at the racetrack.



Source: Photographed by Javier Mirazo

FIGURE 2: Endoscope in position prior to examination.

In horses presented for respiratory noise or for the combination of respiratory noise and poor performance (43 of 52 cases), single abnormalities were observed in 13 horses (25%) and multiple abnormalities in 25 horses (48%) (Figure 4). An abnormality was more likely to be diagnosed by DOE if horses were presented for abnormal respiratory noise or abnormal respiratory noise associated with poor performance (38 of 43 cases, 88%), than if horses were presented only for poor performance (2 of 9 cases, 22%) (Table 1).

The most common abnormalities diagnosed were ADAF, VCC, abnormal arytenoid function (suggestive of RLN) and DDSP (Table 2). Axial deviation of the aryepiglottic folds was detected in 21 of 52 horses (40%). This condition was detected

as a single abnormality in two horses and in conjunction with other conditions in 19 horses. Vocal cord collapse was detected in 18 of 52 horses (35%) and was always associated with other conditions. Abnormal arytenoid function at exercise, consistent with RLN, was detected in 17 of 52 horses (33%). Grade B arytenoid function was observed in nine horses; it was seen as a single abnormality in one horse and in combination with other abnormalities in the other eight horses. Grade C arytenoid function was detected in eight horses; it was seen as a single abnormality in one horse and in association with other abnormalities in the other seven horses. Dorsal displacement of the soft palate was observed in 13 of 52 horses (25%). It was the sole abnormality detected in 8 of 13 horses (60%) and was associated with other abnormalities in 5 of 13 horses (40%).



Source: Photographed by Javier Mirazo

FIGURE 3: Dynamic overground endoscopy examination at gallop.



Source: Photographed by Javier Mirazo

FIGURE 4: Wireless console showing laryngeal function.

Other abnormalities that were less frequently observed were NPC, PI, and LCPC (Table 2). Pharyngeal collapse was observed in 7 of 52 horses (14%). It was found as a single abnormality in two of the seven affected horses and was found in combination with other abnormalities in the other five horses. In two horses there was only collapse of the dorsal pharyngeal wall, whilst in the other five horses there was collapse of the lateral and dorsal pharyngeal walls. Palatal instability was observed in 4 of 52 horses (8%). It was the sole abnormality found in one affected horse and was found in combination with other abnormalities in the other three horses. Only 3 of 52 horses (6%) were observed to have LCPC, which was always found in combination with other abnormalities.

Ethical considerations

The study was approved by the University of Pretoria's Animal Use and Care Committee (protocol reference V073-12).

Discussion

In the present study, dynamic pathological conditions were detected in the majority (77%) of horses. These results are comparable with studies in similar populations overseas where dynamic obstruction was identified in 65% – 77% of horses (Dart *et al.* 2001; Davidson *et al.* 2011; Desmaizieres *et al.* 2009; Franklin, Naylor & Lane 2006; Witte *et al.* 2011).

Multiple abnormalities were observed in 50% of the horses examined (Figure 5 and Figure 6), which is similar to the findings of Tan, Dowling and Dart (2005) and Dart *et al.* (2001), who reported that 49% and 73% of horses in their study populations, respectively, had multiple respiratory abnormalities in contrast to another study that identified a

TABLE 1: Number of abnormalities detected by dynamic overground endoscopy in relation to presenting complaint in 52 Thoroughbred racehorses examined from November 2011 to August 2012 in South Africa.

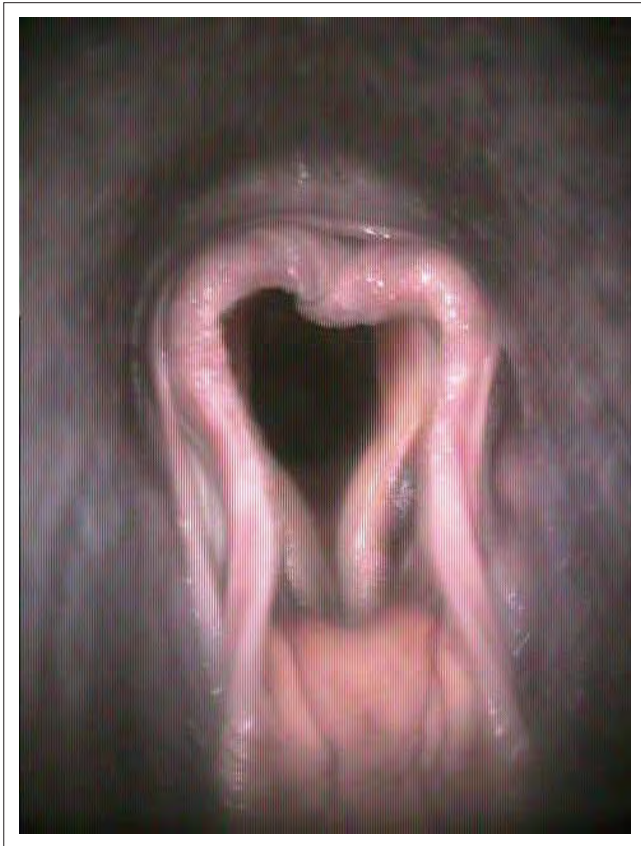Primary complaint	Number of horses						Total number of horses	
	No abnormalities		Single abnormalities		Multiple abnormalities		n	%
	n	%	n	%	n	%		
Respiratory noise	3	6	13	25	18	35	34	66
Respiratory noise and poor performance	2	4	0	0	7	13	9	17
Poor performance	7	13	2	4	0	0	9	17
Total	12	23	15	29	25	48	52	100

lower proportion (32%) of horses with multiple respiratory abnormalities (Lumsden *et al.* 1995). The detection of multiple abnormalities may be influenced by the population examined, evaluator expertise and the type of exercise performed (e.g. distance exercised, speed attained, degree of fatigue achieved). Horses that ran shorter distances or only attained lower speeds may not have been exerted enough to demonstrate an underlying condition.

A respiratory abnormality was more likely to be diagnosed in horses presented with an abnormal respiratory noise or abnormal respiratory noise associated with poor performance, rather than in horses presented for only poor performance. Horses with poor performance but no abnormal respiratory

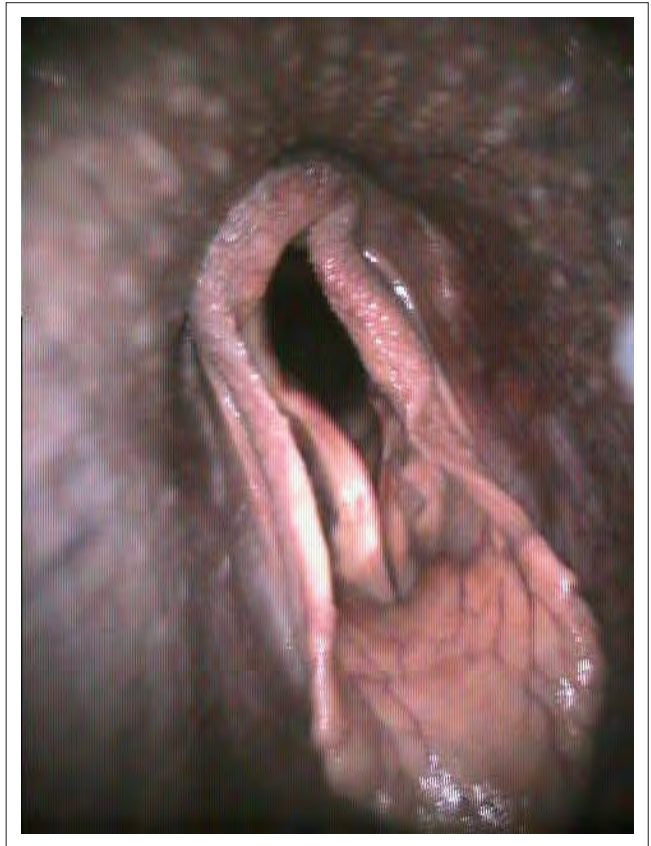noise may suffer from musculoskeletal, lower respiratory tract or heart conditions (Martin *et al.* 2000).

The prevalence of specific upper airway disorders in this study was similar to that reported in other populations of Thoroughbred racehorses with respiratory noise and/or poor performance, consistent with the study hypothesis. In the present study, abnormal arytenoid function at exercise was observed in 33% of horses evaluated for poor performance and/or respiratory noise. Dynamic endoscopy in similar populations has detected this in approximately 8% – 40% of horses (Allen & Franklin 2010; Barakzai & Dixon 2011; Dart *et al.* 2001; Desmaizieres *et al.* 2009; Tan *et al.* 2005). Dorsal displacement of the soft palate was also one of the most



Source: Image captured by Javier Mirazo

FIGURE 5: Multiple abnormalities observed in the study: left corniculate process collapse, axial deviation of aryepiglottic folds and vocal cord collapse.



Source: Image captured by Javier Mirazo

FIGURE 6: Multiple abnormalities observed in the study: Arytenoid collapse, vocal cord collapse and axial deviation of aryepiglottic folds.

TABLE 2: Specific respiratory abnormalities (single and multiple) detected by dynamic overground endoscopy in 52 Thoroughbred racehorses examined from November 2011 to August 2012 in South Africa.

Number of abnormalities	Abnormalities	Number of horses	Percentage of total cases (%)
3	RLN (Grade B) + ADAF + VCC	5	10
	RLN (Grade C) + VCC + ADAF	2	4
	DDSP + RLN (Grade B) + VCC	1	2
	RLN (Grade B) + ADAF + NPC	1	2
Total		9	18
4	DDSP + ADAF + VCC + LCPC	1	2
	VCC + ADAF + LCPC + PC	1	2
Total		2	4
6	DDSP + ADAF + VCC + LCPC + RLN (Grade B) + PI	1	2
	Total	1	2
Total		12	23

RLN, recurrent laryngeal neuropathy; ADAF, axial deviation of aryepiglottic folds; VCC, vocal cord collapse; DDSP, dorsal displacement of the soft palate; NPC, nasopharyngeal collapse; LCPC, left corniculate process collapse; PI, palatal instability.

commonly detected abnormalities in the present study (25%) (Figure 7), similar to the proportion of horses reported with DDSP in comparative populations: 19% (Pollock *et al.* 2009), 26% (Witte *et al.* 2011) and 28% (Desmaizieres *et al.* 2009).

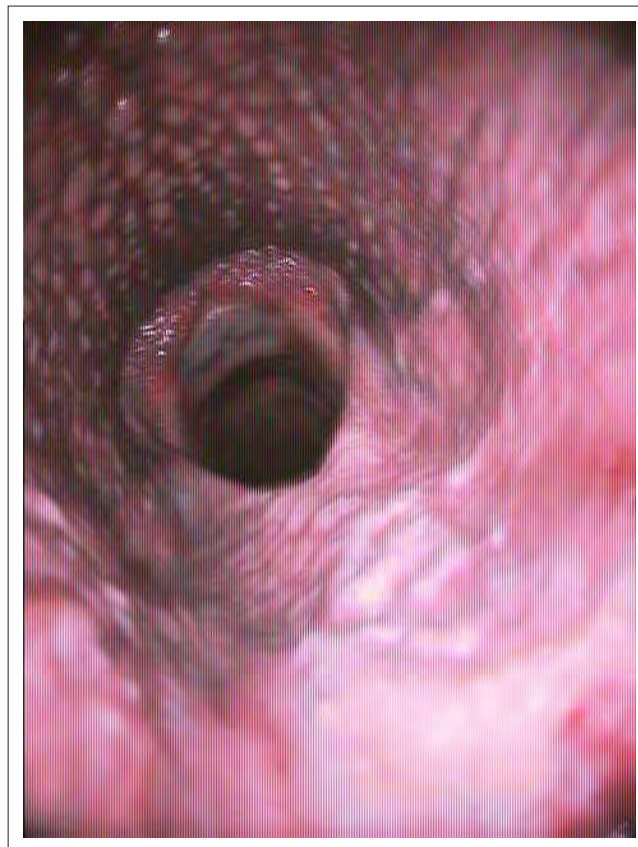Vocal cord collapse, detected in 18% of horses in this study, may be found as the sole URT abnormality, or it may be associated with RLN (Dart *et al.* 2001; Kannegeiter & Dore 1995; Lane *et al.* 2006; Tan *et al.* 2005). Vocal cord collapse has been identified in 2% – 12% of horses referred for HSTE (Dart *et al.* 2001; Kannegeiter & Dore 1995; Lane *et al.* 2006; Martin *et al.* 2000; Tan *et al.* 2005).

Axial deviation of the aryepiglottic folds, detected in 40% of horses in this study, was identified in 5% – 55% of horses referred for HSTE (Dart *et al.* 2001; Desmaizieres *et al.* 2009; Kannegeiter & Dore 1995; King *et al.* 2001; Lane *et al.* 2006; Martin *et al.* 2000; Tan *et al.* 2005). Although ADAF may occur as the sole abnormality (Kannegeiter & Dore 1995; King *et al.* 2001; Lane *et al.* 2006; Tan *et al.* 2005), horses with ADAF frequently have concurrent dynamic upper airway disorders (Lane *et al.* 2006; Tan *et al.* 2005), as seen in this study. The relationship, however, between ADAF and these concurrent dynamic URT disorders is not known.

Nasopharyngeal collapse, which was identified in 14.0% of horses in this study (Figure 8), has been observed during DOE examinations to be a cause of respiratory noise and/or exercise intolerance in performance horses and racehorses (Boyle *et al.* 2006; Dart *et al.* 2001; Kannegeiter & Dore 1995; Martin *et al.* 2000; Strand & Staempfli 1993). Studies have found NPC to occur with considerably less frequency than other dynamic abnormalities of the URT, with a prevalence of 1.3% – 18.0% in racehorses examined because of respiratory noise and/or poor performance (Kannegeiter & Dore 1995; Lane *et al.* 2006; Tan *et al.* 2005).

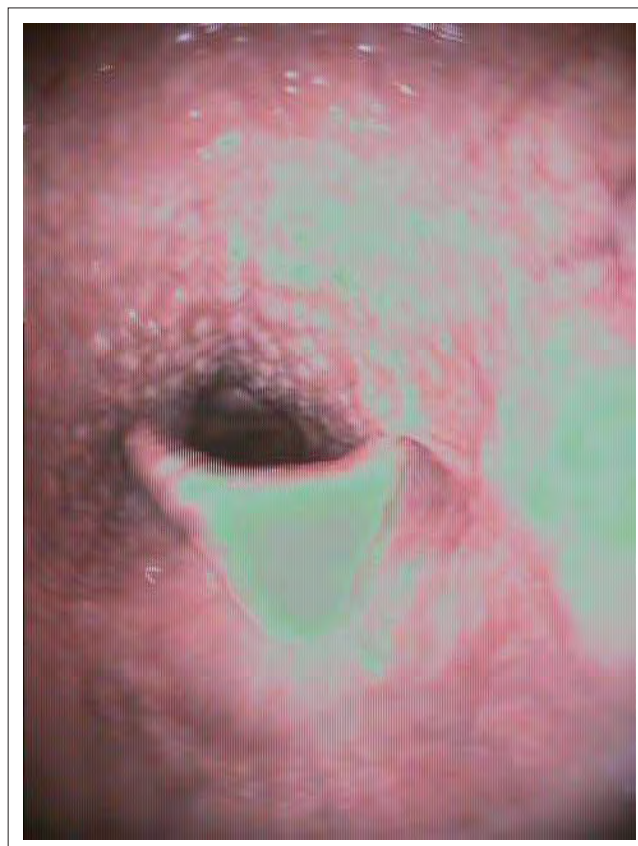Left corniculate process collapse was only identified in 6.0% of the horses in this study, similar to a previous report of 4.9% (15 of 309) of horses examined because of respiratory noise and/or poor performance during exercise (Dart, Dowling & Smith 2005).

This study was limited to the retrospective evaluation of 52 horses and therefore only reflects a sample of Thoroughbred racehorses with poor performance and/or respiratory noise. Horses presented for DOE may be more valuable horses, or horses with more severe diseases, and therefore this sample may not reflect the Thoroughbred racehorse population in South Africa as a whole. Whilst the mean maximal speed reported in the present study (58 km/h) is similar to the 56 km/h reported for 140 Thoroughbred racehorses undergoing DOE and is similar to the average racing speed of 58 km/h for the winning horse in flat races up to 1.6 km (1 mile) (Allen & Franklin 2010), horses that ran short distances or attained lower speeds during DOE may not have developed any detectable conditions or the actual performance-limiting condition that may have occurred during actual training or racing.



Source: Image captured by Javier Mirazo

FIGURE 7: Single abnormality observed in the study: Dorsal displacement of the soft palate.



Source: Image captured by Javier Mirazo

FIGURE 8: Single abnormality observed in the study: Nasopharyngeal collapse.

Conclusion

The results of this study show that DOE is a useful technique and provides valuable information regarding dynamic disorders of the URT of South African Thoroughbred racehorses that suffer from poor performance and/or abnormal respiratory noise. The main abnormalities detected were DDSP, abnormal arytenoid function, ADAF, and VCC; the prevalence of these conditions was comparable to the prevalence in similar populations worldwide.

Acknowledgements

Competing interests

The authors declare that they have no financial or personal relationships which may have inappropriately influenced them in writing this article.

Authors' contributions

All authors (University of Pretoria) contributed to the study design, collection of data and preparation of the manuscript. J.E.M. (University of Pretoria) carried out the data analysis.

References

- Allen, K.J. & Franklin, S.H., 2010, 'Comparisons of overground endoscopy and treadmill endoscopy in UK Thoroughbred racehorses', *Equine Veterinary Journal* 42, 186–191. <http://dx.doi.org/10.1111/j.2042-3306.2010.00033.x>
- Barakzai, S., 2012, 'How is the use of overground exercising endoscopy affecting our management of URT disease in the horse?', in P. Clegg & S. Baines (eds.), *21st Annual Scientific Meeting of European College of Veterinary Surgeons proceedings*, Barcelona, Spain, 05–07 July, pp. 100–101.
- Barakzai, S.Z. & Dixon, P.M., 2011, 'Correlation of resting and exercising endoscopic findings for horses with dynamic laryngeal collapse and palatal dysfunction', *Equine Veterinary Journal* 43, 18–23. <http://dx.doi.org/10.1111/j.2042-3306.2010.00108.x>
- Boyle, A.G., Martin, B.B. Jr., Davidson, E.J., Durando, M.M. & Birks, E.K., 2006, 'Dynamic pharyngeal collapse in racehorses', *Equine Veterinary Journal* 38 S36, 546–550. <http://dx.doi.org/10.1111/j.2042-3306.2006.tb05602.x>
- Dart, A.J., Dowling, B.A., Hodgson, D.R. & Rose, R.J., 2001, 'Evaluation of high-speed treadmill videoendoscopy for diagnosis of upper respiratory tract dysfunction in horses', *Australian Veterinary Journal* 79, 109–112. <http://dx.doi.org/10.1111/j.1751-0813.2001.tb10713.x>
- Dart, A.J., Dowling, B.A. & Smith, C.L., 2005, 'Upper airway dysfunction associated with collapse of the apex of the corniculate process of the left arytenoid cartilage during exercise in 15 horses', *Veterinary Surgery* 34, 543–547. <http://dx.doi.org/10.1111/j.1532-950X.2005.00085.x>
- Davidson, E.J., Martin, B.B., Boston, R.C. & Parente, E.J., 2011, 'Exercising upper respiratory videoendoscopic evaluation of 100 nonracing performance horses with abnormal respiratory noise and/or poor performance', *Equine Veterinary Journal* 43, 3–8. <http://dx.doi.org/10.1111/j.2042-3306.2010.00132.x>
- Desmaizieres, L.M., Serraud, N., Plainfosse, B., Michel, A. & Tamzali, Y., 2009, 'Dynamic respiratory endoscopy without treadmill in 68 performance Standardbred, Thoroughbred and Saddle horses under natural training conditions', *Equine Veterinary Journal* 41, 347–352. <http://dx.doi.org/10.2746/042516409X427169>
- Franklin, S.H., 2008, 'Dynamic collapse of the upper respiratory tract: A review', *Equine Veterinary Education* 20, 212–224. <http://dx.doi.org/10.2746/095777308X290382>
- Franklin, H., Burnt, J.F. & Allen, K.J., 2008, 'Clinical trials using a telemetric endoscope for use during over-ground exercise: A preliminary study', *Equine Veterinary Journal* 40, 712–715. <http://dx.doi.org/10.2746/042516408X363783>
- Franklin, S.H., Naylor, J.R. & Lane, J.G., 2006, 'Videoendoscopic evaluation of the upper respiratory tract in 93 sport horses during exercise testing on a high-speed treadmill', *Equine Veterinary Journal* 38 S36, 540–545. <http://dx.doi.org/10.1111/j.2042-3306.2006.tb05601.x>
- Kannegeiter, N.J. & Dore, M.L., 1995, 'Endoscopy of the upper respiratory tract during treadmill exercise: A clinical study of 100 horses', *Australian Veterinary Journal* 72, 101–107. <http://dx.doi.org/10.1111/j.1751-0813.1995.tb15020.x>
- King, D.S., Tulleners, E., Martin, B.B. Jr., Parente, E.J. & Boston, R., 2001, 'Clinical experiences with axial deviation of the aryepiglottic folds in 52 racehorses', *Veterinary Surgery* 30, 151–160. <http://dx.doi.org/10.1053/jvet.2001.21389>
- Lane, J.G., Bladon, B., Little, D.R., Naylor, J.R. & Franklin, S.H., 2006, 'Dynamic obstructions of the equine upper respiratory tract. Part 1: Observations during high-speed treadmill endoscopy of 600 thoroughbred racehorses', *Equine Veterinary Journal* 38, 393–399. <http://dx.doi.org/10.2746/042516406778400583>
- Lumsden, J.M., Stick, J.A., Caron, J.J., Nickels, F.A., Brown, C.M., Godber, L.M. et al., 1995, 'Upper airway function in performance horses: Videoendoscopy during high speed treadmill exercise', *Compendium of Continuing Education of the Practicing Veterinarian* 17, 1134–1143.
- Martin, B.B. Jr., Reef, V.B., Parente, E.J. & Sage, A.D., 2000, 'Causes of poor performance of horses during training, racing, or showing: 348 Cases (1992–1996)', *Journal of the American Veterinary Medical Association* 216, 554–558. <http://dx.doi.org/10.2460/javma.2000.216.554>
- Perkins, J.D., Salz, R.O., Schumacher, J., Livesey, L., Piercy, R.J. & Barakzai, S.Z., 2009, 'Variability of resting endoscopic grading for assessment of recurrent laryngeal neuropathy in horses', *Equine Veterinary Journal* 41, 342–346. <http://dx.doi.org/10.2746/042516409X423073>
- Pollock, P.J., Reardon, R.J., Parkin, T.D., Johnston, M.S., Tate, J. & Love, S., 2009, 'Dynamic respiratory endoscopy in 67 Thoroughbred racehorses training under normal ridden exercise conditions', *Equine Veterinary Journal* 41, 354–360. <http://dx.doi.org/10.2746/042516409X407107>
- Rakestraw, P.C., Hackett, R.P., Ducharme, N.G., Nielan, G.J. & Erb, H.N., 1991, 'Arytenoid cartilage movement in resting and exercising horses', *Veterinary Surgery* 20, 122–127. <http://dx.doi.org/10.1111/j.1532-950X.1991.tb00319.x>
- Strand, E. & Staempfli, H.R., 1993, 'Dynamic collapse of the roof of the nasopharynx as a cause of poor performance in a Standardbred colt', *Equine Veterinary Journal* 25, 252–254. <http://dx.doi.org/10.1111/j.2042-3306.1993.tb02956.x>
- Tan, R.H., Dowling, B.A. & Dart, A.J., 2005, 'High-speed treadmill videoendoscopic examination of the upper respiratory tract in the horse: The results of 291 clinical cases', *Veterinary Journal* 170, 243–248. <http://dx.doi.org/10.1016/j.tvjl.2004.06.011>
- Witte, S.H., Witte, T.H., Harriss, F., Kelly, G. & Pollock, P., 2011, 'Association of owner-reported noise with findings during dynamic respiratory endoscopy in Thoroughbred racehorses', *Equine Veterinary Journal* 43, 9–17. <http://dx.doi.org/10.1111/j.2042-3306.2010.00152.x>