

**Expression of vascular endothelial growth factor in dogs with *Spirocerca lupi*-  
associated neoplastic transformation**

**By**

**Varaidzo Mukorera**

Submitted to the Faculty of Veterinary Science, University of Pretoria  
in partial fulfilment of the requirements for the MMedVet (Med) degree

**Pretoria, May 2012**

**Expression of vascular endothelial growth factor in dogs with *Spirocerca lupi*-  
associated neoplastic transformation**

**DISSERTATION**

**Varaidzo Mukorera**

Research conducted in the Section of Small Animal Medicine,

Department of Companion Animal Clinical Studies,

Faculty of Veterinary Science,

University of Pretoria

**Supervisor:**

**Prof Eran Dvir**

**Department of companion Animal Clinical Studies**

**Faculty of Veterinary Science**

**University of Pretoria**

## **Declaration**

I hereby declare that this dissertation, submitted for the MMedVet (Med) degree, to the University of Pretoria, is my own work and has not been submitted to another university for a degree, and that the data included in this dissertation are the results of my investigations.

Varaidzo Mukorera

15 May 2012

## SUMMARY

### **Expression of vascular endothelial growth factor in dogs with *Spirocerca lupi*- associated neoplastic transformation**

Mukorera V. University of Pretoria, 2012

Tumour development is dependent upon the formation of an adequate blood supply through angiogenesis. Vascular endothelial growth factor (VEGF) is one of the most potent and specific pro-angiogenic factors associated with tumour development. Vascular endothelial growth factor is elevated in dogs with a variety of neoplastic tumours and has been linked to an increased risk for metastasis and a poorer prognosis in several tumours. *Spirocerca lupi* (*S. lupi*) is a nematode of canids which infests the oesophagus where it forms a nodule. The oesophageal nodule can develop into a neoplastic tumour namely osteosarcoma, fibrosarcoma or anaplastic sarcoma. The pathogenesis of the neoplastic transformation is poorly understood. Diagnosis of neoplastic transformation can be challenging and is based on endoscopy-guided biopsies which are invasive, expensive and may yield non diagnostic samples. The aim of this prospective study was to determine if serum and plasma VEGF levels could be used to distinguish between neoplastic and non-neoplastic spirocercosis.

Twenty four dogs were enrolled in the study, 9 with non-neoplastic, 9 with neoplastic spirocercosis, and 6 control dogs. Plasma and serum samples for VEGF analysis were collected at diagnosis. Measurement of VEGF was done using a canine VEGF Quantikine ELISA kit. Statistical analysis to compare the means of the VEGF concentrations between

the groups was performed using the Kruskal-Wallis followed by the Dunn's test. Significance was set at  $p < 0.05$

The median plasma VEGF concentration of the dogs with neoplastic spirocercosis 629pg/ml (range 282 – 2366) was higher than the median plasma VEGF concentrations of both the non-neoplastic 0pg/ml (range 0 – 716) and controls 0pg/ml (range 0 – 0) ( $p < 0.001$ ). The median serum VEGF concentration of the neoplastic dogs 69pg/ml (range 0 – 212) was higher than the serum VEGF concentrations in the non-neoplastic 0pg/ml (range 0 – 44.13) and control 0pg/ml (range 0 – 39.4) ( $p = 0.001$ ). Plasma VEGF at a cut off value of 250pg/ml was determined to have a sensitivity of 100%, specificity of 77.8%, a PPV of 81.8% and a NPV of 100% for determining neoplastic transformation. Serum VEGF at a cut off value of 25pg/ml was determined to have a sensitivity of 88.9%, specificity of 100%, a PPV of 100% and a NPV of 90% for determining neoplastic transformation.

Both plasma and serum VEGF concentrations can be used to differentiate between non-neoplastic and neoplastic spirocercosis. Plasma VEGF concentrations were higher than serum VEGF concentrations, contrary to what is reported in literature. Both plasma and serum VEGF concentrations can, therefore, potentially be used for diagnosis of neoplastic vs. non-neoplastic cases in canine spirocercosis. There is a need to perform more studies to determine cut-off concentrations that would maximize the sensitivity and specificity for determining neoplastic transformation in canine spirocercosis as well as to determine the role of VEGF in the pathogenesis of the neoplastic transformation.

## TABLE OF CONTENTS

<b>Summary</b>	iv
<b>List of abbreviations</b>	ix
<b>List of figures</b>	x
<b>List of tables</b>	xi
<b>Acknowledgements</b>	xii
<b>Dedication</b>	xiii
<b>CHAPTER 1: Literature Review</b>	1
1.1 Life cycle of <i>Spirocerca lupi</i>	1
1.2 Clinical signs and complications associated with <i>Spirocerca lupi</i>	2
1.3 Diagnosis of canine spirocercosis	2
1.4 Determination of neoplastic transformation in canine spirocercosis	3
1.5 Biomarkers in cancer	5
1.6 Biomarkers in canine spirocercosis	6
1.7 Biomarkers in tumour angiogenesis	8
1.8 Vascular endothelial growth factor	8
1.9 Measurement of vascular endothelial growth factor	10
<b>CHAPTER 2: Study objectives</b>	12
2.1 Problem statement	12
2.2 Research questions	12
2.3 Hypothesis	12

2.4 Objectives	13
2.5 Benefits arising from the study	13
<b>CHAPTER 3: Materials and Method</b>	14
3.1 Model system	14
3.2 study population	14
3.3 Experimental design	14
3.4 Experimental procedure	16
3.5 Vascular endothelial growth factor analysis	18
3.6 Statistical analysis	18
<b>CHAPTER 4: Results</b>	20
4.1 Number of dogs enrolled into the study	20
4.2 Plasma VEGF concentrations	20
4.3 Serum VEGF concentrations	22
4.4 Plasma vs Serum VEGF concentration	23
<b>CHAPTER 5: Discussion</b>	24
5.1 Weaknesses of the study	27
5.2 Future Studies	27
<b>CHAPTER 6: Conclusion</b>	29
<b>REFERENCES</b>	30
<b>APPENDICES</b>	41
<b>Appendix A:</b> Client consent form for groups A and B	41
<b>Appendix B:</b> Client consent form for group C	43
<b>Appendix C:</b> Information sheet on canine spirocercosis	45
<b>Appendix D:</b> Endoscopy form	46

## LIST OF ABBREVIATIONS

<b>ALP</b>	<b>Alkaline phosphatase</b>
<b>bFGF</b>	<b>Basic fibroblast growth factor</b>
<b>CRP</b>	<b>C-reactive protein</b>
<b>EDTA</b>	<b>Ethylenediaminetetraacetic acid</b>
<b>ELISA</b>	<b>Enzyme linked immunosorbent assay</b>
<b>FGF <math>\beta</math></b>	<b>Fibroblast growth factor <math>\beta</math></b>
<b>HIF-1</b>	<b>Hypoxia inducible transcription factor 1</b>
<b>HO</b>	<b>Hypertrophic osteopathy</b>
<b>Ht</b>	<b>Haematocrit</b>
<b>IGF</b>	<b>Insulin-like growth factor</b>
<b>MCV</b>	<b>Mean corpuscular volume</b>
<b>NPV</b>	<b>Negative predictive value</b>
<b>OVAH</b>	<b>Onderstepoort veterinary academic hospital</b>
<b>PDGF</b>	<b>Platelet derived growth factor</b>
<b>PPV</b>	<b>Positive predictive value</b>
<b><i>S. lupi</i></b>	<b><i>Spirocerca lupi</i></b>
<b>SD</b>	<b>Standard deviation</b>
<b>SNPs</b>	<b>Single nucleotide polymorphisms</b>
<b>SPSS</b>	<b>Statistical package for the social sciences</b>



<b>TNF <math>\alpha</math></b>	<b>Tumour necrosis factor <math>\alpha</math></b>
<b>VEGF</b>	<b>Vascular endothelial growth factor</b>
<b>WBC</b>	<b>White blood cell count</b>

### **List of figures**

- Figure 1** Box plot comparing plasma VEGF concentrations in the controls, non neoplastic and neoplastic cases
- Figure 2** Box plot comparing serum VEGF concentrations in the controls, non neoplastic and neoplastic cases
- Figure 3** Box plot comparing serum and plasma VEGF concentrations in the control, non neoplastic and neoplastic cases

## List of Tables

- Table 1** Gender and age distribution in the control, non neoplastic and neoplastic groups
- Table 2** Sensitivity, specificity, PPV and NPV of plasma VEGF concentrations for the determination of neoplastic transformation
- Table 3** Sensitivity, specificity, PPV and NPV of serum VEGF concentrations for the determination of neoplastic transformation

## ACKNOWLEDGEMENTS

I would like to thank the following people for their assistance with this project:

Professor Eran Dvir, my supervisor, mentor and friend who provided invaluable support and guidance from inception to completion of the project. Through thick and thin, we survived.

Professor Robert Kirberger, for his mentorship and a great part of the financial support required to see this project through.

Dr Liesel van der Merwe who was the leader of the *Spirocerca* research group.

Dr Peaceful Mabeta for her technical support and expertise in performing the ELISA.

All the small animal medicine and outpatients clinicians involved in patient selection.

The clinic sisters in the radiology and small animal medicine departments with a special mention for Carla van der Merwe and Liani Kitshoff for their tireless work during the project.

All my colleagues in the Onderstepoort Veterinary Academic Teaching Hospital and owners of some of the blood donor dogs who allowed me to enrol their beloved dogs as control dogs for the trial.

Professor Becker for the statistical advice offered in order to complete the data analysis for this project.

Last but not least, I would like to thank all the final year students that were involved with the project in one way or another.

## **DEDICATION**

This dissertation is dedicated to my partner, Roswall Pfaira. He has been like the wind in my sails when most needed. It is also dedicated to my parents, Mark and Tokozani Florence Mukorera without whom I would not have travelled this far in my academic career.

## CHAPTER 1: Literature review

### 1.1 Life cycle of *Spirocerca lupi*

*Spirocerca lupi* (*S. lupi*) is a nematode that infects primarily canidae.<sup>1-3</sup> The adult worm resides in a nodule in the oesophagus from where eggs are passed into the lumen of the oesophagus. The eggs are passed in the faeces and are ingested by coprophagous beetles that serve as the intermediate hosts. The larvae develop to L3 in the intermediate host. The beetles can be ingested by paratenic hosts which include lizards, hedgehogs, mice, rabbits and birds.<sup>1</sup> The dog becomes infected when it ingests infected beetles or paratenic hosts. Once in the stomach, the larvae excyst and penetrate the gastric mucosal lining and migrate along the gastric arteries to reach the abdominal aorta and ultimately the caudal thoracic aorta. The immature adults migrate from the aorta to the caudal thoracic oesophagus where they develop and reside in a nodule and mature to adults. Spirocercosis is associated with 3 pathognomonic lesions: the caudal oesophageal nodule, aortic aneurysms that develop in the aorta secondary to the migration of *S. lupi* larvae and spondylitis of the ventral bodies of the caudal thoracic vertebrae.<sup>1, 3</sup> In untreated canine spirocercosis, the oesophageal nodule can transform into a sarcoma.<sup>4</sup> The different types of sarcoma that have been diagnosed include osteosarcoma, fibrosarcoma and anaplastic sarcomas.<sup>1, 5-8</sup> Both the non-neoplastic and neoplastic nodules show histological evidence of inflammation.<sup>4</sup> Non-neoplastic spirocercosis is treated successfully with doramectin.<sup>9</sup> In breeds that are susceptible to the side effects of doramectin, milbemycin can be used as an alternative.<sup>10</sup> Once neoplastic transformation occurs, treatment involves surgical resection followed by chemotherapy and the prognosis is much poorer.<sup>3</sup> The identification of cases with neoplastic transformation, therefore, has major therapeutic and prognostic implications.

## 1.2 Clinical signs and complications associated with canine spirocercosis

Clinical signs associated with *S. lupi* infection are related to the different stages of the worm life cycle within the host. Some cases of are subclinical and go undetected for a long time.<sup>5</sup> Regurgitation and/or vomiting, weight loss and pyrexia are the most common clinical signs.<sup>5</sup> <sup>6</sup> Aortic aneurysms can occur from as early as 2 weeks post infection and can lead to sudden death when they rupture.<sup>3</sup> Anaemia may develop as a result of bleeding oesophageal ulcers<sup>6</sup> on necrotic nodules and/or as a result of anaemia of chronic disease. A myriad of respiratory signs are associated with canine spirocercosis including cough and dyspnoea, secondary bronchial compression, mediastinitis or pleuritis.<sup>6, 11</sup> Salivation due to sialoadenitis is a relatively common entity that is observed in *S. lupi*.<sup>3</sup> Paresis has been described in cases that have had aberrant migration into the spinal cord,<sup>12</sup> as well as cases with extramedullary spinal migration.<sup>13</sup> Lameness may develop secondary to hypertrophic osteopathy (HO) and secondary polyarthritis.<sup>2,3</sup>

## 1.3 Diagnosis of canine spirocercosis

The diagnosis of *S. lupi* can be achieved by faecal evaluation, thoracic radiography and endoscopy.

### *Faecal evaluation*

The detection of larvated worm eggs on faecal evaluation is considered definitive.<sup>6, 7, 14</sup> The egg is small (35 x 15um), thick shelled and contains a larva.<sup>3, 5</sup> Diagnosis by this method however is not without pitfalls. Shedding of eggs by the worm happens inconsistently during the adult female lifespan.<sup>3</sup> A recent study demonstrated that the diagnosis of canine spirocercosis using faecal evaluation had a sensitivity of up to 67%, quite a low figure for a

diagnostic test. In addition, egg shedding was shown to be much lower in dogs with neoplastic transformation.<sup>15</sup>

### *Radiology*

Radiology can also be used for the diagnosis of *S. lupi* owing to the characteristic radiological signs seen in *S. lupi* infected dogs. These signs are a mass in the caudodorsal mediastinum, spondylitis of the caudal thoracic vertebrae, and undulation of the left lateral border of the proximal part of the descending aorta.<sup>3, 5</sup> The diagnosis of spirocercosis with thoracic radiographs is 86% sensitive and in 14% of cases the mass in the oesophagus is not visualised on thoracic radiographs, either due to small size or cranial location that results in superimposition on other mediastinal organs.<sup>16</sup>

### *Oesophageal endoscopy*

Direct visualisation of the nodules in the oesophagus can be achieved by performing oesophageal endoscopy. One or several smooth rounded nodules which may have a nipple-like protuberance through which the female lays eggs are typically seen in early infections. Over time, the nodules may enlarge and become ulcerated, lobulated and cauliflower-like.<sup>3</sup> These latter signs are commonly associated with neoplastic transformation.<sup>11</sup>

## **1.4 Determination of neoplastic transformation in canine spirocercosis**

Currently, the definitive ante-mortem determination of neoplastic transformation is based on histopathology of samples obtained through oesophageal endoscopy.<sup>2, 3, 11</sup> Endoscopy guided

biopsies are invasive, expensive and the biopsy samples often yield non-diagnostic necrotic samples.<sup>3</sup> In the study by Ranen, false negative results were obtained in 3 out of 6 cases.<sup>11</sup>

In the study by Dvir, 8 out of 13 biopsy samples were non diagnostic.<sup>5</sup> As the neoplastic mass grows, it becomes fragile and necrotic on the periphery. Biopsies obtained via oesophageal endoscopy often are not deep enough to obtain diagnostic tissue and only necrotic material is obtained.<sup>3, 7, 11</sup> Previous studies evaluating the signalment of dogs with spirocercosis reported that sterilised females seem to be predisposed to the development of neoplastic transformation while intact males were more frequently seen in the non-neoplastic group.<sup>2, 8</sup> Dogs with *Spirocerca*-induced sarcoma were significantly older than those with non-neoplastic nodules. The ages in these groups however, overlapped substantially and it is most likely related to the time required for neoplastic transformation and not biological predisposition.<sup>2, 8</sup> On thoracic radiography neoplastic cases show a higher prevalence of spondylitis of the caudal thoracic vertebrae and bronchial displacement, but as they are seen in 16 and 38 percent of non-neoplastic cases respectively, they are therefore not sensitive markers for neoplastic transformation. Increased height and width of the oesophageal nodules are also features of neoplasia but there was a substantial overlap in the values between neoplastic and non-neoplastic cases.<sup>2, 11</sup> Endoscopic appearance of neoplastic nodules can be used to determine neoplastic transformation.<sup>11</sup> The endoscopic appearance generally correlates well with either non-neoplastic or neoplastic status, it is subjective and sometimes unreliable. Neoplastic nodules generally appear cauliflower-shaped, necrotic and ulcerated. Early neoplastic nodules may be misclassified as non-neoplastic and some non-neoplastic may look neoplastic (possibly old and injured nodules).<sup>5</sup> Response to treatment can be used to determine if neoplastic transformation has occurred. Non-neoplastic nodules are expected to become smaller with treatment while the neoplastic nodules are expected to remain the same size or become bigger.<sup>9</sup> This approach is time consuming and may not be suited to clinically



compromised cases. Hypertrophic osteopathy is associated with neoplastic transformation in cases with canine spirocercosis with 100% specificity.<sup>2</sup> However, only about 40% of cases with neoplastic disease develop HO, making it a insensitive marker for neoplastic transformation.

In light of the expense and difficulties encountered in trying to determine if neoplastic transformation of the *S. lupi* nodule has occurred, there is a need for relatively easy and readily available methods to determine if neoplastic transformation has taken place.

## 1.5 Biomarkers in cancer

A biomarker is described as a characteristic that is objectively measured and evaluated as an indicator of normal biologic process, pathogenic process or pharmacologic responses to a therapeutic intervention. The parameters can be chemical, physical or biological.<sup>17, 18</sup> Soluble biomarkers are “signature” molecules of a disease process which are present in blood, other body fluids and body tissues and are often measured in non-invasively collected biofluids.<sup>19</sup> Blood soluble markers have the potential to provide a relatively non invasive, readily available, rapid and affordable method of determining neoplastic transformation in canine spirocercosis. The challenge is to identify a biomarker with a high sensitivity and specificity.<sup>19, 20</sup> The majority of biomarkers are non specific with a low sensitivity and specificity. In order to overcome the inherent shortcomings of the majority of biomarkers, the use of biomarker panels has shown an increased sensitivity and specificity at distinguishing between controls and diseased individuals. Prolactin, insulin growth factor 1, leptin and osteopontin in a panel were able to distinguish between human patients with ovarian cancer and controls with a sensitivity and specificity of 95%.<sup>20</sup>

## 1.6 Biomarkers in canine spirocercosis

Different soluble biomarkers have been evaluated for their suitability in differentiating between non-neoplastic and neoplastic spirocercosis. The biomarkers evaluated include a panel of routine clinical chemistry parameters<sup>2, 6, 7</sup>, alkaline phosphatase (ALP)<sup>21</sup> and C-reactive protein (CRP).<sup>22</sup> The clinical pathological parameters that have been evaluated for possible use as biomarkers to determine neoplastic transformation in spirocercosis include haematocrit (HT), mean corpuscular volume (MCV), white blood cell count (WBC), mature neutrophil count, immature neutrophil count, monocyte count, eosinophil count, serum albumin and globulin.<sup>2, 6, 7</sup> Of these variables, anaemia, leucocytosis, hyperglobulinaemia, thrombocytosis, and eosinopaenia occurred more commonly in neoplastic cases.<sup>2, 6, 7</sup> These changes could be due to continual oesophageal injury and blood loss from the neoplastic neoplasm. They can also be associated with chronic disease, but paraneoplastic causes cannot be excluded. At best, they would be useful for increasing the index of suspicion for neoplastic transformation in a confirmed case of canine spirocercosis.<sup>2</sup>

Alkaline phosphatase is a membrane bound glycoprotein with three clinically significant isoforms in the dog namely bone, liver and corticosteroid induced.<sup>23</sup> Alkaline phosphatase has been found to be elevated in a variety of neoplastic conditions, especially appendicular osteosarcoma, where the bone-specific ALP isoenzyme is elevated.<sup>23-25</sup> Previous studies on spirocercosis have documented an increase in serum ALP in some cases with neoplastic spirocercosis.<sup>11, 26</sup> However in a retrospective study on a larger sample population (88 confirmed non-neoplastic and 32 confirmed neoplastic cases, in which other diseases that could influence serum ALP levels were excluded), there was no significant difference in the ALP levels between the two groups.<sup>21</sup> Based on these results, serum ALP could be used to differentiate between non-neoplastic and neoplastic spiorcercosis<sup>15</sup>. Further research

quantifying the different isoforms of ALP in the two groups may be beneficial in differentiating them. However, the determination of ALP isoforms may have a limited clinical value since the measurement of the different isoforms is not done routinely.

C-reactive protein is one of the major positive acute phase proteins in the dog and it is produced in response to infection and inflammation.<sup>27</sup> It is non-specific as it is part of the innate host response.<sup>27, 28</sup> Nonetheless, CRP has shown potential as a diagnostic, prognostic and disease monitoring marker in a variety of human neoplasms, namely Hodgkin's lymphoma, non-Hodgkin's lymphoma, and epithelial ovarian cancer amongst others.<sup>28</sup> In dogs, C-reactive protein has been shown to be elevated in multicentric lymphoma and was useful in predicting complete remission status in patients treated with cytotoxic drugs.<sup>28</sup> In order to determine if CRP could be used to determine neoplastic transformation in canine spirocercosis, CRP concentrations were compared between non-neoplastic, neoplastic and healthy control cases.<sup>22</sup> In addition six of the non-neoplastic cases had follow up serum samples which were collected after treatment had commenced. The mean CRP concentrations of the non-neoplastic and neoplastic cases were markedly higher compared to the normal range with no statistically significant difference in the CRP concentrations between neoplastic and non-neoplastic cases. The six follow up cases had significantly lower CRP concentrations on the convalescent serum samples. Thus, elevated serum CRP concentration cannot be used to differentiate between non-neoplastic and neoplastic *S. lupi* cases. Serial C-reactive protein concentrations can however potentially be used to monitor response to treatment in non-neoplastic spirocercosis cases. Serial CRP concentrations are only useful in cases where other diseases that could increase CRP concentrations are eliminated.

## **1.7 Biomarkers in tumour angiogenesis**

Angiogenesis is a fundamental process in tumour progression and metastasis. Tumour growth is dependent on angiogenesis to allow exchange of nutrients, oxygen and waste products once simple diffusion is no longer able to meet the needs of the rapidly dividing cell population.<sup>29</sup> Metastasis of tumours is dependant upon angiogenesis so that the neoplastic cells within a primary tumour can gain access to the circulation and also in order for the metastasized cells to grow within target organs. In the normal state, angiogenesis is a finely controlled process with a balance between proangiogenic factors and antiangiogenic factors. An angiogenic switch occurs in tumour tissue that grows beyond one cubic millimeter.<sup>30, 31</sup> The angiogenic switch occurs when local hypoxia within the growing tumour induces the expression of hypoxia-inducible transcription factor 1 (HIF-1). The HIF-1 leads to an increased production of proangiogenic factors.<sup>31</sup> Dysregulation of proangiogenic factors can lead to the development, progression and metastasis of tumours. The angiogenic factors can be measured in serum, plasma, body effusions and tissues and their concentrations may be of therapeutic and prognostic value in animals with neoplastic disease.<sup>32</sup> The proangiogenic factors that have been identified amongst others are basic fibroblast growth factor (bFGF), platelet derived growth factor (PDGF), vascular endothelial growth factor (VEGF) and insulin-like growth factor (IGF). Of these factors, VEGF is the most potent and specific factor that was identified.<sup>33</sup> The VEGF levels were demonstrated to be more likely detected in dogs with neoplasia as opposed to healthy dogs and those with non neoplastic conditions.<sup>32</sup>

## **1.8 Vascular endothelial growth factor**

Vascular endothelial growth factor is a homodimeric heparin binding protein that is one of the most potent pro-angiogenic factors described to date. It plays a role in embryo

angiogenesis and maintenance of the female reproductive tract,<sup>34-37</sup> inflammation and repair,<sup>38, 39</sup> and blood vessel function.<sup>40</sup> Hypoxia and hypoglycaemia are the major stimulators of VEGF expression. Hypoxia-induced production of VEGF is mediated by HIF-1.<sup>41, 42</sup> Cytokines may also modulate angiogenesis by regulating VEGF expression. Factors that can enhance VEGF production include tumour necrosis factor alpha (TNF $\alpha$ ),<sup>43, 44</sup> angiotensin II,<sup>45</sup> and transforming growth factor  $\beta$ (TGF  $\beta$ ).<sup>46</sup> Cells that have been shown to produce VEGF include activated T-cells,<sup>47</sup> platelets,<sup>48</sup> monocytes, macrophages,<sup>44</sup> fibroblastic and epithelial cells.<sup>46</sup>

Angiogenesis in neoplasia has been shown to be an independent prognostic marker associated with metastasis in several types of tumours and VEGF plays a major role in this process.<sup>49</sup> Vascular endothelial growth factor is a potent stimulator of angiogenesis, an inducer of endothelial cell migration as well as vascular permeability.<sup>50, 51</sup> It is the key mediator for angiogenesis in cancer, where it is upregulated by oncogenic expression and a variety of growth factors. VEGF has been reported to contribute to the high degree of vascularisation in malignant tumours as well as promote the progression of neoplasia.<sup>52</sup> It exerts its effects by binding to one of three tyrosine kinase receptors (VEGF receptors 1, 2 and 3).<sup>53</sup> Vascular endothelial growth factor is expressed in human tumours including breast carcinoma,<sup>54</sup> angiosarcoma<sup>55</sup> and lymphoma.<sup>56</sup> Plasma and serum VEGF is elevated in dogs with mammary gland tumours, seminomas, and a variety of other tumours.<sup>33</sup> In addition, tissue expression of VEGF has been documented in both the peri-tumour and tumoral regions in multiple canine soft tissue sarcomas including extraskeletal osteosarcoma, neoplastic peripheral nerve sheath tumour, haemangiosarcoma and liposarcoma.<sup>57</sup> Importantly, tissue levels of VEGF have been shown to be elevated in the *S. lupi*-induced nodule. Tissue expression progressively increases from the non-neoplastic to pre-neoplastic nodules with the highest levels being seen in the neoplastic nodules.<sup>58</sup> An increase in VEGF expression has been linked to an increased risk for

metastasis and a poorer prognosis in several human tumours.<sup>59</sup> In canine mammary tumours, circulating VEGF can be used as a prognostic indicator with higher serum and plasma concentrations in neoplastic tumours versus the non-neoplastic canine mammary gland tumours.<sup>32, 33</sup>

Since neoplastic transformation of tissue is associated with the growth of new blood vessels, and there has been a documented increase in tissue expression of VEGF in *S. lupi*-induced neoplasias,<sup>58</sup> it was expected that there would be an increase in serum or plasma VEGF concentrations in dogs that have neoplastic spirocercosis and hence aid in the determination of neoplastic transformation and ultimately the prognostication of canine spirocercosis.

## **1.6 Measurement of vascular endothelial growth factor**

There is some debate as to the optimal sample to be used for the measurement of VEGF for prognostication purposes. The aim is to use a sample that will closely represent what is going on at the tumour site. Vascular endothelial growth factor can be measured from plasma, serum and whole blood.<sup>60</sup> Plasma levels represent free circulating levels while serum levels also include VEGF that is released during the coagulation cascade.<sup>61</sup> Platelet activation leads to the release of VEGF from alpha granules within platelets and hence the assumption that serum samples may yield higher VEGF concentrations compared to plasma. Additionally, the concentration of VEGF per platelet has been shown to increase in correlation with the progression of neoplasia.<sup>62</sup> Previously, measurement of VEGF in dogs was done using a Quantikine Human VEGF Immunoassay (R&D systems Inc. Minneapolis) that was validated for use in dogs.<sup>63</sup> Recently, a Canine kit CAVE00 (R&D Systems Inc. Minneapolis) was introduced and is now available on the market. The new canine VEGF immunoassay kit (CAVE00) has been validated for use on serum, EDTA plasma and heparin plasma samples.

Our study objective was to measure serum and EDTA plasma VEGF levels in dogs that have spirocercosis-associated neoplastic transformation and to compare the levels to those without neoplastic transformation. A comparison between the EDTA plasma and serum levels will be carried out to try and determine which of the two will be an optimum sample.

## CHAPTER 2: Study objectives

### 2.1 Problem statement

There is need for a quick, objective and non invasive way of determining neoplastic transformation in canine spirocercosis. Measurement of VEGF concentrations in the circulation is non-invasive and potentially cheaper and therefore warranted investigation to show if it can differentiate neoplastic from non-neoplastic spirocercosis cases.

### 2.2 Research questions

1. Is there a difference in the serum and or plasma concentration of VEGF between dogs with non-neoplastic *S. lupi* nodules and those with neoplastic transformation of the nodule?
2. If there is a difference, is it possible to use levels of VEGF to determine neoplastic transformation in *S. lupi* infected dogs?
3. If VEGF levels can be used to determine neoplastic transformation, which sample, serum or plasma gives better results?

### 2.3 Hypothesis

- i. There is an increase in the concentrations of circulatory VEGF levels in dogs that have *S. lupi*-induced sarcomas.
- ii. The increase in VEGF levels in dogs with *S. lupi*-induced sarcomas can be used to differentiate between dogs with non-neoplastic *S. lupi* nodules and those with neoplastic transformation.



- iii. Plasma and serum VEGF levels in dogs with *S. lupi*-associated sarcomas have the same predictive value for neoplastic transformation.

## 2.4 Objectives

- i. To establish if VEGF can be used as a biomarker to determine neoplastic transformation of *S. lupi*-associated nodules. This will allow the clinician to make the most appropriate treatment and management decisions. Cost implications can also be set out from the start for the clients and a realistic prognosis can be offered.
- ii. To determine if plasma and serum VEGF levels have the same predictive value for neoplastic transformation of *S. lupi*-associated nodules

## 2.5 Benefits arising from the study

- i. The establishment of a biochemical marker that will be able to determine neoplastic transformation of the oesophageal nodule in *S. lupi* cases will help with overcoming the difficulties faced in obtaining a diagnostic biopsy sample from the nodule. Veterinarians will be in a position to prognosticate earlier in the disease process and institute appropriate treatment protocols.
- ii. The results of this study will aid further research on the pathogenesis of *S. lupi* associated sarcoma and hopefully open a window of understanding into the pathogenesis of neoplasia as a whole.

## CHAPTER 3: Materials and Methods

### 3.1 Model system

This study was a prospective, cross-sectional, observational study based on disease status (case-control).

### 3.2 Study population

Dogs presented to the OVAH and diagnosed with naturally acquired *S. lupi* infection were included into the study. These dogs were further divided into those with non-neoplastic (group A) and neoplastic (group B) spirocercosis. The control population was made up of healthy staff-owned and client-owned dogs. The study was approved by the institutional Animal Use and Care Committee (protocol number V039/08). This study was run concurrently with a pre-existing spirocercosis epidemiological study (V037/07). The dogs enrolled into this current study were also part of the epidemiological study and in addition had to meet the specific requirements of this study. The author was also actively involved in the epidemiological study.

### 3.3 Experimental design

#### Inclusion criteria

All dogs had to have a consent form signed by the owner (Appendices A and B) and each owner was furnished with an information sheet on canine spirocercosis (Appendix C).

### *Group A dogs*

This group included dogs that were diagnosed as with non-neoplastic *S. lupi* and no other concurrent disease. Haematology, serum chemistry (total serum protein, albumin, globulin, creatinine, and alkaline phosphatase) and abdominal ultrasound performed were performed in order to screen for the presence of concurrent disease.

Diagnosis of benign spirocercosis will have been made by one of the following criteria:

- A faecal float that is positive for *S. lupi* worm eggs
- Radiological signs consistent with *S. lupi* infection. The radiological signs noted were a combination of: a caudodorsal mediastinal mass, spondylitis of the caudal thoracic vertebrae and undulation of the lateral border of the descending aorta
- Visual identification of caudal oesophageal *S. lupi* masses by oesophageal endoscopy.

Classification of the mass as non-neoplastic was achieved by a different combinations of the following criteria:

- The oesophageal nodule had a typical smooth, non-neoplastic appearance on endoscopy and response to treatment was shown by a reduction in the size on endoscopy six weeks after initiation of treatment
- Histopathological evaluation of the entire oesophageal nodule with no evidence of neoplastic transformation. The samples were obtained by surgical excision or necropsy.

### *Group B dogs*

The dogs in this group were diagnosed with *S. lupi*-associated neoplasia and no other concurrent disease. Haematology, serum biochemistry (total serum protein, albumin,

globulin, creatinine, and alkaline phosphatase) and abdominal ultrasound were performed in order to exclude the presence concurrent disease.

Diagnosis of spirocercosis was achieved using the same criteria as for group A. Classification of the mass as neoplastic was achieved through histopathological diagnosis. The samples for histopathology were obtained by one of the following methods: endoscopy guided biopsy sample, surgical excision of the mass or at necropsy.

#### *Group C dogs*

This group comprised of normal healthy dogs without *S. lupi* infection or any other concurrent diseases. The following criteria were met:

- Physical examination findings within normal parameters (temperature, pulse, respiration, thoracic auscultation, and abdominal examination)
- No radiological evidence of *S. lupi* infection or any other thoracic pathology
- A negative faecal float for *S. lupi* worm eggs
- Urinalysis results within normal limits (urine specific gravity, urine dipstick evaluation and urine sediment evaluation)
- Normal haematology and serum chemistry (total serum protein, albumin, globulin, creatinine, and alkaline phosphatase)
- An abdominal ultrasound scan within normal limits.

### **3.4 Experimental procedure**

At admission, a full physical examination was performed on all the dogs.

### *Radiographic views*

Four thoracic radiographs were taken for dogs assigned to groups A and B: dorsoventral, ventrodorsal, left and right lateral recumbent views. The radiographs were assessed for spondylitis of the ventral bodies of the caudal thoracic vertebrae, an undulating aorta, and mass effect in the caudodorsal mediastinum. Two thoracic radiographic views (right lateral recumbent and a ventrodorsal) were taken from dogs in group C to assess for radiographic evidence of *S. lupi* infection and any other thoracic pathology.

### *Oesophageal endoscopy*

Oesophageal endoscopy was performed on dogs in groups A and B when they were enrolled into the study. The length of the nodules was measured using the scale that appears on the endoscope. The degree of the oesophageal lumen obstructed by the nodule was estimated as a percentage of the oesophageal lumen. The surface appearance of the nodule/s was also noted. The form on appendix D was used to record the endoscopic findings. The decision for the anaesthetic protocol to be used was left up to the clinician performing the endoscopy.

### *Sample collection processing and storage for all groups*

Blood samples were collected at presentation from each dog. The blood was collected by routine venipuncture from either the jugular or cephalic veins and immediately transferred into 4ml ethylenediaminetetraacetic acid (EDTA) and plain plastic tubes (Vacutainer™, BD Vacutainer Systems, Plymouth, UK). The plain tube samples were left to clot for between 1 ½ and 2 hours and the spun down to separate the red blood cells and plasma and divided into two aliquots. One aliquot was used for performing serum chemistry (total serum protein, albumin, globulin, and alkaline phosphatase) and the other was stored at -80°C until analysis for VEGF was performed.

The EDTA sample was also divided into two aliquots. One aliquot was used for running haematology and the other was spun down within 30 minutes to separate the plasma from the red blood cells. The plasma was stored at  $-80^{\circ}\text{C}$  until analysis for VEGF was performed.

The VEGF samples were analysed as a batch when an adequate sample size had been obtained.

### **3.5 Vascular endothelial growth factor analysis**

Measurement of VEGF was performed using a canine VEGF Quantikine ELISA kit, CAVE00 (R&D Systems Inc, Minneapolis, USA). Vascular endothelial growth factor in  $100\mu\text{l}$  of serum or plasma was determined using a quantitative sandwich enzyme immunoassay technique according to the manufacturer's guidelines. The system used a solid phase monoclonal antibody and an enzyme-linked polyclonal antibody against canine VEGF. All analysis and calibrations were performed in triplicate. Optical densities were determined by using a microtiter plate reader (BioTek 800-BioTek, Bad Friedrichshall, Germany) at 450 nm. A standard curve was created using Gen 5 software (BioTek Bad Friedrichshall, Germany).

### **3.6 Statistical analysis**

The data obtained was captured onto a spread sheet on Microsoft excel spreadsheet (Microsoft Office Excel 2007 for Windows, Microsoft Inc., Redmond, WA), The data did not have a normal distribution based on the Kolmogorov-Smirnov test (SPSS software, SPSS 17.0 for Microsoft Windows, SPSS Inc., Chicago, IL). Statistical analysis to compare the VEGF concentrations in the different groups was performed using the Kruskal-Wallis with Dunn's post hoc test (GraphPad Prism 5 for windows, version 5.04, GraphPad Software, Inc,

La Jolla California USA, [www.graphpad.com](http://www.graphpad.com)). A p value of  $< 0.05$  was considered significant for all tests.

## CHAPTER 4: Results

### 4.1 Number of dogs included in the study

A total of 24 dogs were enrolled into the study. Of these, 18 dogs had naturally occurring canine spirocercosis, with 9 being classified as having non-neoplastic spirocercosis and the other 9 as having neoplastic spirocercosis. The remaining 6 dogs were healthy staff and client owned dogs. The neoplasms in the neoplastic group were osteosarcoma (8), fibrosarcoma (1). There was no significant difference in the mean ages of the non-neoplastic ( $4.4 \pm 2.5$  years) (mean $\pm$ SD) and neoplastic ( $5.3 \pm 1.4$  years) and control ( $4.1 \pm 1.4$  years) cases. (Table 1)

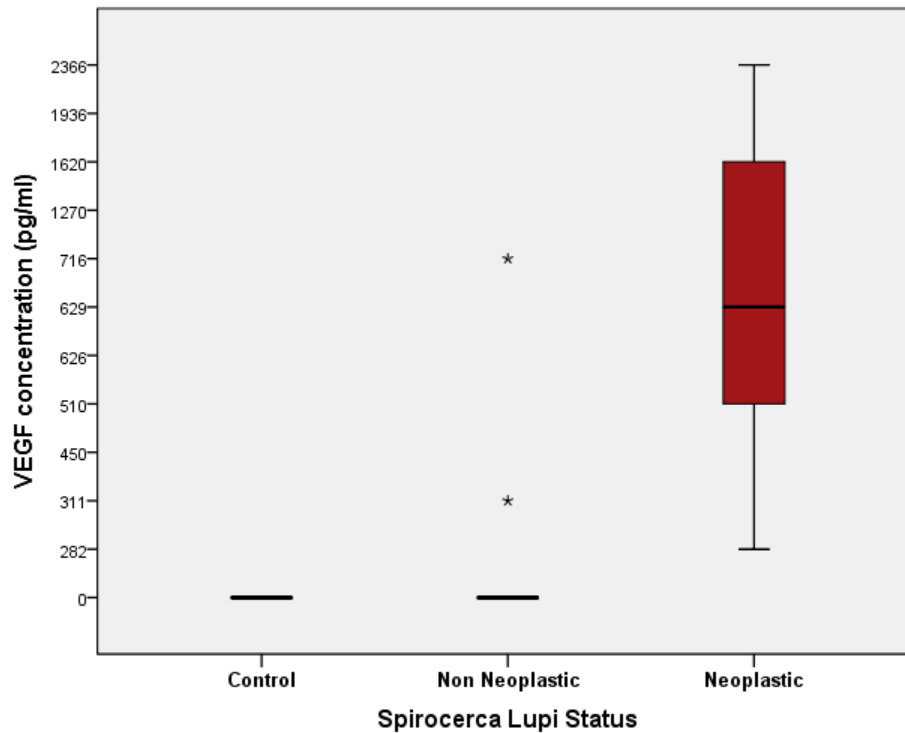
Parameter	Non-neoplastic		Neoplastic		Controls	
	Male	Female	Male	Female	Male	Female
Gender	4	5	5	4	4	2
Age	$4.4 \pm 2.5$		$5.3 \pm 1.4$		$4.1 \pm 1.4$	

**Table 1:** Gender and age distribution in the control, non-neoplastic and neoplastic groups

### 4.2 Plasma VEGF concentrations

The median plasma VEGF concentrations of the control, non-neoplastic and neoplastic groups were 0pg/ml (range 0 – 0), 0pg/ml (range 0 – 716) and 629pg/ml (range 282 – 2366), respectively. There was an overall difference in the plasma VEGF concentrations of the control, non-neoplastic and neoplastic groups ( $p = 0.0003$ ) (Figure 1). The plasma VEGF concentration of the neoplastic group was significantly higher than that of both the control ( $p < 0.001$ ) and non-neoplastic groups ( $p < 0.01$ ). There was no difference in the plasma VEGF concentrations of the control and non-neoplastic groups ( $p > 0.05$ ).





**Figure 1:** Box and whisker plot representing plasma VEGF concentrations in control, non-neoplastic and neoplastic dogs. The box represents the 25<sup>th</sup> – 75<sup>th</sup> percentile range, the horizontal line through the box represents the median and the outliers are represented by an asterisk.

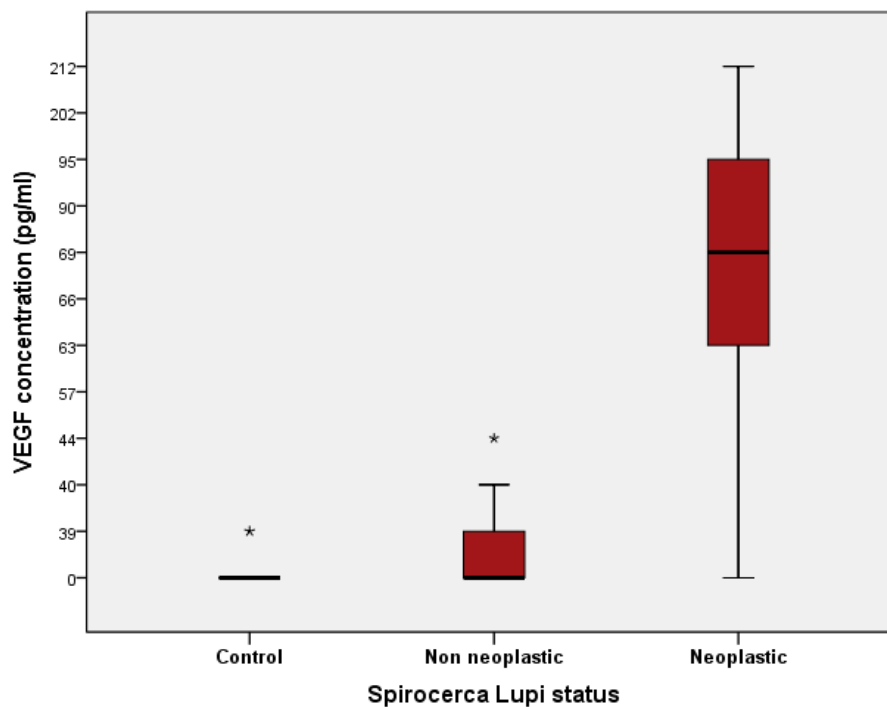
A cut off value of 250pg/ml was set in order to determine the sensitivity, specificity, positive predictive value (PPV) and negative predictive value (NPV) of plasma VEGF concentrations as a determinant for neoplastic transformation. Plasma VEGF was determined to have a sensitivity of 100%, specificity of 77.8%, a PPV of 81.8% and a NPV of 100%. (Table 2).

		Neoplastic spirocercosis	Non-neoplastic spirocercosis	Total
Test(plasma VEGF)	>250pg/ml	9	2	11
	≤250pg/ml	0	7	7
Total		9	9	
Sensitivity = $9/9 = 100\%$				
Specificity = $7/9 = 77.8\%$				
Positive predictive value = $9/11 = 81.8\%$				
Negative predictive value = $7/7 = 100\%$				

**Table 2:** Sensitivity, specificity, PPV and NPV of plasma VEGF concentrations for determining neoplastic transformation in canine spirocercosis using plasma VEGF concentrations

### 4.3 Serum VEGF concentrations

The median serum VEGF concentrations of the control, non-neoplastic and neoplastic groups were 0pg/ml(range 0 – 39.4), 0pg/ml (range 0 – 44.13) and 69pg/ml (range 0 – 212) respectively. There was an overall difference in the serum VEGF concentrations of the control, non-neoplastic and neoplastic groups ( $p = 0.001$ ) (Figure 2). The serum VEGF concentration of the neoplastic group was significantly higher than that of both the control ( $p < 0.01$ ) and non-neoplastic groups ( $p < 0.01$ ). There was no difference in the serum VEGF concentration of the control and non-neoplastic groups ( $p > 0.05$ ).



**Figure 2: Box and whisker plot representing** serum VEGF concentrations in control, non-neoplastic and neoplastic dogs. The box represents the 25<sup>th</sup> – 75<sup>th</sup> percentile range, the horizontal line through the box represents the median and the outliers are represented by an asterix

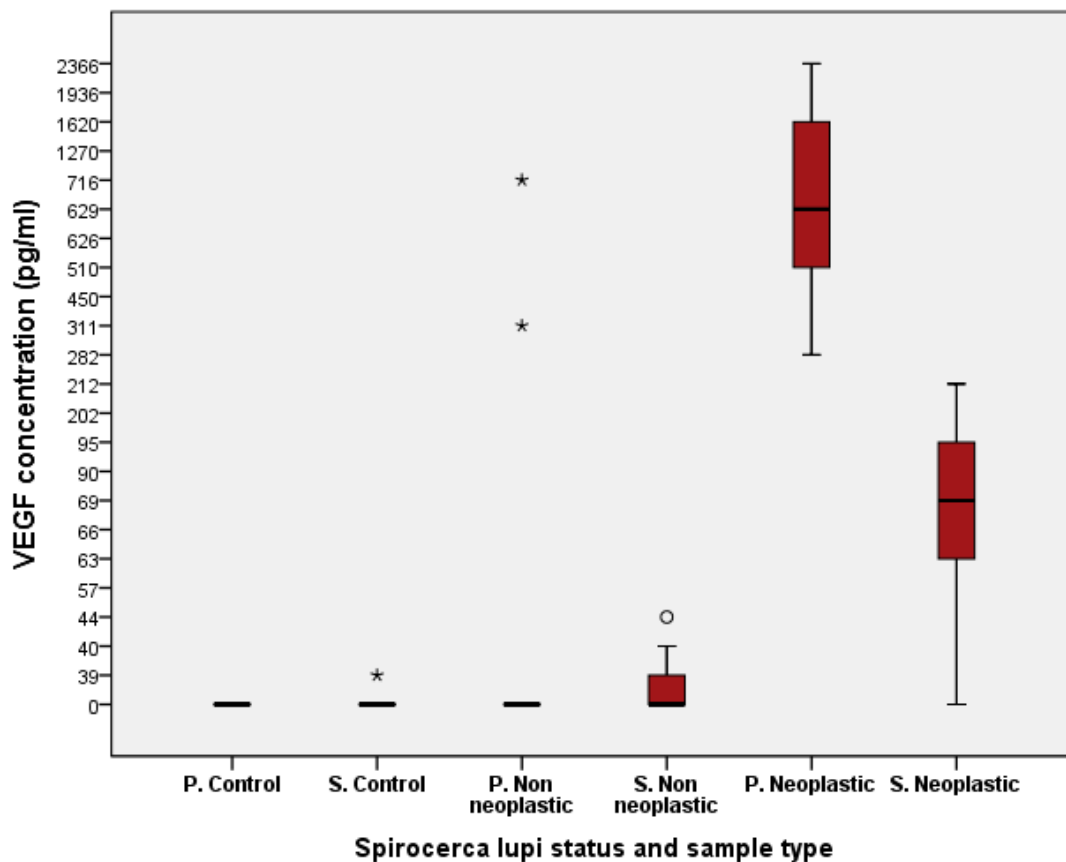
A cut off value of 25pg/ml was set in order to determine the sensitivity, specificity, positive predictive value (PPV) and negative predictive value (NPV) of serum VEGF concentrations as a determinant for neoplastic transformation. Serum VEGF was determined to have a sensitivity of 88.9%, specificity of 100%, a PPV of 100% and a NPV of 90%. (Table 3)

		Neoplastic spirocercosis	Non-neoplastic spirocercosis	Total
Test(Serum VEGF)	>25pg/ml	8	0	8
	≤25pg/ml	1	9	10
Total		9	9	
Sensitivity = $8/9 = 88.9\%$				
Specificity = $9/9 = 100\%$				
Positive predictive value = $8/8 = 100\%$				
Negative predictive value = $9/10 = 90\%$				

**Table 3:** Sensitivity, specificity, PPV and NPV of serum VEGF concentrations for determining neoplastic transformation in canine spirocercosis using serum VEGF concentrations

#### 4.4 Plasma vs serum VEGF concentrations

The serum concentrations were generally consistently lower than the plasma concentrations in all three groups with a statistically significant difference between the samples in the neoplastic group,  $p < 0.01$ . (Figure 3)



**Figure 3:** Box and whisker plot representing serum and plasma concentrations in the control, neoplastic and non neoplastic cases. The box represents the 25<sup>th</sup> – 75<sup>th</sup> percentile range, the horizontal line through the box represents the median and the outliers are represented by an asterisk and circle

## CHAPTER 5: Discussion

While non-neoplastic spirocercosis can be easily treated with early diagnosis, neoplastic spirocercosis often has a poor long term prognosis and requires expensive and invasive diagnostic as well as treatment options. This study aimed to identify a non invasive and relatively inexpensive method of making an expedient determination of neoplastic transformation in canine spirocercosis.

Both plasma and serum VEGF concentrations were significantly higher in dogs with neoplastic spirocercosis compared to non-neoplastic and control groups. Plasma VEGF concentrations were generally higher than serum VEGF concentrations. Plasma VEGF had a higher sensitivity (100%) than serum (88.9%) for determining neoplastic transformation. The implications of this would be that the use of plasma for the determination of neoplastic transformation would detect all dogs with neoplastic transformation including some false positives. This can be both an advantage and disadvantage of using plasma VEGF concentrations for neoplastic determination. It would be an advantage in that dogs that are likely to have neoplastic transformation are all identified and hence improving their chances of being treated appropriately. It would be a potential disadvantage because elevated plasma VEGF concentrations could mean that a dog is prematurely euthanised due to perceived poor prognosis. In order to avoid the latter scenario, one would have to perform further confirmatory tests such as biopsy and histopathology. These sensitivity and specificity values would need to be reproduced on a larger population of dogs. In addition, the cut off values would also need to be re-evaluated on a larger population of dogs.

The tissue expression of VEGF and bFGF have been proven to be higher in *S. lupi*-induced sarcoma compared to non-neoplastic nodules and normal dogs.<sup>33</sup> The results from this study show that in addition to the increased tissue expression proven earlier, there is a

corresponding increase in circulatory VEGF. It would be worthwhile to measure the levels of bFGF in the blood in order to determine if there is a corresponding circulatory increase as there is for VEGF.

Vascular endothelial growth factor can potentially be used to differentiate between neoplastic and non-neoplastic spirocercosis with higher concentrations being associated with malignancy. It is worthwhile noting that VEGF is produced in other neoplasms<sup>64</sup> and hence a thorough evaluation for concurrent neoplastic disease is warranted.

Apart from its possible role in prognostication, VEGF may play a role in the treatment of *S. lupi* induced sarcomas. Anti-angiogenic therapy has become an additional pillar in the treatment of various human malignancies including melanoma<sup>65, 66</sup>, and is considered as a basic standard of care in combination with other therapies in colorectal cancer.<sup>67</sup> The principles behind anti-VEGF therapy mostly inhibit the binding of VEGF to its receptors. These treatments include neutralising antibodies to either the ligand or receptor and small molecule inhibitors directed against the tyrosine kinase activity of VEGF receptors.<sup>53</sup> Examples of these drugs include the monoclonal antibody, bevacizumab, and the kinase inhibitors sorafenib and cediranib.<sup>68</sup> Bevacizumab was the first VEGF targeting monoclonal antibody to be officially approved for cancer therapy. It demonstrated survival benefits in humans with metastatic colon cancer when combined with conventional chemotherapy.<sup>69</sup> Although bevacizumab was designed to inhibit human VEGF, the great degree of homology between canine and human VEGF prompted trials to ascertain efficacy on canine neoplasms.<sup>70</sup> It must be noted that the current cost of bevacizumab is prohibitive for use in most veterinary patients.

Previous reports of the differences in plasma and serum VEGF concentrations suggest that plasma VEGF concentrations are consistently lower than those obtained in serum.<sup>71, 72</sup> This is

speculated to be as a result of the release of VEGF from platelet alpha granules upon activation of coagulation cascade.<sup>73</sup> Additionally, it has been suggested that the VEGF concentration per platelet increases with tumour progression thereby suggesting that higher platelet numbers would lead to higher serum VEGF concentrations.<sup>74</sup> The clinical implication of the latter part was made questionable because of the study carried out by Gentilini, showing a lack of statistical correlation between platelet numbers and serum VEGF concentrations.<sup>62</sup>

Contrary to other published reports, plasma samples yielded consistently higher VEGF concentrations compared to serum samples. Though plasma concentrations were on average ten times higher than the serum levels, there was a good correlation between the ability of both plasma and serum at being able to identify neoplastic and non neoplastic cases in this study. This implies that either plasma or serum VEGF concentrations can be used to differentiate between the two groups as long sample consistency is maintained. The plasma and serum samples for this study were run as batches on two separate dates. This may have introduced some inter-assay variability resulting in the consistently lower serum VEGF concentrations.

There is some controversy in the literature with regards to the stability of VEGF in storage as well as with repeated freeze-thaw cycles. Salven et al showed that VEGF in serum was stable after a single freeze-thaw cycle.<sup>75</sup> Unfortunately, the storage time and the temperature at which the serum samples were stored were not mentioned. Recently, serum VEGF has been shown to be unstable when subjected to repeated freeze/thaw cycles leading to a rapid decrease in VEGF concentrations.<sup>76</sup> This finding may explain the lower serum VEGF concentrations observed in this study. No similar studies on plasma VEGF concentration

could be identified. It remains to be determined whether plasma VEGF is more stable under storage and repeated freeze/thaw cycles compared to serum.

## **5.2 Weaknesses of the study**

This study serves as a proof of concept for the potential use of VEGF as a marker for neoplastic transformation in *S. lupi*. The study would need to be repeated on a larger population of dogs in order to allow for the establishment of a cut off value with a high sensitivity and specificity for the diagnosis of neoplastic transformation in canine spirocercosis. The small sample size and multiple values of 0pg/ml in the non-neoplastic group precluded the generation of Receiver operator curves (ROC). This would have allowed a more accurate determination of the ideal plasma and serum cut off values for neoplastic transformation.

## **5.3 Future studies**

A previous study by Dvir et al was able to prove that there are elevated tissue levels of VEGF amongst other growth factors in *S. lupi*-induced sarcomas.<sup>58</sup> This current study has shown that there are elevated levels of circulating VEGF. Vascular endothelial growth factor can be produced by the majority of cells in the body including anchorage type cells such as vascular smooth muscle,<sup>77</sup> and circulatory cells such as macrophages,<sup>78</sup> platelets<sup>79</sup> T lymphocytes,<sup>80</sup> mononuclear cells<sup>81</sup> and polymorphonuclear cells.<sup>82</sup> It is now necessary to determine the source of the VEGF, the trigger for its secretion and if it has any other function in the neoplastic transformation in canine spirocercosis apart from its known angiogenic properties.

The stimulation for the VEGF secretion can be the well described hypoxia within the developing tumour, but it cannot be excluded that the worm itself secretes a product that stimulate growth factor synthesis and secretion. These questions warrant further investigation.

The importance of VEGF in the progression and spread of neoplastic disease makes it an important target for cancer treatment. Future studies evaluating the therapeutic benefit of antagonists of VEGF and its receptors in canine spirocercosis in combination with more traditional treatment modalities such as surgical excision and chemotherapy is warranted. In certain human neoplastic disease such as ovarian,<sup>83</sup> colorectal<sup>84</sup> and renal-cell<sup>85</sup> cancers amongst others, single nucleotide polymorphisms (SNPs) in the VEGF gene have been identified as having treatment predictive and prognostic value. It would be worthwhile to assess the genetic variation of the VEGF gene in dogs with neoplastic spirocercosis in order to determine if there is any association with prognosis.



## **CHAPTER 6: Conclusion**

Vascular endothelial growth factor is a promising biomarker for neoplastic transformation in canine spirocercosis. This study serves as a basis for the evaluation of VEGF in a larger population. The study also justifies evaluating anti VEGF therapy in conjunction with surgical excision and chemotherapy in the treatment of dogs with neoplastic spirocercosis.

## References

1. Bailey WS. Spirocerca-associated esophageal sarcomas. *J Am Vet Med Assoc.* 1979;175:148-150.
2. Dvir E, Kirberger RM, Mukorera V, van der Merwe LL, Clift SJ. Clinical differentiation between dogs with benign and malignant spirocercosis. *Vet Parasitol.* 2008;155:80-88.
3. van der Merwe LL, Kirberger RM, Clift S, Williams M, Keller N, Naidoo V. Spirocerca lupi infection in the dog: a review. *Vet J.* 2008;176:294-309.
4. Dvir E, Clift SJ, Williams MC. Proposed histological progression of the Spirocerca lupi-induced oesophageal lesion in dogs. *Vet Parasitol.* 2010;168:71-77.
5. Dvir E, Kirberger RM, Malleczek D. Radiographic and computed tomographic changes and clinical presentation of spirocercosis in the dog. *Vet Radiol Ultrasound.* 2001;42:119-129.
6. Mazaki-Tovi M, Baneth G, Aroch I, et al. Canine spirocercosis: clinical, diagnostic, pathologic, and epidemiologic characteristics. *Vet Parasitol.* 2002;107:235-250.
7. Mylonakis ME, Rallis T, Koutinas AF, et al. Clinical signs and clinicopathologic abnormalities in dogs with clinical spirocercosis: 39 cases (1996-2004). *J Am Vet Med Assoc.* 2006;228:1063-1067.
8. SEIBOLD HR, BAILEY WS, HOERLEIN BF, JORDAN EM, SCHWABE CW. Observations on the possible relation of malignant esophageal tumors and Spirocerca lupi lesions in the dog. *Am J Vet Res.* 1955;16:5-14.

9. Lavy E, Aroch I, Bark H, et al. Evaluation of doramectin for the treatment of experimental canine spirocercosis. *Vet Parasitol.* 2002;109:65-73.
10. Kelly PJ, Fisher M, Lucas H, Krecek RC. Treatment of esophageal spirocercosis with milbemycin oxime. *Vet Parasitol.* 2008;156:358-360.
11. Ranen E, Lavy E, Aizenberg I, Perl S, Harrus S. Spirocercosis-associated esophageal sarcomas in dogs. A retrospective study of 17 cases (1997-2003). *Vet Parasitol.* 2004;119:209-221.
12. Chai O, Shelef I, Brenner O, Dogadkin O, Aroch I, Shamir MH. Magnetic resonance imaging findings of spinal intramedullary spirocercosis. *Vet Radiol Ultrasound.* 2008;49:456-459.
13. Du Plessis CJ, Keller N, Millward IR. Aberrant extradural spinal migration of *Spirocerca lupi*: four dogs. *J Small Anim Pract.* 2007;48:275-278.
14. Lobetti RG. Survey of the incidence, diagnosis, clinical manifestations and treatment of *Spirocerca lupi* in South Africa. *J S Afr Vet Assoc.* 2000;71:43-46.
15. Christie J, Schwan EV, Bodenstein LL, Sommerville JE, van der Merwe LL. The sensitivity of direct faecal examination, direct faecal flotation, modified centrifugal faecal flotation and centrifugal sedimentation/flotation in the diagnosis of canine spirocercosis. *J S Afr Vet Assoc.* 2011;82:71-75.
16. Kirberger RM, Dvir E, van der Merwe LL. The effect of positioning on the radiographic appearance of caudodorsal mediastinal masses in the dog. *Vet Radiol Ultrasound.* 2009;50:630-634.

17. Naylor S. Biomarkers: current perspectives and future prospects. *Expert Rev Mol Diagn.* 2003;3:525-529.
18. Katz R. Biomarkers and Surrogate Markers: An FDA Perspective. *Journal of the American Society for experimental neurotherapeutics.* 2004;1:189-185.
19. Polanski M, Anderson NL. A list of candidate cancer biomarkers for targeted proteomics. *Biomark Insights.* 2007;1:1-48.
20. Mor G, Visintin I, Lai Y, et al. Serum protein markers for early detection of ovarian cancer. *Proc Natl Acad Sci U S A.* 2005;102:7677-7682.
21. Mukorera V, van der Merwe LL, Lavy E, Aroch I, Dvir E. Serum alkaline phosphatase activity is not a marker for neoplastic transformation of esophageal nodules in canine spirocercosis. *Vet Clin Pathol.* 2011;40:389-392.
22. Mukorera V, Dvir E, van der Merwe LL, Goddard A. Serum C-reactive protein concentration in benign and malignant canine spirocercosis. *J Vet Intern Med.* 2011;25:963-966.
23. Fernandez NJ, Kidney BA. Alkaline phosphatase: beyond the liver. *Vet Clin Pathol.* 2007;36:223-233.
24. Garzotto CK, Berg J, Hoffmann WE, Rand WM. Prognostic significance of serum alkaline phosphatase activity in canine appendicular osteosarcoma. *J Vet Intern Med.* 2000;14:587-592.

25. Karayannopoulou M, Koutinas AF, Polizopoulou ZS, et al. Total serum alkaline phosphatase activity in dogs with mammary neoplasms: a prospective study on 79 natural cases. *J Vet Med A Physiol Pathol Clin Med.* 2003;50:501-505.
26. Mylonakis ME, Rallis T, Koutinas AF. Canine spirocercosis. *Compend Contin Educ Vet.* 2008;30:111-116.
27. Ceron JJ, Eckersall PD, Martynez-Subiela S. Acute phase proteins in dogs and cats: current knowledge and future perspectives. *Vet Clin Pathol.* 2005;34:85-99.
28. Nielsen L, Toft N, Eckersall PD, Mellor DJ, Morris JS. Serum C-reactive protein concentration as an indicator of remission status in dogs with multicentric lymphoma. *J Vet Intern Med.* 2007;21:1231-1236.
29. Weidner N. Current pathologic methods for measuring intratumoral microvessel density within breast carcinoma and other solid tumors. *Breast Cancer Res Treat.* 1995;36:169-180.
30. Cuenod CA, Fournier L, Balvay D, Guinebretiere JM. Tumor angiogenesis: pathophysiology and implications for contrast-enhanced MRI and CT assessment. *Abdom Imaging.* 2006;31:188-193.
31. Pradeep CR, Sunila ES, Kuttan G. Expression of vascular endothelial growth factor (VEGF) and VEGF receptors in tumor angiogenesis and malignancies. *Integr Cancer Ther.* 2005;4:315-321.
32. Troy GC, Huckle WR, Rossmeisl JH, et al. Endostatin and vascular endothelial growth factor concentrations in healthy dogs, dogs with selected neoplasia, and dogs with nonneoplastic diseases. *J Vet Intern Med.* 2006;20:144-150.

33. Kato Y, Asano K, Mogi T, et al. Clinical significance of circulating vascular endothelial growth factor in dogs with mammary gland tumors. *J Vet Med Sci.* 2007;69:77-80.
34. Licht AH, Muller-Holtkamp F, Flamme I, Breier G. Inhibition of hypoxia-inducible factor activity in endothelial cells disrupts embryonic cardiovascular development. *Blood.* 2006;107:584-590.
35. Flamme I, Breier G, Risau W. Vascular endothelial growth factor (VEGF) and VEGF receptor 2 (flk-1) are expressed during vasculogenesis and vascular differentiation in the quail embryo. *Dev Biol.* 1995;169:699-712.
36. Cheung CY, Singh M, Ebaugh MJ, Brace RA. Vascular endothelial growth factor gene expression in ovine placenta and fetal membranes. *Am J Obstet Gynecol.* 1995;173:753-759.
37. Chakraborty I, Das SK, Dey SK. Differential expression of vascular endothelial growth factor and its receptor mRNAs in the mouse uterus around the time of implantation. *J Endocrinol.* 1995;147:339-352.
38. Paleolog EM, Miotla JM. Angiogenesis in arthritis: role in disease pathogenesis and as a potential therapeutic target. *Angiogenesis.* 1998;2:295-307.
39. Deodato B, Arsic N, Zentilin L, et al. Recombinant AAV vector encoding human VEGF165 enhances wound healing. *Gene Ther.* 2002;9:777-785.
40. Connolly DT. Vascular permeability factor: a unique regulator of blood vessel function. *J Cell Biochem.* 1991;47:219-223.
41. Shweiki D, Itin A, Soffer D, Keshet E. Vascular endothelial growth factor induced by hypoxia may mediate hypoxia-initiated angiogenesis. *Nature.* 1992;359:843-845.

42. Nomura M, Yamagishi S, Harada S, et al. Possible participation of autocrine and paracrine vascular endothelial growth factors in hypoxia-induced proliferation of endothelial cells and pericytes. *J Biol Chem.* 1995;270:28316-28324.
43. Ryuto M, Ono M, Izumi H, et al. Induction of vascular endothelial growth factor by tumor necrosis factor alpha in human glioma cells. Possible roles of SP-1. *J Biol Chem.* 1996;271:28220-28228.
44. Haneda Y, Hasegawa S, Hirano R, Hashimoto K, Ohsaki A, Ichiyama T. Leukotriene D4 enhances tumor necrosis factor-alpha-induced vascular endothelial growth factor production in human monocytes/macrophages. *Cytokine.* 2011;55:24-28.
45. Feliars D, Gorin Y, Ghosh-Choudhury G, Abboud HE, Kasinath BS. Angiotensin II stimulation of VEGF mRNA translation requires production of reactive oxygen species. *Am J Physiol Renal Physiol.* 2006;290:F927-36.
46. Pertovaara L, Kaipainen A, Mustonen T, et al. Vascular endothelial growth factor is induced in response to transforming growth factor-beta in fibroblastic and epithelial cells. *J Biol Chem.* 1994;269:6271-6274.
47. Mor F, Quintana FJ, Cohen IR. Angiogenesis-inflammation cross-talk: vascular endothelial growth factor is secreted by activated T cells and induces Th1 polarization. *J Immunol.* 2004;172:4618-4623.
48. Gunsilius E, Petzer A, Stockhammer G, et al. Thrombocytes are the major source for soluble vascular endothelial growth factor in peripheral blood. *Oncology.* 2000;58:169-174.
49. O'Brien T, Cranston D, Fuggle S, Bicknell R, Harris AL. Different angiogenic pathways characterize superficial and invasive bladder cancer. *Cancer Res.* 1995;55:510-513.

50. Hattori K, Dias S, Heissig B, et al. Vascular endothelial growth factor and angiopoietin-1 stimulate postnatal hematopoiesis by recruitment of vasculogenic and hematopoietic stem cells. *J Exp Med.* 2001;193:1005-1014.
51. Dvorak HF, Brown LF, Detmar M, Dvorak AM. Vascular permeability factor/vascular endothelial growth factor, microvascular hyperpermeability, and angiogenesis. *Am J Pathol.* 1995;146:1029-1039.
52. Berger DP, Herbstritt L, Dengler WA, Marme D, Mertelsmann R, Fiebig HH. Vascular endothelial growth factor (VEGF) mRNA expression in human tumor models of different histologies. *Ann Oncol.* 1995;6:817-825.
53. Pircher A, Hilbe W, Heidegger I, Dreves J, Tichelli A, Medinger M. Biomarkers in tumor angiogenesis and anti-angiogenic therapy. *Int J Mol Sci.* 2011;12:7077-7099.
54. Lv M, Xiaoping X, Cai H, et al. Cytokines as prognostic tool in breast carcinoma. *Front Biosci.* 2011;17:2515-2526.
55. Park MS, Ravi V, Araujo DM. Inhibiting the VEGF-VEGFR pathway in angiosarcoma, epithelioid hemangioendothelioma, and hemangiopericytoma/solitary fibrous tumor. *Curr Opin Oncol.* 2010;22:351-355.
56. Jorgensen JM, Sorensen FB, Bendix K, et al. Expression level, tissue distribution pattern, and prognostic impact of vascular endothelial growth factors VEGF and VEGF-C and their receptors Flt-1, KDR, and Flt-4 in different subtypes of non-Hodgkin lymphomas. *Leuk Lymphoma.* 2009;50:1647-1660.



57. de Queiroz GF, Dagli ML, Fukumasu H, Zavala AA, Matera JM. Vascular endothelial growth factor expression and microvascular density in soft tissue sarcomas in dogs. *J Vet Diagn Invest.* 2010;22:105-108.
58. Dvir E, Clift SJ. Evaluation of selected growth factor expression in canine spirocercosis (*Spirocerca lupi*)-associated non-neoplastic nodules and sarcomas. *Vet Parasitol.* 2010;174:257-266.
59. Restucci B, Borzacchiello G, Maiolino P, Martano M, Paciello O, Papparella S. Expression of vascular endothelial growth factor receptor Flk-1 in canine mammary tumours. *J Comp Pathol.* 2004;130:99-104.
60. George ML, Eccles SA, Tutton MG, Abulafi AM, Swift RI. Correlation of plasma and serum vascular endothelial growth factor levels with platelet count in colorectal cancer: clinical evidence of platelet scavenging? *Clin Cancer Res.* 2000;6:3147-3152.
61. Hormbrey E, Gillespie P, Turner K, et al. A critical review of vascular endothelial growth factor (VEGF) analysis in peripheral blood: is the current literature meaningful? *Clin Exp Metastasis.* 2002;19:651-663.
62. Gentilini F, Calzolari C, Turba ME, et al. Prognostic value of serum vascular endothelial growth factor (VEGF) and plasma activity of matrix metalloproteinase (MMP) 2 and 9 in lymphoma-affected dogs. *Leuk Res.* 2005;29:1263-1269.
63. Rossmesl JH, Duncan RB, Huckle WR, Troy GC. Expression of vascular endothelial growth factor in tumors and plasma from dogs with primary intracranial neoplasms. *Am J Vet Res.* 2007;68:1239-1245.

64. Schmidt T, Carmeliet P. Angiogenesis: a target in solid tumors, also in leukemia? *Hematology Am Soc Hematol Educ Program*. 2011;2011:1-8.
65. Emmett MS, Dewing D, Pritchard-Jones RO. Angiogenesis and melanoma - from basic science to clinical trials. *Am J Cancer Res*. 2011;1:852-868.
66. Amini A, Masoumi Moghaddam S, Morris DL, Pourgholami MH. Utility of vascular endothelial growth factor inhibitors in the treatment of ovarian cancer: from concept to application. *J Oncol*. 2012;2012:540791.
67. Zhou Z, V. Walsh W, G. Bathini V, Piperdi B. Anti-VEGF and Anti-EGFR Monoclonal Antibodies in the First-line Therapy for Metastatic Colorectal Cancer - A Meta-Analysis. *Current Cancer Therapy Reviews*. 2011;7:282.
68. Pircher A, Hilbe W, Heidegger I, Drevs J, Tichelli A, Medinger M. Biomarkers in tumor angiogenesis and anti-angiogenic therapy. *Int J Mol Sci*. 2011;12:7077-7099.
69. Hurwitz H, Fehrenbacher L, Novotny W, et al. Bevacizumab plus irinotecan, fluorouracil, and leucovorin for metastatic colorectal cancer. *N Engl J Med*. 2004;350:2335-2342.
70. Biller BJ. Cancer immunotherapy for the veterinary patient. *Vet Clin North Am Small Anim Pract*. 2007;37:1137-49; vii.
71. Botelho F, Pina F, Lunet N. VEGF and prostatic cancer: a systematic review. *Eur J Cancer Prev*. 2010;19:385-392.
72. Ding S, Lin S, Dong X, et al. Potential prognostic value of circulating levels of vascular endothelial growth factor-A in patients with gastric cancer. *In Vivo*. 2005;19:793-795.

73. Caine GJ, Lip GY, Stonelake PS, Ryan P, Blann AD. Platelet activation, coagulation and angiogenesis in breast and prostate carcinoma. *Thromb Haemost.* 2004;92:185-190.
74. Caine GJ, Lip GY, Blann AD. Platelet-derived VEGF, Flt-1, angiopoietin-1 and P-selectin in breast and prostate cancer: further evidence for a role of platelets in tumour angiogenesis. *Ann Med.* 2004;36:273-277.
75. Salven P, Teerenhovi L, Joensuu H. A high pretreatment serum vascular endothelial growth factor concentration is associated with poor outcome in non-Hodgkin's lymphoma. *Blood.* 1997;90:3167-3172.
76. Kisand K, Kerna I, Kumm J, Jonsson H, Tamm A. Impact of cryopreservation on serum concentration of matrix metalloproteinases (MMP)-7, TIMP-1, vascular growth factors (VEGF) and VEGF-R2 in Biobank samples. *Clin Chem Lab Med.* 2011;49:229-235.
77. Koehne P, Willam C, Strauss E, Schindler R, Eckardt KU, Buhner C. Lack of hypoxic stimulation of VEGF secretion from neutrophils and platelets. *Am J Physiol Heart Circ Physiol.* 2000;279:H817-24.
78. Riazzy M, Chen JH, Steinbrecher UP. VEGF secretion by macrophages is stimulated by lipid and protein components of OxLDL via PI3-kinase and PKCzeta activation and is independent of OxLDL uptake. *Atherosclerosis.* 2009;204:47-54.
79. Mohle R, Green D, Moore MA, Nachman RL, Rafii S. Constitutive production and thrombin-induced release of vascular endothelial growth factor by human megakaryocytes and platelets. *Proc Natl Acad Sci U S A.* 1997;94:663-668.

80. Freeman MR, Schneck FX, Gagnon ML, et al. Peripheral blood T lymphocytes and lymphocytes infiltrating human cancers express vascular endothelial growth factor: a potential role for T cells in angiogenesis. *Cancer Res.* 1995;55:4140-4145.
81. Iijima K, Yoshikawa N, Connolly DT, Nakamura H. Human mesangial cells and peripheral blood mononuclear cells produce vascular permeability factor. *Kidney Int.* 1993;44:959-966.
82. Gaudry M, Bregerie O, Andrieu V, El Benna J, Pocidalo MA, Hakim J. Intracellular pool of vascular endothelial growth factor in human neutrophils. *Blood.* 1997;90:4153-4161.
83. Smerdel MP, Waldstrom M, Brandslund I, Steffensen KD, Andersen RF, Jakobsen A. Prognostic importance of vascular endothelial growth factor-A expression and vascular endothelial growth factor polymorphisms in epithelial ovarian cancer. *Int J Gynecol Cancer.* 2009;19:578-584.
84. Hansen TF, Christensen RD, Andersen RF, Spindler KL, Johnsson A, Jakobsen A. The predictive value of single nucleotide polymorphisms in the VEGF system to the efficacy of first-line treatment with bevacizumab plus chemotherapy in patients with metastatic colorectal cancer : Results from the Nordic ACT trial. *Int J Colorectal Dis.* 2011.
85. Garcia-Donas J, Esteban E, Leandro-Garcia LJ, et al. Single nucleotide polymorphism associations with response and toxic effects in patients with advanced renal-cell carcinoma treated with first-line sunitinib: a multicentre, observational, prospective study. *Lancet Oncol.* 2011;12:1143-1150.

## APPENDICES

### Appendix A: Client consent form for groups A and B

#### CLIENT CONSENT FORM:

Dear Client

Your pet \_\_\_\_\_ has been diagnosed with suspected Spirocercosis.

The incidence of this parasitic disease is increasing dramatically and we are trying to improve our ability to diagnose infection earlier in patients, determine if the nodule has become cancerous and determine the best form of treatment and prevention of infection.

To achieve these goals we would like to perform some additional procedures on your pet. These are listed below.

- A. Whilst under anaesthetic for oesophageal endoscopy (camera passed down the oesophagus), a routine procedure in these cases, we would like to take additional X-ray views whilst filling the oesophagus with air.
- B. We would need to perform an additional abdominal ultrasound (sonar scan) to evaluate the oesophageal nodule.
- C. We would wish to collect additional blood samples from your pet (< 20 ml of blood).

**The above-mentioned procedures hold no additional risk for your pet, the anaesthesia is just prolonged for approximately 20 minutes.**

**The abovementioned additional procedures will be subsidised by the Veterinary Faculty**

- D. If your pet undergoes therapy you will undertake to return for re-evaluation by means of endoscopy at a predetermined time-point. The costs for this routine follow up procedure will be calculated at cost of materials used only. The follow up evaluations are routine but often waived by the client due to an improvement in clinical signs, however this does not mean that your dog is healed. We have to

insist on a follow up evaluation, as it is vital to assess efficacy of treatment protocols.

- E. If at any stage you decide to put your pet to sleep due to poor prognosis for recovery or escalating costs we would request permission to perform a full post mortem examination (autopsy). Disposal options would be arranged as routinely done at the OVAH.

I Mr/Mrs/Ms/Dr/Prof/ \_\_\_\_\_

Hereby acknowledge that I have received the information brochure on spirocercosis in dogs and I hereby give permission for the additional tests mentioned from A-E to be performed on my pet \_\_\_\_\_ over the following 3 months.  
\_\_\_\_\_

Signed at: \_\_\_\_\_

Date: \_\_\_\_\_

Signature \_\_\_\_\_

Duty Clinician:      Print: \_\_\_\_\_

Sign: \_\_\_\_\_

## Appendix B: Consent form for vascular endothelial growth factor trial (Healthy dogs)

### Consent form for vascular endothelial growth factor trial (Healthy dogs)

*Spirocerca lupi* (*S. lupi*) is a worm that infects mainly dogs. The worm stays in nodules in the oesophagus from where it sheds eggs. The eggs are passed down the gastrointestinal tract and are passed out in the faeces. Dung beetles pick up the eggs when they feed on the faeces. The eggs develop to larvae inside the beetles. The beetles are eaten by other animals such as birds, lizards and hedgehogs. The larvae are passed from the beetles to the next animal in the food chain. Dogs get infected when they eat beetles with larvae or alternatively when they eat the other animals higher up in the food chain. When the dogs ingest animals with larvae, the larvae are released in the stomach. Once in the stomach, the larvae penetrate the wall of the stomach and migrate to the aorta through the gastric arteries. Once in the aorta, the larvae develop to immature adults. When the worms reach this stage of development, they move from the aorta to the wall of the oesophagus. In the wall of the oesophagus, a nodule forms around the adult worms. Sometimes as the nodule grows, it transforms into a tumour.

We are conducting a study to measure vascular endothelial growth factors in dogs that are infected with *Spirocerca lupi*. The aim of the study is to see if we can use the levels of vascular endothelial growth factors to pick up the dogs in which the nodules in which the worm resides have transformed into tumours. For this to be possible we need to be able to compare the levels of vascular endothelial growth factor in healthy dogs and *S. lupi* infected dogs. The healthy dogs chosen have to be free of *S. lupi* and any other accompanying illness. We therefore need to screen your pet for other diseases and *S. lupi*. This will be done by means of chest x-rays, faecal floatation and routine blood samples (for haematology and serum chemistry). This set of tests are offered to you free of charge and are very valuable to screen your dog for possible *S. lupi* manifestation and other disease.

After your pet had been screened, the same blood samples used for routine screening will be stored for further evaluation of VEGF. Please feel free to contact Dr V Mukorera on the following number should you have any further questions or queries.

**Office:** 012 529 8519

**SAM Clinics:** 012 529 8128/8096

**Cell:** 0839837684

**Email:** vari.mukorera@up.ac.za

I, (full name) \_\_\_\_\_ hereby give permission for  
the dog under my care (Dog's name) \_\_\_\_\_  
Breed \_\_\_\_\_ Age \_\_\_\_\_ Sex \_\_\_\_\_

To participate in the clinical study on vascular endothelial growth factor levels in *S. lupi* infected dogs at the Onderstepoort Veterinary Academic Hospital.

The trial has been explained to me and I understand that the study will in no way harm my dog and that the costs of additional testing will be borne by the trial fund.

Signed at \_\_\_\_\_ on the \_\_\_\_\_ day of

(month) \_\_\_\_\_ (year) \_\_\_\_\_

Signature of owner/authorised person \_\_\_\_\_

Home Tel \_\_\_\_\_

Office Tel \_\_\_\_\_

Cell \_\_\_\_\_



## **Appendix C: Client information brochure on spirocercosis (Groups A and B)**

### Client information brochure on spirocercosis

*Spirocerca lupi* is a worm which starts its lifecycle in the dung-beetle which contains infective larvae. Infective larvae are also found in animals which eat the dung beetles, such as mice, lizards and birds. Dogs become infested when eating either the beetle or the so-called transport hosts. The worm larvae are released by the process of digestion and move through the stomach wall from where they migrate via the walls of the major blood vessels to eventually reach the aorta, the largest blood vessel in the body. They then rest and grow to maturity here, a process which takes 100 days. Once mature they then migrate across the aortic wall towards the oesophagus, which lies in-between the lungs, together with the aorta, trachea and heart. Once the worms reach the oesophagus, they burrow into the wall and make a small nodule. Here they reach sexual maturity and start laying eggs. Each nodule can contain many worms. When the eggs are passed in the faeces, they once again infect the dung beetles

The worm causes disease in many ways: Fever, infection, lung infection, and rupture of the major blood vessels due to aneurysms, obstruction of the oesophagus due the nodule, intractable vomiting due to oesophageal irritation and eventual transformation of the nodule into a cancer with spread to the lungs.

There is, to date, no method of detecting infection with this parasite prior to it settling in the oesophagus and starting to pass eggs. These eggs can be detected in stool examinations but the test is not very sensitive, as the worms only pass very small eggs, intermittently. Once clinical signs of vomiting have been detected chest x-rays will often show a suspicious area behind the heart. Confirmation of the diagnosis is usually by passing an endoscope (camera) into the oesophagus and visualising the nodule. If there is a suspicion that the nodule may be cancerous a biopsy is taken. In complicated cases the diagnostic and treatment protocol are individualised.

Treatment is initiated and response to treatment is usually established by a follow up endoscopy after 48-56 days

**Appendix D: Spirocerca lupi patient endoscopy forms**

**SPIROCERCA LUPI PATIENT ENDOSCOPY FORMS:**

(NB – Only the video endoscope must be used to enable data capture)

Date: \_\_\_\_\_ Unique Patient no. \_\_\_\_\_

<b>Patient Sticker</b>
------------------------

Distance in cm: ( measured from canine tooth to cranial border of mass) \_\_\_\_\_

Appearance of nodules:

a) smooth (  ): 

Y	N
---	---

b) Cauliflower like : 

Y	N
---	---

Worms visible? \_\_\_\_\_

Length of nodules(cm): \_\_\_\_\_

(measure using distance to cranial pole at level of canine and subtract from distance to caudal pole from canine.)

Ulcerated ? 

Y	N
---	---

Necrosis? 

Y	N
---	---

Approximate % of insufflated oesophageal lumen compromised: \_\_\_\_\_

Biopsied? 

Y	N
---	---

Procedure recorded on the DVD:

Follow up Scoping dates:

(i) \_\_\_\_\_

(ii) \_\_\_\_\_

(iii) \_\_\_\_\_