

**THE PATHOLOGY OF TUBERCULOSIS,
CAUSED BY *Mycobacterium tuberculosis*,
IN A HERD OF SEMI FREE-RANGING
SPRINGBOK (*Antidorcas marsupialis*)**

By

TERTIUS A GOUS

Submitted in partial fulfillment of the requirements for the degree of
MASTER IN VETERINARY PATHOLOGY MMEDVET (PATH)
IN THE DEPARTMENT OF PARACLINICAL SCIENCES IN THE
FACULTY OF VETERINARY SCIENCE,
UNIVERSITY OF PRETORIA

Date Submitted: February 2007, Pretoria



DEDICATION

To Sumi



Detail from "Springbokke by Etosha" by Johan Grobler

ACKNOWLEDGEMENTS

I wish to express my sincere thanks and appreciation to the following people:

Drs. Gideon Brückner and James Kitching of the Directorate Veterinary Services, Western Cape Department of Agriculture (WCDA) for allowing me the use of the necropsy facilities at the Provincial Veterinary Laboratory (PVL), Stellenbosch. I am also extremely grateful to the WCDA for funding the mycobacterial cultures and interferon-gamma (INFg) assays.

Dr. Horst Kettner of the iThemba LABS Staff Environmental Club for organizing and assisting with the culling of the springbok.

Messers. Paul Slingers and Chrisjan Jantjes for their energetic after-hours assistance with the necropsies at the Stellenbosch PVL.

Mr. Adri Terblanche of the Stellenbosch PVL for assisting with the processing of the blood samples for the INFg assays.

Messers. Errol van Kerwel and André Meyer, and Me. Gwen du Plessis at PathCare's Somerset West laboratory for the processing, sectioning and staining of all the histopathological sections.

Dr. Anita Michel and her staff at the Tuberculosis Laboratory of the Onderstepoort Veterinary Institute (OVI) for performing the mycobacterial cultures and INFg assays.

Prof. Joop Boomker of the Department of Veterinary Tropical Diseases, Faculty of Veterinary Science, University of Pretoria for identification of the nematodes.

Dr. Lucia Lange, my partner at PathCare Vet Lab, for allowing me ample leave time to work on the project and for managing the laboratory in my absence.

My supervisor Prof. Mark Williams for his guidance, advice and patience during the course of this study.

My mother for her encouragement and support throughout my career.

And finally, but most importantly, Sumi for inspiration, encouragement, support and graphic design assistance.



TABLE OF CONTENTS

TOPIC	PAGE
Dedication	i
Acknowledgements	ii
Table of contents	iv
List of tables and figures	vi
Summary	ix
Opsomming	x
CHAPTER ONE	1
1.1 Introduction	1
1.2 Literature review	4
1.2.1 General overview of tuberculosis	4
1.2.2 Bovine tuberculosis in wildlife of sub-Saharan Africa	5
1.2.3 Human tuberculosis in wildlife	7
1.2.4 Tuberculosis in springbok	7
1.2.5 Pathology of tuberculosis	8
1.2.6 Diagnosis of tuberculosis	11
1.2.7 Tuberculosis at the human / animal interface	15
CHAPTER TWO	17
2.1 Material and methods	17
2.1.1 Part one: Index cases	17
2.1.1.1 Animals	17
2.1.1.2 Macroscopic and microscopic pathology	18
2.1.1.3 Bacteriology	18
2.1.2 Part two: Pilot study	20
2.1.2.1 Animals	20
2.1.2.2 Macroscopic and microscopic pathology	20
2.1.2.3 Bacteriology	22
2.1.2.4 Interferon-gamma (INFg) assay	23
2.1.3 Part three: Main study	25
2.1.3.1 Animals	25
2.1.3.2 Macroscopic and microscopic pathology	25
2.1.3.3 Bacteriology	26
2.1.3.4 Interferon-gamma (INFg) assay	27
CHAPTER THREE	28
3.1 Results	28
3.1.1 Part one: Index cases	28
3.1.1.1 Macroscopic and microscopic pathology	28
3.1.1.1.1 Macroscopic pathology	28
3.1.1.1.2 Microscopic pathology	31
3.1.1.2 Bacteriology	47
3.1.2 Part two: Pilot study	47



3.1.2.1	Macroscopic and microscopic pathology	47
3.1.2.1.1	Macroscopic pathology	47
3.1.2.1.2	Microscopic pathology	52
3.1.2.2	Bacteriology	67
3.1.2.3	INFg assay	67
3.1.3	Part three: Main study	68
3.1.3.1	Macroscopic and microscopic pathology	68
3.1.3.1.1	Macroscopic pathology	68
3.1.3.1.2	Microscopic pathology	73
3.1.3.2	Bacteriology	84
3.1.3.3	INFg assay	84
3.1.4	Summary of results	84
 CHAPTER FOUR		 98
4.1	Discussion	98
 REFERENCES		 110

LIST OF TABLES & FIGURES

TABLE		PAGE
Table 3.1	Summary of results	86
Table 3.2	Comparison of organs showing macroscopic and microscopic tuberculosis lesions, acid-fast bacilli and no lesions	87
Table 3.3	Summary of tuberculosis lesions in <i>Mycobacterium tuberculosis</i> culture-positive animals	92
FIGURE		
Fig. 1.1	Aerial view of iThemba LABS	2
Fig. 3.1	Springbok A1, lung. Necrogranulomas with central caseous necrosis and moderate calcification. H&E. 100x ...	32
Fig. 3.2.	Springbok A1, lung. Adult <i>B. magna</i> nematodes within a bronchiole (arrows). H&E. 20x	33
Fig. 3.3.	Springbok A1, lung. Acid-fast bacilli in macrophages along the edge of the caseous necrotic centre of a granuloma (arrows). ZN. 400x	34
Fig 3.4.	Springbok A1, mediastinal lymph node. Necrogranulomas with central caseous necrosis and prominent calcification. H&E. 40x	35
Fig. 3.5.	Springbok A1, mediastinal lymph node. Multinucleated giant cell of the foreign-body type (arrow). H&E. 200x	36
Fig. 3.6.	Springbok A1, mediastinal lymph node. Numerous acid-fast bacilli in macrophages within a granulomatous lesion (arrow). ZN. 400x	37
Fig. 3.7.	Springbok A1, spleen. Multifocal to confluent necrosis. H&E. 200x	38
Fig. 3.8.	Springbok A1, spleen. Numerous acid-fast bacilli in macrophages within a necrogranulomatous lesion. ZN. 400x	39
Fig. 3.9.	Springbok A1, liver. Focally disseminate necrosis (arrows). H&E. 200x	40
Fig. 3.10.	Springbok A1, liver. Granuloma in a portal tract consisting of macrophages and epithelioid cells. H&E. 400x	41
Fig. 3.11.	Springbok A1, liver. Acid-fast bacilli in macrophages within a granulomatous lesion (arrow). ZN. 400x	41
Fig. 3.12.	Springbok A1, kidney. Granuloma in the cortex consisting of central macrophages surrounded by lymphoplasmacells. H&E. 200x	42
Fig. 3.13.	Springbok A1, kidney. Numerous acid-fast bacilli in macrophages within granulomatous lesions (arrow). ZN. 400x	43
Fig. 3.14.	Springbok A1, kidney. Acid-fast bacilli in mesangial cells of a renal corpuscle (arrow). ZN. 400x	43
Fig. 3.15.	Springbok A1, adrenal gland. Clusters of acid-fast bacilli in macrophages within the cortex. ZN. 400x	44



Fig. 3.16.	Springbok A1, rectum. Acid-fast bacilli in macrophages within the lamina propria of the mucosa (arrows). ZN. 400x	45
Fig. 3.17.	Springbok B4, lung. Granulomas showing indistinct arborescent central caseous necrosis with numerous individual encapsulated necrotic foci.	48
Fig. 3.18.	Springbok B4, lung. Translucent to pale whitish plaques and nodules in the pleura.	49
Fig 3.19.	Springbok B4, parietal pleura. "TB-grapes" attached to the pleura.	50
Fig. 3.20.	Springbok B4, diaphragm. "TB-grapes" attached to the pleura.	50
Fig. 3.21.	Springbok B4, lung. Necrogranulomas with central caseous necrosis and moderate calcification. H&E. 40x	53
Fig. 3.22.	Springbok B4, lung. Necrogranulomas with central caseous necrosis infiltrated by neutrophils (arrow). H&E. 200x	53
Fig. 3.23.	Springbok B4, pleura. Low numbers acid-fast bacilli in macrophages within a granulomatous lesion (arrow). ZN. 400x	55
Fig. 3.24.	Springbok B4, bronchial lymph node. Necrogranuloma with central caseous necrosis and moderate calcification. H&E. 40x	57
Fig. 3.25.	Springbok B4, bronchial lymph node. Granuloma consisting mostly of Langhans' giant cells. H&E. 400x	58
Fig. 3.26.	Springbok B4, bronchial lymph node. Low numbers acid-fast bacilli in the peripheral edge of the caseous necrotic centre of a necrogranuloma (arrow). ZN. 400x	58
Fig. 3.27.	Springbok B4, left mandibular lymph node. Small granuloma in the cortex consisting of a few macrophages (arrow). H&E. 400x	61
Fig. 3.28.	Springbok B4, ileocaecal lymph node. Multinucleated giant cell exhibiting characteristics of both Langhans' and foreign-body type cells. H&E. 400x	62
Fig. 3.29.	Springbok B2, mesenteric lymph node. Cluster of acid-fast bacilli in a macrophage. MOTT were isolated from this animal (arrow). ZN. 400x	63
Fig. 3.30.	Springbok B1, ileocaecal lymph node. Parasitic granuloma with nematode larval remnants (arrows) surrounded by Langhans' giant cells. H&E. 200x	64
Fig. 3.31.	Springbok B4, pleura attached to diaphragm. Granulomatous inflammation with prominent nodular fibroplasia. H&E. 40x	65
Fig. 3.32.	Springbok B4, testicle. Granuloma consisting of macrophages surrounded by lymphoplasmacells. H&E. 200x	66
Fig. 3.33.	Springbok C1, kidney. Focal nodular granuloma in the cortex.	69
Fig. 3.34.	Springbok C1, uterus. Petechiae and ecchymoses of a caruncle with necrosis and moderate accumulation of pus.	71



Fig. 3.35.	Springbok C1, kidney. Necrogranuloma with central caseous necrosis and early calcification. H&E. 100x	73
Fig. 3.36.	Springbok C1, left prescapular lymph node. Reactive hyperplasia with numerous secondary follicles in the cortex. H&E. 40x	75
Fig. 3.37.	Springbok C1, mesenteric lymph node. Nematode larvae (arrows) surrounded by macrophages and eosinophils. H&E. 200x	77
Fig. 3.38.	Springbok C1, gastrocnemius muscle. Calcinosis circumscripta. H&E. 200x	78
Fig. 3.39.	Springbok C1, uterus. Necro-haemorrhagic endometritis. H&E. 40x	79
Fig. 3.40.	Springbok C1, lung. Bronchiolar lesions as a result of <i>B. magna</i> consisted of hypertrophy and hyperplasia of the epithelium and smooth muscle, as well as infiltration of lymphoplasmacells and eosinophils in the lamina propria of the epithelial layer. H&E. 100x	80
Fig. 3.41.	Springbok C1, lung. Numerous <i>B. magna</i> larvae in alveolar spaces (arrows). H&E. 100x	82
Fig. 3.42.	Springbok C1, lung. Multinucleated giant cell engulfing a <i>B. magna</i> larva (arrow). H&E. 400x	82

SUMMARY

THE PATHOLOGY OF TUBERCULOSIS, CAUSED BY *Mycobacterium tuberculosis*, IN A HERD OF SEMI FREE-RANGING SPRINGBOK (*Antidorcas marsupialis*)

**By
TERTIUS A GOUS**

Promotor: Professor MC Williams

Department: Section of Pathology, Department of Paraclinical Sciences, Faculty of Veterinary Science, University of Pretoria

Degree: MMedVet (Path)

This first detailed description of the pathology of tuberculosis, caused by *Mycobacterium tuberculosis* in springbok is reported. The springbok were part of a semi free-ranging herd kept on the grounds of iThemba Laboratory for Accelerator Based Science (LABS) in the Kuils River district of the Western Cape Province, South Africa. Of the 33 animals sampled, two animals had tuberculosis lesions. *Mycobacterium tuberculosis* was isolated from these two animals, as well as an animal that did not show tuberculosis pathology. The index case was an adult ewe that was presented for necropsy in a severely weakened condition. The ewe showed advanced miliary tuberculosis with marked macroscopic lesions in the lungs, pleura and respiratory lymph nodes. Limited sampling was done but microscopic tuberculosis lesions were found in almost all the organs sampled, and acid-fast bacilli were generally numerous. Six healthy rams were culled nine months later and a pilot study indicated miliary tuberculosis lesions in one ram, which again were macroscopically most prominent in the lungs, pleura and respiratory lymph nodes. Macroscopic lesions were also noted in the sternal, iliac, prefemoral and retropharyngeal lymph nodes. Microscopy in this animal revealed lesions in the macroscopically affected organs as well as numerous other lymph nodes, and suspected lesions occurred in the testicle and colon. Acid-fast bacilli were scarce to moderate in affected organs. Because of the miliary nature of the lesions in both affected animals, the route of infection could not be established conclusively. The lesions in most affected organs of both animals resembled classical tuberculous granulomas, viz. central caseous necrosis, with various degrees of calcification, surrounded by various numbers macrophages, epithelioid cells, multinucleated giant cells and lymphoplasmacells, and mild to moderate fibrous encapsulation. Necrotic lesions in the spleen, liver and kidney of the ewe were more disseminate and coagulative. A main study conducted on healthy culled animals 19 months after the pilot study failed to find any animal with tuberculosis lesions in the group of 25 sampled. These animals were all negative for mycobacteria *via* mycobacterial culture. The Interferon-gamma (INFg) assay was performed on all the animals of the pilot and main study but failed to identify the culture-positive animals and showed one false-positive reaction.

Keywords: *Mycobacterium tuberculosis*, springbok, pathology, iThemba LABS, Interferon-gamma assay

OPSOMMING

THE PATHOLOGY OF TUBERCULOSIS, CAUSED BY *Mycobacterium tuberculosis*, IN A HERD OF SEMI FREE-RANGING SPRINGBOK (*Antidorcas marsupialis*)

deur
TERTIUS A GOUS

Promotor: Professor MC Williams

Departement: Seksie Patologie, Departement van Parakliniese Wetenskappe,
Fakulteit Veeartsenykunde, Universiteit van Pretoria

Graad: MMedVet (Path)

Die patologie van tuberkulose in springbokke, soos veroorsaak deur *Mycobacterium tuberculosis*, word vir die eerste keer volledig beskryf. Die springbokke was deel van 'n trop semi-vrylewende springbokke op die perseel van die iThemba Laboratory for Accelerator Based Science (LABS) in die Kuilsrivier distrik van die Wes-Kaap Provinsie, Suid-Afrika. Uit die 33 diere wat gemonster is, het twee tuberkulose letsels gewys. *Mycobacterium tuberculosis* was geïsoleer uit albei, asook 'n dier wat geen tuberkulose patologie gewys het nie. Die eerste geval was 'n erg verswakte volwasse ooi wat aangebied is vir nadoodse ondersoek. Die ooi het gevorderde miliêre tuberkulose gewys met opvallende makroskopiese letsels in die longe, pleura en respiratoriese limfknope. Mikroskopiese tuberkulose letsels was gesien in omtrent al die organe wat versamel was. Menige suur-vaste basille is in meeste organe gesien. Ses gesonde ramme is uitgedun nege maande later en 'n loods-studie het miliêre tuberkulose in een ram aangedui. Die makroskopiese letsels in die ram was weereens mees prominent in die longe, pleura en respiratoriese limfknope. Makroskopiese letsels is ook gesien in die sternale, iliakiese, prefemorale en retrofaringeale limfknope. Mikroskopiese letsels is in die makroskopies aangetaste organe gesien, asook in verskeie ander limfknope. Verdagte tuberkulose letsels is in die testikel en kolon gesien. Min tot matige getalle suur-vaste basille is in aangetaste organe gesien. Die miliêre verspreiding van letsels in albei diere het dit onmoontlik gemaak om die roete van besmetting te bepaal. Die letsels in meeste van die aangetaste organe van beide diere het ooreengestem met klassieke tuberkulose granulome. Dit het bestaan uit sentrale kaasagtige nekrose, met variërende grade van kalsifikasie, omring deur makrofage, epiteloïede selle, meerkernige reuseselle en limfoplasmaselle, met geringe tot matige fibreuse afkapseling. Die nekrotiese letsels in die milt, lewer en nier van die ooi was meer gedissimineer en koagulatief van aard. 'n Hoofstudie is 19 maande na die loods-studie op 25 uitgedunde gesonde springbokke gedoen, en almal was negatief vir tuberkulose letsels en mikobakterieë met kweking. Die interferon-gamma (INFγ) toets was gedoen op al die diere van die loods- en hoofstudie, maar die toets kon nie die twee kultuur-positiewe diere identifiseer nie, en daar was een vals-positiewe uitslag.

Sleutelwoorde: *Mycobacterium tuberculosis*, springbok, patologie, iThemba LABS, interferon-gamma toets.

CHAPTER ONE

1.1 INTRODUCTION

Tuberculosis, caused by the bacterium *Mycobacterium tuberculosis*, also referred to as human tuberculosis (HTB), is an uncommon disease in species other than humans. Human tuberculosis is sporadically encountered in wildlife species under captive conditions, particularly zoological gardens, but is also found very rarely in semi free-ranging or free-ranging wildlife populations. In December, 1999 HTB was diagnosed in a springbok ewe that originated from a herd of semi free-ranging springbok that were kept on the grounds of the iThemba Laboratory for Accelerator Based Science (LABS) near Faure in the Kuils River district of the Western Cape Province.

iThemba LABS, previously known as the National Accelerator Centre, was established in 1977 under the control of the Council for Scientific and Industrial Research (CSIR) and since 1988 administered by the Foundation for Research Development. It provides facilities for basic and applied research using particle beams, particle radiotherapy for the treatment of cancer, and the supply of accelerator-produced radioactive isotopes for nuclear medicine and research. Buildings on the 42ha site are interspersed with artificially maintained kikuyu (*Pennisetum clandestinum*) and kweek (*Cynodon dactylon*) lawns, with groves of exotic alien vegetation consisting almost exclusively of Port Jackson willow (*Acacia saligna*).



Fig 1.1 Aerial view of iThemba LABS

The grounds of iThemba LABS have been used as one of the host sites for the Quagga Breeding Project (QBP) since 1993. The aim of the QBP is to breed a population of plains zebras that is phenotypically and genotypically close to, if not identical with, the former population known as quagga (*Equus quagga*), which was exterminated during the second half of the 19th Century. Apart from zebras, other semi free-ranging game on the premises includes springbok (*Antidorcas marsupialis*), bontebok (*Damaliscus dorcas dorcas*), grysbok (*Raphicerus melanotis*) and steenbok (*Raphicerus campestris*). These other species have been at iThemba LABS since 1990 and are managed by the Staff Environmental Club. When the initial case of tuberculosis was diagnosed in a springbok during December, 1999, there

were 48 springbok, six bontebok, four zebra and a few grysbok and steenbok present.

This dissertation documents the pathology of HTB in the springbok of iThemba LABS. After the index case was diagnosed in December, 1999, an opportunity to examine more springbok presented itself on 26 September, 2000 when the iThemba LABS Staff Environmental Club decided to cull six animals due to unsustainable numbers. One animal showed advanced generalized (miliary) tuberculosis, and *M. tuberculosis* was subsequently isolated from four organs pools. This prompted the main study during which 25 animals were culled from April, 2002 to July, 2002 for detailed pathological and bacteriological investigation.

This is the first report of *M. tuberculosis* infection in semi free-ranging springbok, and probably also for the species itself. Although tuberculosis has been reported before in captive springbok (Robinson 1953; Hofmeyr 1956), the identity of the causative *Mycobacterium* sp. was not conclusively established, and detailed description of the pathology is lacking for this species. Much has been published on the role of wildlife in transmitting bovine tuberculosis (BTB), and even HTB, to humans, but there is a dearth of information regarding HTB as an anthroozoonosis to semi free-ranging and free-ranging wildlife.

1.2 LITERATURE REVIEW

1.2.1 GENERAL OVERVIEW OF TUBERCULOSIS

Tuberculosis is defined as a disease caused by members of the *Mycobacterium tuberculosis* complex, which consists of *M. tuberculosis*, *M. bovis*, *M. microti*, *M. africanum* and *M. canettii* (Brosch, Gordon, Marmiesse, Brodin, Buchrieser, Eiglmeier, Garnier, Gutierrez, Hewinson, Kremer, Parsons, Pym, Samper, Van Soolingen & Cole 2002), although disease conditions caused by distinct *Mycobacterium* spp. such as *M. avium* are also designated as tuberculosis if they are associated with granulomatous lesions and the presence of acid-fast bacilli (Thoen & Himes 1981; Dungworth 1993). Mycobacteriosis refers to infection by any type of *Mycobacterium* spp. but is usually applied to mycobacteria other than tuberculous mycobacteria (MOTT). Disease caused by *M. tuberculosis* is referred to as human tuberculosis (HTB), while bovine tuberculosis (BTB) is used when *M. bovis* is the causative organism (Anon 2001 (b); Rastogi, Legrand & Sola 2001).

Mycobacteria appear to infect an unlimited range of domestic and non-domestic animal hosts throughout the world (Francis 1958) and tuberculosis is becoming more prevalent in wild animals, especially where there is close association with man, such as in zoological gardens and primate colonies (Francis 1958; Kovalev 1980; Thoen & Himes 1981).

1.2.2 BOVINE TUBERCULOSIS IN THE WILDLIFE OF SUB-SAHARAN AFRICA

Tuberculosis, putatively caused by *M. bovis*, has been described in the following captive indigenous wild animals in South Africa, viz. springbok (Robinson 1953; Hofmeyr 1956), giraffe (*Giraffa camelopardalis*) (Martinaglia 1930; Basson, McCully, Kruger, Van Niekerk, Young, De Vos, Keep & Ebedes 1971), black rhinoceros (*Diceros bicornis*), African buffalo (*Syncerus caffer*) and nyala (*Tragelaphus angasi*) (Hofmeyr 1956).

The first recorded outbreak of BTB in free-ranging indigenous wild animals in South Africa occurred in greater (Cape) kudu (*Tragelaphus strepsiceros*) and common duiker (*Sylvicapra grimmia*) (Paine & Martinaglia 1929). A strain of *M. bovis* was involved in an outbreak of endemic tuberculosis in the greater kudu population of the eastern Cape region of South Africa (Thorburn & Thomas 1940; Robinson 1944). Mycobacteriosis was recorded in the Kruger National Park (KNP) in 1967 in an impala (*Aepyceros melampus*) from the Crocodile Bridge area. Isolation of the causative organism was not attempted, however, and a diagnosis of the avian form was made based solely on the histopathological lesions (De Vos, McCully & Van Niekerk 1977). Keep and Basson (1973) recorded a case of mycobacteriosis in a free-ranging black rhinoceros in the Hluhluwe Game Reserve in KwaZulu-Natal, and recently, the African buffalo populations from the Umfolozi-Hluhluwe Game Reserve in KwaZulu-Natal were found to be infected with *Mycobacterium bovis* (Cooper 1998). The presence of BTB in the KNP was confirmed in 1990 when the

disease was diagnosed in an African buffalo (Bengis, Kriek, Keet, Raath, De Vos & Huchzermeyer 1996). Since then the disease has become firmly established in African buffalo in the southern and central regions of the KNP (Keet, Kriek, Huchzermeyer & Bengis 1994; Bengis *et al.* 1996), with spillover of infection to cheetah (*Acinonyx jubatus*), lion (*Panthera leo*), chacma baboon (*Papio ursinus*) (Keet, Kriek, Penrith, Michel & Huchzermeyer 1996), kudu (Keet, Kriek, Bengis & Michel 2001), leopard (*Panthera pardus*) (De Vos, Bengis, Kriek, Michel, Keet, Raath & Huchzermeyer 2001), common genet (*Genetta genetta*), spotted hyaena (*Crocuta crocuta*), bushpig (*Potamochoerus larvatus*) and honey badger (*Mellivora capensis*) (Bengis, Kock, Thomson & Bigalke 2004).

Further afield in sub-Saharan Africa BTB has been reported in the following indigenous African free-ranging wildlife: African buffalo and warthog (*Phacochoerus aethiopicus*) in Uganda (Woodford 1982 (a); Woodford 1982 (b)), Kafue lechwe (*Kobus leche kafuensis*) and bushbuck (*Tragelaphus scriptus*) in Zambia (Zieger, Pandey, Kriek & Cauldwell 1998) and olive baboon (*Papio cynocephalus anubis*) in Kenya (Tarara, Suleman, Sapolsky, Wabomba & Else 1985). In Tanzania the disease has been recorded in free-ranging African buffalo, wildebeest (*Connochaetes taurinus*), eland (*Taurotragus oryx*), topi (*Damaliscus lunatus*) and giraffe (Mlengeya 2001, cited by Bengis *et al.* 2004). Bovine tuberculosis is regarded as one of the most serious wildlife health issues currently confronting conservationists and veterinary regulatory officials in South Africa, Zambia and Uganda, and possibly some other sub-Saharan countries (Bengis *et al.* 2004).

1.2.3 HUMAN TUBERCULOSIS IN WILDLIFE

While there have been numerous reports of BTB in both captive and free-ranging indigenous wild animals in South Africa, almost all reports published on HTB in indigenous wild animals in South Africa refer only to wild animals in captivity, notably non-human primates such as chacma baboon and vervet monkey (*Cercopithecus aethiops*) (Fourie 1983; Michel, Venter, Espie & Coetzee 2003). Only one report describes HTB in free-ranging indigenous wildlife, viz. banded mongoose (*Mungos mungo*) in Botswana and suricates (*Suricata suricatta*) in South Africa (Alexander, Pleydell, Williams, Lane, Nyange & Michel 2002).

In the rest of the world HTB in wild animals has been recorded exclusively in captive wildlife, and does not appear to occur naturally in free-living animals. The range of species infected includes non-human primates, elephants, ungulates, carnivores, marine mammals and psittacine birds (Thoen, Richards & Jarnagin 1977; Forshaw & Phelps 1991; Montali, Mikota & Cheng 2001).

1.2.4 TUBERCULOSIS IN SPRINGBOK

The first case of tuberculosis in a springbok was recorded by Robinson in 1951 at the Pretoria Zoological Gardens. The animal was killed after a positive reaction to the tuberculin test, and post mortem examination revealed extensive tuberculous lesions in the lungs. Acid-fast bacilli were numerous in smears from the lung lesions. Although pure cultures of *M. tuberculosis* were

obtained, subsequent cultures from guinea-pigs that were inoculated with affected lung material were considered to be of the bovine type. A pure culture of *M. tuberculosis* was obtained from an in-contact springbok that died shortly afterwards, but inoculation of guinea-pigs was never attempted. The identity of the causative *Mycobacterium* sp. in both these cases is therefore, at best, equivocal. No description of the pathology was given in either of the animals other than “extensive tuberculosis lesions in the lungs”. The paper by Hofmeyr (1956) mentions one case of tuberculosis in a springbok at the Pretoria Zoological Gardens, but gives no additional information regarding the causative *Mycobacterium* sp. or pathology.

1.2.5 PATHOLOGY OF TUBERCULOSIS

Mycobacteria are highly successful microbial parasites capable of infecting not only numerous domestic and wildlife hosts, but almost every organ of the body as well. The characteristics and distribution of the lesions of tuberculosis vary according to the species of animal affected, the species and strain of mycobacteria involved, the immunity of the host, the route of infection and probably other ill-defined variables (Dungworth 1993; Neill, Pollock, Bryson & Hanna 1994). The macroscopical and microscopical appearance of lesions produced by *M. tuberculosis* and *M. bovis* are generally similar in humans, non-human primates and other mammals (Francis 1958; Thoen & Himes 1981; Montali *et al.* 2001).

The lesions of tuberculosis are regarded as the prototype of granulomatous inflammation. The classic lesion, the tubercle, consists of central caseous necrosis that often undergoes rapid dystrophic calcification. This central core is surrounded by epithelioid cells and Langhans' giant cells, and more peripherally by lymphocytes, macrophages and varying degrees of fibroplasia. The character of the tubercle changes as cell-mediated immunity progresses, with initial granulomatous inflammation developing central caseous necrosis as a result of delayed type hypersensitivity. Rarely the inflammatory reaction becomes more exudative with the accumulation of large amounts of fibrin, haemorrhage and neutrophil infiltration in addition to the presence of macrophages. Ziehl-Neelsen (ZN) staining reveals varying numbers of pleomorphic, intracellular acid-fast bacilli. The distribution of lesions is usually determined by the route of infection, with primary foci of tuberculosis occurring most commonly in the gastrointestinal and respiratory tracts, with secondary spread to the regional lymph nodes. Further dissemination of infection may occur *via* several routes, including lymphatics, haematogenously, natural passages, body cavities and by direct extension (Dungworth 1993; Lopez 2001). Variations in host susceptibility are reflected in the prevalence of generalized lesions and the number of organisms in these lesions (De Lisle, Bengis, Schmitt & O'Brien 2002).

Macroscopic lesions of tuberculosis in cattle are typically caseous, yellow and mineralized (Dungworth 1993), and 95% of lesions are located in the lungs and lymph nodes of the head, thorax and abdomen (Corner 1994). The lesions caused by *M. bovis* and *M. tuberculosis* in cattle are similar in

appearance, but *M. tuberculosis* infection usually does not progress beyond the development of small granulomas in the pharyngeal, thoracic and mesenteric lymph nodes (Cousins, Huchzermeyer, Griffin, Brückner, Van Rensburg & Kriek 2004). The appearance and distribution of macroscopic lesions in other hosts, including wildlife, are sometimes different from those observed in cattle. For example, abscessation and fistulation of the parotid lymph nodes are common findings in greater kudu (Bengis & Keet 1998; Keet *et al.* 2001), while the lesions in lions are more proliferative in nature without caseation or calcification (Keet, Kriek, Penrith & Michel 1998). The distribution of lesions in wildlife depends on the route of infection and whether or not secondary spread of infection has occurred (Thoen & Himes 1981; De Lisle *et al.* 2002). In contrast to cattle, extensive lesions and progressive pulmonary disease often develop in captive wildlife infected with *Mycobacterium tuberculosis* (Lomme, Thoen, Himes, Vinson & King 1976; Montali *et al.* 2001).

The classical histological lesion of tuberculosis in cattle is the tubercle, as described above. Variations on this theme are observed between different hosts with regard to the frequency of histological features such as caseous necrosis, neutrophil infiltration, calcification, giant cells, fibrous encapsulation and acid-fast organisms. However, although there may be considerable variation in lesion characteristics between different hosts, these tissue changes cannot be used to determine the mycobacterial species involved. The lesions caused by *M. tuberculosis*, *M. bovis* and even other

mycobacterial species are often indistinguishable from one another (Francis 1958; De Lisle *et al.* 2002).

Histopathology is not only used to establish a presumptive diagnosis of tuberculosis, but also to rule out other causes of macroscopically similar lesions. These differential diagnoses include foreign bodies, helminth parasites, bacteria such as *Staphylococcus*, *Rhodococcus*, *Actinomyces*, *Actinobacillus*, *Arcanobacterium* and *Nocardia*, and fungi, including *Aspergillus*, *Cryptococcus*, *Blastomyces* and *Histoplasma*, as well as several neoplasms such as adenocarcinoma, anaplastic carcinoma, malignant lymphoma and mesothelioma (De Lisle *et al.* 2002; Cousins *et al.* 2004).

1.2.6 DIAGNOSIS OF TUBERCULOSIS

A tentative diagnosis of tuberculosis can be made following the macroscopic detection at necropsy of typical lesions. Smears prepared from the content of lesions and stained by the ZN method may reveal acid-fast bacilli. Histopathology, combined with ZN staining, will often lead to a presumptive diagnosis, but bacteriological isolation of the causative *Mycobacterium* spp. is necessary to make a definitive diagnosis (Corner 1994). Mycobacterial culture and species identification is therefore considered the gold standard for establishing a diagnosis of tuberculosis (De Lisle *et al.* 2002). However, false-negative results may occur with culture and is dependent on total number of infectious organisms, destruction of viable organisms by overgrowth of other bacteria, state of preservation of tissues, and the use of decontamination

during tissue processing (Corner 1994; Fitzgerald, Kaneene, Butler, Clarke, Fierke, Schmitt, Bruning-Fann, Mitchell, Berry & Payeur 2000).

Presumptive clinical signs of tuberculosis such as emaciation and coughing are usually only apparent when the disease has reached an advanced stage. In most infected animals the disease is inapparent and other methods must be used to establish a diagnosis. The ante-mortem diagnosis of tuberculosis in wildlife is hampered by a lack of sensitive and specific diagnostic tests that have been sufficiently validated for use in the different species. Additionally, there are significant problems associated with capturing and restraining animals for testing. Ideally, ante-mortem tests should be sensitive and specific, and require single sampling (De Lisle, Mackintosh & Bengis 2001).

Although there are several methods available for diagnosing tuberculosis in living wildlife, some are only practical and applicable to certain species. Radiology has been found to be of value in identifying lesions in baboons (Thoen & Himes 1981). Culture of respiratory secretions obtained by trunk lavage is considered to be the most reliable ante-mortem test for diagnosing tuberculosis in elephants. The muco-cutaneous lesions caused by HTB in psittacines can be biopsied and cultured (Montali *et al.* 2001).

The intradermal tuberculin (IDT) test, using purified protein derivative (PPD) from culture of *M. bovis* or *M. avium*, is the most frequently used ante-mortem test for the diagnosis of tuberculosis or detection of *M. bovis* infection in cattle (Adams 2001). Intradermal tuberculin testing has been applied to a few

wildlife species with variable success, usually only after modifications to the test site, the dose of tuberculin and test interpretation. This test has practical disadvantages when applied to free-ranging wildlife, because animals must be re-examined 48 hours to 96 hours after the injection of tuberculin. A significant complication of the IDT test in wildlife is the high level of non-specific sensitization as a result of exposure to environmental mycobacteria (De Lisle *et al.* 2001; De Lisle *et al.* 2002). The IDT test is the most frequently used ante-mortem assay for diagnosing tuberculosis in non-human primates. Because of the cross-reactivity between *M. tuberculosis* and *M. bovis* the test can only be used to diagnose tuberculosis, and not to identify the causative organism (Thoen & Himes 1981; Montali *et al.* 2002).

The development of *in vitro* methods to detect cell-mediated immunity initially focused on the lymphocyte transformation test (LTT). This test is, however, far too complex, costly and slow for use as a practical alternative to the IDT test (Wood & Rothel 1994). The recently developed interferon-gamma (INF γ) assay for detecting cattle infected with *M. bovis* is a major advancement in the diagnosis of BTB. In a number of countries this assay has been shown to produce sensitivity and specificity values in cattle comparable to or higher than the IDT test, with even better results when the two tests are used in parallel (Wood, Corner, Rothel, Baldock, Jones, Cousins, McCormick, Francis, Creeper & Tweddle 1991; Wood 1994; Wood & Rothel 1994; Adams 2001; Cousins *et al.* 2004).

The INFg assay has a significant advantage over the IDT test in that only one blood sample is necessary. The assay was developed for cattle and has the limitation that the monoclonal antibodies used in the enzyme-linked immunosorbent assay (ELISA) will only recognize the interferon-gamma of a limited range of species including cattle, sheep and goats (De Lisle *et al.* 2002). Investigations in African buffalo have shown that the INFg assay has potential as an ante-mortem test for detecting BTB under field conditions in the Kruger National Park. Cross-reactions with environmental mycobacteria such as *M. fortuitum* were overcome by including a *M. fortuitum* PPD sample as well as bovine and avian PPD, and by modifying the cut-off algorithm to differentiate an immune response due to environmental mycobacteria from true BTB reactors (Michel & Jones 1998; Grobler, Michel, De Klerk & Bengis 2002). Recently, an INFg assay for diagnosing *M. tuberculosis* in non-human primates has become available (Anon 2002). The use of the INFg assay to detect other wildlife infected with *M. tuberculosis* has not been attempted.

Serology, using the ELISA, may aid in the identification of animals with advanced tuberculosis, but due to its poor sensitivity has found only limited application as an ante-mortem diagnostic test (Wood & Rothel 1994; Griffin & Mackintosh 2000).

Because of the limitations of the currently available ante-mortem diagnostic tests for wildlife, their use is only really warranted in indigenous protected wildlife species, and if post-mortem samples are not readily available (De Lisle *et al.* 2002). The post-mortem examination of free-ranging wildlife is the

most commonly used method for surveying wildlife for tuberculosis, and detailed information can be gathered from culling operations (De Lisle *et al.* 2001; De Vos *et al.* 2001; De Lisle *et al.* 2002).

1.2.7 TUBERCULOSIS AT THE HUMAN / ANIMAL INTERFACE

The reported incidence of tuberculosis in humans in the Western Cape Province, particularly in the Cape Town metropole, is amongst the highest in the world, complicated and exacerbated by the HIV/AIDS pandemic. The Oostenberg sub-district, where iThemba LABS is situated, had the third highest incidence of tuberculosis in the Cape Town metropole in 2003. This sub-district had an estimated tuberculosis incidence rate of 950 per 100 000 of the population in 2003, compared to 678 per 100 000 for the Cape Town metropole in 2003, and 686 per 100 000 for South Africa in 2001 (Anon 2001 (a); Anon 2004 (a)).

Although *M. tuberculosis* is the most common infection in humans, *M. bovis* is responsible for an increasing proportion of human tuberculosis cases (O'Reilly & Daborn 1995; Cosivi, Grange, Daborn, Raviglione, Fujikara, Cousins, Robinson, Huchzermeyer, Kantor & Meslin 1998). Tremendous attention has been given to the zoonotic potential of tuberculosis in wildlife populations and the threat they present to human health (Fredrickson, Barton, Ragan & Roberts 1971; Thoen 1988; Stetter, Mikota, Gutter, Monterosso, Dalovisio, Degraw & Farley 1995; Cosivi *et al.* 1998; Michalak, Austin, Diesel, Bacon, Zimmerman & Maslow 1998; De Lisle *et al.* 2001). The reverse situation,

however, has received little attention: the threat tuberculous humans present to wildlife (Alexander *et al.* 2002).

Mycobacterium tuberculosis is a primary human pathogen but may infect domestic or wildlife species that are in close or prolonged contact with humans (Fourie 1983; Michalak *et al.* 1998; Michel & Huchzermeyer 1998; Montali *et al.* 2001). Transmission to semi free-ranging and free-ranging wildlife is an extremely rare occurrence and only two outbreaks of HTB in free-ranging wildlife have been reported (Alexander *et al.* 2002).

CHAPTER TWO

2.1 MATERIALS AND METHODS

2.1.1 PART ONE: INDEX CASES

2.1.1.1 ANIMALS

On 20 December, 1999 a prostrate and weakened adult springbok ewe was presented for necropsy at the Western Cape Provincial Veterinary Laboratory (WCPVL) in Stellenbosch to establish the cause of the clinical signs. The ewe was euthanased by means of an overdose of intravenous barbiturates and a full necropsy performed. Necropsy revealed the possibility of tuberculosis and various specimens to confirm the diagnosis were collected as indicated below.

On 29 June, 2000 an old springbok ram was found dead at iThemba LABS after it appeared “tired” for at least a week prior to death. The carcass was presented for necropsy at the WCPVL but advanced post mortem changes made detailed examination impossible. However, lesions suggestive for tuberculosis were present in the lungs, and specimens were collected as indicated below.

2.1.1.2 MACROSCOPIC AND MICROSCOPIC PATHOLOGY

All macroscopic lesions found at necropsy of the index case were recorded. The following tissue specimens were collected from the index case for histopathological examination and fixed in 10% buffered formalin: heart (multiple specimens), lung (multiple specimens), mediastinal lymph node, bronchial lymph node, liver, spleen, kidney, adrenal glands and alimentary tract (oesophagus, abomasum, small intestine, large intestine and rectum). Specimens from the ram consisted of lung tissue and pulmonary lymph nodes. The formalin-fixed tissues were embedded in paraffin wax and sections were cut at 5µm and stained routinely with haematoxylin and eosin (H&E). All sections were also stained with Ziehl-Neelsen (ZN) stain to detect acid-fast bacilli. Microscopic lesions were recorded after light-microscopic examination.

2.1.1.3 BACTERIOLOGY

A fresh unpreserved mediastinal lymph node that showed lesions suggestive of tuberculosis was aseptically collected from the index case. Two fresh unpreserved lung specimens were aseptically collected from the ram. These specimens were all frozen (-20°C) and dispatched in a frozen state, within 5 days of collection, to the Tuberculosis Laboratory at the Onderstepoort Veterinary Institute (OVI) for mycobacterial culture.

The specimens were cultured for *Mycobacterium* spp. according to the standard isolation and identification methods for mycobacteria used by the OVI. These methods have been described (Anon 1983; Bengis *et al.*; 1996 Keet *et al.* 1996). The procedure can be summarized as follows:

The tissue samples are described, homogenised, decontaminated and inoculated onto suitable solid medium such as Loewenstein-Jensen medium. During a maximum culture period of 10 weeks the medium slopes are evaluated on a weekly basis and typical growth is tested for acid-fastness. Heat-killed cell suspensions of acid-fast isolates are subjected to PCR testing for identification of *M. tuberculosis* complex isolates. PCR is performed using primers designed to target a sequence encoding the MPB 70 antigen of *M. tuberculosis* complex bacteria and the presence of a product of 372 base pairs is considered as positive for *M. tuberculosis* complex. Differentiation between *M. tuberculosis* and *M. bovis* isolates is possible by a second PCR test. If necessary, biochemical tests are used to assist in species identification of *Mycobacterium* isolates. These include the nitrate reduction test, niacin test, oxygen preference test, arylsulphatase test, temperature growth test, and tellurite reduction test.

2.1.2 PART TWO: PILOT STUDY

2.1.2.1 ANIMALS

On 26 September, 2000 the iThemba LABS Staff Environmental Club decided to cull six animals due to unsustainable numbers. At this stage, HTB was known to be present within the herd and a pilot study was designed to evaluate these animals for the presence of tuberculosis. The animals were randomly selected and consisted of clinically healthy rams comprising three sub-adult and three adult animals. The animals were stunned before death by professional hunters using the intracranial gunshot method with .22 calibre rifles. As soon as each animal fell to the ground the throat was cut to cause exsanguination and death. Animals were identified numerically and chronologically as they were euthanased, and transported to the WCPVL for necropsy and sampling.

2.1.2.2 MACROSCOPIC AND MICROSCOPIC PATHOLOGY

The main aim of the pilot study was to detect animals with macroscopic and microscopic tuberculosis lesions, and to describe the lesions in detail. The hallmark tuberculosis lesion is the granuloma, or tubercle, and any macroscopic lesion resembling granulomatous inflammation was described. These were lesions showing any of the following characteristics: pinpoint to larger size, multiple to single, distinctly outlined or poorly demarcated, flat to

elevated above the organ surface, pale to pigmented, with or without necrosis, calcification, liquefaction, abscessation or encapsulation.

Tissue specimens were collected for histopathological examination and all, except the lymph nodes and specimens for mycobacterial culture (see below), fixed in 10% buffered formalin. These included the brain, eyes, heart (multiple specimens), lung (multiple specimens), liver, kidneys, spleen, adrenal glands, testes, thymus (if present) and alimentary tract (tongue, oesophagus, abomasum, duodenum, jejunum, ileum and colon). Specimens from other organs were only collected if macroscopic abnormalities were noted.

Fresh unpreserved lymph nodes were collected aseptically and each lymph node placed in a separate sterile container for further processing within 24 hours after collection. Processing of lymph nodes entailed aseptic sectioning of each lymph node into thin (one to two millimetre) slices for macroscopic evaluation. Specimens from each lymph node were then placed in 10% buffered formalin, and the remainder dispatched for mycobacterial culture. Lymph nodes sampled included the tonsils, parotid (left and right), retropharyngeal (left and right), mandibular (left and right), bronchial, mediastinal, sternal, hepatic, splenic, ileocaecal, mesenteric, iliac, inguinal, prescapular (left and right), prefemoral (left and right) and popliteal lymph (left and right) nodes.

The formalin-fixed tissues were embedded in paraffin wax and sections were cut at 5µm and stained routinely with haematoxylin and eosin (H&E). All

sections were also stained with Ziehl-Neelsen (ZN) stain to detect acid-fast bacilli. Microscopic lesions were recorded after light-microscopic examination.

The possible macroscopic granulomatous lesions were confirmed and described microscopically. Additional granulomatous inflammatory lesions not detected macroscopically, were given microscopic descriptions. For the purpose of this study, microscopic granulomatous inflammation was defined as a lesion showing any combination of the following: central caseous or coagulative necrosis, with or without calcification, surrounded by macrophages, epithelioid cells and multinucleated giant cells, and more peripherally lymphocytes, plasma cells, macrophages and varying degrees of fibroplasia, with or without encapsulation. The reaction may be modified by haemorrhage, accumulation of fibrin and neutrophil infiltration. The presence or absence, location and relative numbers of acid-fast bacilli were noted after ZN staining.

2.1.2.3 BACTERIOLOGY

Specimens for mycobacterial culture comprised fresh unpreserved lung (multiple specimens), liver, spleen, kidneys, ileum and all the lymph nodes listed under 2.1.2.2. These specimens were placed in individual sterile containers, immediately refrigerated at 2–4°C and the lymph nodes processed as indicated under 2.1.2.2. Specimens were then frozen (-20°C) and dispatched in a frozen state, within five days of collection, to the Tuberculosis Laboratory at the OVI for mycobacterial culture.

At the OVI the specimens were pooled into the following four groups per animal: lungs, other organs (liver, spleen, kidneys and ileum), organ lymph nodes (bronchial, mediastinal, hepatic, splenic, ileocaecal and mesenteric) and carcass lymph nodes [tonsils, parotid (left and right), retropharyngeal (left and right), mandibular (left and right), sternal, iliac, inguinal, prescapular (left and right), prefemoral (left and right) and popliteal (left and right)]. These tissue pools were each cultured individually for *Mycobacterium* spp. according to the same protocol mentioned under 2.1.1.3 above.

2.1.2.4 INTERFERON-GAMMA (IFN γ) ASSAY

Blood was collected from the jugular vein into 10ml blood collection tubes containing lithium heparin shortly after the throat was cut. The blood samples were kept at ambient temperature and prepared for the IFN γ assay at the WCPVL within six hours of collection. The preparatory procedure involved stimulation of the blood with mycobacterial antigens before testing the samples for IFN γ and was as follows: Four sterile plastic tubes per animal were labeled according to the antigen to be added (tube 1 = bovine; tube 2 = avian; tube 3 = fortuitum and tube 4 = control). Afterwards 1.5ml blood was dispensed in each tube. Thirty μ l of bovine PPD was added to tube 1; 60 μ l of avian PPD to tube 2; 25 μ l of fortuitum PPD to tube 3 and nothing to tube 4. The tubes were closed and tilted a few times to ensure sufficient mixing. The tubes were incubated at 37°C for 24 hours. Following incubation the plasma was transferred to sterile plastic tubes and frozen (-20°C) before shipment to the OVI where IFN γ testing was performed. A commercial IFN γ Enzyme

Immunoassay (EIA) test kit (Bovigam™ Kit, CSL Ltd., Parkville, Australia) was used according to the manufacturer's recommendations.

The results of the INGg assay were compared to the mycobacterial culture results (gold standard) to determine the sensitivity and specificity of the assay according to the following calculations:

	Mycobacterial culture positive	Mycobacterial culture negative
Positive	a	b
Negative	c	d

$a + c =$ Total number of diseased animals

$b + d =$ Total number of disease-free animals

Sensitivity = $a / a + c$

Specificity = $d / b + d$

The following formulae were used to calculate the predictive value of a positive test and the predictive value of a negative test:

Predictive value of a positive test = $a / a + b$

Predictive value of a negative test = $d / c + d$

2.1.3 PART THREE: MAIN STUDY

2.1.3.1 ANIMALS

In 2002 the springbok numbers had increased to 62 animals and the iThemba LABS Staff Environmental Club decided to cull more springbok, which afforded the opportunity to sample more animals for tuberculosis. Professional hunters were employed to cull 25 animals, consisting of 15 adult ewes and 10 adult rams, from April, 2002 to July, 2002. One ewe showed right hind-leg lameness, while the others all appeared clinically healthy and were randomly selected. Random selection was achieved by shooting every second animal encountered. The animals were euthanased in batches of between 5 and 10 animals per day of sampling. Euthanasia was performed as described under 2.1.2.1 above. Animals were identified numerically and chronologically as they were euthanased, and transported to the WCPVL for necropsy and sampling.

2.1.3.2 MACROSCOPIC AND MICROSCOPIC PATHOLOGY

Similar to that of the pilot study, the aim of the main study was to detect animals with macroscopic and microscopic tuberculosis lesions, and to describe the lesions in detail. The same macroscopic and microscopic criteria for evaluation were therefore applied.

Tissue specimens were collected for histopathological examination and all, except the lymph nodes and specimens for mycobacterial culture (see 2.1.3.3

below), were fixed in 10% buffered formalin. These included the brain, eyes, heart (multiple specimens), lung (multiple specimens), liver, kidneys, spleen, adrenal glands, testes, ovaries, uterus, mammary gland, urinary bladder, pancreas and alimentary tract (tongue, oesophagus, rumen, abomasum, duodenum, jejunum, ileum and colon). Specimens from other organs were only collected if macroscopic abnormalities were noted.

Fresh unpreserved lymph nodes were collected, handled and processed as described under 2.1.2.2. Lymph nodes sampled included the tonsils, parotid (left and right), retropharyngeal (left and right), mandibular (left and right), bronchial, mediastinal, ileocaecal, mesenteric, iliac, inguinal, prescapular (left and right), prefemoral (left and right) and popliteal (left and right) lymph nodes.

The formalin fixed tissues were processed, stained and examined for granulomatous inflammation in a similar fashion to the pilot study (2.1.2.2).

2.1.3.3 BACTERIOLOGY

Specimens for mycobacterial culture comprised fresh unpreserved lung (multiple specimens), all the lymph nodes listed above and any other organ that showed suspected tuberculous lesions. These specimens were placed in individual sterile containers, immediately refrigerated at 2–4°C and the lymph nodes processed as indicated under 2.1.2.2. After macroscopic examination of the lymph nodes, they were pooled into four groups as follows: head

(tonsils, parotid, retropharyngeal and mandibular), thoracic (bronchial and mediastinal), abdominal (mesenteric and ileocaecal), peripheral (prescapular, prefemoral, popliteal and inguinal). Specimens were then frozen (-20°C) and dispatched in a frozen state, within five days of collection, to the Tuberculosis Laboratory at the OVI for mycobacterial culture.

At the OVI the lymph node pools, lungs, and other organ specimens were each cultured individually for *Mycobacterium* spp. according to the protocol outlined under 2.1.1.3.

2.1.3.4 INTERFERON-GAMMA (IFN γ) ASSAY

Blood was collected, handled and processed as described under 2.1.2.4. The results were combined with the pilot study to determine the sensitivity, specificity, predictive value of a positive test and the predictive value of a negative test for the IFN γ assay as described under 2.1.2.4.

CHAPTER THREE

3.1 RESULTS

3.1.1 PART ONE: INDEX CASES

The index case was an adult ewe (A1) and a second possible case an adult ram (A2)

3.1.1.1 MACROSCOPIC AND MICROSCOPIC PATHOLOGY

3.1.1.1.1 MACROSCOPIC PATHOLOGY

A1

The ewe showed marked emaciation. Hard and dry faecal pellets were present in the rectum, resulting in constipation and rectal prolapse. There was depletion of peri-renal and mesenteric fat reserves, and the fat in the coronary groove of the heart and bone marrow cavity was soft, translucent and jelly-like (serous atrophy of fat). These changes reflected marked cachexia. The following organs showed significant lesions:

Lung:

There were moderate numbers of multifocal, firm, round to oval, greyish white, nodular granulomatous lesions throughout the lungs that were more numerous in the caudal lobes. The nodules measured 1 to 10mm in diameter. Some of the granulomatous nodules displayed irregular, multifocal, central, yellowish, caseous necrotic foci measuring 2 to 5mm in diameter, with moderate calcification, and were moderately encapsulated.

The entire visceral and parietal pleura were covered in moderate numbers of multifocal, round to ovoid, non-encapsulated, translucent to greyish white plaques and nodules measuring 1 to 10mm in diameter. These nodules resembled “TB-grapes” and consisted mostly of fibrous connective tissue showing no to mild, multifocal areas of irregular, pale yellowish, central caseous necrosis measuring 1 to 5mm in diameter, and often prominent calcification.

There were large numbers of adult *Bronchonema magna* nematodes in the lumen of the trachea at the tracheal bifurcation.

Lymph node:

The bronchial and mediastinal lymph nodes were enlarged and measured 30 x 10mm, and 50 x 10mm, respectively. Both lymph nodes showed multifocal to confluent irregular areas, measuring 1 to 10mm in diameter, of pale yellowish caseous necrosis with prominent calcification. The necrotic areas were moderately encapsulated.

Spleen:

The spleen was moderately enlarged and had an increased (“meaty”) consistency. The red pulp was prominent and the white pulp indistinct.

Liver:

There was moderate hepatomegaly with focally disseminate necrosis, the latter represented by numerous pinpoint, pale white foci throughout the parenchyma.

Kidney:

The kidneys were pale brown and moderately swollen.

Adrenal gland:

Both adrenal glands displayed marked enlargement of the cortex as a result of hyperplasia.

A2

The carcass of the ram showed advanced post-mortem autolysis and putrefaction with evidence of post-mortem predation. The right lung lobe was consolidated, and both lobes showed a few round to oval, pale white, firm, nodular suspected granulomatous areas, measuring 1 to 10mm in diameter. The suspected tuberculosis lesions were more numerous in the cranial lobes. Moderate numbers of adult *Bronchonema magna* nematodes were present in the lumen of the trachea at the tracheal bifurcation.

3.1.1.1.2 MICROSCOPIC PATHOLOGY

The microscopical appearance of the lesions in the organs mentioned above, as well as significant lesions detected in other organs, are described below. Multinucleated giant cells were always of both the Langhans' and foreign-body type, except where otherwise indicated. Ziehl-Neelsen staining was negative for acid-fast bacilli in all the organs that did not show significant lesions.

A1

Lung (Figs. 3.1, 3.2 and 3.3):

There were numerous multifocal to confluent necrogranulomas visible throughout the parenchyma. These granulomas consisted of a central area of caseous necrosis that was usually moderately calcified, surrounded by a rim of moderate numbers of macrophages and epithelioid cells, and low numbers of multinucleated giant cells. There was an outer layer of lymphocytes and plasma cells, within a moderately developed fibrous capsule. Numerous multifocal smaller, and often indistinctly outlined granulomas, without necrosis and calcification, consisting of macrophages, epithelioid cells, lymphocytes and plasma cells were also visible. These smaller granulomas were often infiltrated by low to moderate numbers of neutrophils. The remainder of the lungs show multifocal areas of alveolar neutrophil infiltration admixed with moderate to large numbers of macrophages, Low to moderate numbers of macrophages were also present in alveolar walls.

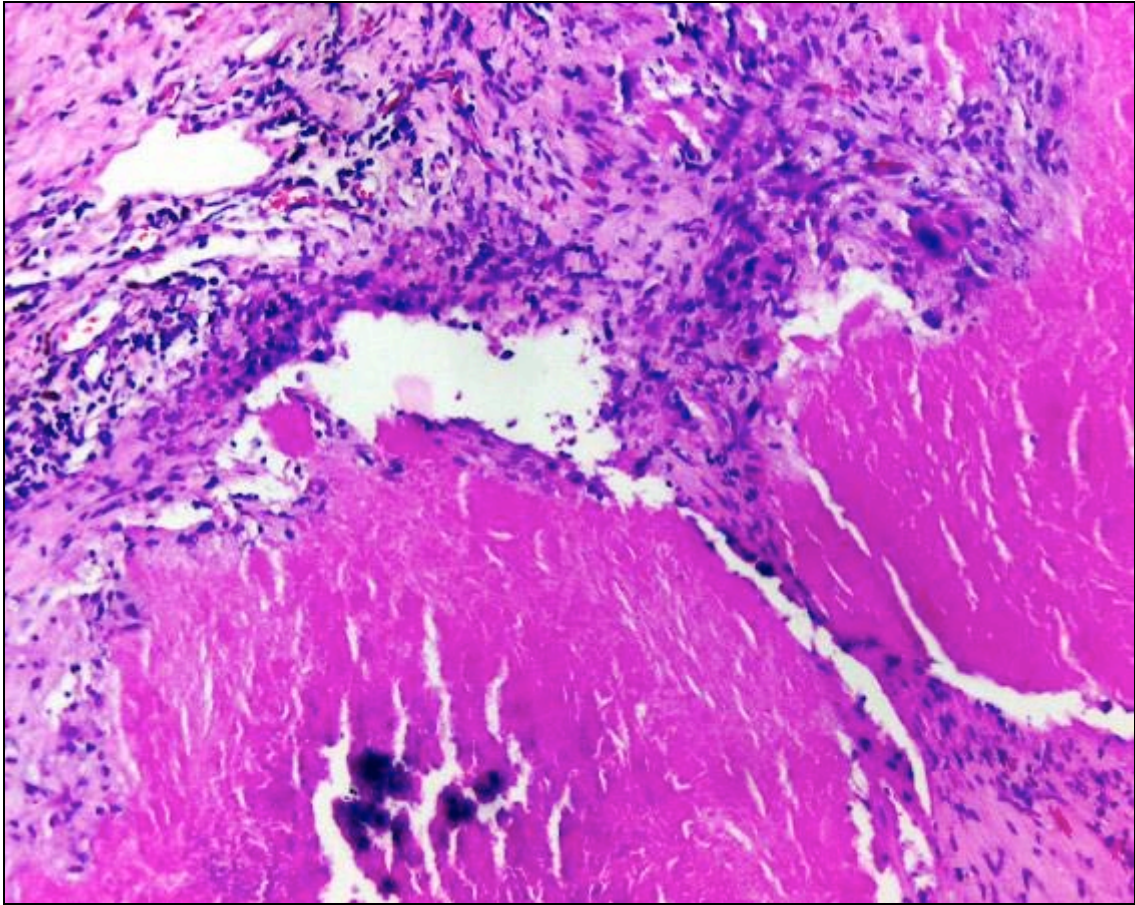


Fig. 3.1. Springbok A1, lung. Necrogranulomas with central caseous necrosis and moderate calcification. H&E. 100x

A few bronchioles contained numerous adult *B. magna* nematode parasites. Lesions that were ascribed to nematode infection consisted of moderate to marked hyperplasia and hypertrophy of bronchiolar epithelium and smooth muscle. The lamina propria of the bronchiolar epithelium was infiltrated by moderate numbers of lymphocytes and plasma cells, and low numbers of eosinophils. Moderate numbers to numerous globular leukocytes, with moderate to abundant, variably-sized, round, eosinophilic, cytoplasmic globules, occurred in the intercellular areas of the bronchiolar epithelium. The bronchiolar- and perivascular-associated lymphoid tissue was moderately

hyperplastic. Some bronchioles, notably those parasitized by adult nematodes, were filled with a moderate amount of exudate consisting of fibrin, neutrophils, eosinophils and low numbers of macrophages.

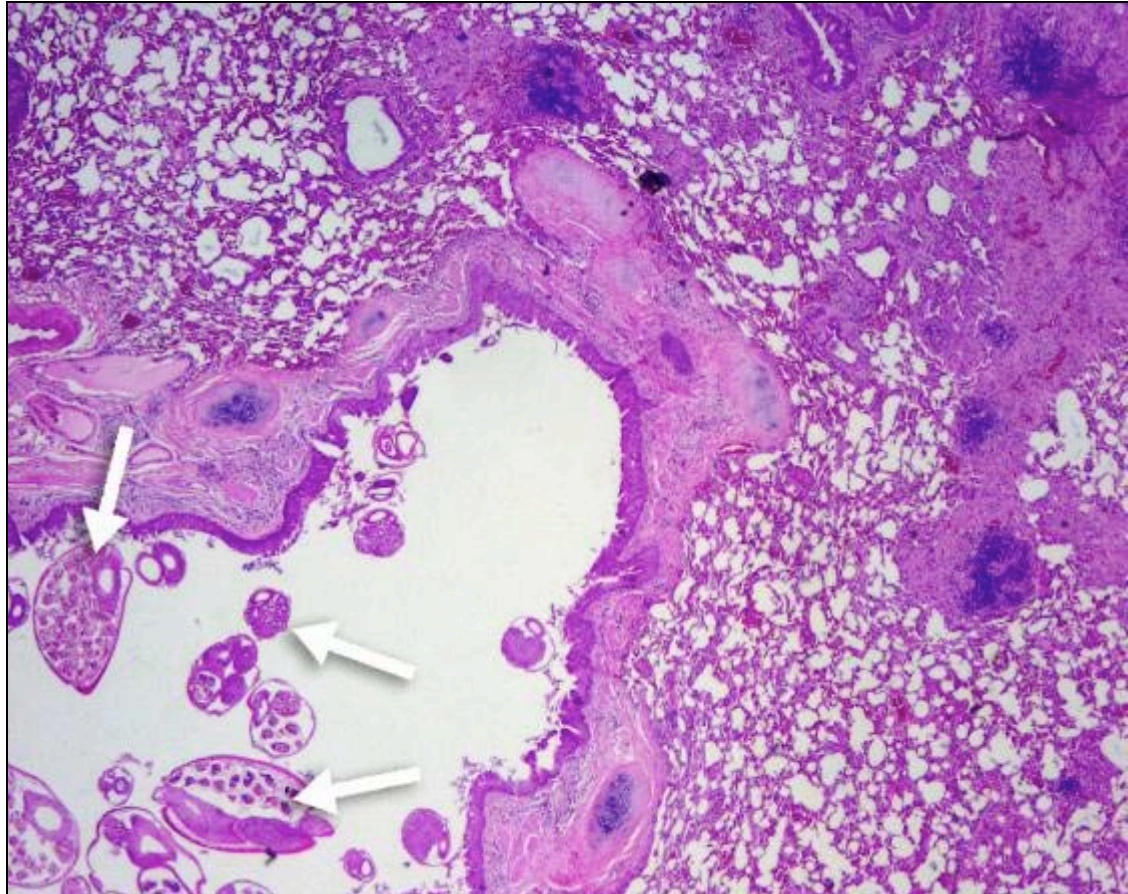


Fig 3.2. Springbok A1, lung. Adult *B. magna* nematodes within a bronchiole (arrows). H&E. 20x

Ziehl-Neelsen staining of the lungs revealed numerous medium-sized, slender, acid-fast bacilli in the cytoplasm of macrophages, epithelioid cells and multinucleated giant cells in necrogranulomas along the edge of the necrotic centre. Bacilli were also present in moderate numbers in macrophages and epithelioid cells of the smaller granulomas. Free-lying acid-

fast bacilli in bronchioles were admixed with cellular debris, and there were also bacilli in the cytoplasm of intra-bronchiolar macrophages.

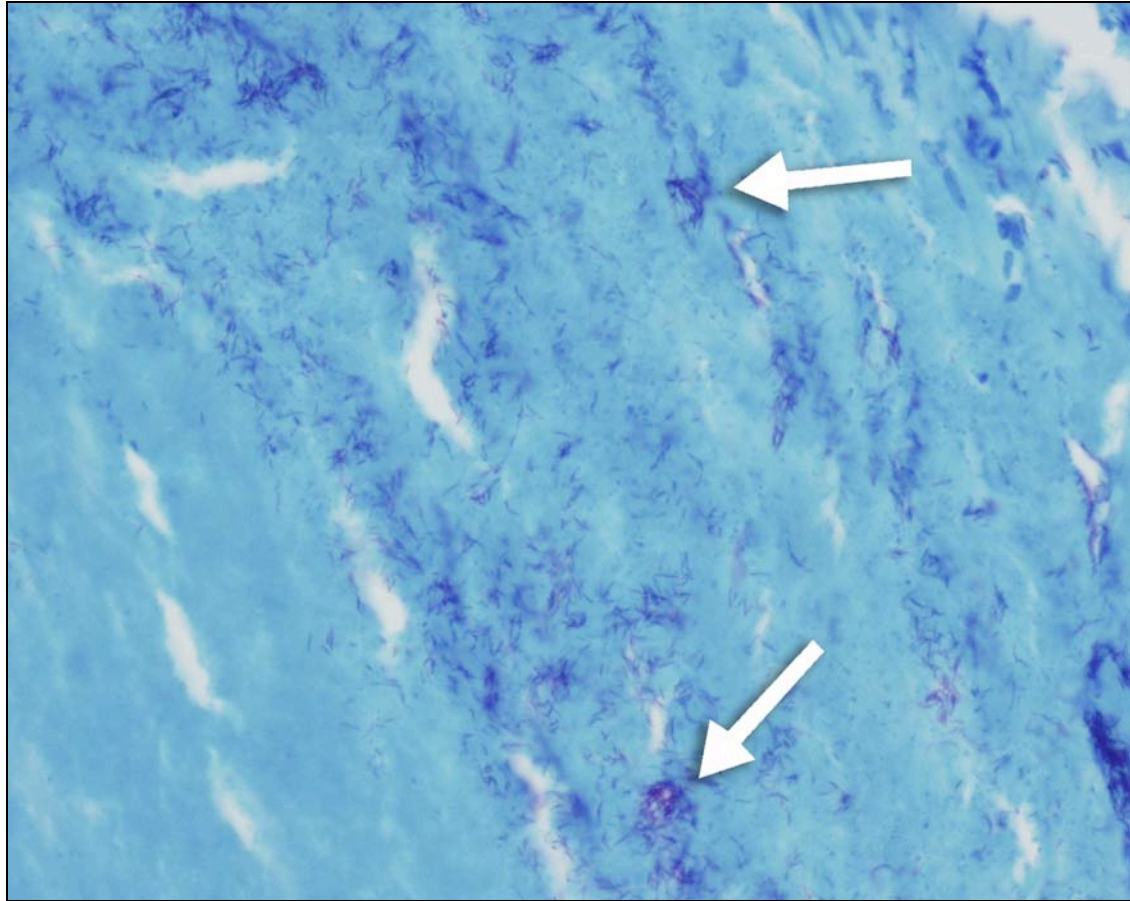


Fig 3.3. Springbok A1, lung. Acid-fast bacilli in macrophages along the edge of the caseous necrotic centre of a granuloma (arrows). ZN. 400x

Lymph node (Figs. 3.4, 3.5 and 3.6):

The mediastinal lymph nodes displayed large multifocal to confluent necrogranulomas, involving almost the entire lymph node, with only a small rim of relatively normal tissue remaining. These necrogranulomas consisted of a central caseous necrotic area that was usually moderately calcified, with a surrounding layer of low to moderate numbers of macrophages, epithelioid cells and multinucleated giant cells. A few extremely large giant cells,

containing numerous centrally located nuclei, were visible. The outer layer consisted of a well-developed fibrous capsule that was infiltrated by moderate numbers of lymphocytes and plasma cells, and low to moderate numbers of haemosiderin-containing macrophages. A few smaller granulomas, consisting of macrophages and epithelioid cells, with peripheral lymphocyte and plasma cell infiltration, were also visible. The relatively normal lymph node tissue showed numerous multifocal nests, consisting of macrophages, epithelioid cells and multinucleated giant cells.

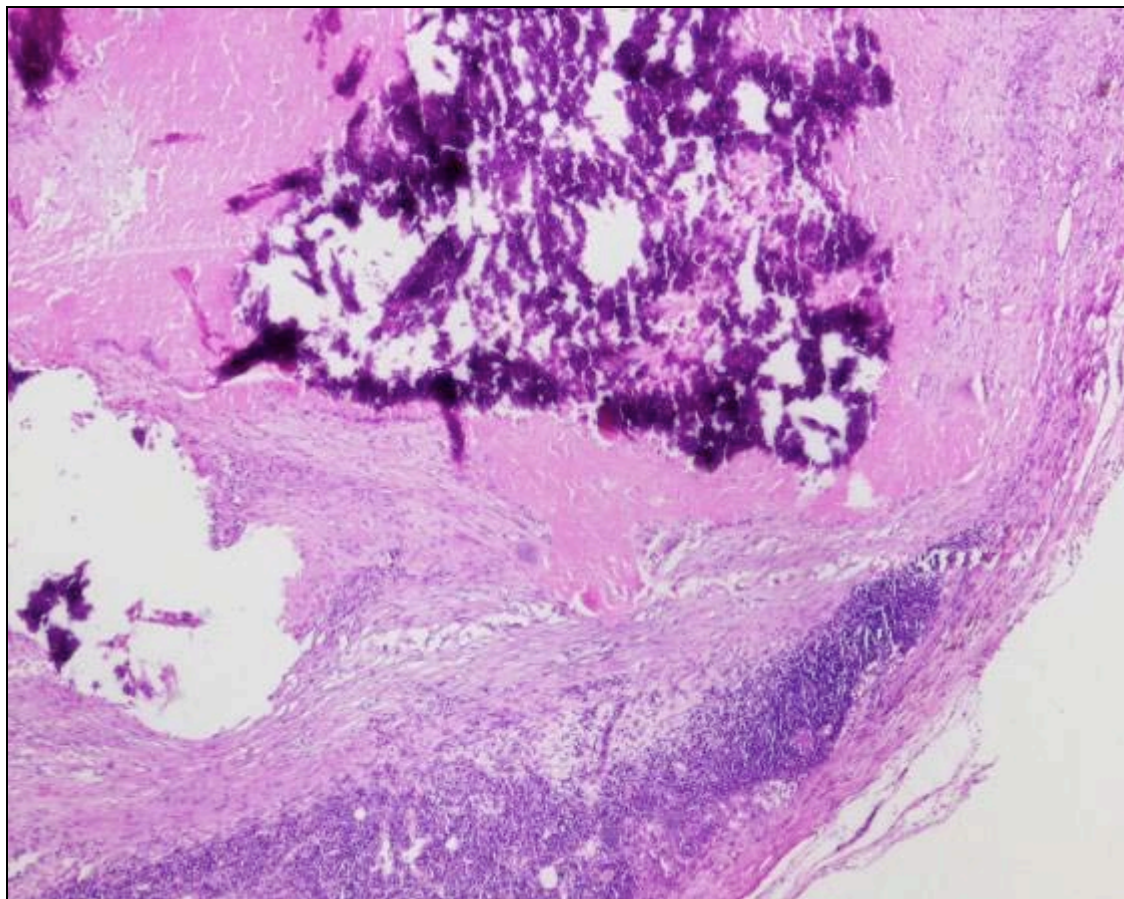


Fig 3.4. Springbok A1, mediastinal lymph node. Necrogranulomas with central caseous necrosis and prominent calcification. H&E. 40x

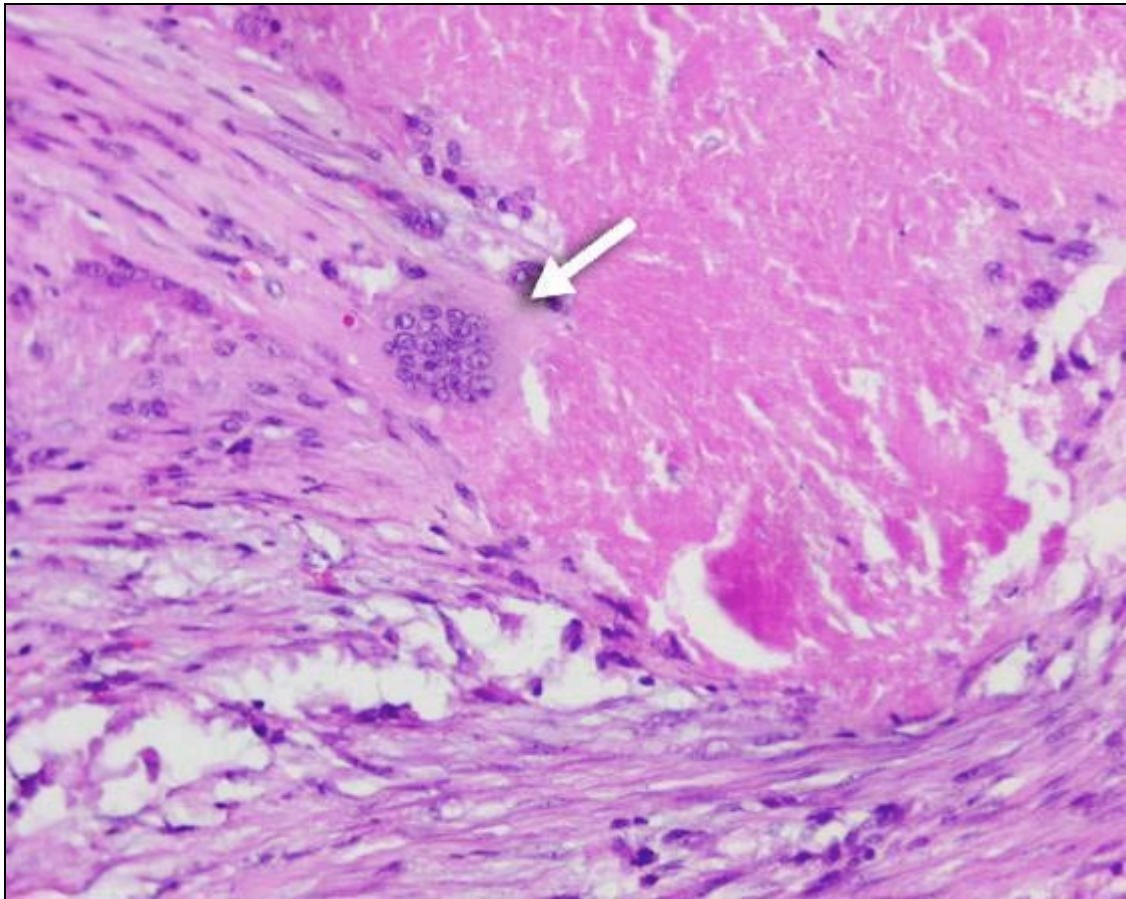


Fig. 3.5. Springbok A1, mediastinal lymph node. Multinucleated giant cell of the foreign-body type (arrow). H&E. 200x

The bronchial lymph nodes showed less extensive but otherwise similar lesions to the above. Additionally, there were multifocal areas of coagulative necrosis in the relatively normal lymph node tissue that was infiltrated by moderate to large numbers of neutrophils. The medulla was infiltrated by large numbers of macrophages with many showing erythrophagocytosis of blood present in the medulla.

Ziehl-Neelsen staining in both lymph nodes was positive for large numbers of medium-sized, slender, acid-fast bacilli along the edges of the necrotic caseous exudate. The bacilli often formed thick clumps. Acid-fast bacilli were

also present in large numbers in the cytoplasm of macrophages, epithelioid cells and multinucleated giant cells surrounding the necrotic centre, as well as in the multifocal nests formed by these cells.

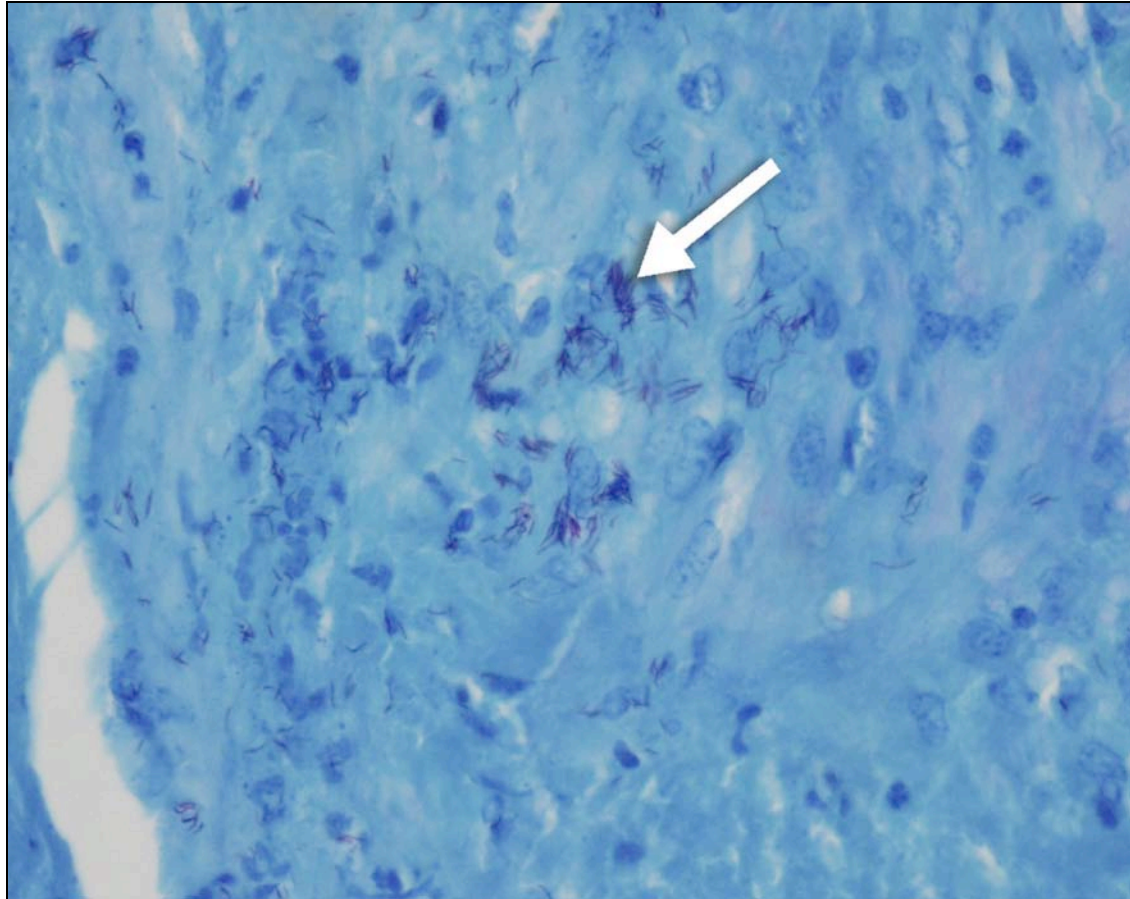


Fig. 3.6. Springbok A1, mediastinal lymph node. Numerous acid-fast bacilli in macrophages within a granulomatous lesion (arrow). ZN. 400x

Spleen (Figs. 3.7 and 3.8):

There was marked multifocal to confluent necrotic to necrogranulomatous splenitis, represented by coagulative to caseous necrotic macrophage aggregates in the red pulp. The necrotic areas were infiltrated by moderate numbers of neutrophils. Moderate numbers of macrophages, and low numbers of multinucleated giant cells, were also present throughout the red

pulp. There was moderate extramedullary haematopoiesis. Medium-sized, slender, acid-fast bacilli were numerous in the cytoplasm of most macrophages after ZN staining.

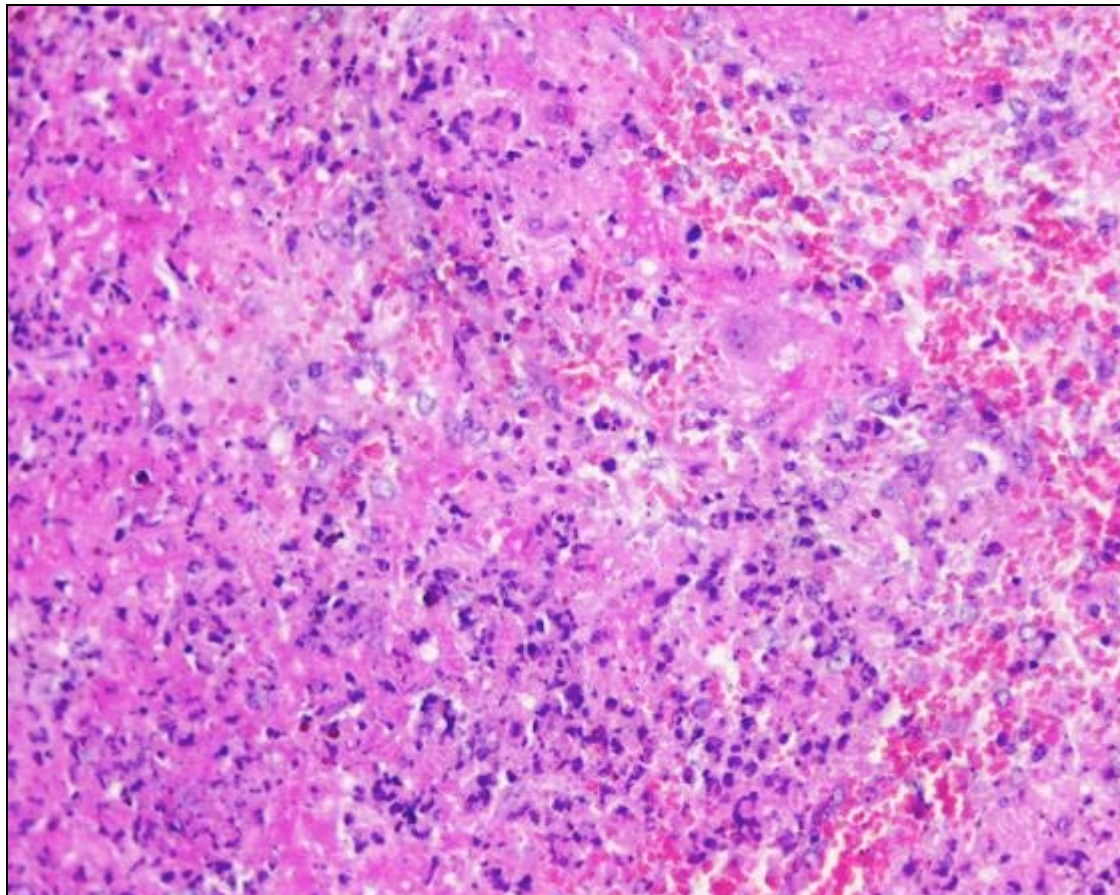


Fig. 3.7. Springbok A1, spleen. Multifocal to confluent necrosis. H&E. 200x

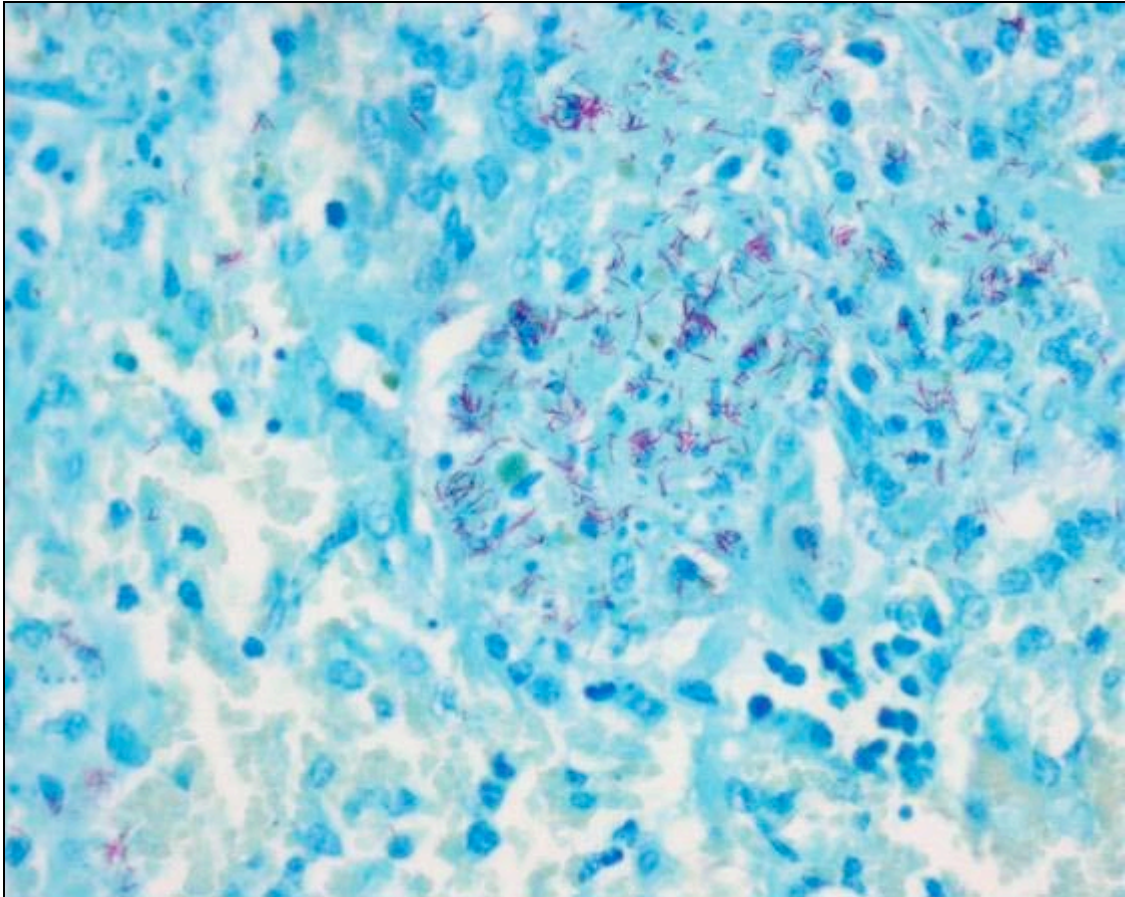


Fig. 3.8. Springbok A1, spleen. Numerous acid-fast bacilli in macrophages within a necrogranulomatous lesion. ZN. 400x

Liver (Figs. 3.9, 3.10 and 3.11):

There was marked focally disseminate coagulative necrosis of hepatocytes, with mild to moderate neutrophil and macrophage infiltration. The sinusoids and portal tracts were infiltrated by low to moderate numbers of macrophages, and low numbers of multinucleated giant cells, that often formed small microgranulomas. Moderate numbers of macrophages occurred in the portal venules and lymphatics, as well as in the central veins. There was a focal area of capsular proliferative fibroplasia and mature fibrosis. Ziehl-Neelsen staining showed numerous medium-sized, slender, acid-fast bacilli in necrotic

areas, and low to moderate numbers in the cytoplasm of macrophages of both the macrophages occurring throughout the liver, as well as those inside portal venules and lymphatics, and central veins.

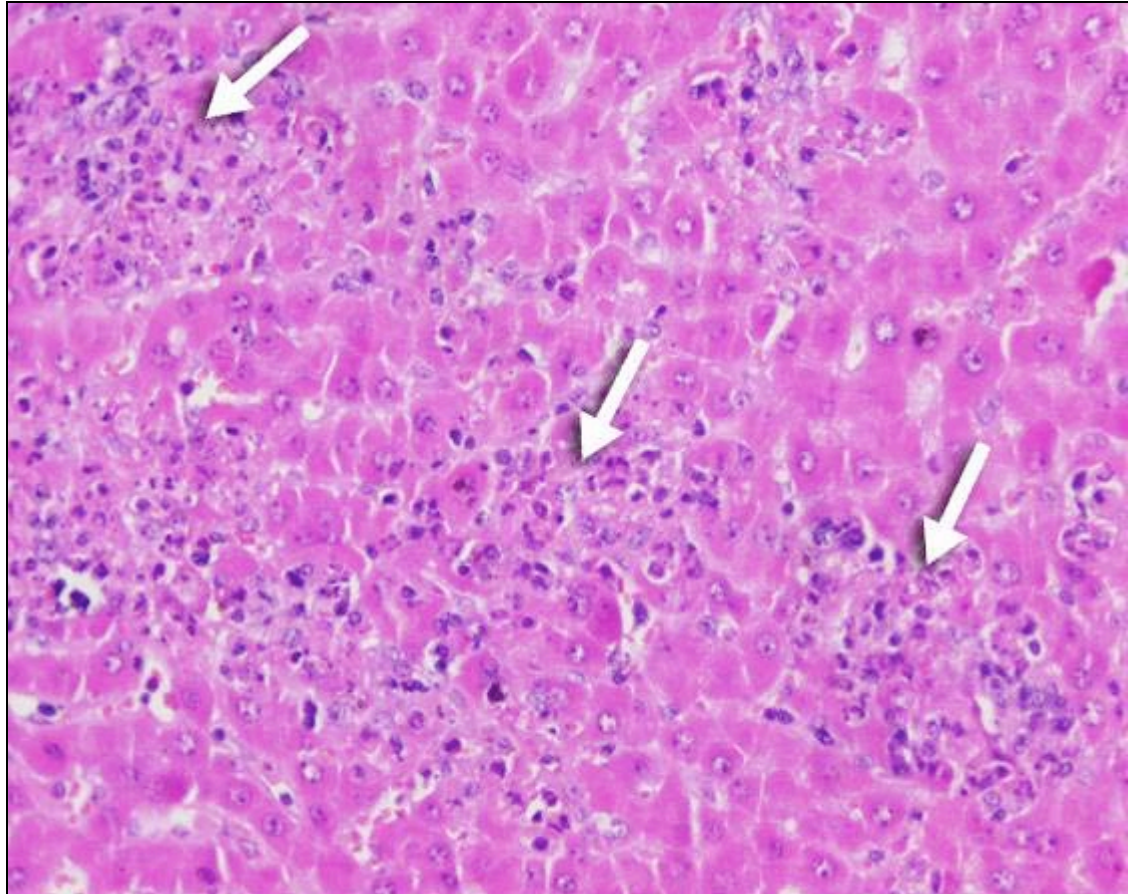


Fig. 3.9. Springbok A1, liver. Focally disseminate necrosis (arrows). H&E. 200x

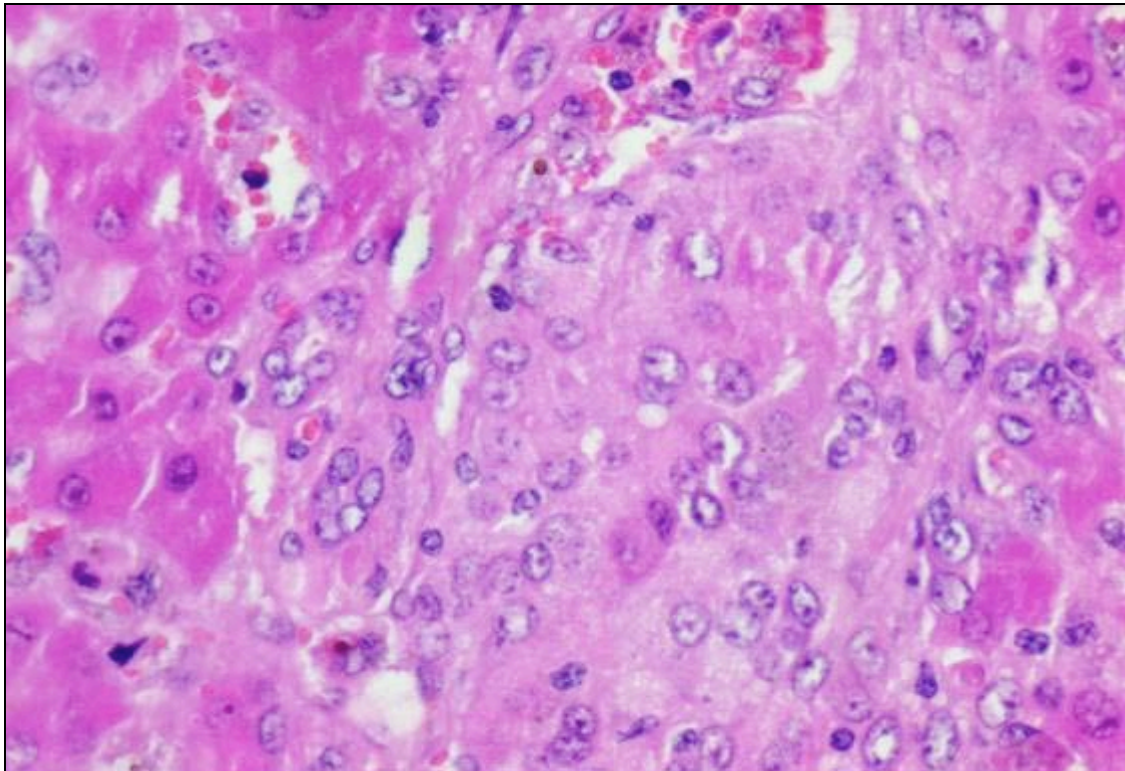


Fig. 3.10. Springbok A1, liver. Granuloma in a portal tract consisting of macrophages and epithelioid cells. H&E. 400x

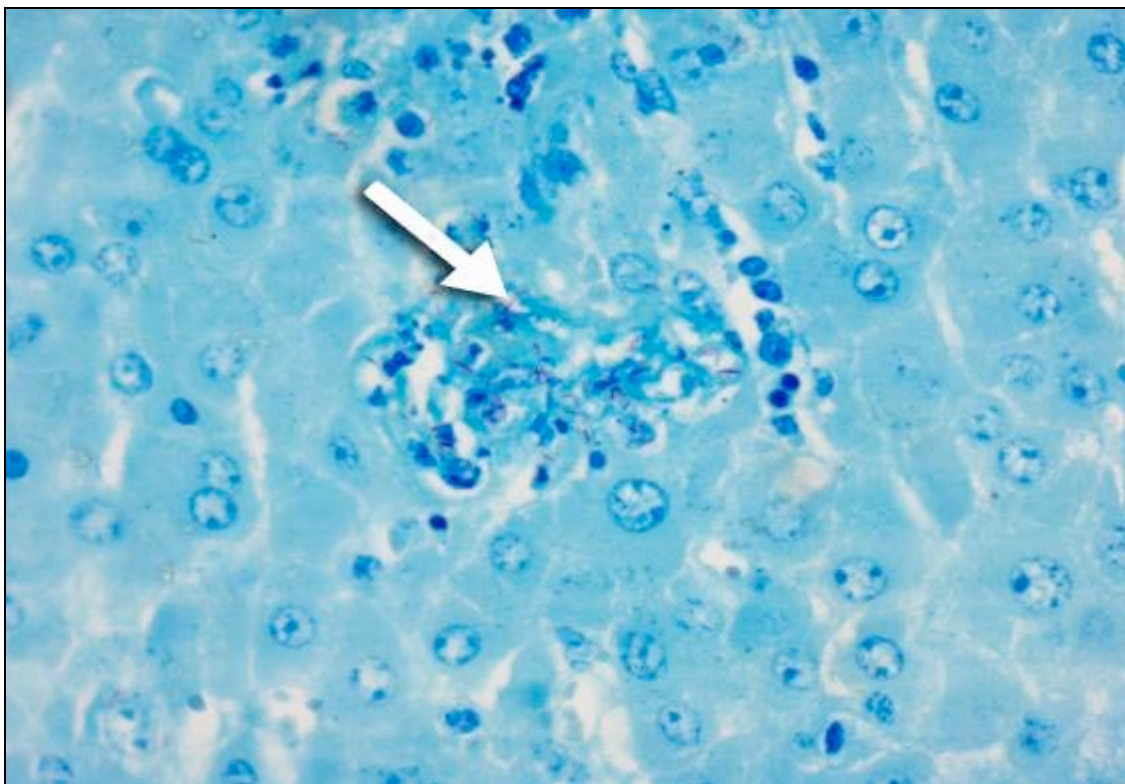


Fig. 3.11. Springbok A1, liver. Acid-fast bacilli in macrophages within a granulomatous lesion (arrow). ZN. 400x

Kidney (Figs. 3.12, 3.13 and 3.14):

Numerous multifocal necrogranulomas occurred in the cortex and cortico-medullary junction. These microgranulomas consisted of low to moderate numbers of central macrophages, some of which were necrotic, surrounded by moderate to large numbers of lymphocytes and plasma cells. With ZN staining large numbers of medium-sized, slender, acid-fast bacilli were found in the cytoplasm of macrophages in the microgranulomas, but were also noted in scattered individual macrophages. A few acid-fast bacilli were also present in the cytoplasm of mesangial cells in a few renal corpuscles.

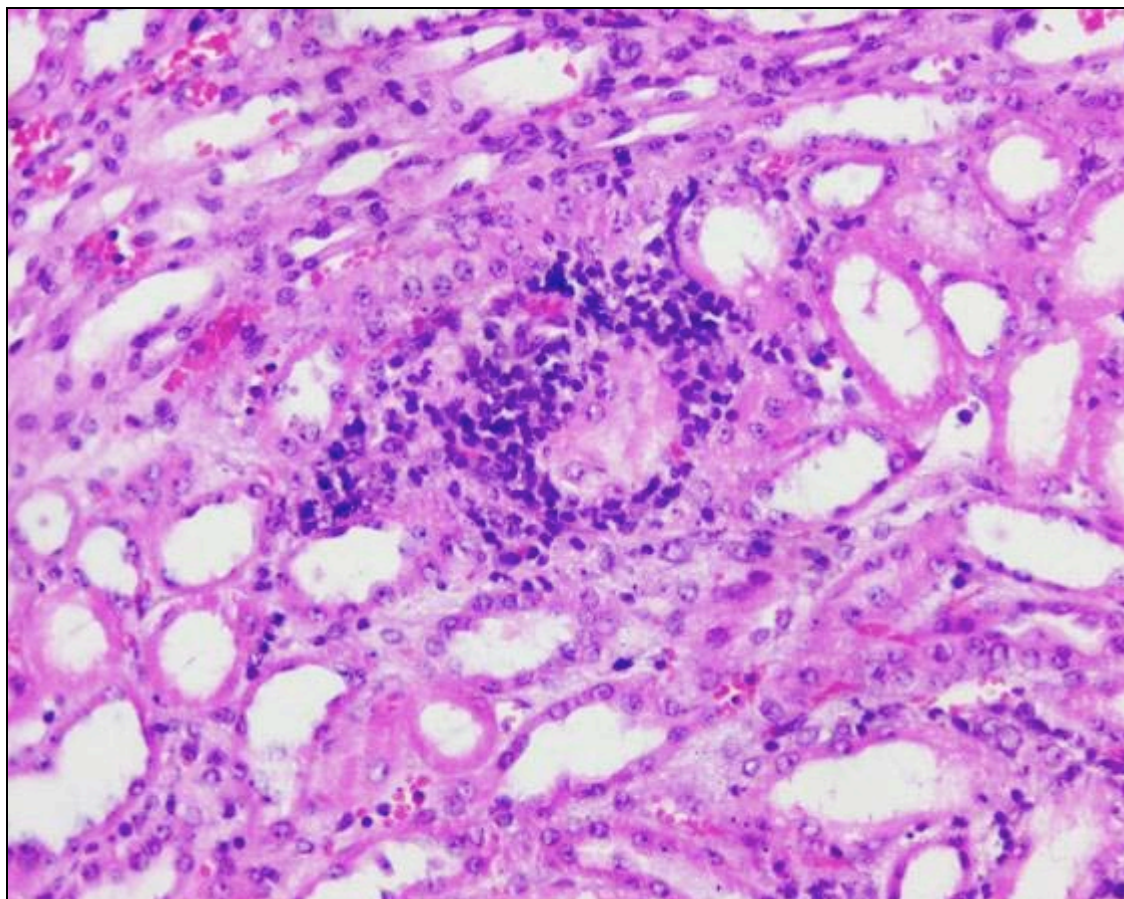


Fig. 3.12. Springbok A1, kidney. Granuloma in the cortex consisting of central macrophages surrounded by lymphocytes and plasma cells. H&E. 200x

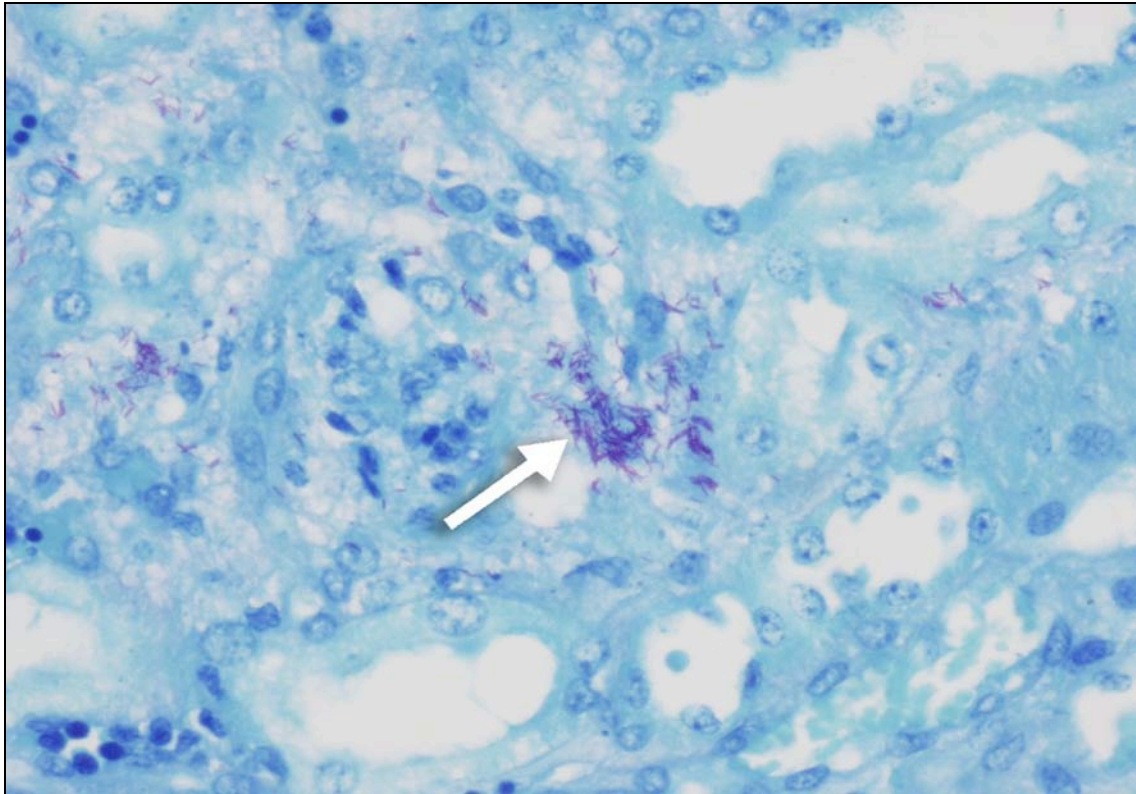


Fig. 3.13. Springbok A1, kidney. Numerous acid-fast bacilli in macrophages within granulomatous lesions (arrow). ZN. 400x

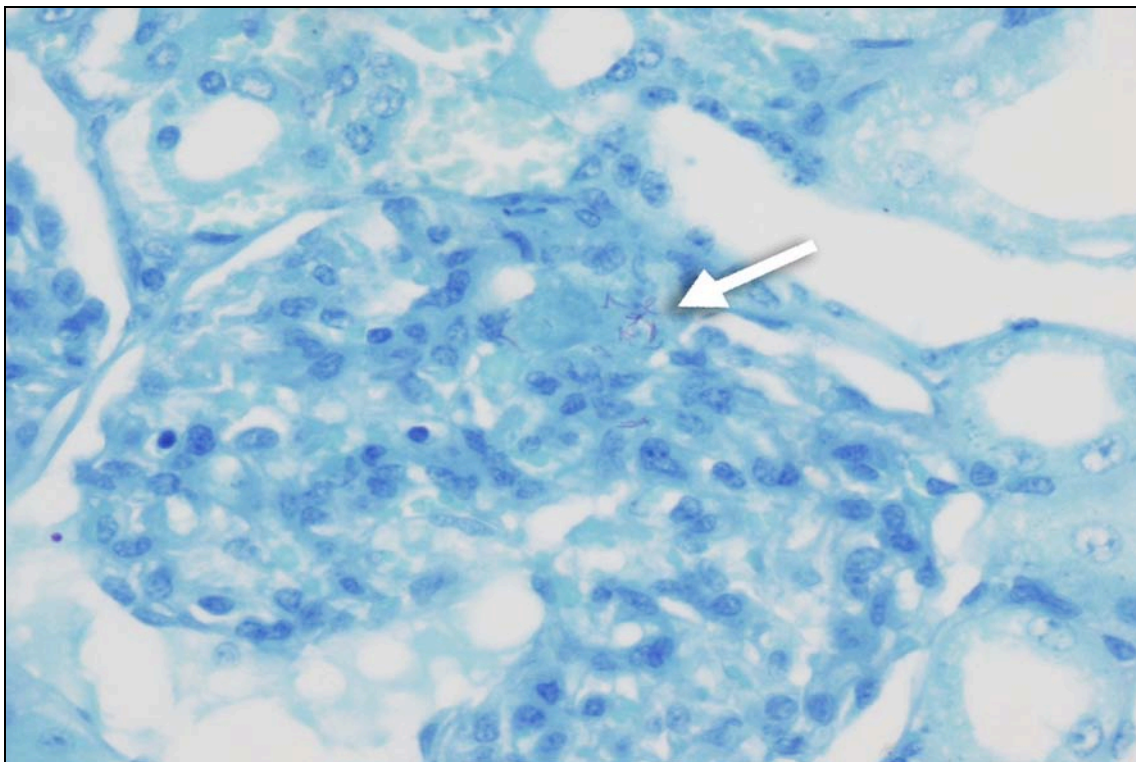


Fig. 3.14. Springbok A1, kidney. Acid-fast bacilli in mesangial cells of a renal corpuscle (arrow). ZN. 400x

Adrenal gland (Fig. 3.15):

There was marked hyperplasia of the *zona fasciculata* with marked accumulation of clear, single to multiple, variably-sized, round vacuoles in the cytoplasm of the cells, representing lipid droplets. Scattered cells in this zone were necrotic. There was scanty macrophage infiltration in the sinusoids of all zones of the cortex. ZN staining revealed moderate numbers of medium-sized, slender, acid-fast bacilli, often forming clumps, in the cytoplasm of macrophages and scattered parenchymal cells of all zones of the cortex.

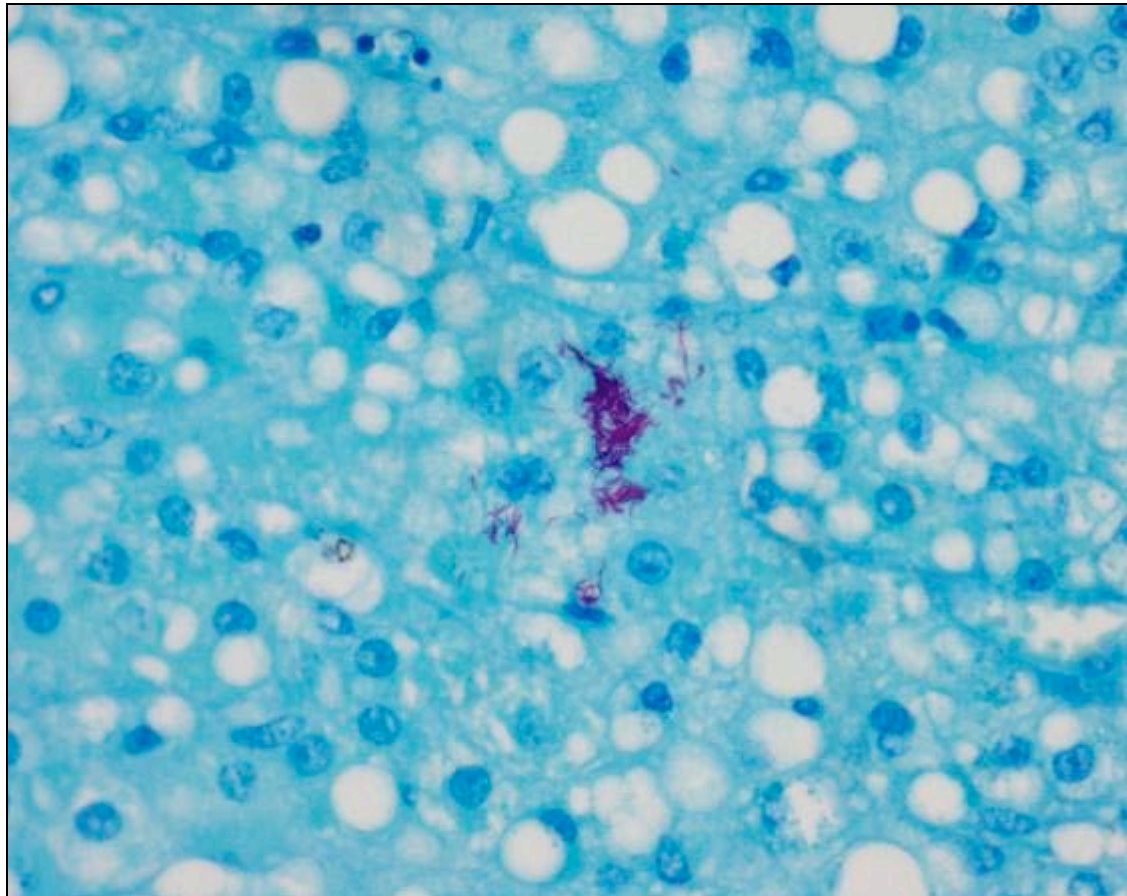


Fig. 3.15. Springbok A1, adrenal gland. Clusters of acid-fast bacilli in macrophages within the cortex. ZN. 400x

Gastro-intestinal tract (Fig. 3.16):

The small intestine, colon and rectum showed scanty to low numbers of multifocal nests of macrophages in the lamina propria of the mucosa. These organs, as well as the abomasum, also had low numbers of widely scattered individual macrophages in the same location. The lamina propria of the mucosa of the small intestine was also infiltrated by moderate numbers of lymphocytes and plasma cells. Scanty nematode larvae were present in gastric glands of the mucosa of the abomasum, without an inflammatory reaction. Ziehl-Neelsen staining of the abomasum, small intestine, colon and rectum revealed low to moderate numbers of medium-sized, slender, acid-fast bacilli in the cytoplasm of macrophages located in the mucosa.

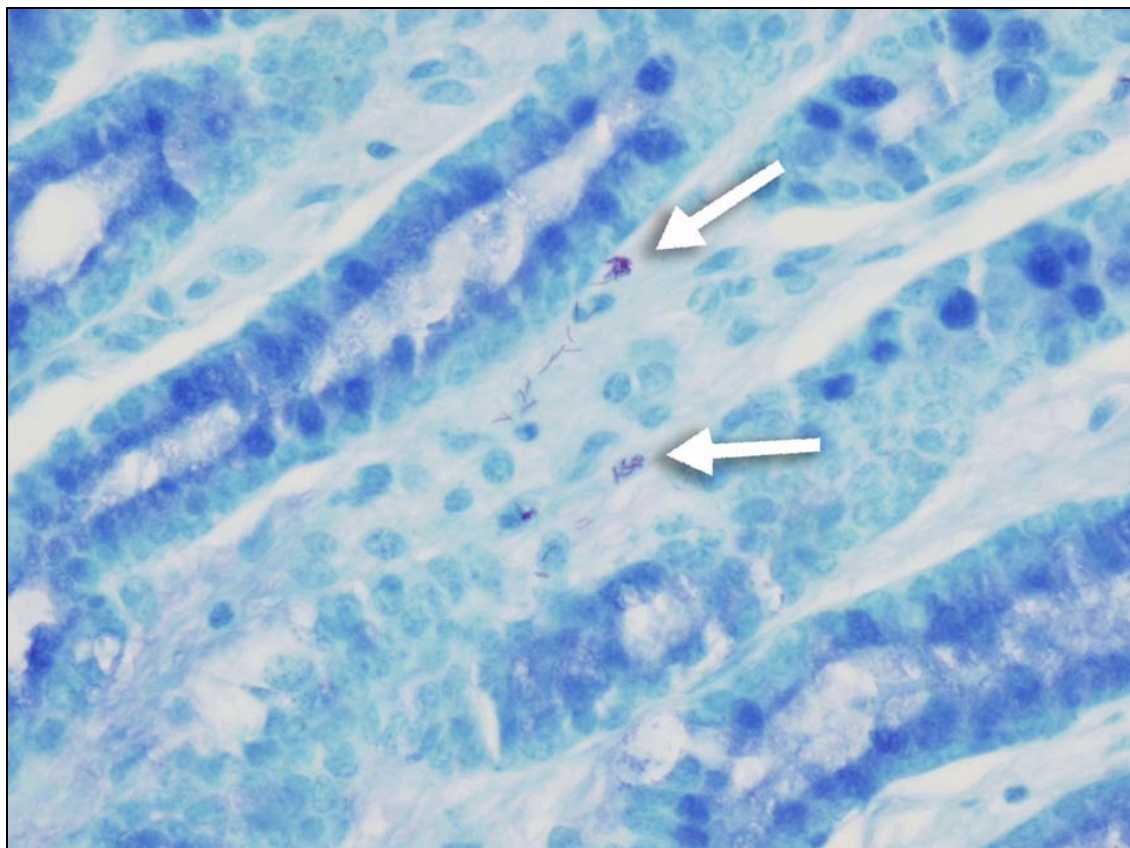


Fig. 3.16. Springbok A1, rectum. Acid-fast bacilli in macrophages within the lamina propria of the mucosa (arrows). ZN. 400x

A2

Lung:

The lungs were markedly autolysed and putrefied, with the presence of numerous mixed bacteria many of which morphologically resembled *Clostridium* spp. There were multifocal areas of what appeared to be coagulative and caseous necrosis, separated from the adjacent lung tissue by a prominent reaction zone consisting of haemorrhage, fibrin exudation and possible neutrophils. Large numbers of Gram-negative cocco-bacilli were present in the necrotic areas and reaction zone. The remainder of the lungs showed marked haemorrhage, protein-rich alveolar oedema, fibrin exudation and widespread alveolar macrophage infiltration. All sections stained negatively for acid-fast bacilli with ZN staining. The lung lesions probably reflect necrotic bacterial pneumonia with possible early abscessation.

Lymph node:

The respiratory lymph nodes showed similar advanced post-mortem changes to the lungs. There was a focal area of suspected coagulative necrosis in the cortex, with accumulation of fibrin and necrotic cellular debris. Ziehl-Neelsen staining was negative for acid-fast bacilli.

3.1.1.2 BACTERIOLOGY

Mycobacterium tuberculosis was isolated from a mediastinal lymph node of A1. The lung specimens from A2 were negative for *Mycobacterium* spp. after 10 weeks incubation.

3.1.2 PART TWO: PILOT STUDY

Three adult (B3, B5 and B6) and three sub-adult (B1, B2 and B4) rams were sampled.

3.1.2.1 MACROSCOPIC AND MICROSCOPIC PATHOLOGY

3.1.2.1.1 MACROSCOPIC PATHOLOGY

All the animals were in good condition, except for B4 which showed moderate emaciation. B2 and B6 did not show any noteworthy macroscopic lesions. Significant lesions were found in the following organs of the other animals:

Lung (Figs. 3.17, 3.18, 3.19 and 3.20):

The lungs of B4 showed lesions highly suggestive for tuberculosis. There were four large and fairly distinctly demarcated, multifocal, granulomatous, nodular lesions. One was situated in the cranial edge of the left cranial lobe, was irregularly ovoid and 20 x 10mm in size, yellowish in colour, granulomatous and non-encapsulated. Two granulomas that occurred in the

dorso-caudal area of the left and right caudal lobe respectively, were similar in appearance. They were round and 20mm in diameter, and had an indistinct arborescent central area of yellowish caseous necrosis containing numerous individual necrotic foci measuring 1 to 2mm in diameter. The individual necrotic foci and entire nodules were surrounded by mildly developed fibrous connective tissue. The fourth granuloma occurred in the cranio-medial aspect of the right caudal lobe and was round, 30mm in diameter with a central, pale yellow, caseous necrotic area surrounded by a well-developed fibrous capsule. Apart from these large nodular granulomas, there were numerous non-encapsulated, multifocal to confluent, translucent to greyish white, round to irregular granulomas measuring 1 to 5mm in diameter distributed throughout the lung parenchyma.

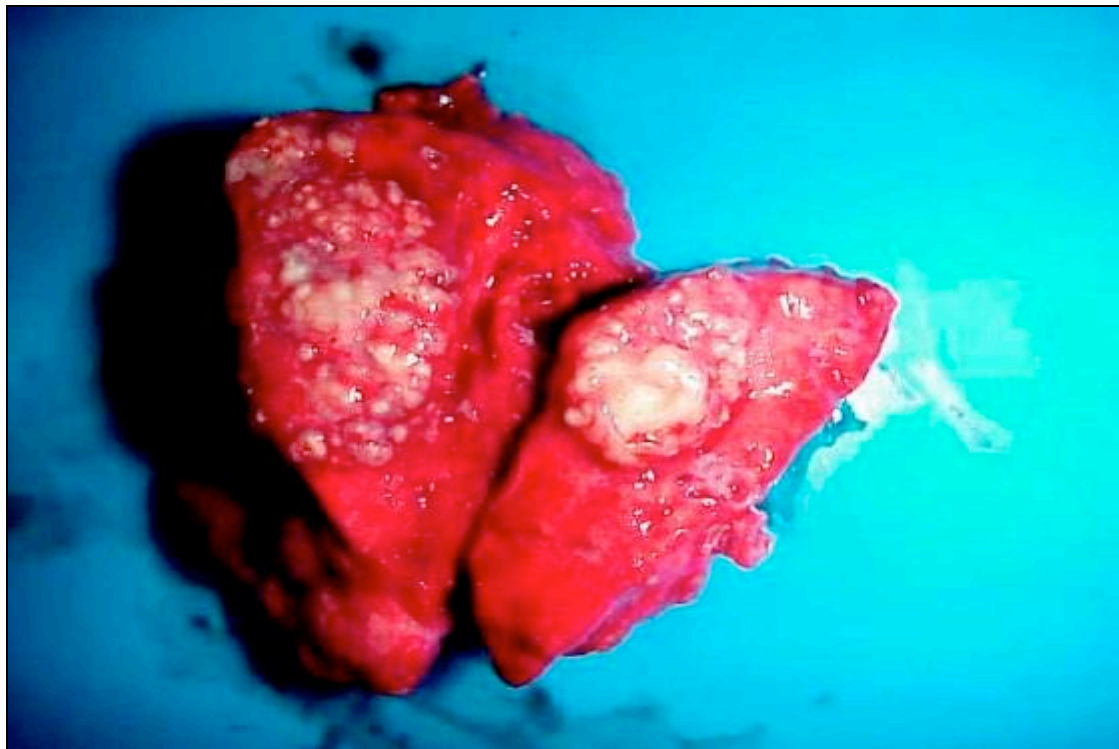


Fig. 3.17. Springbok B4, lung. Granulomas showing indistinct arborescent central caseous necrosis with numerous individual encapsulated necrotic foci.

The entire visceral and parietal pleura was covered in numerous, multifocal to confluent, round to ovoid, translucent to pale whitish, non-encapsulated plaques and nodules, measuring 1 to 10mm in diameter. These nodules resembled “TB-grapes” and consisted mostly of fibrous connective tissue showing no to mild multifocal areas of pale yellowish caseous necrosis measuring 1 to 5mm in diameter on cut section.

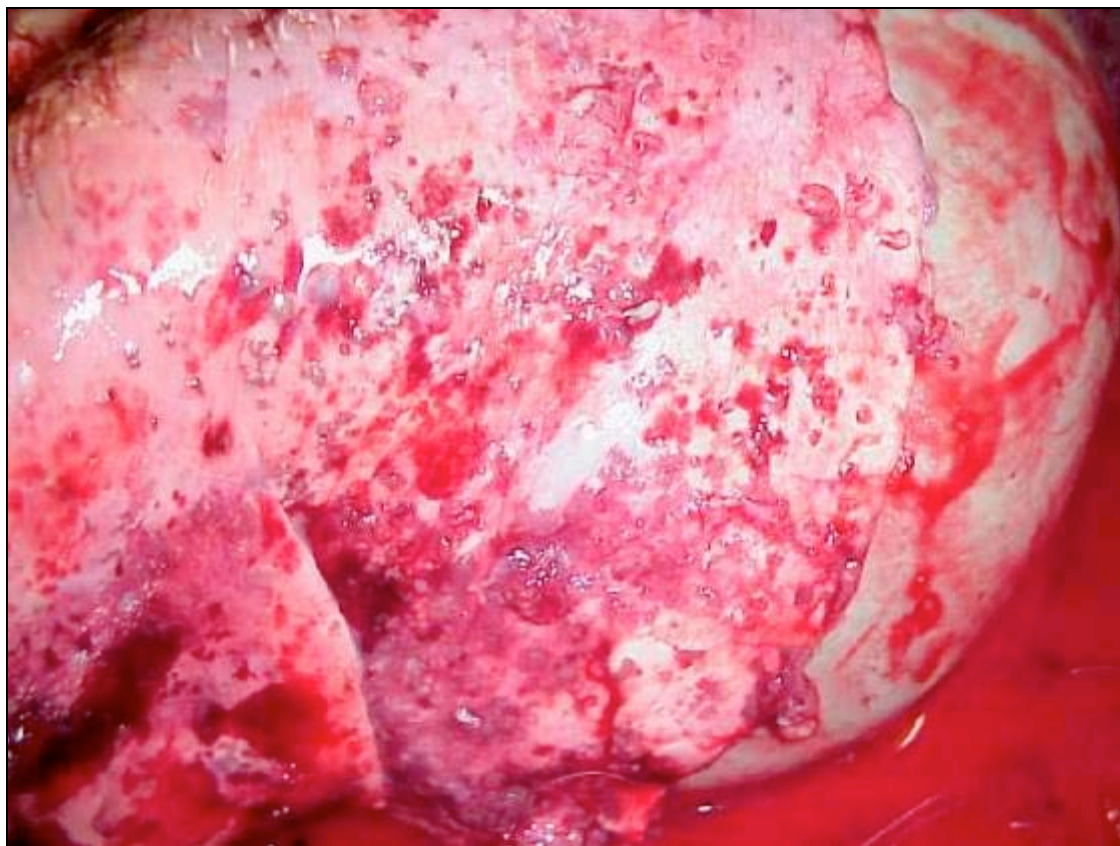


Fig. 3.18. Springbok B4, lung. Translucent to pale whitish plaques and nodules in the pleura.

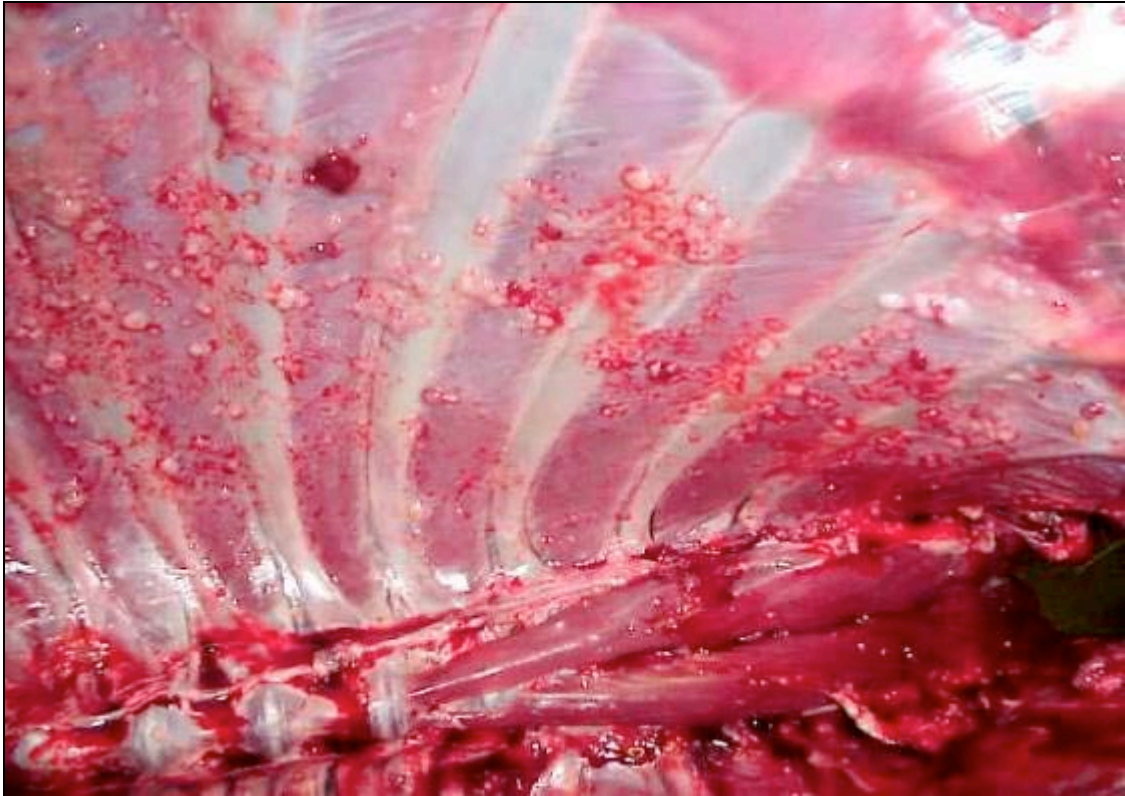

Fig 3.19. Springbok B4, parietal pleura. “TB-grapes” attached to the pleura.

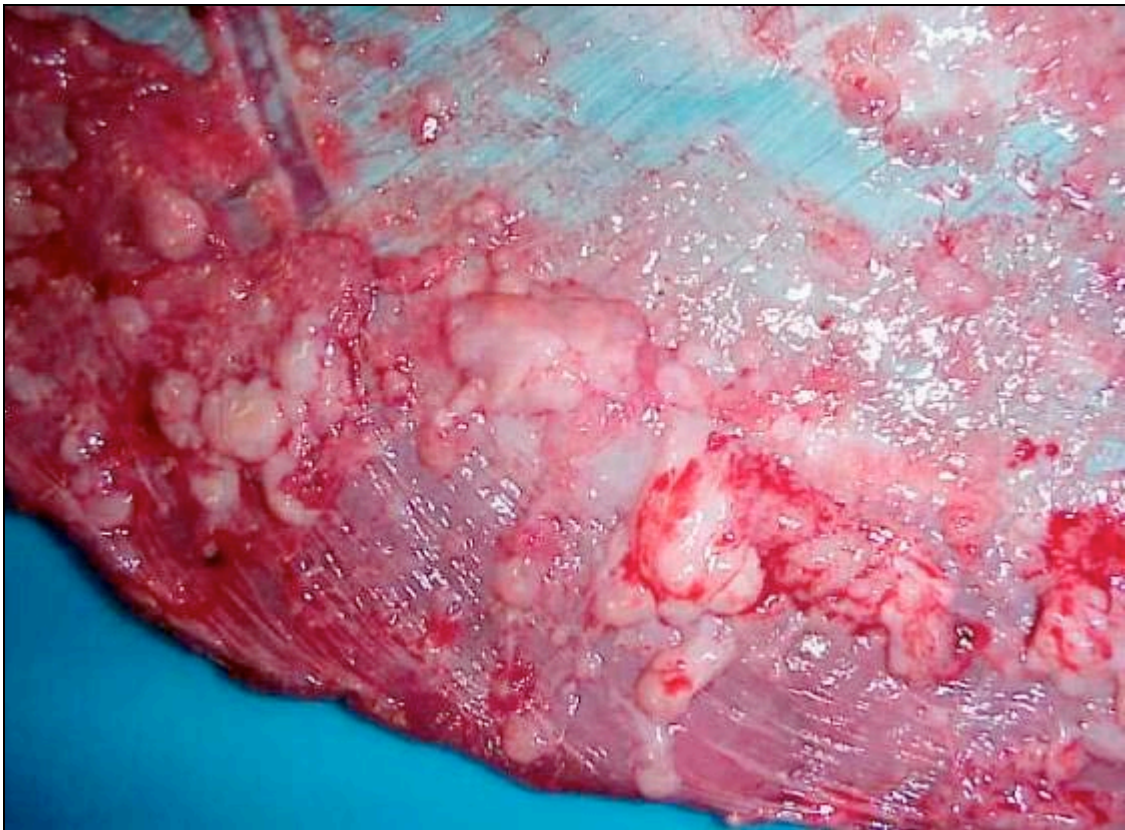

Fig. 3.20. Springbok B4, diaphragm. “TB-grapes” attached to the pleura.

B5 displayed moderate numbers of adult *Bronchonema magna* nematodes in the lumen of the trachea and both bronchi, especially at the tracheal bifurcation.

Liver:

The livers of B1, B3 and B4 showed scanty to low numbers of multifocal, round, distinctly outlined, pinpoint to 3mm diameter, pale white foci randomly distributed throughout the parenchyma.

Lymph node:

The following lymph nodes of B4 showed macroscopic lesions highly suggestive for tuberculosis:

Bronchial: Multifocal to coalescing, non-encapsulated, round to ovoid, pale yellowish, caseous necrotic to granulomatous areas measuring 1 to 15mm in diameter, with mild to moderate calcification.

Mediastinal: Multifocal to coalescing, non-encapsulated, ovoid to irregular, granulomatous areas measuring 2 to 18mm in diameter. There was a small focal, round, 1mm diameter area of dull yellowish necrosis.

Sternal: Multifocal, non-encapsulated, round, whitish to slightly yellowish, necrotic areas of up to 1mm in diameter, and a focal, round, non-encapsulated area of granulomatous inflammation measuring 4mm in diameter.

Iliac: Multifocal, encapsulated, round to oval, pale yellowish, caseous necrotic foci measuring 3 to 7mm in diameter, with moderate calcification.

Right prefemoral: Focal, non-encapsulated, round area of yellowish caseous necrosis measuring 3mm in diameter, with moderate calcification.

Right retropharyngeal: Focal, non-encapsulated, round area of slightly yellow-tinged necrosis measuring 1mm in diameter.

3.1.2.1.2 MICROSCOPIC PATHOLOGY

The microscopical lesions of the organs mentioned above, as well as significant lesions detected in other organs, are described below. Multinucleated giant cells were always of both the Langhans' and foreign-body type, except where otherwise indicated. All lesions in all organs were negative for acid-fast bacilli with ZN staining, except where otherwise stated.

Lung (Figs. 3.21, 3.22 and 3.23):

The lungs of B4 showed numerous multifocal to confluent necrogranulomas throughout the parenchyma. The necrogranulomas consisted of a central area of caseous necrosis that was often moderately calcified, surrounded by large numbers of macrophages and epithelioid cells, and low to moderate numbers of multinucleated giant cells. Enveloping this layer was an outer layer consisting of low to moderate numbers of lymphocytes and plasma cells, within a moderately developed fibrous capsule. Some granulomas did not show central necrosis. A few necrogranulomas showed infiltration of moderate numbers of neutrophils into the necrotic centre with occasional pus formation. The surrounding bronchioles were plugged with necrotic cellular debris consisting of neutrophils, macrophages and respiratory epithelial cells.

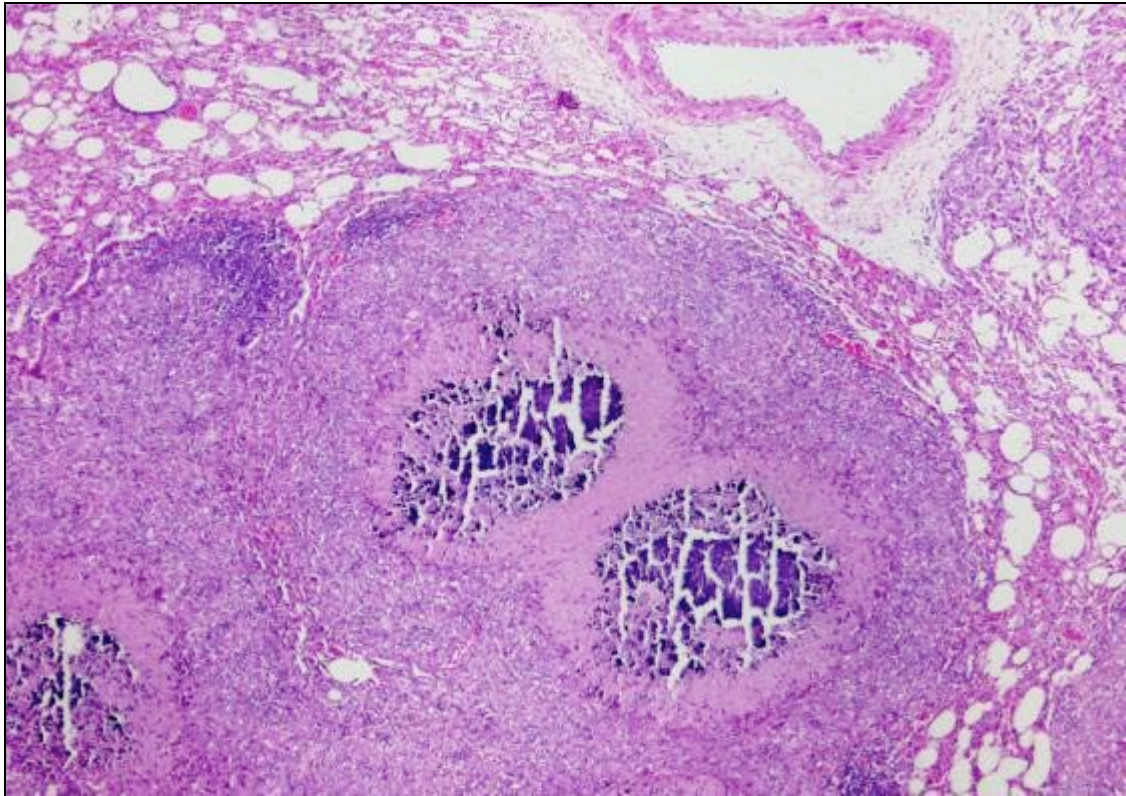


Fig. 3.21. Springbok B4, lung. Necrogranulomas with central caseous necrosis and moderate calcification. H&E. 40x

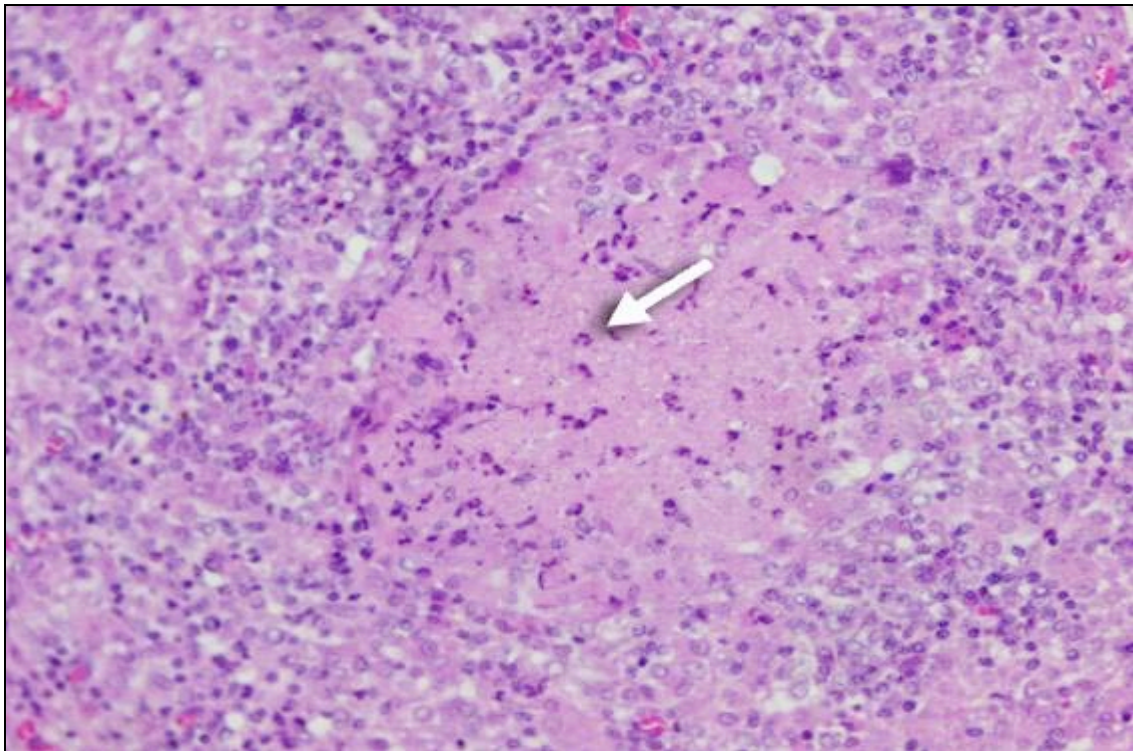


Fig. 3.22. Springbok B4, lung. Necrogranulomas with central caseous necrosis infiltrated by neutrophils (arrow). H&E. 200x

The pleura showed a proliferative response characterized by prominent fibroplasia with moderate numbers of multifocal to confluent granulomas that showed occasional central coagulative to caseous necrosis. The granulomas consisted of large numbers of macrophages and epithelioid cells, and moderate numbers of lymphocytes and plasma cells. Scanty to low numbers of neutrophils infiltrated the granulomas. The mesothelium showed moderate hypertrophy and hyperplasia.

Ziehl-Neelsen staining of the lungs and pleura revealed low numbers of medium-sized, slender acid-fast bacilli in the cytoplasm of macrophages, epithelioid cells and multinucleated giant cells of the granulomas. Moderate numbers of acid-fast bacilli were present along the peripheral edge of the necrotic exudate in some necrogranulomas.

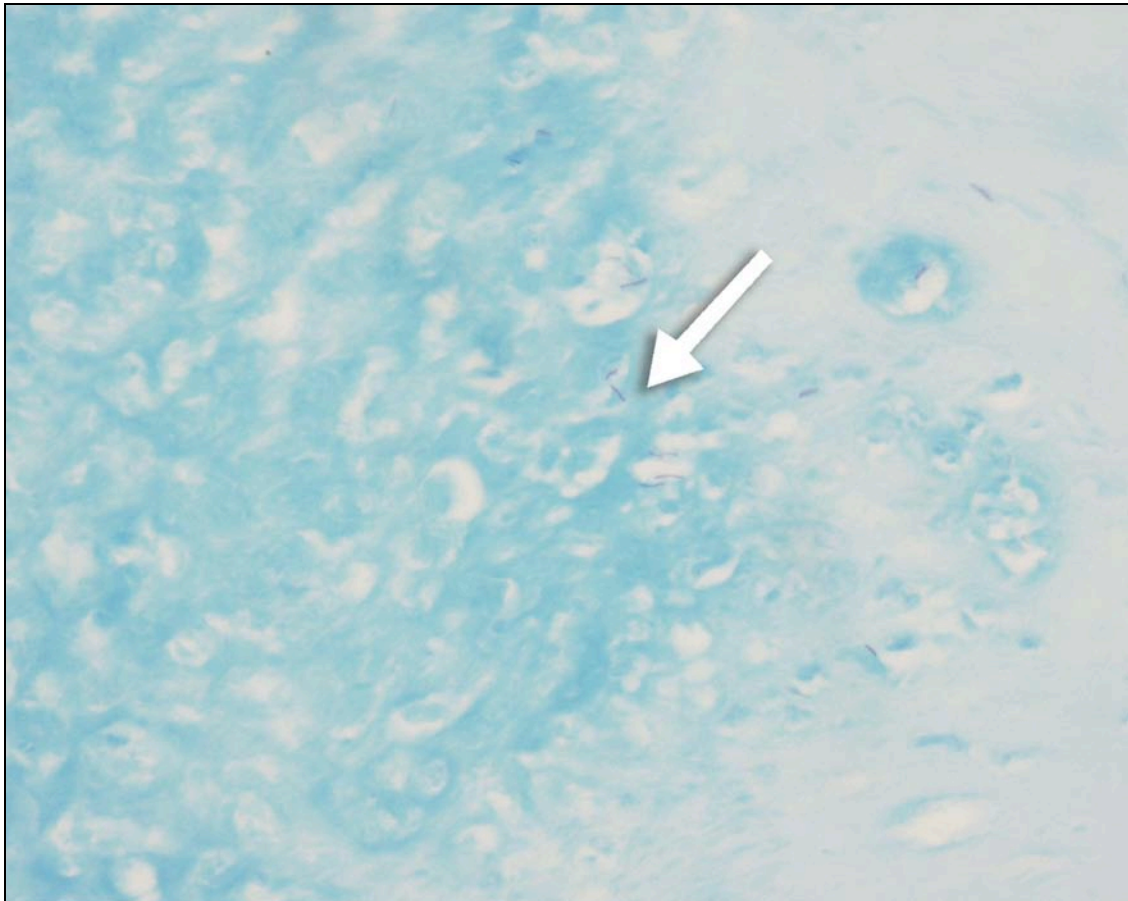

Fig. 3.23. Springbok B4, pleura. Low numbers acid-fast bacilli in macrophages within a granulomatous lesion (arrow). ZN. 400x

The lungs of B5 displayed low numbers of adult nematodes in some bronchioles. There was mild to moderate epithelial and smooth muscle hypertrophy and hyperplasia of bronchioles, with infiltration of small numbers of eosinophils, lymphocytes and plasma cells in the lamina propria of the bronchiolar epithelium, and occasionally perivascularly. Low numbers of globular leukocytes, with moderate to abundant, variably-sized, round, eosinophilic, cytoplasmic globules, occurred in the intercellular areas of the bronchiolar epithelium.

Liver:

The macroscopic multifocal pale white foci in the livers of B1, B3 and B4 consisted of nodular portal aggregations of moderate to large numbers of lymphocytes and plasma cells; scanty eosinophils and macrophages were found only in B4. The liver of B5 showed a focal lesion similar to B4 but with only scanty eosinophil infiltration (no macrophages). A small focal granuloma occurred in the parenchyma of B5, which consisted of central caseous necrosis surrounded by small numbers of macrophages, epithelioid cells and eosinophils. All animals showed infiltration of scanty to low numbers of lymphocytes, plasma cells and eosinophils in the portal tracts, without the formation of distinct nodules. The liver lesions were probably a response to previous parasitic larval migration.

Lymph node:

The lymph nodes of B4 that had macroscopic lesions showed the following changes:

Bronchial (Figs. 3.24, 3.25 and 3.26): There were multifocal to confluent necrogranulomas consisting of a central caseous necrotic area that was moderately calcified, with a surrounding layer of moderate numbers of macrophages, epithelioid cells and scanty multinucleated giant cells, admixed with moderate numbers of lymphocytes and plasma cells. There was a poorly to moderately developed outer fibrous capsule. Numerous small multifocal granulomas, that did not show central necrosis and calcification, occurred in the remainder of the lymph node. These granulomas consisted of small

numbers of macrophages and epithelioid cells, and numerous (mostly Langhans') giant cells. Ziehl-Neelsen staining revealed low numbers of medium-sized, slender, acid-fast bacilli in the peripheral edge of the necrotic centre of necrogranulomas, and also in the cytoplasm of macrophages surrounding the necrotic centre.

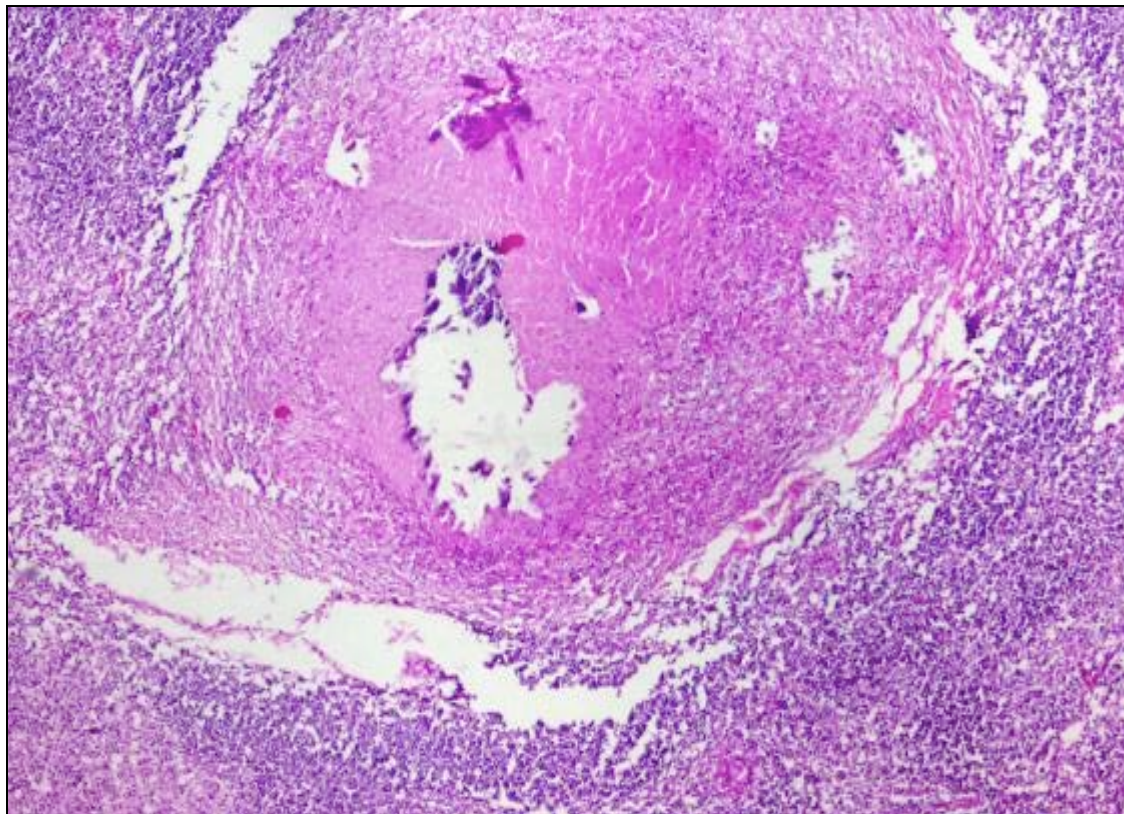


Fig. 3.24. Springbok B4, bronchial lymph node. Necrogranuloma with central caseous necrosis and moderate calcification. H&E. 40x

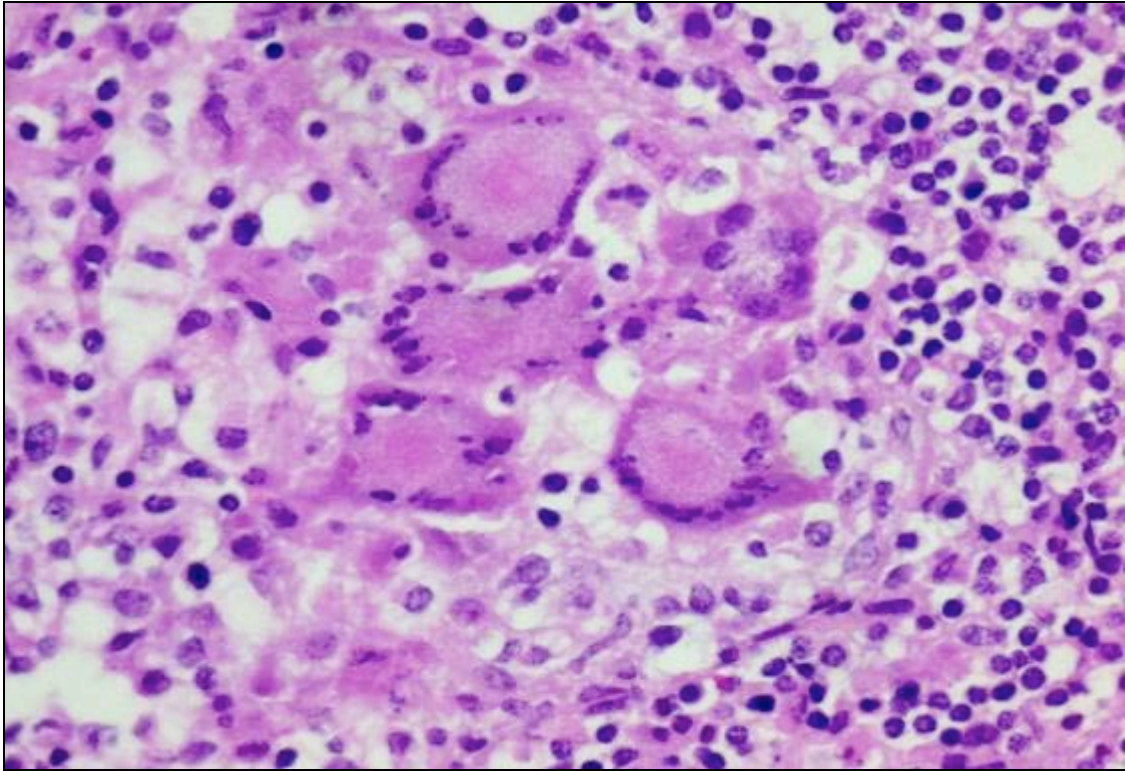


Fig. 3.25. Springbok B4, bronchial lymph node. Granuloma consisting mostly of Langhans' giant cells. H&E. 400x

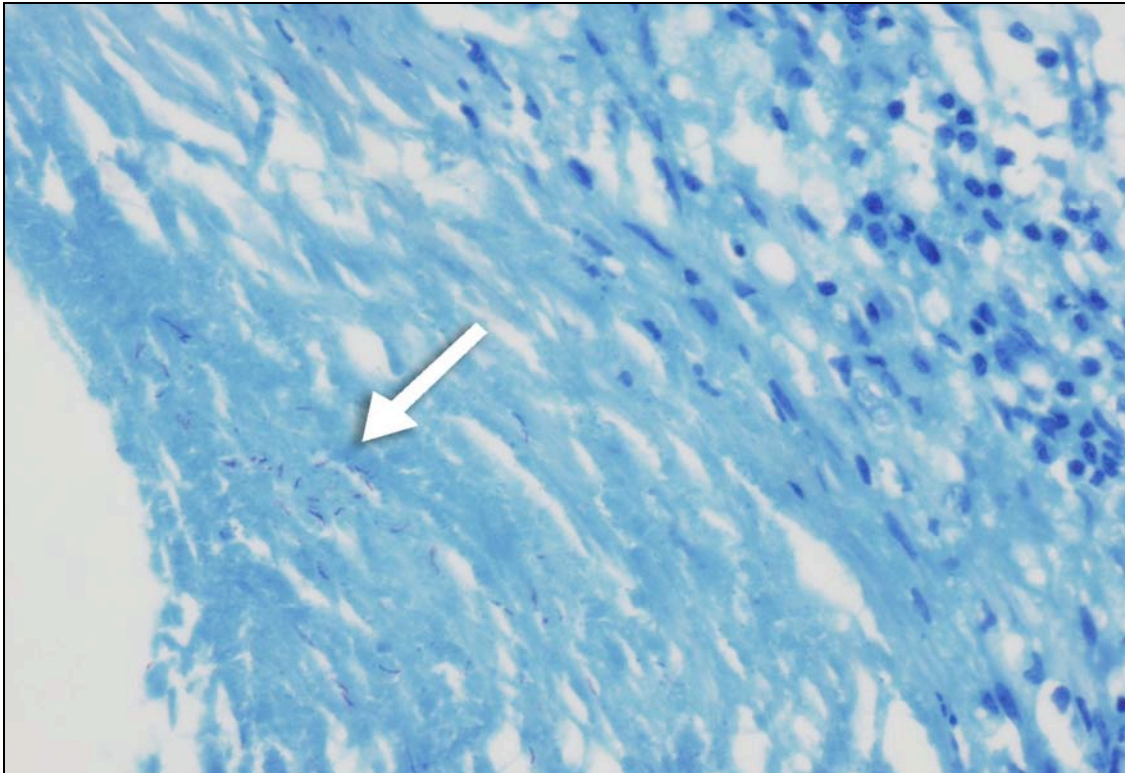

Fig. 3.26. Springbok B4, bronchial lymph node. Low numbers of acid-fast bacilli in the peripheral edge of the caseous necrotic centre of a necrogranuloma (arrow). ZN. 400x

Mediastinal: Multifocal to coalescing granulomatous lymphadenitis, represented by numerous small granulomas composed of small numbers of macrophages and epithelioid cells, and numerous, mostly Langhans' giant cells. One granuloma showed mild central calcification. Very rare medium-sized, slender, acid-fast bacilli were present in the cytoplasm of epithelioid cells and multinucleated giant cells following ZN staining.

Sternal: There was a focal granuloma that displayed central caseous necrosis with moderate calcification. This was surrounded by moderate numbers of macrophages and epithelioid cells, and scanty multinucleated giant cells, admixed with moderate numbers of lymphocytes and plasma cells. There was a poorly-developed fibrous capsule. Numerous small multifocal granulomas, similar in appearance to the small granulomas in the bronchial lymph node, occurred in the remainder of the lymph node. Ziehl-Neelsen staining revealed rare medium-sized, slender, acid-fast bacilli in the peripheral edge of the necrotic centre of the necrogranuloma, and also in the cytoplasm of macrophages that occurred in the small granulomas.

Iliac: There were multifocal necrogranulomas, similar in appearance to the necrogranulomas in the bronchial lymph node, but with more numerous multinucleated giant cells and a well-developed fibrous capsule. A few small granulomas, consisting of low numbers macrophages and epithelioid cells, occurred in the remainder of the lymph node. The pattern of ZN staining was similar to that in the bronchial lymph node.

Right prefemoral: There were multifocal necrogranulomas, similar in appearance to the necrogranulomas in the bronchial lymph node, but with large numbers of multinucleated giant cells. The necrogranulomas were

surrounded by a few satellite granulomas, some showing central caseous necrosis, composed of moderate numbers of macrophages, epithelioid cells, multinucleated giant cells, lymphocytes and plasma cells. Most showed a moderately developed outer fibrous capsule. The pattern of ZN staining was similar to that in the bronchial lymph node.

Right retropharyngeal: There was a focal granuloma that consisted of central caseous necrosis with early calcification, surrounded by numerous macrophages and epithelioid cells, admixed with small numbers of lymphocytes, plasma cells and neutrophils. The macrophages and epithelioid cells exhibited occasional round, variably-sized, single to multiple, clear cytoplasmic vacuoles resembling fat globules. The granuloma had an outer layer of poorly developed fibrous connective tissue. The remainder of the lymph node showed numerous scattered macrophages, epithelioid cells and multinucleated giant cells that were occasionally arranged in granulomas. Ziehl-Neelsen staining revealed very rare medium-sized, slender, acid-fast bacilli in the peripheral edge of the necrotic centre of necrogranulomas, and also in the cytoplasm of macrophages surrounding the necrotic centre.

The microscopic lesions in lymph nodes of B4 that did not exhibit macroscopic abnormalities were as follows:

Left retropharyngeal: There was one poorly-developed granuloma in the cortex that consisted of small numbers of macrophages and epithelioid cells, and scanty multinucleated giant cells. Scanty individual Langhans' giant cells occurred in the cortex and paracortex.

Left mandibular, right mandibular and left prescapular (Fig. 3.27): There was moderate sinus histiocytosis with a few nests composed of small to moderate numbers of macrophages in the cortex.

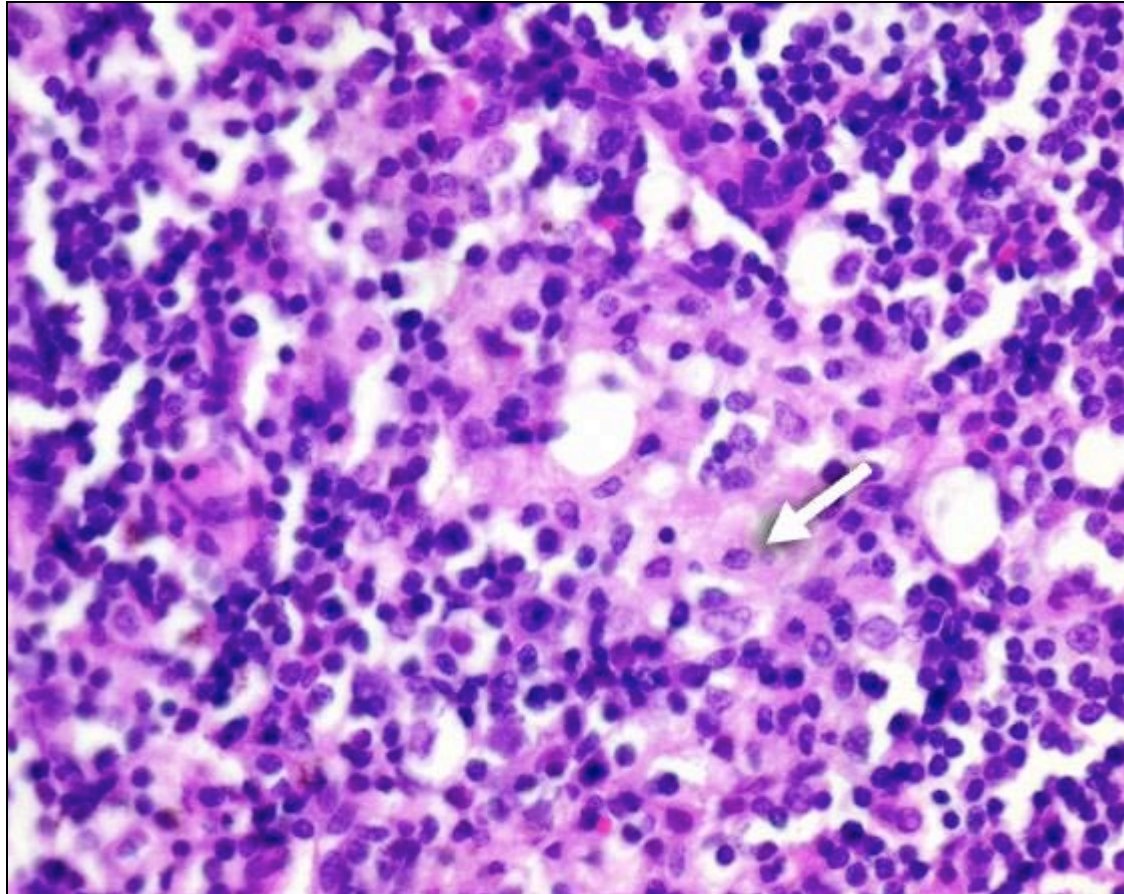


Fig. 3.27. Springbok B4, left mandibular lymph node. Small granuloma in the cortex consisting of a few macrophages (arrow). H&E. 400x

Left prefemoral: A focal granuloma occurred in the cortex and consisted of a central necrotic area that was completely calcified, surrounded by moderate numbers of macrophages and epithelioid cells, numerous multinucleated giant cells and small numbers of lymphocytes, plasma cells, neutrophils and eosinophils. There was a poorly-developed fibrous capsule. Very scanty

medium-sized, slender, acid-fast bacilli were present in the cytoplasm of macrophages after ZN staining.

Mesenteric: There were moderate numbers of small granulomas consisting of moderate numbers of Langhans' giant cells, and smaller numbers of macrophages and epithelioid cells. Scanty individual multinucleated giant cells were also visible.

Ileocaecal (Fig. 3.28): A few small granulomas consisting almost exclusively of multinucleated giant cells occurred in the cortex. One multinucleated giant cell displayed characteristics of both Langhans' and foreign-body giant cells, *i.e.* with nuclei arranged both in a row along the periphery of the cell, and as a group centrally.

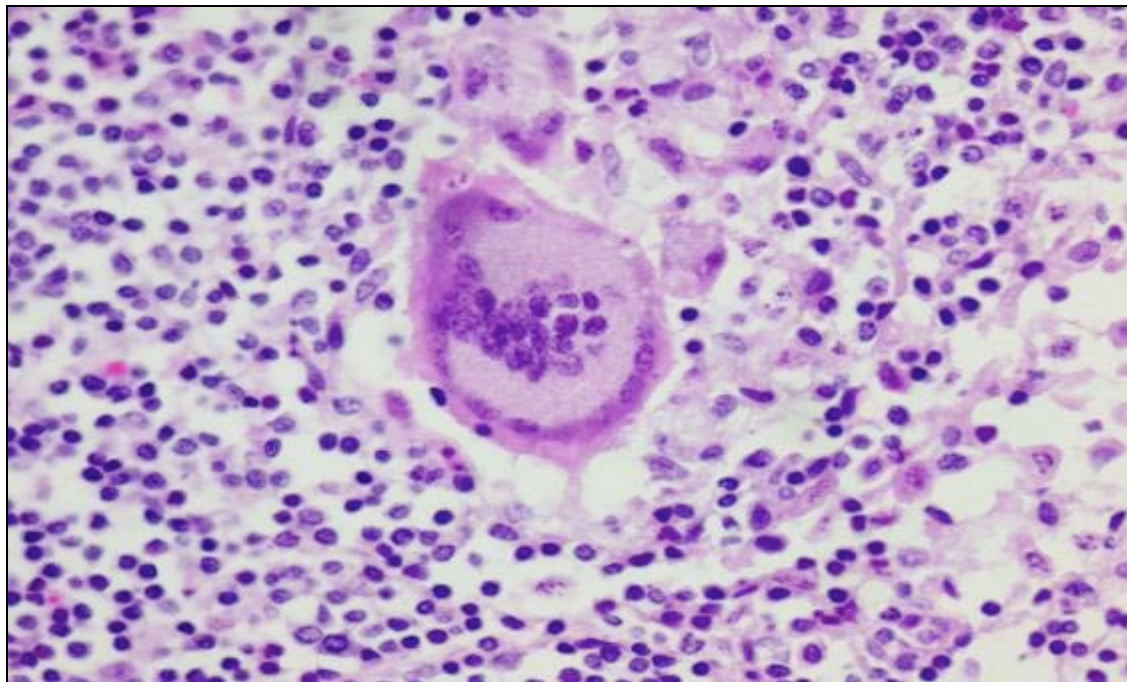


Fig. 3.28. Springbok B4, ileocaecal lymph node. Multinucleated giant cell exhibiting characteristics of both Langhans' and foreign-body type cells. H&E. 400x.

Inguinal: There was a single small granuloma in the cortex which consisted of a few macrophages. Two large individual multinucleated giant cells (one each of the Langhans and foreign-body type) occurred in the cortex.

There was a nest of short, acid-fast bacilli in the cytoplasm of a macrophage in the medulla of a mesenteric lymph node of B2, unaccompanied by an inflammatory reaction (Fig. 3.29). The lymph node also showed small multifocal areas of calcification in the cortex and medulla, and marked sinus histiocytosis.

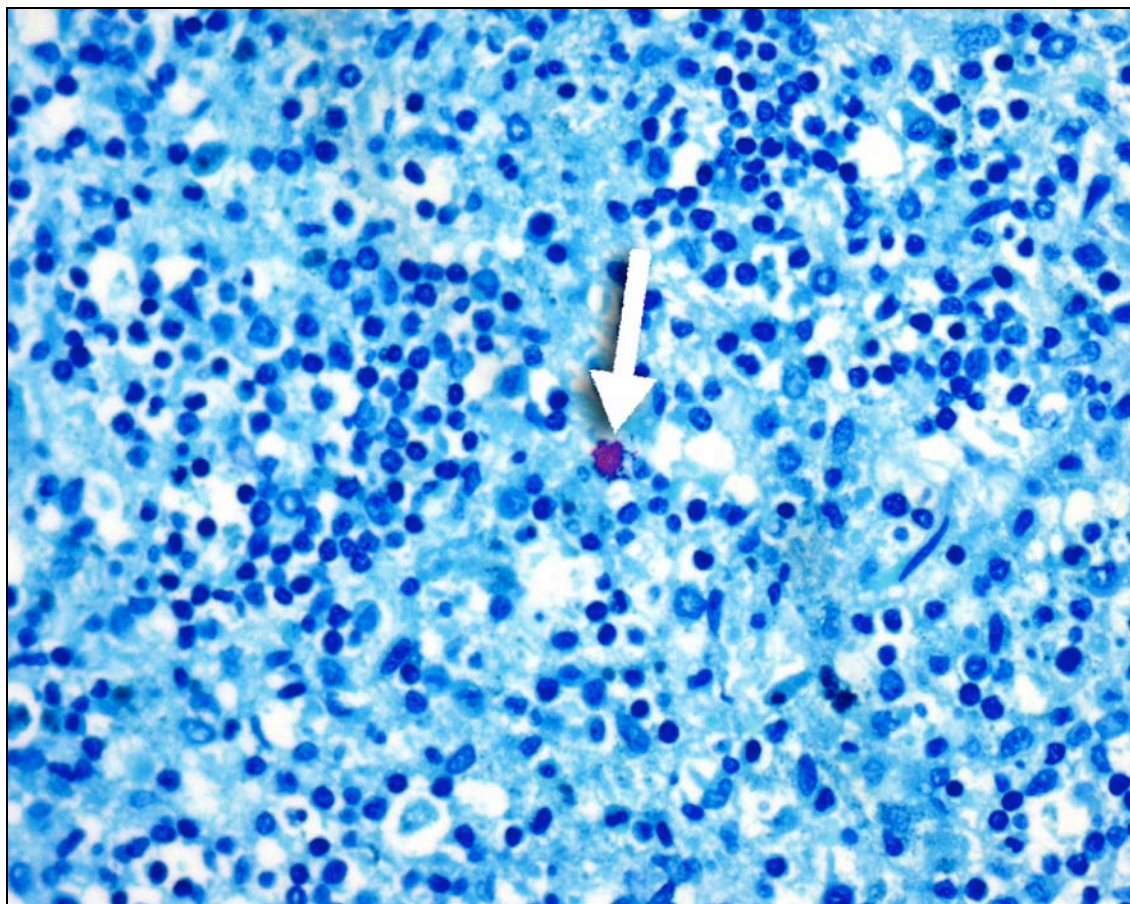


Fig. 3.29. Springbok B2, mesenteric lymph node. Cluster of acid-fast bacilli in a macrophage. MOTT were isolated from this animal (arrow). ZN. 400x

Lesions in the mesenteric lymph nodes of B1 and B5, and the ileocaecal lymph node of B1 reflected nematode larval migration. B1 showed two granulomas in the ileocaecal lymph node, one each in the cortex and capsule, and one cortical granuloma in the mesenteric lymph node. The cortical ileocacecal granuloma displayed remnants of a nematode larva that was surrounded by numerous multinucleated giant cells, and small numbers of macrophages and epithelioid cells (Fig. 3.30). The capsular granuloma displayed a similar reaction, but without nematode larval remnants visible. The granuloma in the mesenteric lymph node of B1 showed mild central coagulative necrosis, surrounded by small numbers of macrophages and epithelioid cells. B5 showed a focal granuloma in the cortex of a mesenteric lymph node that resembled the cortical ileocaecal granuloma of B1.

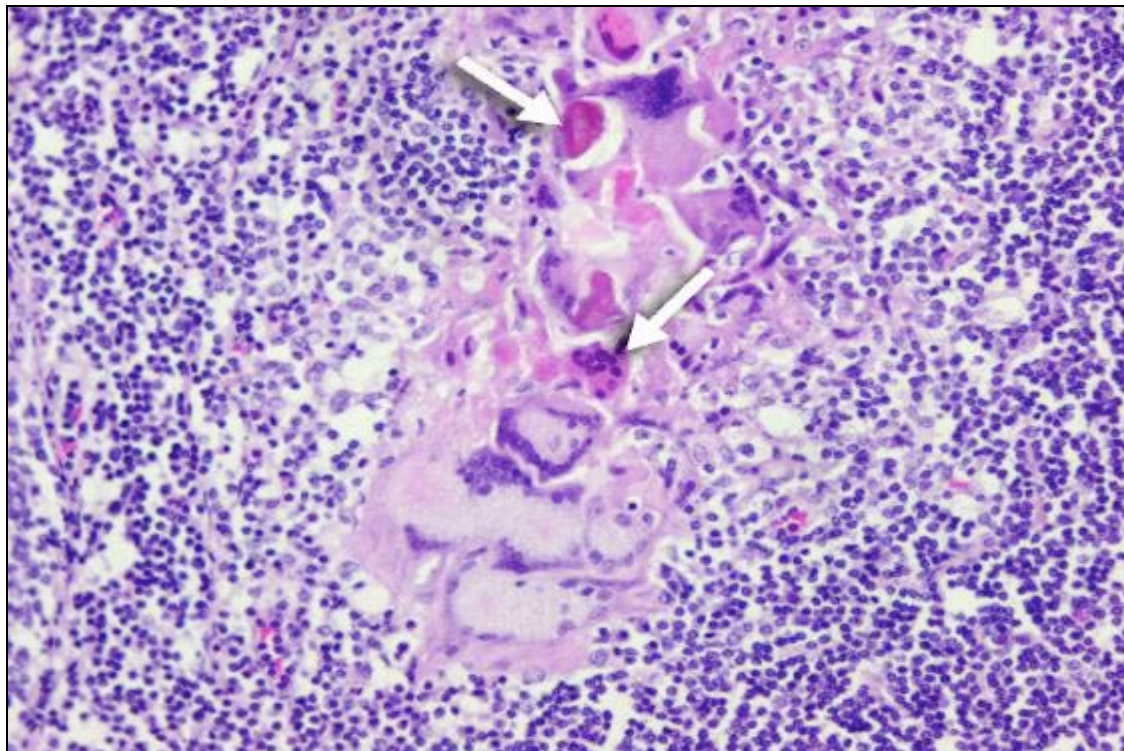


Fig. 3.30. Springbok B1, ileocaecal lymph node. Parasitic granuloma with nematode larval remnants (arrows) surrounded by Langhans' giant cells. H&E. 200x

Diaphragm (Fig. 3.31):

The parietal pleura covering the diaphragm of B4 displayed lesions similar to the lung pleura, but with the presence of mild central calcification of necrogranulomas. Ziehl-Neelsen staining was positive for scanty medium-sized, slender, acid-fast bacilli in the cytoplasm of a few epithelioid cells in necrogranulomas.

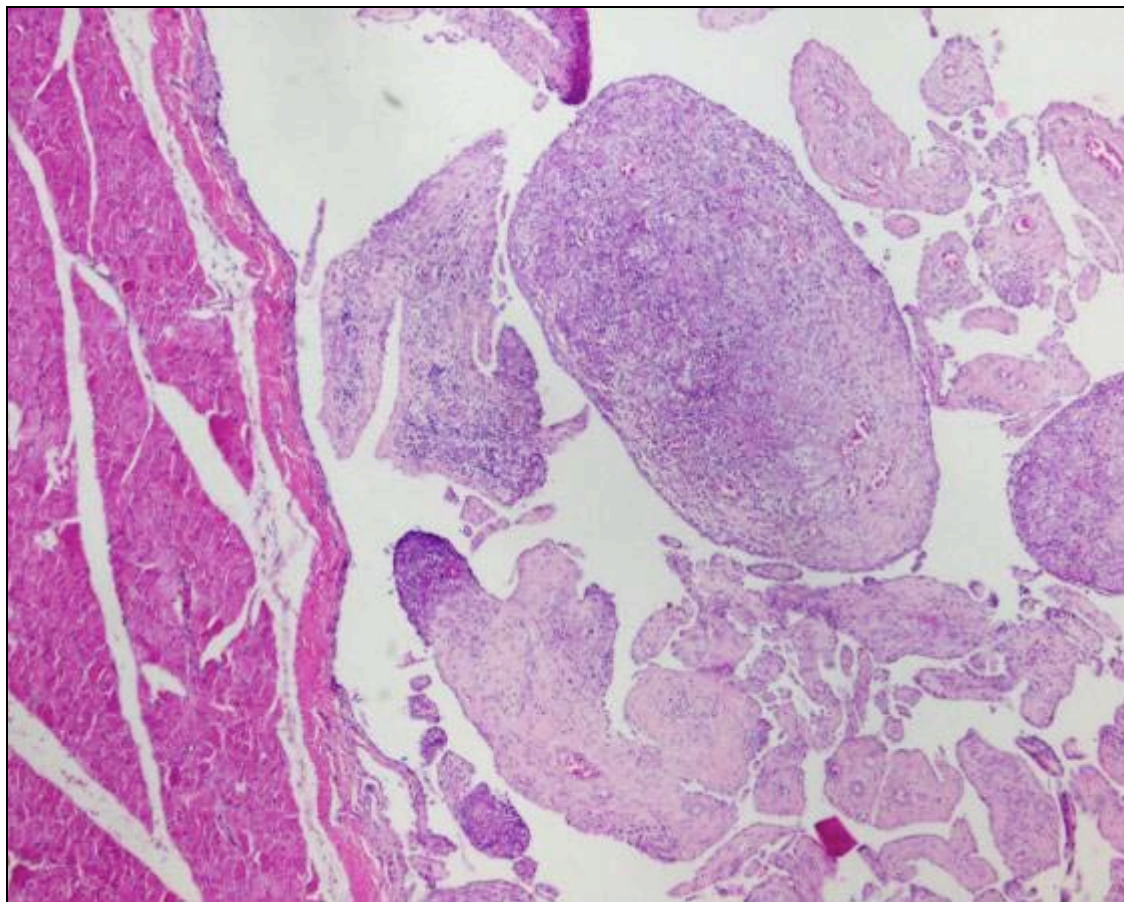


Fig. 3.31. Springbok B4, pleura attached to diaphragm. Granulomatous inflammation with prominent nodular fibroplasia. H&E. 40x

Testes (Fig. 3.32):

The testes of B4 showed infiltration of moderate numbers of lymphocytes and plasma cells, and scanty to small numbers of macrophages in the interstitium.

There were scanty microgranulomas, consisting of macrophage nests surrounded by small numbers of lymphocytes and plasma cells.

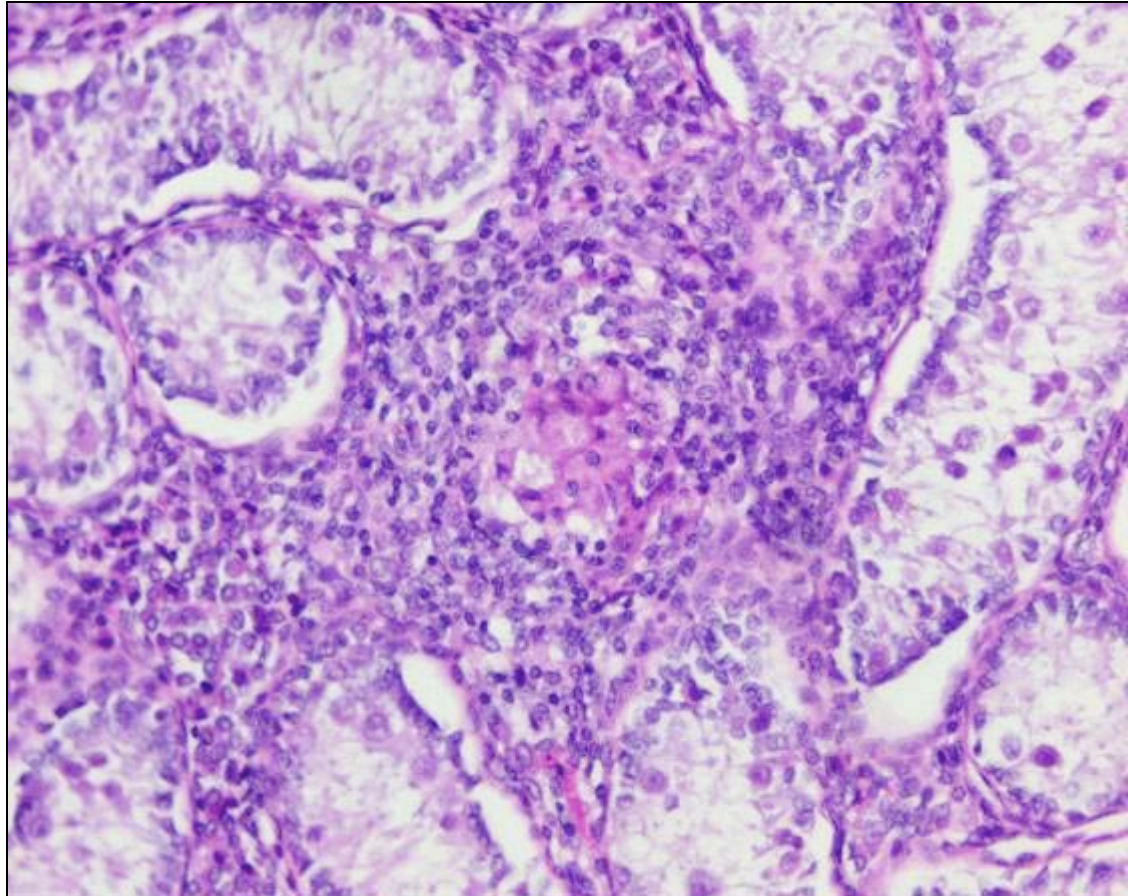


Fig. 3.32. Springbok B4, testis. Granuloma consisting of macrophages surrounded by lymphocytes and plasma cells. H&E. 200x

Gastro-intestinal tract:

The colon of B4 displayed four granulomas, one in the submucosa, two in the muscle layer, and one in the serosa. The submucosal granuloma showed a central nematode larva within necrotic tissue that was infiltrated by scanty eosinophils, and surrounded by numerous multinucleated giant cells and smaller numbers of macrophages, epithelioid cells, lymphocytes and plasma cells. The other three granulomas were similar in appearance, but without the

central nematode larva, necrosis and eosinophils, and only scanty multinucleated giant cells. There was a focal granuloma in the submucosa of B5 that consisted of a few central multinucleated giant cells surrounded by moderate numbers of macrophages, epithelioid cells, lymphocytes, plasma cells and eosinophils.

The colon of all six animals showed scanty to small numbers of coccidia, in various stages of their life-cycle, in the epithelium of the mucosa of the colon, without an inflammatory reaction. There was a single nematode larva visible in a mucosal gastric gland of the abomasum in B4, without a noticeable inflammatory reaction.

3.1.2.2 BACTERIOLOGY

Mycobacterium tuberculosis was isolated from all organ pools of B4, and the organ lymph node pool of B6. Mycobacteria other than tuberculous mycobacteria (MOTT) were isolated from the lungs, organ lymph nodes and carcass lymph nodes of B2, and organ lymph nodes and organs other than the lungs of B3.

3.1.2.3 INFg ASSAY

B5 tested strongly positive for INFg with the INFg assay, while the other animals all tested negative.

3.1.3 PART THREE: MAIN STUDY

Fifteen adult ewes (C1, C2, C3, C4, C5, C6, C7, C8, C10, C11, C12, C13, C14, C19 and C22) and 10 adult rams (C9, C15, C16, C17, C18, C20, C21, C23, C24 and C25) were sampled.

3.1.3.1 MACROSCOPIC AND MICROSCOPIC PATHOLOGY

3.1.3.1.1 MACROSCOPIC PATHOLOGY

All the animals were in good condition and only C1 showed clinical signs consisting of right hind-leg lameness before euthanasia. Ewes C3, C11, C12, C13 and C22 were in the early stages of pregnancy, while ewes C2 and C6 were in an advanced stage of pregnancy. C4, C7 and C8 did not show any noteworthy macroscopic lesions. Significant lesions were found in the following organs of the other animals:

Kidney (Fig. 3.33):

The right kidney of C1 showed a lesion highly suggestive for tuberculosis. In the cortex there was a focal, round, fairly distinctly demarcated, 8mm diameter, dull white, nodular, granulomatous lesion that bulged slightly from the surface. The nodule showed central caseation and was encapsulated by a fairly well-developed fibrous capsule. Part of this nodule was pooled with specimens from the uterus of C1 (see below) and submitted for mycobacterial culture.

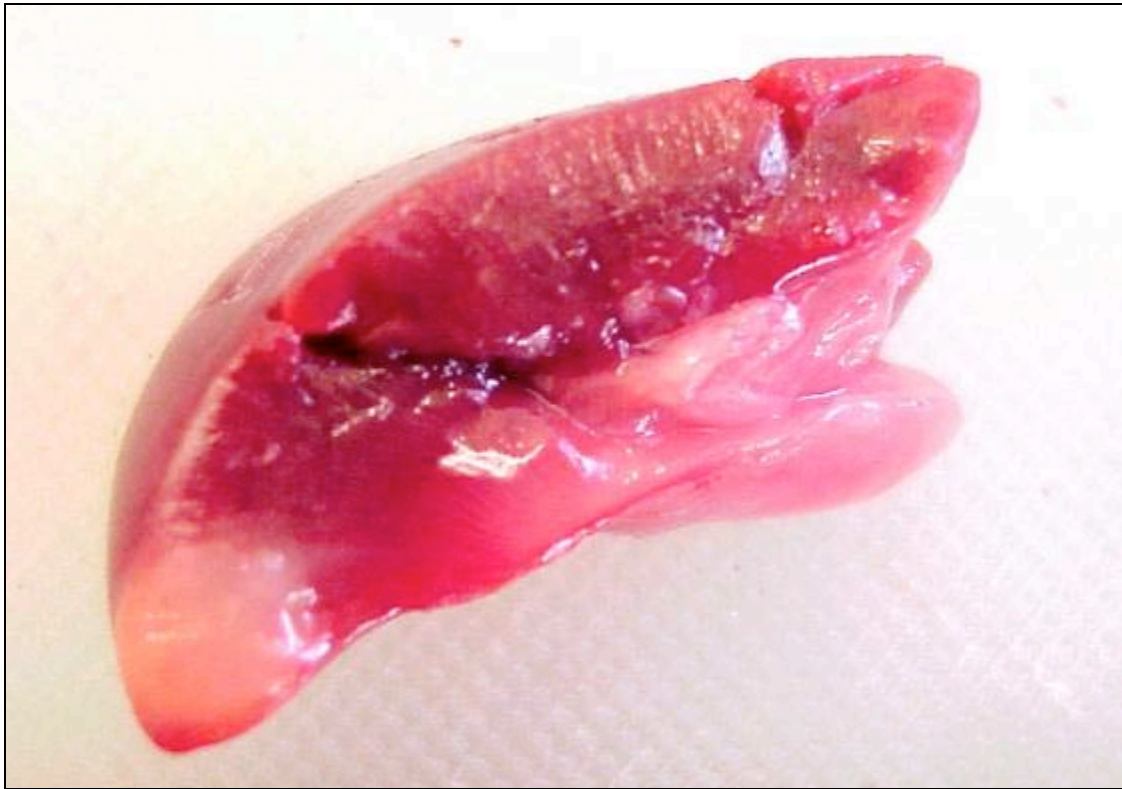

Fig. 3.33. Springbok C1, kidney. Focal granuloma in the cortex.

Liver:

There were scanty to small numbers of round, distinctly outlined, pinpoint to 3mm diameter, pale white foci randomly distributed throughout the parenchyma in the livers of C3, C9, C10, C11, C12, C13, C14, C15, C16, C17, C18, C19, C20, C21, C22, C23, C24 and C25.

Lymph node:

Both prescapular lymph nodes and the right mandibular lymph node of C1 were enlarged and showed significant proliferative changes consisting of multifocal to confluent, indistinctly outlined, oval to round nodules measuring 4mm (right prescapular lymph node) and 15mm (left prescapular and right

mandibular lymph nodes) in diameter throughout the node. These nodules were moderately firmer in consistency than the rest of the lymph node.

The right parotid and right retropharyngeal lymph nodes of C9 were enlarged and both showed marked focal, proliferative, indistinctly outlined, oval nodules measuring 23 x 10mm (right parotid lymph node) and 15 x 10mm (right retropharyngeal lymph node) in the cortex. These nodules were firmer in consistency than the rest of the lymph node. The right parotid lymph node showed poor distinction between the medulla and cortex.

The proliferative lymph node changes probably reflected marked reactive follicular hyperplasia, but early tuberculous granulomatous inflammation could not be ruled out macroscopically.

Skeletal muscle:

The gastrocnemius muscles of C20 showed bilaterally symmetrical, focal, 5 x 20mm accumulations of a gritty, granular, pale white material, resembling calcified tissue, underneath the outer muscle sheath.

Uterus (Fig. 3.34):

The endometrium of C1 showed multifocal petechiae. There were well-developed caruncles that showed multifocal petechiae and ecchymoses, and multifocal dull yellow-white areas of necrosis measuring from pinpoint to 3mm in diameter. The caruncles were covered with a moderate amount of purulent exudate. There were multifocal petechiae and ecchymoses

measuring 3 to 5mm in diameter in the cervical mucosa. Several specimens of affected tissue from the uterus and cervix were pooled with a specimen from the kidney (see above) of C1 and submitted for mycobacterial culture. The uterus of C5 was congested and displayed similar haemorrhagic lesions to those seen in C1. However, no areas of necrosis or purulent inflammation were visible.

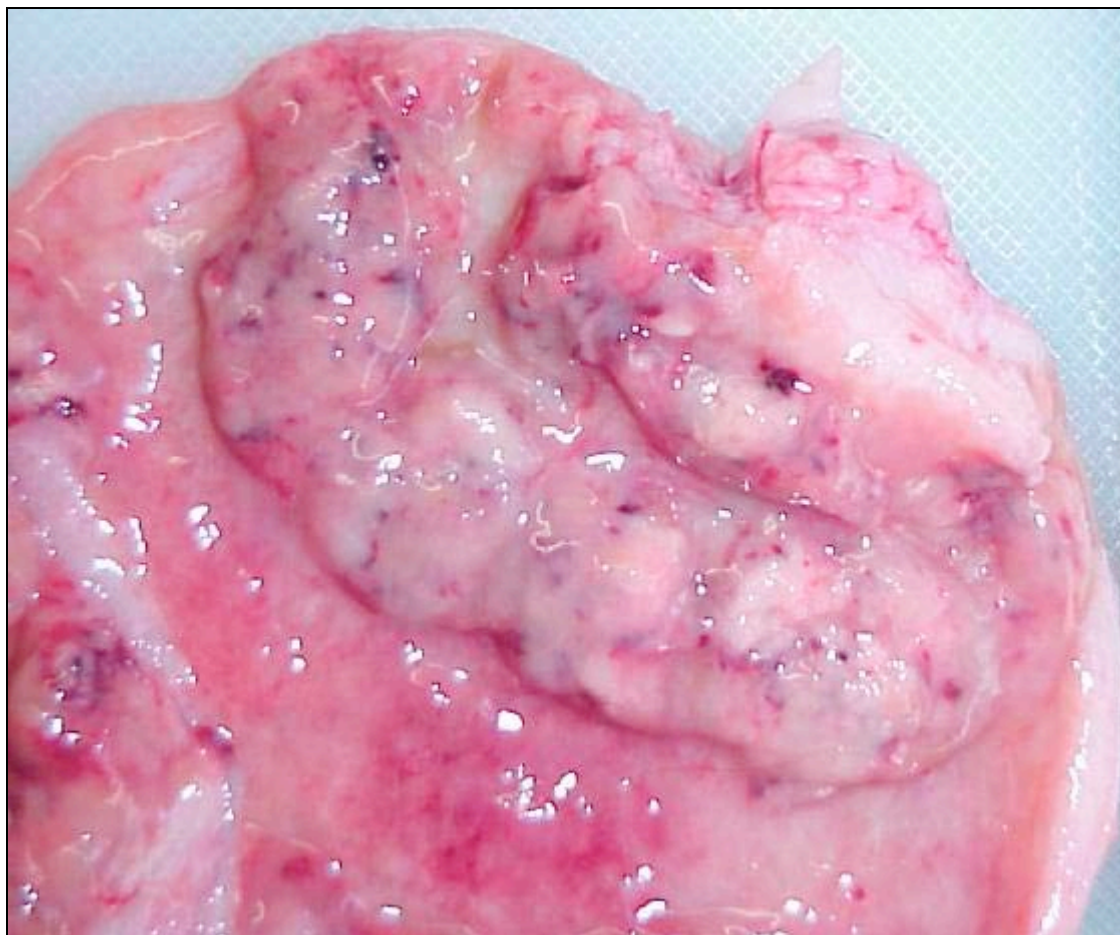


Fig. 3.34. Springbok C1, uterus. Petechiae and ecchymoses of a caruncle with necrosis and moderate accumulation of pus.

Lung:

The following animals had moderate numbers of adult *Bronchonema magna* nematodes visible in the lumen of the trachea and both bronchi, notably at the tracheal bifurcation: C2, C5, C10, C24 and C25.

Abdominal cavity:

Several mature unidentified cestode larvae that morphologically resembled *Taenia hydatigena* cysticerci were visible in the abdominal cavity of C3 and C1. They were attached to the liver (C3) and abomasum (C1), or were lying loose (C1). Three cestode larvae of C1 that were attached to the abomasum, and one that was lying loose, were firm, round to irregularly-shaped nodules consisting of a calcified and inspissated centre, surrounded by a fairly well-developed fibrous capsule. The three nodules attached to the abomasum measured 15mm in diameter while the loose nodule measured 30mm in diameter.

Eyelid:

The right ventral eyelid of C9 showed a focal purulent sinus tract that extended from the surface for 20mm into the eyelid and was 5mm wide. There was extensive purulent inflammation of the eyelid and surrounding subcutaneous tissues. This lesion may have been a traumatic injury and probably resulted in the hyperplastic lesions observed in the right parotid and right retropharyngeal lymph nodes (see above) of this animal.

3.1.3.1.2 MICROSCOPIC PATHOLOGY

The microscopical lesions of the organs mentioned above, except for the eyelid, as well as significant lesions detected in other organs are described below. Multinucleated giant cells were always of both the Langhans' and foreign-body type. All lesions in all organs were negative for acid-fast bacilli with ZN staining.

Kidney (Fig. 3.35):

The focal lesion in the right kidney of C1 consisted of a central area of caseous necrosis that contained necrotic cellular debris, mostly necrotic neutrophils, and showed early calcification.

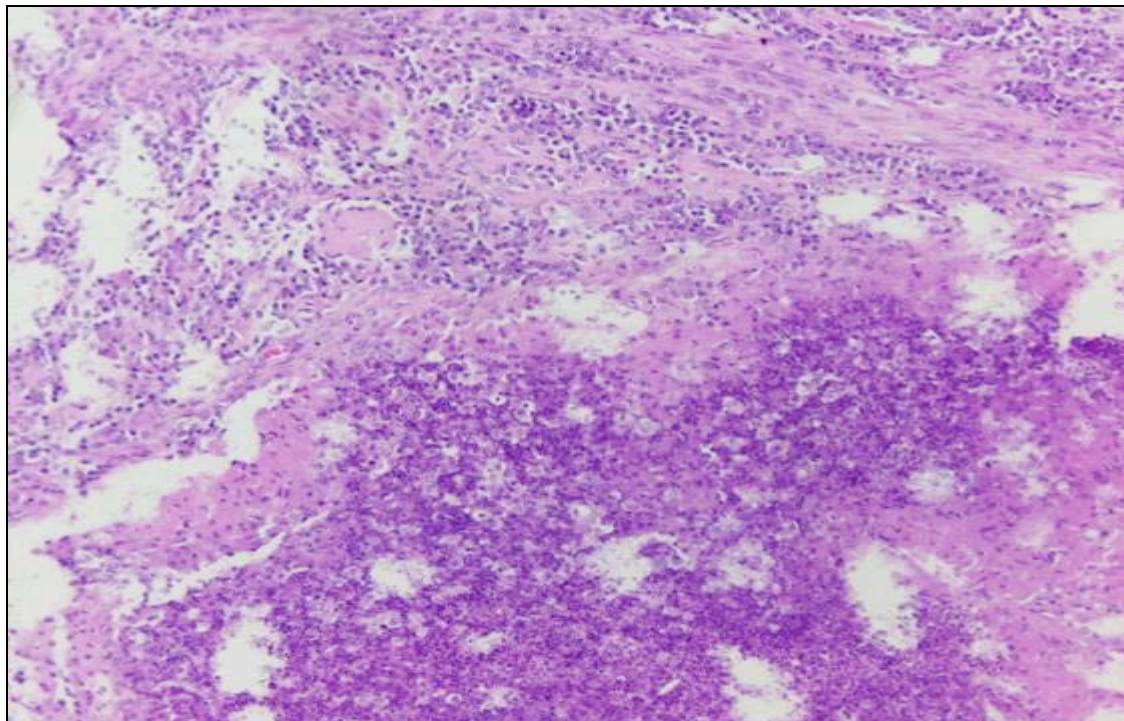


Fig. 3.35. Springbok C1, kidney. Necrogranuloma with central caseous necrosis and early calcification. H&E. 100x

This was surrounded by moderate numbers of macrophages and epithelioid cells, and numerous lymphocytes and plasma cells. There was a fairly well-developed outer layer consisting of fibrous connective tissue.

Liver:

The macroscopic multifocal pale white foci in the liver consisted of nodular aggregations of a mixture of moderate to large numbers of lymphocytes, plasma cells and eosinophils in portal tracts, and occasionally in the parenchyma. C25 had a small focal granuloma in a portal tract consisting of a central area of coagulative necrosis surrounded by small numbers of macrophages and epithelioid cells. In one animal (C1) there was a small focal empty cyst in the parenchyma that was surrounded by a thin layer of degenerative and necrotic hepatocytes, with haemorrhage and infiltration of moderate numbers of neutrophils and eosinophils. The cyst was probably parasitic in nature and had a thin outer wall, with an inner adherent single row of spindle-shaped cells projecting into the cyst cavity. All animals, except C9 and C20, showed infiltration of scanty to moderate numbers of lymphocytes, plasma cells and eosinophils in the portal tracts, without the formation of distinct nodules. The lesions present in the liver were probably in response to previous parasitic larval migration.

The liver of C4 displayed multifocal areas, consisting of one to multiple open fusiform slits or clefts throughout the parenchyma, and also involving portal tracts. The cleft aggregates were surrounded by low to moderate numbers of macrophages, epithelioid cells and fibroblasts, with occasional multinucleated

giant cells and small numbers of lymphocytes, plasma cells and eosinophils. The cause of the clefts could not be established but they are unlikely to have been related to tuberculosis.

Lymph nodes (Figs. 3.36 and 3.37):

The prescapular lymph nodes and right mandibular lymph node of C1, and the right parotid and right retropharyngeal lymph nodes of C9 displayed typical reactive hyperplastic changes, without evidence of possible tuberculosis. These changes were marked and consisted of numerous cortical secondary reactive follicles with prominent germinal centres, necrosis of individual lymphocytes in follicles with increased tingible body macrophage activity, a prominent hyperplastic paracortical zone and sinus histiocytosis.

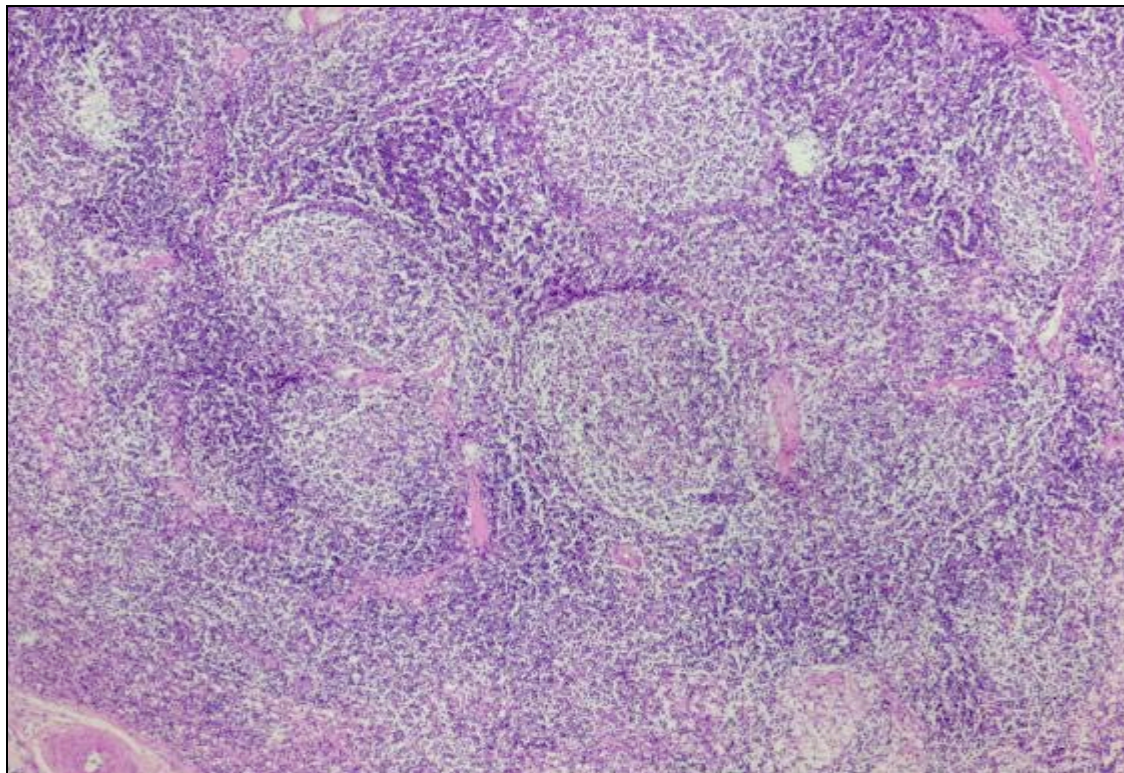


Fig. 3.36. Springbok C1, left prescapular lymph node. Reactive hyperplasia with numerous secondary follicles in the cortex. H&E. 40x

The following lymph nodes showed focal to multifocal microscopic granulomatous lymphadenitis: mesenteric (C1, C2, C9, C10, C11, C12, C13, C14, C16, C17, C18, C20, C21, C22, C23, C24 and C25), ileocaecal (C1, C8, C12, C16, C19, C24 and C25), bronchial (C1 and C7) and inguinal (C20). The lesions were characterized by variable numbers (usually single) of centrally-located nematode larvae, or their necrotic remnants, in the following animals: mesenteric lymph nodes of C1, C2, C9, C11, C12, C17 and C25; ileocaecal lymph nodes of C1, C8, C12, C19 and C24; bronchial lymph nodes of C1 and C7; and the inguinal lymph nodes of C20. The nematode larvae were occasionally surrounded by low to moderate numbers of eosinophils that often displayed degenerative and necrotic changes. Granulomas without central nematode larvae occasionally showed central caseous necrosis. All animals showed infiltration of variable numbers of a mixture of macrophages, epithelioid cells, multinucleated giant cells, lymphocytes, plasma cells and eosinophils around the central parasite or necrotic area.

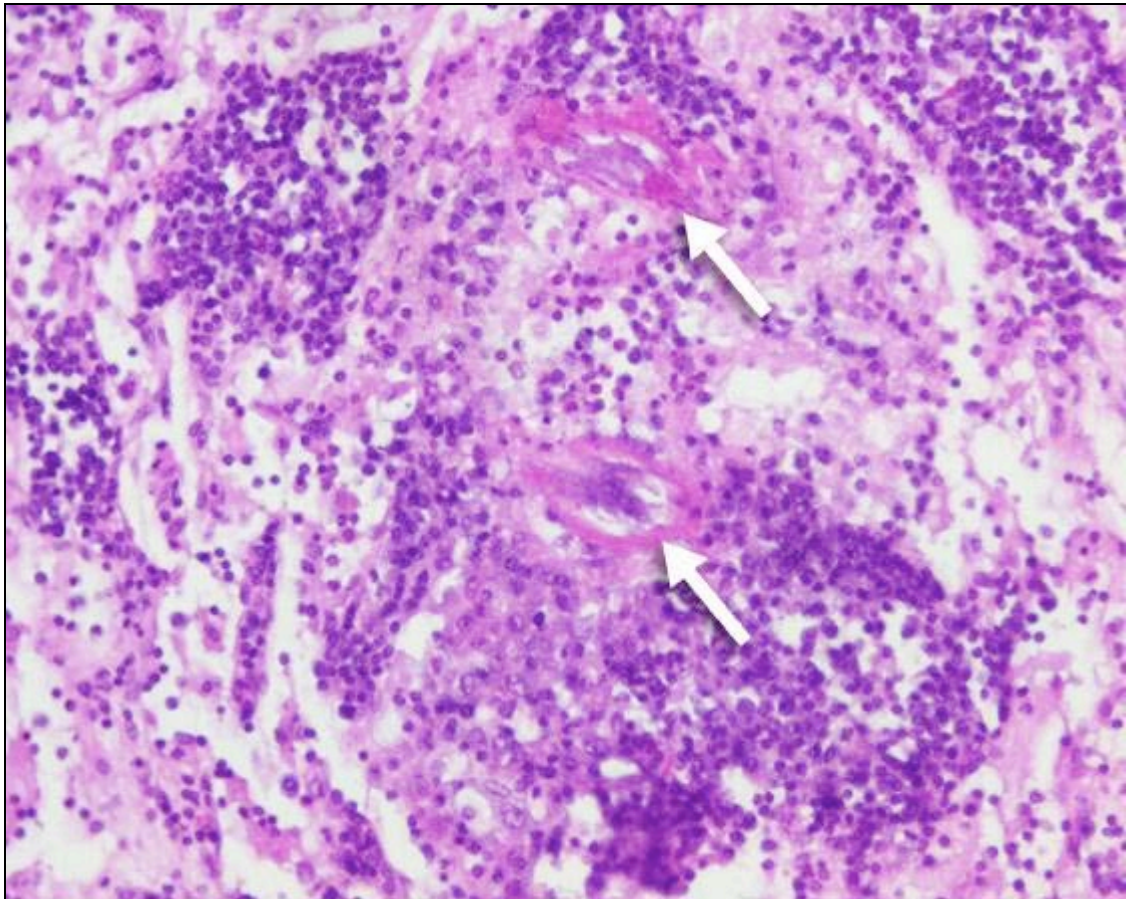


Fig. 3.37. Springbok C1, mesenteric lymph node. Nematode larvae (arrows) surrounded by macrophages and eosinophils. H&E. 200x

The bronchial and mediastinal lymph nodes of C22 showed accumulations of moderate to large numbers of macrophages, containing cytoplasmic foreign particulate matter, in the cortex and medulla. The macrophages were often arranged in nests.

Tonsils:

One of the tonsils of C2 displayed a focal granuloma that consisted of a central area of caseous necrosis surrounded by moderate numbers of macrophages. Moderate numbers of small plant fibres were present in the crypts and it is likely that the granuloma was a foreign-body reaction.

Skeletal muscle (Fig. 3.38):

C20 displayed multifocal, well-defined and variably-sized lakes of calcification in muscle and the surrounding connective tissue that were rimmed and separated from each other by moderately-developed fibrous connective tissue. The connective tissue was infiltrated by moderate to large numbers of lymphocytes and plasma cells, and small to moderate numbers of macrophages. The lesion resembled *calcinosis circumscripta*.

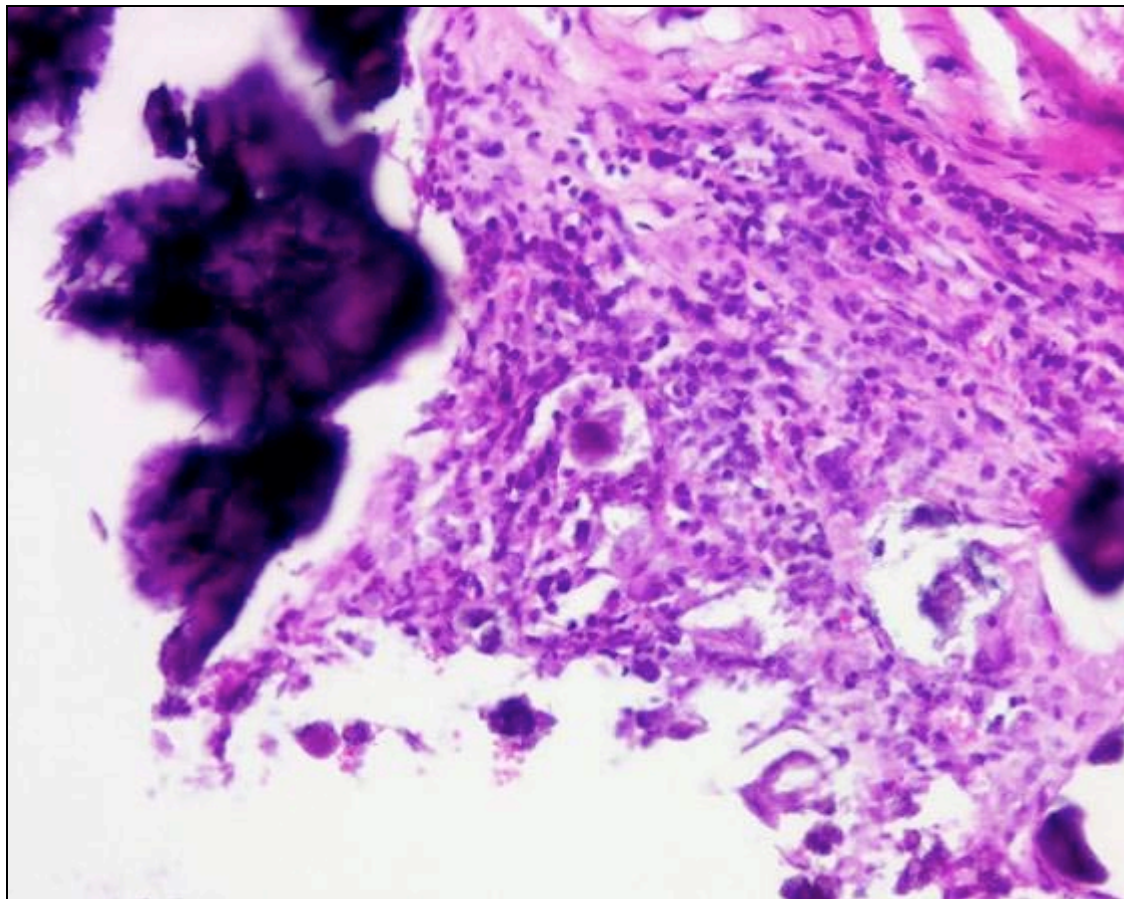


Fig. 3.38. Springbok C1, gastrocnemius muscle. Calcinosis circumscripta. H&E. 200x

Uterus (Fig. 3.39):

The lesions in the uterus of C1 were marked and consisted of multifocal haemorrhages and coagulative necrosis of the endometrium. The necro-

haemorrhagic exudate contained large numbers of bacterial rods morphologically resembling *Clostridium* spp. The remainder of the endometrium showed infiltration of large numbers of neutrophils, and there was moderate early granulation tissue formation consisting of angiogenesis, macrophage infiltration and fibroplasia. A few endometrial blood vessels contained fibrin thrombi. The lesions probably represented post-partum involution with bacterial endometritis.

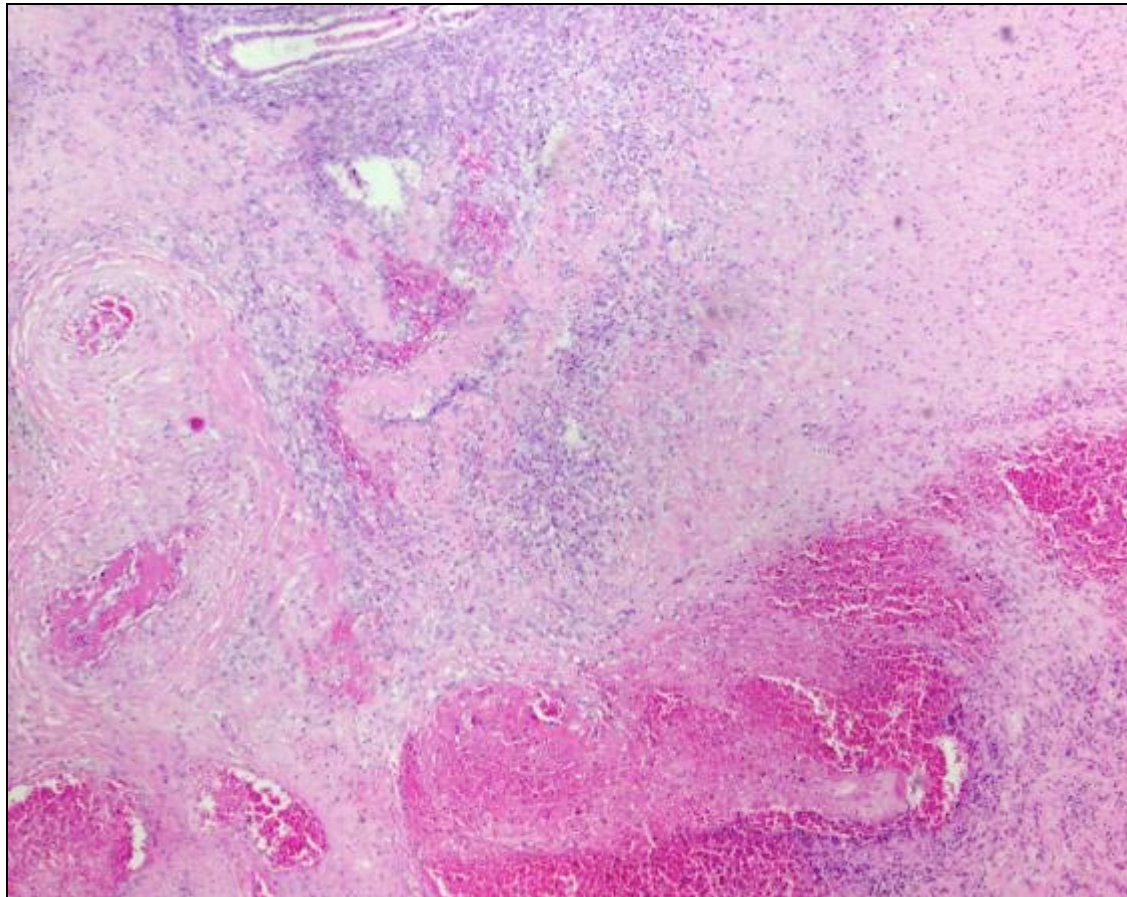


Fig. 3.39. Springbok C1, uterus. Necro-haemorrhagic endometritis. H&E. 40x

The uterus of C5 showed marked vascular congestion. The endometrium was infiltrated by numerous macrophages that contained abundant cytoplasmic haemosiderin pigment. There were a few multinucleated giant cells and early

granulation tissue formation similar to C1. Small numbers of lymphocytes and plasma cells were also present. The lesions probably reflected post-partum involution.

Lung (Figs. 3.40, 3.41 and 3.42):

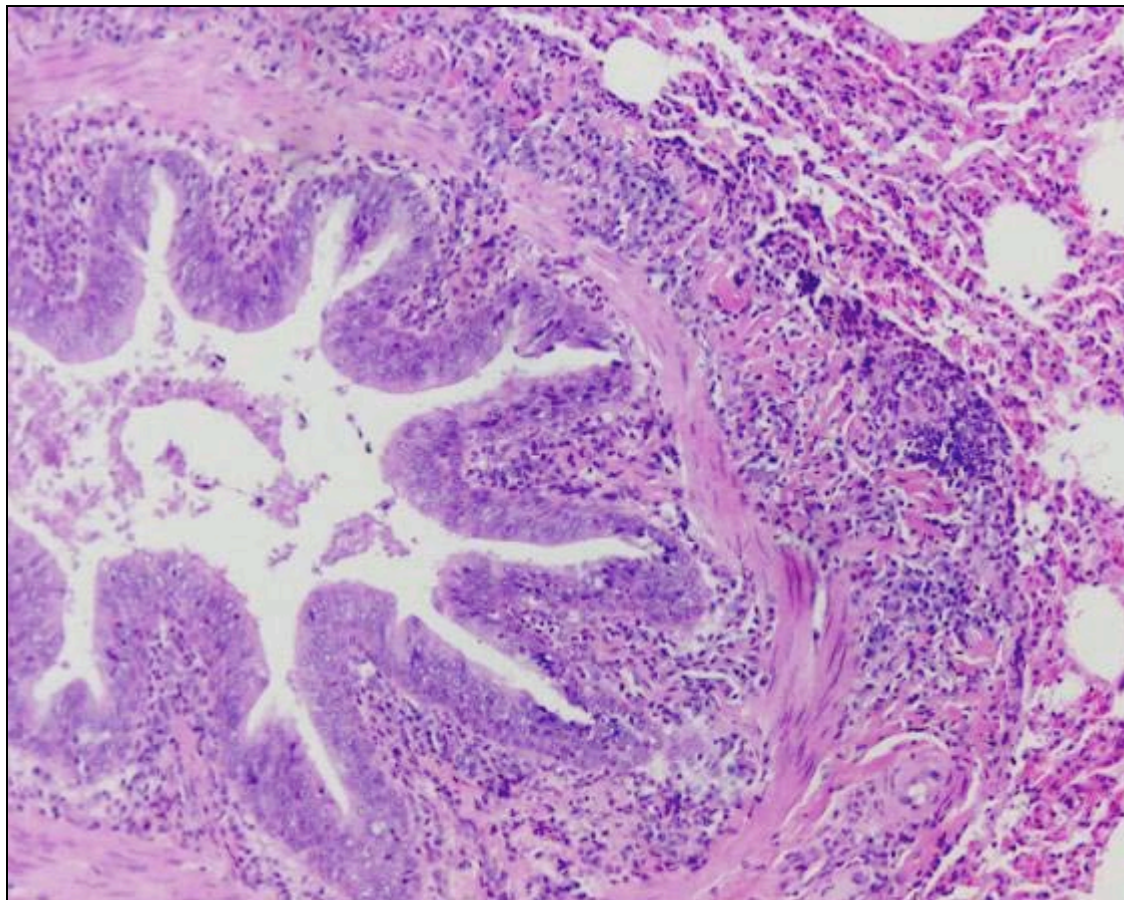


Fig. 3.40. Springbok C1, lung. Bronchiolar lesions as a result of *B. magna* consisted of hypertrophy and hyperplasia of the epithelium and smooth muscle, as well as infiltration of lymphocytes, plasma cells and eosinophils in the lamina propria of the epithelial layer. H&E. 100x

The following animals showed moderate, multifocal, parasitic, eosinophilic and granulomatous bronchopneumonia with moderate numbers of adult

Bronchonema magna nematodes visible in bronchioles, as well as moderate numbers of larvae present in alveoli: C1, C2, C6 and C8. The lesions consisted of moderate to marked hyperplasia and hypertrophy of bronchiolar epithelium and smooth muscle. There was occasional mild bronchiolar epithelial squamous metaplasia in bronchioles plugged with adult parasites. A few bronchioles were ruptured, resulting in free-lying adult nematodes in the parenchyma that were surrounded by moderate to large numbers of macrophages and multinucleated giant cells, and moderate numbers of lymphocytes, plasma cells and eosinophils. There was widespread infiltration of small to moderate numbers of lymphocytes, plasma cells and eosinophils in the lamina propria of the bronchiolar epithelium, and often perivascularly. Moderate numbers to numerous globular leukocytes, with moderate to abundant, variably-sized, round, eosinophilic, cytoplasmic globules occurred in the intercellular areas of the bronchiolar epithelium. The reaction to the larvae in the alveoli consisted of infiltration of moderate to large numbers of eosinophils, macrophages, multinucleated giant cells, lymphocytes and plasma cells, with mild to moderate epithelialization of pneumocytes and mild fibrosis. Similar lesions were present in C5, C7, C9, C16 and C17, with C22 and C25 showing very mild changes, but no nematode larvae could be found in the alveoli of any of these seven animals.

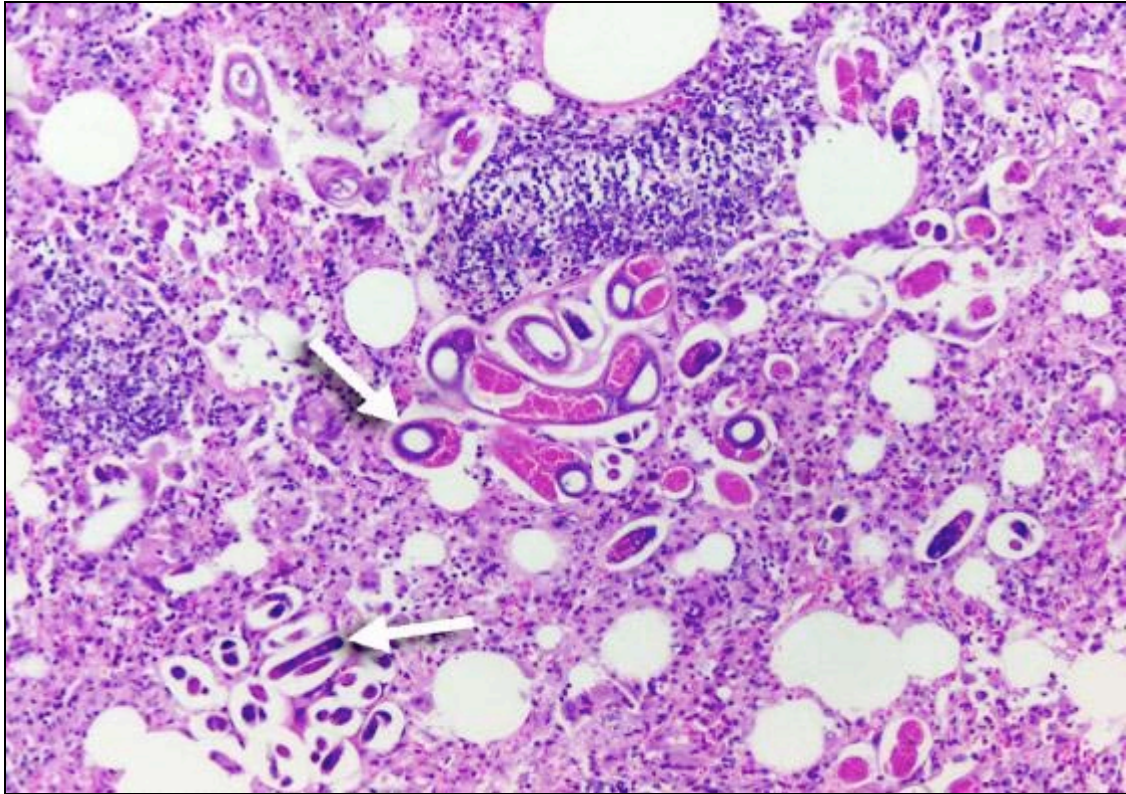


Fig. 3.41. Springbok C1, lung. Numerous *B. magna* larvae in alveolar spaces (arrows).

H&E. 100x

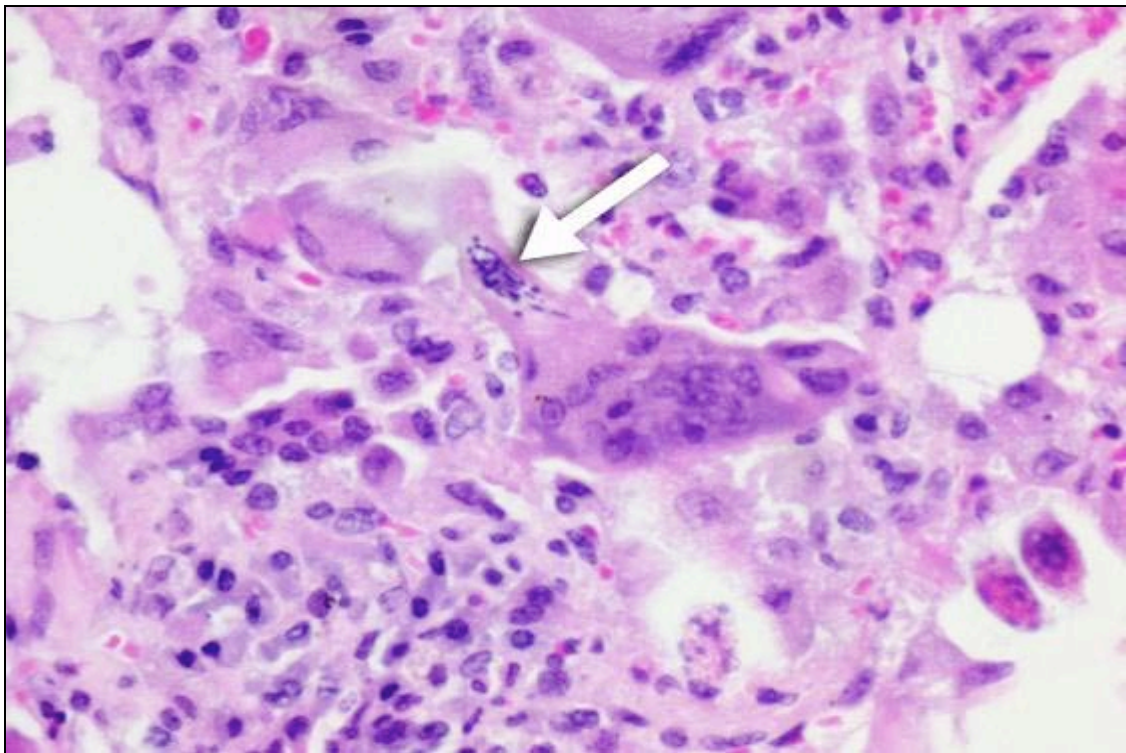


Fig. 3.42. Springbok C1, lung. Multinucleated giant cell engulfing a *B. magna* larva

(arrow). H&E. 400x

The following animals showed mild lesions suggestive for *Bronchonema magna* infestation, but no parasites were visible: C3, C4, C10, C11, C12, C13, C14, C15, C18, C19, C20, C21, C23 and C24. The lesions in these animals were generally confined to the bronchioles, and consisted of mild to moderate epithelial and smooth muscle hypertrophy and hyperplasia, with infiltration of small numbers of eosinophils, lymphocytes and plasma cells in the lamina propria of the bronchiolar epithelium, and occasionally perivascularly. Low to moderate numbers of globular leukocytes, with moderate to abundant, variably-sized, round, eosinophilic, cytoplasmic globules often occurred in the intercellular areas of the bronchiolar epithelium.

Abdominal cavity:

The parasitic nodules found in the abdominal cavity of C1 had a central cavity that was filled with caseous necrotic material that was markedly calcified. The calcified necrotic centre was surrounded by a thin layer of macrophages, multinucleated giant cells, lymphocytes and plasma cells. There was a well-developed fibrous connective tissue capsule.

Gastro-intestinal tract:

Apart from the nematodes causing lesions in the liver, lymph nodes and lungs several gastro-intestinal tract organs were also infested with parasites. The following animals had scanty to small numbers of nematode larvae present within gastric glands in the abomasum, usually with a negligible to mild lymphocyte, plasma cell and eosinophil inflammatory reaction: C1, C2, C5, C6, C7, C10 and C25. The ileum of C13 and the jejunum of C25 each had a

focal parasitic granuloma in the submucosa and muscle layer respectively. Both granulomas consisted of a central nematode larva surrounded by small to moderate numbers of macrophages, epithelioid cells, multinucleated giant cells (only C13), lymphocytes and plasma cells. A single nematode parasite was found in the lumen of the jejunum of C24. The following animals showed scanty to small numbers of coccidia, in various stages of their life-cycle, in the epithelium of the mucosa of the colon, with a minimal inflammatory reaction: C4, C7, C9, C15, C16, C17, C18, C20, C21 and C24.

3.1.3.2 BACTERIOLOGY

Mycobacterial culture was performed on the organ pools mentioned under 2.1.3.3, as well as on an additional pool for C1 that consisted of specimens from the kidney and uterus. All pools of all animals were negative for *Mycobacterium* spp. after 10 weeks incubation.

3.1.3.3 INFg ASSAY

The INFg assay was negative in all 25 animals.

3.1.4 SUMMARY OF RESULTS

Table 3.1 is a summary of the macroscopical, microscopical, mycobacterial culture and INFg results of all 33 springbok. *Mycobacterium tuberculosis* was confirmed *via* culture in only three springbok (A1, B4 and B6), indicating a

prevalence of 9 %. Two (A1 and B4) of the three culture-positive animals displayed tuberculosis lesions, while B6 did not show any significant macroscopic or microscopic pathology.

Mycobacteria other than tuberculous mycobacteria (MOTT) were isolated from two animals (B2 and B3). B2 was positive for one nest of acid-fast bacilli in one macrophage of a mesenteric lymph node, but no lesions were present.

Only one animal (B5) tested positive with the INF γ assay, but did not show tuberculosis lesions and was negative for *Mycobacterium* spp. *via* culture. The sensitivity and specificity of the INF γ assay, when compared to the mycobacterial culture results for diagnosing *M. tuberculosis* in springbok in this study, is 0% and 96% respectively. The predictive value of a positive test is therefore 0%, and the predictive value of a negative test is 90%.

Table 3.2 indicates the presence of macroscopic and microscopic lesions, presence of acid-fast bacilli, and organs that did not show lesions for all organs sampled in both animals with tuberculosis lesions.

Table 3.1 Summary of results

Springbok	Macroscopy (granulomatous lesions)	Microscopy (granulomatous lesions positive for acid-fast bacilli)	Mycobacterial culture	INFg
A1	+	+	+	ND
A2	S	-	-	ND
B1	-	-	-	-
B2	-	-	MOTT	-
B3	-	-	MOTT	-
B4	+	+	+	-
B5	-	-	-	+
B6	-	-	+	-
C1	S	-	-	-
C2	-	-	-	-
C3	-	-	-	-
C4	-	-	-	-
C5	-	-	-	-
C6	-	-	-	-
C7	-	-	-	-
C8	-	-	-	-
C9	S	-	-	-
C10	-	-	-	-
C11	-	-	-	-
C12	-	-	-	-
C13	-	-	-	-
C14	-	-	-	-
C15	-	-	-	-
C16	-	-	-	-
C17	-	-	-	-
C18	-	-	-	-
C19	-	-	-	-
C20	-	-	-	-
C21	-	-	-	-
C22	-	-	-	-
C23	-	-	-	-
C24	-	-	-	-
C25	-	-	-	-

+ = Positive

S = Suspect

- = Negative

MOTT = Mycobacteria other than tuberculous mycobacteria

ND = Not done

Table 3.2 Comparison of organs showing macroscopic and microscopic tuberculosis lesions, acid-fast bacilli and no lesions

Organ	Macroscopic lesions		Microscopic lesions		Acid-fast bacilli		No lesions	
	A1	B4	A1	B4	A1	B4	A1	B4
Lung	+	+	+	+	+	+	-	-
Pleura	+	+	+	+	ND	+	-	-
Bronchial In.	+	+	+	+	+	+	-	-
Mediastinal In.	+	+	+	+	+	+	-	-
Sternal In.	NS	+	NS	+	NS	+	NS	-
Iliac In.	NS	+	NS	+	NS	+	NS	-
R-prefemoral In.	NS	+	NS	+	NS	+	NS	-
L-prefemoral In.	NS	-	NS	+	NS	+	NS	-
R-retropharyngeal In.	NS	+	NS	+	NS	+	NS	-
L-retropharyngeal In.	NS	-	NS	+	NS	-	NS	-
R-mandibular In.	NS	-	NS	+	NS	-	NS	-
L-mandibular In.	NS	-	NS	+	NS	-	NS	-
L-prescapular In.	NS	-	NS	+	NS	-	NS	-
Mesenteric In.	NS	-	NS	+	NS	-	NS	-
Ileocaecal In.	NS	-	NS	+	NS	-	NS	-
Inguinal In.	NS	-	NS	+	NS	-	NS	-
Spleen	-	-	+	-	+	-	-	+
Liver	+	-	+	-	+	-	-	+
Kidney	-	-	+	-	+	-	-	+
Adrenal gland	-	-	+	-	+	-	-	+
Testicle	NS	-	NS	+	NS	-	NS	-
Abomasum	-	-	+	-	+	-	-	+
Small intestine	-	-	+	-	+	-	-	+
Colon	-	-	+	+	+	-	-	-
Rectum	-	NS	+	NS	+	NS	-	NS
Oesophagus	-	-	-	-	-	-	+	+
Heart	-	-	-	-	-	-	+	+
Brain	NS	-	NS	-	NS	-	NS	+
Eyes	NS	-	NS	-	NS	-	NS	+
Thymus	NS	-	NS	-	NS	-	NS	+
Tongue	NS	-	NS	-	NS	-	NS	+
Tonsils	NS	-	NS	-	NS	-	NS	+
R-parotid In.	NS	-	NS	-	NS	-	NS	+
L-parotid In.	NS	-	NS	-	NS	-	NS	+
Hepatic In.	NS	-	NS	-	NS	-	NS	+
Splenic In.	NS	-	NS	-	NS	-	NS	+
R-prescapular	NS	-	NS	-	NS	-	NS	+
R-popliteal	NS	-	NS	-	NS	-	NS	+
L-popliteal	NS	-	NS	-	NS	-	NS	+

+ = present

- = absent

NS = Not sampled

ND = No microscopy done

B4 had prominent macroscopic tuberculosis lesions in the lungs, pleura and the following lymph nodes: bronchial, mediastinal, sternal and iliac. The right prefemoral and right retropharyngeal lymph nodes showed mild macroscopic lesions. Microscopic tuberculosis lesions with acid-fast bacilli were present in the above organs, as well as in the left prefemoral lymph node. The following organs of B4 did not show macroscopic lesions, but only microscopic lesions that were typical or highly suggestive for tuberculosis, although no acid-fast bacilli were visible: testis, colon and the following lymph nodes: left retropharyngeal, mesenteric, ileocaecal, inguinal, left mandibular, right mandibular and left prescapular.

The other affected springbok (A1) showed marked macroscopic tuberculosis lesions in the lungs, pleura, liver and bronchial- and mediastinal lymph nodes. Because this animal was presented for a routine diagnostic necropsy, only a limited set of organs were sampled for microscopy. The only lymph nodes sampled for microscopy in this animal were the bronchial and mediastinal lymph nodes. Microscopic tuberculosis lesions with acid-fast bacilli were present in all the organs of A1 that showed macroscopic lesions, as well as the following organs: kidney, adrenal gland, abomasum, small intestine, colon and rectum. The heart and oesophagus were also sampled, but did not show any macroscopic or microscopic tuberculosis lesions.

Macroscopic lesions ranged from encapsulated (lungs of both, pulmonary lymph nodes of A1 and iliac lymph node of B4) to non-encapsulated (pleura of both and mediastinal lymph node of B4). Macroscopic granulomas with and

without obvious caseous necrosis were prominent in the lungs of both, while the iliac lymph node of B4 showed only necrotic foci. The lesions in the pleura of both animals were nodular, plaque-like and proliferative to almost sarcomatous. The liver of A1 showed marked focally disseminate necrosis, which proved to be small necrogranulomas microscopically. The degree of calcification varied from absent (liver of A1) to moderate (lungs and bronchial lymph nodes of both). The size of lesions varied from single pinpoint lesions (right retropharyngeal of B4), to miliary (lungs of both), to multifocal (sternal lymph node of B4 and lungs of both).

The microscopical lesions varied in terms of severity, relative numbers of inflammatory cells, degree and type of necrosis, and abundance of acid-fast bacilli with ZN staining. Lesions were marked in organs such as the lungs, pleura and bronchial lymph nodes of both, and liver, spleen and kidney of A1. Mild lesions consisting of individual macrophages or only a few nests of macrophages were present in the adrenal gland, abomasum, small intestine, colon and rectum of A1, and the testes, left and right mandibular lymph nodes, and left prescapular lymph node of B4. Marked granulomatous inflammation, with large numbers macrophages, epithelioid cells and multinucleated giant cells, were present in the lungs and bronchial lymph nodes of both animals, the mediastinal lymph node of A1, and the sternal, iliac, right prefemoral, left prefemoral and right retropharyngeal lymph nodes of B4. The pleura of B4 displayed prominent fibroplasia. Giant cells were of both the Langhans' and foreign-body type, but Langhans' giant cells predominated in the bronchial and mediastinal lymph nodes of B4. Some

granulomas showed central caseous necrosis (lungs and bronchial lymph nodes of both), while necrosis was absent in others, often in the same organ (lungs and bronchial lymph nodes of both, left retropharyngeal and mesenteric lymph nodes of B4). The liver, spleen and kidney of A1 showed prominent multifocal coagulative necrosis of granulomas that were composed of moderate numbers of macrophages, and small numbers epithelioid cells and multinucleated giant cells. The mesenteric and ileocaecal lymph nodes of B4 did not show macroscopic lesions, but prominent microscopic granulomas consisting of large numbers of multinucleated giant cells. The giant cells were mostly the Langhans' type in the case of the mesenteric lymph node. One multinucleated giant cell in the ileocaecal lymph node showed characteristics of both foreign-body and Langhans' giant cells. Multinucleated giant cells in lesions comprised both types, with Langhans' giant cells usually outnumbering the foreign-body type.

Necrogranulomas in the lungs of B4, and bronchial lymph node, spleen and liver of A1 were infiltrated by moderate numbers of neutrophils, but macroscopically visible pus formation was not a feature of the lesions. Small numbers of neutrophils infiltrated the lesions in the lung of A1, and the pleura, left prefemoral and right retropharyngeal lymph nodes of B4.

All of the organs sampled for microscopy in A1, except the oesophagus and heart, showed lesions and acid-fast bacilli after ZN staining. For B4, the presence of acid-fast bacilli was generally related to the severity of the lesions. They were visible in almost all organs showing macroscopic

pathology, while not visible in the organs that only showed microscopic pathology (except for the left prefemoral lymph node). B4 displayed acid-fast bacilli in the lungs, pleura and the following lymph nodes: bronchial, mediastinal, sternal, iliac, right prefemoral, left prefemoral and right retropharyngeal. Acid-fast bacilli were numerous (lung, spleen, liver, kidney and the bronchial and mediastinal lymph nodes of A1), to moderate in number (adrenal gland of A1 and lung of B4), to low in number (abomasum, small intestine, colon and rectum of A1, and pleura and the following lymph nodes of B4: bronchial, sternal, iliac and right prefemoral). Very rare acid-fast bacilli were visible in the mediastinal, left prefemoral and right retropharyngeal lymph nodes of B4.

The morphological diagnoses of the tuberculosis and suspected tuberculosis lesions seen in A1 and B4 are listed below, and summarised in Table 3.3. The granulomatous lesions seen in the testes, colon and following lymph nodes: left retropharyngeal, left and right mandibular, left prescapular, mesenteric, ileocaecal and inguinal, of B4 are included in the list as tuberculosis lesions, even though no acid-fast bacilli were seen with ZN staining. The multifocal granulomas in the colon of B4 were probably caused by migrating nematode larvae, but a nematode larva was visible in only one of the four granulomas.

Table 3.3 Summary of tuberculosis lesions in *Mycobacterium tuberculosis* culture-positive animals

Organ	Necrosis		Calcification		Macrophages		Epithelioid Cells		Giant cells		Neutrophil infiltration		Fibrous encapsulation		Acid-fast bacilli	
	A1	B4	A1	B4	A1	B4	A1	B4	A1	B4	A1	B4	A1	B4	A1	B4
Lung	+++	+++	++	++	+++	+++	+++	+++	+	++	+	++	++	++	+++	++
Pleura #	+	+	++	+	ND	+++	ND	+++	ND	+/-	ND	+	-	-	ND	+
Bronchial In.	+++	+++	++	++	+++	+++	+++	+++	++	+++	++	-	++	+	+++	+
Mediastinal In.	+++	+/-	++	+/-	+++	+	+++	+	++	+++	-	-	++	-	+++	+/-
Sternal In.	NS	+	NS	+	NS	+++	NS	+++	NS	+++	NS	-	NS	+/-	NS	+
Iliac In.	NS	+++	NS	++	NS	+++	NS	+++	NS	+++	NS	-	NS	++	NS	+
R-prefemoral In.	NS	+++	NS	++	NS	+++	NS	+++	NS	+++	NS	-	NS	+	NS	+
L-prefemoral In.	NS	+	NS	+	NS	++	NS	++	NS	+++	NS	+	NS	+	NS	+/-
R-retropharyngeal In.	NS	+	NS	+	NS	+++	NS	+++	NS	+++	NS	+	NS	+/-	NS	+/-
L-retropharyngeal In.	NS	-	NS	-	NS	+	NS	+	NS	+/-	NS	-	NS	-	NS	-
R-mandibular In.	NS	-	NS	-	NS	+	NS	-	NS	-	NS	-	NS	-	NS	-
L-mandibular In.	NS	-	NS	-	NS	+	NS	-	NS	-	NS	-	NS	-	NS	-
L-prescapular In.	NS	-	NS	-	NS	+	NS	-	NS	-	NS	-	NS	-	NS	-
Mesenteric In.	NS	-	NS	-	NS	+	NS	+	NS	++	NS	-	NS	-	NS	-
Ileocaecal In.	NS	-	NS	-	NS	+/-	NS	+/-	NS	+++	NS	-	NS	-	NS	-
Inguinal In.	NS	-	NS	-	NS	+	NS	-	NS	+/-	NS	-	NS	-	NS	-
Spleen	+++	NA	-	NA	++	NA	+	NA	+	NA	++	NA	-	NA	+++	-
Liver	+++	NA	-	NA	++	NA	+	NA	+	NA	++	NA	-	NA	+++	-
Kidney	++	NA	-	NA	++	NA	+/-	NA	+/-	NA	-	NA	-	NA	+++	-
Adrenal gland	+/-	NA	-	NA	+	NA	-	NA	-	NA	-	NA	-	NA	++	-
Testicle	NS	-	NS	-	NS	+	NS	-	NS	-	NS	-	NS	-	NS	-
Abomasum	-	NA	-	NA	+/-	NA	-	NA	-	NA	-	NA	-	NA	+	-
Small intestine	-	NA	-	NA	+	NA	-	NA	-	NA	-	NA	-	NA	+	-
Colon	-	-	-	-	+	++	-	++	-	-	-	-	-	-	+	-
Rectum	-	NS	-	NS	+	NS	-	NS	-	NS	-	NS	-	NS	+	NS

Frequency of detection in a lesion:

- = absent
- +/- = rarely found
- + = low
- ++ = medium
- +++ = high

- NS = Not sampled
- NA = Not affected
- ND = No microscopy done
- # = only macroscopy done for A1

A1

Lung: Marked, chronic, multifocal to confluent, necrogranulomatous pneumonia with moderate calcification and numerous intracytoplasmic acid-fast bacilli in macrophages, epithelioid cells, multinucleated giant cells, and in the necrotic exudate.

Pleura: Marked, chronic, multifocal to confluent, proliferative to necrogranulomatous, nodular pleuritis with moderate calcification (No specimens were collected for microscopical examination).

Bronchial lymph node: Marked, chronic, multifocal to confluent, necrogranulomatous lymphadenitis with moderate calcification and numerous intracytoplasmic acid-fast bacilli in macrophages, epithelioid cells, multinucleated giant cells, and in the necrotic exudate.

Mediastinal lymph node: Moderate, chronic, multifocal to confluent, necrogranulomatous lymphadenitis with moderate calcification and numerous intracytoplasmic acid-fast bacilli in macrophages, epithelioid cells, multinucleated giant cells, and in the necrotic exudate.

Spleen: Marked, subacute, multifocal to confluent, necrotic to necrogranulomatous splenitis with numerous intracytoplasmic acid-fast bacilli in macrophages.

Liver: Marked, subacute, focally disseminate, necrotic to necrogranulomatous hepatitis with numerous intracytoplasmic acid-fast bacilli in macrophages and in the necrotic exudate.

Kidney: Marked, subacute, multifocal cortico-medullary, necrogranulomatous interstitial nephritis with numerous intracytoplasmic acid-fast bacilli in macrophages, and rare intracytoplasmic acid-fast bacilli in mesangial cells of renal corpuscles.

Adrenal gland: Mild, subacute, multifocal, granulomatous adrenitis with moderate numbers of intracytoplasmic acid-fast bacilli in macrophages and cortical parenchymal cells.

Abomasum: Mild, subacute, multifocal, granulomatous abomasitis with small numbers of intracytoplasmic acid-fast bacilli in macrophages.

Small intestine: Mild, subacute, multifocal, granulomatous enteritis with small numbers of intracytoplasmic acid-fast bacilli in macrophages.

Colon: Mild, subacute, multifocal, granulomatous colitis with small numbers of intracytoplasmic acid-fast bacilli in macrophages.

Rectum: Mild, subacute, multifocal, granulomatous proctitis with small numbers of intracytoplasmic acid-fast bacilli in macrophages.

B4

Lung: Marked, chronic, multifocal to confluent, necrogranulomatous pneumonia with moderate calcification and moderate numbers of intracytoplasmic acid-fast bacilli in macrophages, epithelioid cells, multinucleated giant cells, and in the necrotic debris and exudate.

Pleura: Marked, chronic, multifocal to confluent, proliferative to necrogranulomatous, nodular pleuritis with mild calcification and moderate numbers of intracytoplasmic acid-fast bacilli in macrophages, epithelioid cells, multinucleated giant cells, and in the necrotic debris and exudate.

Bronchial lymph node: Marked, chronic, multifocal to confluent, necrogranulomatous lymphadenitis with moderate calcification and small numbers of intracytoplasmic acid-fast bacilli in macrophages and in the necrotic debris and exudate.

Mediastinal lymph node: Moderate, subacute, multifocal to confluent, granulomatous lymphadenitis with minimal calcification and rare intracytoplasmic acid-fast bacilli in epithelioid cells and multinucleated giant cells.

Sternal lymph node: Moderate, subacute, multifocal, necrogranulomatous lymphadenitis with mild calcification and rare intracytoplasmic acid-fast bacilli in macrophages and in the necrotic debris and exudate.

Mesenteric Lymph node: Moderate, subacute, multifocal, granulomatous lymphadenitis.

Ileocaecal lymph node: Moderate, subacute, multifocal, granulomatous lymphadenitis.

Iliac lymph node: Marked, chronic, multifocal, necrogranulomatous lymphadenitis with moderate calcification and small numbers of intracytoplasmic acid-fast bacilli in macrophages and in the necrotic debris and exudate.

Right prefemoral lymph node: Marked, chronic, multifocal, necrogranulomatous lymphadenitis with moderate calcification and small numbers of intracytoplasmic acid-fast bacilli in macrophages and in the necrotic debris and exudate.

Left prefemoral lymph node: Moderate, chronic, focal, necrogranulomatous lymphadenitis with mild calcification and rare intracytoplasmic acid-fast bacilli in macrophages.

Right retropharyngeal lymph node: Marked, subacute, multifocal, necrogranulomatous lymphadenitis with mild calcification and rare intracytoplasmic acid-fast bacilli in macrophages and in the necrotic debris and exudate.

Left retropharyngeal lymph node: Mild, subacute, multifocal, granulomatous lymphadenitis.

Right mandibular lymph node: Mild, subacute, multifocal, granulomatous lymphadenitis.

Left mandibular lymph node: Mild, subacute, multifocal, granulomatous lymphadenitis.

Left prescapular lymph node: Mild, subacute, multifocal, granulomatous lymphadenitis.

Inguinal lymph node: Mild, subacute, multifocal, granulomatous lymphadenitis.

Testis: Mild, subacute, multifocal, granulomatous orchitis.

Colon: Mild, subacute, multifocal, granulomatous colitis with one granuloma containing an intralesional nematode larva.

CHAPTER FOUR

4.1 DISCUSSION

This study represents the first confirmed cases of *M. tuberculosis* in springbok. Previous reports of tuberculosis in springbok did not conclusively establish the *Mycobacterium* sp. involved, and no detailed description of the pathology was given (Robinson 1953; Hofmeyr 1956).

Mycobacterium tuberculosis was cultured from three springbok (A1, B4 and B6), indicating a prevalence of 9% (3/33), but only two (A1 and B4) showed tuberculosis lesions. This emphasizes the importance of mycobacterial culture in diagnostic surveys for tuberculosis. There is no documented information on the prevalence of *M. tuberculosis* in infected semi-free ranging and free ranging wildlife. This is not surprising, as HTB is exceptionally rare in wildlife populations not kept in captivity, although it may be an important emerging disease in certain free-ranging wildlife species in some regions of the world (Alexander *et al.* 2002). In captive wildlife, *Mycobacterium tuberculosis* was found to be the third most frequently isolated mycobacterium (11%) among a total of 263 mycobacterial isolates obtained from zoos and wildlife parks in the United States of America in the mid-1970s (Thoen *et al.* 1977). Between 1991 and 2001 a total of 12 cases of *M. tuberculosis* infection in eight different species were recorded at the National Zoological Gardens of South Africa in Pretoria (Michel 2003).

The generalised nature of the lesions in both affected springbok makes it difficult to establish the route of infection, although the oral route appears most likely. The lung lesions in both animals involved the interstitium and alveolar walls rather than the bronchioles, strongly suggesting the oral route of infection. However, the pulmonary lymph nodes in both animals showed marked macroscopic lesions, while the mesenteric and ileocaecal lymph nodes only showed moderate lesions, suggesting infection *via* inhalation. The behavioral pattern of springbok would have facilitated exposure to human excretions in the environment, supporting the oral route of infection. Investigations into the possible source of infection revealed that two of the groundskeepers were under treatment for confirmed *M. tuberculosis* infection (H Kettner, iThemba LABS, pers. comm., 2000). The springbok were semi-free ranging and never handled, so it is highly unlikely that aerosol transmission occurred from the infected humans to springbok. The lung lesions in the springbok were not markedly encapsulated and the possibility of aerosol shedding from open lung lesions, and subsequent intraspecific transmission after the initial infection should also be considered.

Cattle infected with *M. tuberculosis* usually do not develop progressive disease and typically only show small granulomas in the pharyngeal, thoracic and mesenteric lymph nodes (Dungworth 1993; O'Reilly & Daborn 1995; Cousins *et al.* 2004). Captive and free-ranging wildlife, however, often develop extensive lesions and progressive pulmonary disease after infection with *Mycobacterium tuberculosis* (Lomme *et al.* 1976; Montali *et al.* 2001; Alexander *et al.* 2002). Generalised or miliary tuberculosis occurs when there

is haematogenous dissemination of both free and macrophage-associated mycobacteria from the primary site of infection throughout the body. This is most frequently the result of breakdown of a blood vessel by an expanding caseating granuloma or cavitating lesion (Dungworth 1993; López 2001). Susceptible hosts also tend to develop rapidly progressing generalised lesions more readily than resistant animals (De Lisle *et al.* 2002), indicating that springbok should be regarded as highly susceptible. Lesions were found in numerous organs (Table 3.3), and it is likely that A1 would have shown lesions in many more organs if sampling was done more extensively.

The lesions observed in the two affected springbok were dissimilar in appearance in the various organs. The lesions varied in appearance in terms of extent and macro- and microscopic appearance, as indicated in Table 3.3. The variability in lesion appearance is probably a reflection of the progression of the infection as determined by the host's cell-mediated immune response, and ranged from early small granulomatous lesions to chronic encapsulated necrogranulomas and proliferative nodules (Dungworth 1993; Neill *et al.* 1994; Cousins *et al.* 2004). This variability in the appearance of tuberculosis lesions has also been noted for African Buffalo infected with *M. bovis* in the Kruger National Park of South Africa (Kriek, De Vos, Bengis, Huchzermeyer, Keet & Raath 1992; Kriek 1994). This pronounced variation should be considered when assessing the macroscopic lesions for diagnostic purposes in single animals.

The macroscopic and microscopic appearance of the tuberculosis lesions in the springbok mostly conformed to the classical tuberculous granulomatous inflammatory lesions as described for humans, non-human primates and various domesticated animals and wildlife. More specifically the lesions resembled lesions found in herbivores and omnivores. (Francis 1958; Thoen & Himes 1981; Dungworth 1993). There were indistinct to discrete granulomas with or without central caseous necrosis, surrounded by variable, but usually numerous, macrophages, epithelioid cells, multinucleated giant cells, lymphocytes and plasma cells. Fibrous encapsulation was absent to moderate. Calcification was generally mild to moderate and microscopic neutrophil infiltration was only occasionally observed. The pleural nodular lesions were more proliferative with prominent fibroplasia. Multinucleated giant cells consisted of both Langhans' and foreign-body types, with Langhans' giant cells occasionally predominating. This is in accordance with Thomson (1984) who states that the distinction between Langhans' and foreign-body giant cells is not valid, as both types are found in the same lesions and there is no relationship between the type and aetiological agent. Acid-fast bacilli were scanty to numerous, with large clumps visible in the necrotic exudate of the pulmonary lymph nodes of one animal. Some organs showed typical or highly suggestive tuberculous granulomatous lesions but acid-fast bacilli could not be detected. This marked variation in numbers of acid-fast bacilli, and even absence, in typical lesions is commonly found in cattle (Cousins *et al.* 2004).

Some animals, notably certain wildlife species, show obvious differences regarding the appearance and distribution of lesions when compared to those observed in cattle infected with *M. bovis* (De Lisle *et al.* 2002). The lesions in the springbok differed from those in *M.bovis* infected cattle mainly in the degree of calcification. The springbok showed minimal to moderate calcification while cattle often show marked calcification of caseous necrogranulomas (Dungworth 1993). Renal lesions in cattle are limited to the cortex (Dungworth 1993). The renal lesions in A1 occurred in the cortex but were confined to the cortico-medullary junction. Acid-fast bacilli were numerous in the renal granulomas but there were also rare acid-fast bacilli in the mesangial cells of renal corpuscles. Abscessation and fistulation of the parotid lymph nodes are common findings in greater kudu infected by *M. bovis* (Bengis & Keet 1998; Keet *et al.* 2001), but absent in most other species, including springbok. In contrast to herbivores and omnivores, certain *M.bovis* infected carnivore species such as lion show lesions that are more proliferative in nature without caseation, calcification or multinucleated giant cells, but acid-fast bacilli are often numerous (Keet *et al.* 1996; Keet *et al.* 1998; De Lisle *et al.* 2002). The proliferative nodular lesions in the pleura of the springbok resembled the pleural lesions of cattle (Dungworth 1993), and showed, in contrast to lion, caseation, calcification and acid-fast bacilli. Scanty multinucleated giant cells were found in the pleural lesions of springbok.

There are few detailed reports on the pathology of *M. tuberculosis* in wildlife. Most reports only superficially mention or describe the pathology, and concentrate mainly on the epidemiology, mycobacteriology or zoonotic

aspects of the disease (Thoen *et al.* 1977; Michalak *et al.* 1998; Oh, Granich, Scott, Sun, Joseph, Stringfield, Thisdell, Staley, Workman-Malcolm, Borenstein, Lehnkering, Ryan, Soukup, Nitta & Flood 2002; Michel *et al.* 2003).

There is only one report that gives some indication of the pathology of probable *M. tuberculosis* infection in springbok. In this report, two springbok from the Pretoria Zoological Gardens showed extensive tuberculosis lesions of the lungs, with numerous acid-fast bacilli in smears from the lung lesions. The one springbok displayed pus in the lesions that was of a soft creamy consistency (Robinson 1953). The two springbok with tuberculosis lesions in the present study also showed extensive lung lesions with moderate to large numbers acid-fast bacilli, but no macroscopically visible pus.

Two East African Oryxes (*Oryx gazella beisa*) from the same pen at the Jackson Zoological Park in Missouri, USA, had tuberculosis as a result of *M. tuberculosis* infection. One animal died from tuberculosis while the other was euthanased as a result of a positive IDT test. Both showed generalised disease with extensive necrogranulomatous lesions in the lungs, liver, mediastinal and mesenteric lymph nodes. One animal also had necrogranulomas in the uterus. Acid-fast bacilli were visible in the affected organs (Lomme *et al.* 1976). The lesions were generally similar in the springbok, but neither A1 or B4 had macroscopically visible lesions in the mesenteric lymph nodes. Springbok A1 was a ewe but the uterus was not

sampled for microscopic analysis, and therefore the presence of lesions could not be confirmed, although there were no macroscopic lesions.

Mycobacterium tuberculosis infection in captive Asian elephants (*Elephas maximus*) results in necrogranulomas primarily in the lungs and thoracic lymph nodes. With extensive involvement of both lungs, severe calcified necrogranulomas and cavitating lesions with pulmonary abscesses develop that often cause the death of the animal. Typical microscopical findings include granulomas with giant cells in the lymph nodes and lungs initially, that progress to extensive necro- and pyogranulomatous pneumonia in advanced cases. Acid-fast bacilli are sparsely distributed but more easily found in central areas of caseation in the lungs, rather than in the lymph nodes where they are usually rare (Montali *et al.* 2001). Springbok A1 was markedly weakened and recumbent when it was euthanased for necropsy. This animal would have probably died naturally from tuberculosis, indicating that tuberculosis can be fatal, similar to the East African Oryx and Asian elephant. Springbok B4, however, had tuberculosis as an incidental finding. Although the springbok showed marked lesions in the lungs, there was never cavitation or abscessation, and only moderate calcification. The numbers of acid-fast bacilli in the springbok were low to numerous, with large numbers visible in the necrotic exudate of the lungs, and bronchial and mediastinal lymph nodes of A1.

Humans and non-human primates infected with *M. tuberculosis* typically show pulmonary disease with involvement of pulmonary lymph nodes, and

occasionally systemic dissemination. Macroscopic granulomas are characterised by caseation and cavitation. Microscopically the lesions display classical tuberculous granulomatous inflammation with calcification, fibrous encapsulation and variable numbers acid-fast bacilli (Thoen & Himes 1981; Kumar, Cotran & Robbins 1997; Montali 2001). The springbok in the current study had similar lesions but cavitation was not a macroscopic feature.

The main differential diagnosis for the tuberculosis lesions in the springbok was granulomatous inflammation caused by migrating nematode larvae. Adult *Bronchonema magna* lungworms in the airways of the lungs did not cause granulomatous inflammation, except where bronchioles had ruptured. Granulomas occurred in the lungs, various lymph nodes, but mostly the mesenteric lymph node, tonsil, liver, kidney and gastro-intestinal tract. Inspissated and calcified parasitic larval nodules occurred in the abdominal cavity of two animals. The lesions were differentiated from tuberculous granulomas by the presence of larvae in cross-section in most granulomas, the absence of acid-fast bacilli, and infiltration of eosinophils. Many animals had multifocal nodular aggregations of lymphocytes and plasma cells with variable numbers of eosinophils in the liver, particularly the portal tracts. These aggregations probably represent lymphoid follicles in response to parasitic migration and were all negative for acid-fast bacilli.

The focal granuloma in the kidney of C1 resembled a typical tuberculous granuloma both macroscopically and microscopically, but no acid-fast bacilli were visible. The uterus of C1 and C5 showed necro-haemorrhagic bacterial

endometritis and granulomatous endometritis respectively. These lesions probably reflect post-partum involution, with bacterial infection in the case of C1. The lesions did not show acid-fast bacilli, and mycobacterial culture of pooled kidney and uterus specimens from C1 was negative. The gastrocnemius muscle of C20 displayed bilaterally symmetrical areas of calcification macroscopically, which was confirmed to be calcinosis circumscripta microscopically. The liver of C20 showed multifocal granulomatous inflammation that surrounded groups of open fusiform clefts. The cause of the clefts could not be established but they probably contained an immunogenic substance which elicited a foreign-body reaction. Acid-fast bacilli could not be found in the lesions, and the animal was mycobacterial culture-negative.

Mycobacterial culture is regarded as the gold standard for diagnosing tuberculosis (De Lisle *et al.* 2002). *Mycobacterium tuberculosis* was cultured from three springbok (A1, B4 and B6) in this study, but only two had tuberculosis lesions. The historical literature is often ambiguous as to the identity of mycobacteria isolated from animals with tuberculosis. The paper by Robinson (1953) on tuberculosis of springbok indicates that pure cultures of *M. tuberculosis* were obtained from one animal. However, subsequent cultures from guinea-pigs that were inoculated with affected lung material were considered to be of the bovine type. An in-contact springbok that died shortly afterwards yielded a pure culture *M. tuberculosis*, but inoculation of guinea-pigs was never attempted. The identity of the causative *Mycobacterium* sp. in both these cases should be regarded as equivocal,

although *M. bovis* may have been involved. The case of tuberculosis mentioned by Hofmeyr (1956) gives no additional information regarding the causative *Mycobacterium* sp. Springbok B6 did not show any macroscopical or microscopical tuberculosis lesions, and the isolation was made from the organ lymph node pool. This pool comprised the bronchial, mediastinal, hepatic, splenic, ileocaecal and mesenteric lymph nodes. This animal could therefore have been infected *via* either the oral or inhalation route, with bacterial spread to lymph nodes draining either the lungs or gastro-intestinal tract. Springbok B6 may have been sampled during the early infection phase before there was enough time for detectable lesions to develop. Another possible reason for the absence of lesions is localised containment of the infection as a result of an effective immune response.

The isolation of MOTT from B2 and B3 indicates that these animals were exposed and infected by environmental mycobacteria, without the development of tuberculosis lesions. Springbok B2 showed a single cluster of acid-fast bacilli in the cytoplasm of a macrophage in a mesenteric lymph node, without an inflammatory reaction. These acid-fast bacilli were short, straight and thick-set rods, in contrast to the *M. tuberculosis* bacilli in the infected springbok which were all medium to fairly long, slender and often curved. Although the microscopic morphology of acid-fast bacilli cannot be used to identify the causative organism, the morphological difference between the MOTT and *M. tuberculosis* was striking. The morphology of *M. bovis* appears similar to *M. tuberculosis* (Cousins *et al.* 2004). This difference may therefore be a useful microscopical indicator of the *Mycobacterium* sp.

involved, although mycobacterial culture will always be needed to confirm the identity.

The INFg assay was developed to detect *M. bovis* infection in cattle in a single blood sample (Rothel, Jones, Corner, Cox & Wood 1990). A modified INFg assay was developed for use in African buffalo to overcome cross-reactions with environmental mycobacteria (Michel & Jones 1998; Grobler *et al.* 2002). The modified INFg assay was used on the six and 25 springbok that comprised the pilot and main study respectively. Only B5 showed a positive result, but no tuberculosis lesions were present and mycobacterial culture was negative. False-positive reactions may occur as a result of sensitization by environmental mycobacteria (Michel & Jones 1998), but the modified test should have overcome this, and no MOTT were isolated from the INFg positive animal. The assay also failed to correctly identify the two tuberculosis culture-positive animals. The INFg assay therefore had poor sensitivity (0%) as an ante-mortem test to detect the *M. tuberculosis* infected springbok of this study. The specificity was considerably better at 96%. However, the sample size was small and the tuberculosis prevalence low, and therefore more extensive testing will be needed to establish a more reliable indication of the sensitivity and specificity of the assay. An INFg assay has been developed for the ante-mortem detection of *M. tuberculosis* infection in non-human primates, but the monoclonal antibodies used in the ELISA will only recognize the interferon-gamma of non-human primates, precluding its use in other mammals (Anon 2002).

Although the source of infection could not be established conclusively, it is likely to be one or both of the *M. tuberculosis* positive groundskeepers. Unfortunately, both groundskeepers terminated their employment several months before the index case, and it was not possible to get *M. tuberculosis* isolates from them for genomic typing to confirm transmission. Although the initial infection of the springbok at iThemba LABS is likely to be from humans (zooanthroponosis), subsequent intraspecific transmission cannot be ruled out. Tuberculosis was not recorded in any of the other wildlife species on the property during the study period, and only time will tell if they are also infected. The wildlife at iThemba LABS are kept in a semi-free ranging state on the grounds, which is securely fenced, and it is unlikely that they will act as a source of infections to humans. The site is also closed to the general public. iThemba LABS is situated in the Cape Town metropole, which has one of the highest reported incidence rates of tuberculosis in humans in the world (Anon 2001 (a); Anon 2004 (a)). With this high incidence rate in humans, the zooanthroponotic risk of tuberculosis is far greater than the zoonotic potential of tuberculosis in this area.

REFERENCES

- ADAMS, L.G. 2001. In vivo and in vitro diagnosis of *Mycobacterium bovis* infection in: *Mycobacterial infections in domestic and wild animals*, edited by E.J.B. Manning & M.T. Collins. *OIE Scientific and Technical Review*, 20: 304 - 324.
- ALEXANDER, K.A., PLEYDELL, E., WILLIAMS, M.C., LANE, E.P., NYANGE, J.F.C. & MICHEL, A.L. 2002. *Mycobacterium tuberculosis*: an emerging disease of free-ranging wildlife. *Emerging Infectious Diseases*, 8: 598 – 601.
- ANON. 1983. Laboratory manual: Tuberculosis Laboratory, Bacteriology. Onderstepoort Veterinary Institute.
- ANON. 2001 (a). South African National Tuberculosis Association. Latest tuberculosis statistics. <http://www.santa.org.za/main5.html>
- ANON. 2001 (b). Terminology in: *Mycobacterial infections in domestic and wild animals*, edited by E.J.B. Manning & M.T. Collins. *OIE Scientific and Technical Review*, 20: 12 - 20.
- ANON. 2002. Gamma Interferon TB Test for Non-Human Primates Approved for use by U.S.D.A. *Biocor Animal Health and CSL Animal Health Veterinary Diagnostic Newsletter*, Fall 2002: 1.
- ANON. 2004 (a). Cape Town TB Control. A Partnership between the Provincial Administration of the Western Cape Metropole Region and the City of Cape Town. Progress Report 1997 – 2003. <http://www.hst.org.za>
- BASSON, P.A., MCCULLY, R.M., KRUGER, S.P., VAN NIEKERK, J.W., YOUNG, E., DE VOS, V., KEEP, M.E. & EBEDES, H. 1971. Disease conditions of game in Southern Africa: Recent miscellaneous findings. *Veterinary Medical Review*, 2/3: 313 – 340.
- BENGIS, R.G. & KEET, D.F. 1998. Bovine tuberculosis in free-ranging kudu (*Tragelaphus strepsiceros*) in the Greater Kruger National Park complex. *Proceedings of the ARC-Onderstepoort OIE International Congress with WHO-Cosponsorship on Anthrax, Brucellosis, CBPP, Clostridial and Mycobacterial diseases. 9 – 15 August 1998*. Pretoria: Sigma Press: 418 – 421.
- BENGIS, R.G., KOCK, R.A., THOMSON, G.R. & BIGALKE, R.D. 2004. Infectious diseases of animals in sub-Saharan Africa: the wildlife/livestock interface in: *Infectious Diseases of Livestock*, edited by J.A.W. Coetzer & R.C. Tustin. Cape Town: Oxford University Press: 225 – 238.
- BENGIS, R.G., KRIEK, N.P.J., KEET, D.F., RAATH, J.P., DE VOS, V. & HUCHZERMAYER, H.F.A.K. 1996. An outbreak of bovine tuberculosis in a free-living African buffalo (*Syncerus caffer* – Sparman) population in the

Kruger National Park: a preliminary report. *Onderstepoort Journal of Veterinary Research*, 63: 15 – 18.

BROSCH, R., GORDON, S.V., MARMIESSE, M., BRODIN, P., BUCHRIESER, C., EIGLMEIER, K., GARNIER, T., GUTIERREZ, C., HEWINSON, G., KREMER, K., PARSONS, L.M., PYM, A.S., SAMPER, S., VAN SOOLINGEN, D. & COLE, S.T. 2002. A new evolutionary scenario for the *Mycobacterium tuberculosis* complex. *Proceedings of the National Academy of Sciences of the United States of America*, 99: 3684 – 3689.

CORNER, L.A. 1994. Post mortem diagnosis of *Mycobacterium bovis* infection in cattle. *Veterinary Microbiology*, 40: 53 – 63.

COSIVI, O., GRANGE, J.M., DABORN, C.J., RAVIGLIONE, M.C., FUJIKURA, T., COUSINS, D., ROBINSON, R.A., HUCHZERMAYER, H.F.A.K., DE KANTOR, I. & MESLIN, F.-X. 1998. Zoonotic tuberculosis due to *Mycobacterium bovis* in developing countries. *Emerging Infectious Diseases*, 4: 1 – 14.

COOPER, D. 1998. Tuberculosis in wildlife in the Hluhluwe/Umfolozzi complex. Proceedings of *The Southern African Tuberculosis Indaba*. The Mpumalanga Parks Board Headquarters, Nelspruit, South Africa.

COUSINS, D.V., HUCHZERMAYER, H.F.K.A., GRIFFIN, J.F.T., BRÜCKNER, G.K., VAN RENSBURG, I.B.J. & KRIEK, N.P.J. 2004. Tuberculosis in: *Infectious Diseases of Livestock*, edited by J.A.W. Coetzer & R.C. Tustin. Cape Town: Oxford University Press: 1973 – 1993.

DE LISLE, G.W., BENGIS, R.G., SCHMITT, S.M. & O'BRIEN, D.J. 2002. Tuberculosis in free-ranging wildlife: detection, diagnosis and management. *OIE Scientific and Technical Review*, 21: 317 - 334.

DE LISLE, G.W., MACKINTOSH, C.G. & BENGIS, R.G. 2001. *Mycobacterium bovis* in free-living and captive wildlife, including farmed deer in: *Mycobacterial infections in domestic and wild animals*, edited by E.J.B. Manning & M.T. Collins. *OIE Scientific and Technical Review*, 20: 86 - 111.

DE VOS, V., BENGIS, R.G., KRIEK, N.P.J., MICHEL, A., KEET, D.F., RAATH, J.P. & HUCHZERMAYER, H.F.K.A. 2001. The epidemiology of tuberculosis in free-ranging African buffalo (*Syncerus caffer*) in the Kruger National Park, South Africa. *Onderstepoort Journal of Veterinary Research*, 68: 119 – 130.

DE VOS, V., MCCULLY, R.M. & VAN NIEKERK, C.A.W.J. 1977. Mycobacteriosis in the Kruger National Park. *Koedoe*, 20: 1 – 9.

DUNGWORTH, D.L. 1993. The respiratory system in: *Pathology of Domestic Animals*, 4th edn., Vol. 2, edited by K.V.F. Jubb, P.C. Kennedy & N. Palmer. San Diego: Academic Press: 641 - 652.

FITZGERALD, S.D., KANEENE, J.B., BUTLER, K. L., CLARKE, K.R., FIERKE, J.S., SCHMITT, S.M., BRUNING-FANN, C.S., MITCHELL, R.R., BERRY, D.E. & PAYEUR, J.B. 2000. Comparison of postmortem techniques for the detection of *Mycobacterium bovis* in white-tailed deer (*Odocoileus virginianus*). *Journal of Veterinary Diagnostic Investigation*, 12: 322 – 327.

FORSHAW, D. & PHELPS, G.R. 1991. Tuberculosis in a captive colony of pinnipeds. *Journal of Wildlife Diseases*, 27: 288 – 295.

FOURIE, P.B. 1983. Tuberculosis in captive wild mammals: the situation in South Africa. *South African Journal of Science*, 79: 345 – 346

FRANCIS, J. 1958. *Tuberculosis in animals and man. A study of comparative pathology*. London: Cassell and Company.

FREDRICKSON, L.E., BARTON, C.E., RAGAN, J.R. & ROBERTS, J.W. 1971. An epizootic of tuberculosis in a municipal zoo: a public health problem. *Journal of the American Veterinary Medical Association*, 159: 1474 – 1476.

GRIFFIN, J.F.T. & MACINTOSH, C.G. 2000. Tuberculosis in deer: perceptions, problems and progress. *The Veterinary Journal*, 160: 202 – 219.

GROBLER, D.G., MICHEL, A.L., DE KLERK, L.-M. & BENGIS, R.G. 2002. The gamma-interferon test: its usefulness in a bovine tuberculosis survey in African buffaloes (*Syncerus caffer*) in the Kruger National Park. *Onderstepoort Journal of Veterinary Research*, 69: 221 – 227.

HOFMEYR, C.F.B. 1956. Two hundred and eighty-four autopsies at the National Zoological Gardens, Pretoria. *Journal of the South African Veterinary Medical Association*, 27: 263 – 282.

KEEP, M.E. & BASSON, P.A. 1973. Mycobacteriosis in black rhinoceros (*Diceros bicornis* Linnaeus, 1758). *Journal of the South African Veterinary Association*, 44: 285 – 286.

KEET, D.F., KRIEK, N.P.J., BENGIS, R.G. & MICHEL, A.L. 2001. Tuberculosis in kudu (*Tragelaphus strepsiceros*) in the Kruger National Park. *Onderstepoort Journal of Veterinary Research*, 68: 225 – 230.

KEET, D.F., KRIEK, N.P.J., HUCHZERMEYER, H. & BENGIS, R.G. 1994. Advanced tuberculosis in an African buffalo (*Syncerus caffer* Sparrman). *Journal of the South African Veterinary Association*, 65: 79 – 83.

KEET, D.F., KRIEK, N.P.J., PENRITH, M.-L. & MICHEL, A. 1998. Tuberculosis in free-ranging lions in the Kruger National Park. *Proceedings of the ARC-Onderstepoort OIE International Congress with WHO-Cosponsorship on Anthrax, Brucellosis, CBPP, Clostridial and Mycobacterial diseases. 9 – 15 August 1998*. Pretoria: Sigma Press: 444 – 453.

KEET, D.F., KRIEK, N.P.J., PENRITH, M.-L., MICHEL, A. & HUCHZERMAYER, H. 1996. Tuberculosis in buffaloes (*Syncerus caffer*) in the Kruger National Park: spread of the disease to other species. *Onderstepoort Journal of Veterinary Research*, 63: 239 – 244.

KOVALEV, G.K. 1980. Tuberculosis in wildlife (review). *Journal of Hygiene, Epidemiology, Microbiology and Immunology*, 24: 495 – 504.

KRIEK, N.P.J. 1994. Macroscopic assessment of tuberculous lesions in African buffalo (*Syncerus caffer*). *Proceedings of the Tuberculosis in Animals Symposium*, 17 – 18 March 1994, OVI, Pretoria, South Africa.

KRIEK, N.P.J., DE VOS, V., BENGIS, R., HUCHZERMAYER, R., KEET, D. & RAATH, J. 1992. Pathology of bovine tuberculosis in buffalo in the Kruger National Park. Poster presentation at the *Third International Wildlife Ranching Symposium*, 27 – 30 October 1992, CSIR, Pretoria, South Africa.

KUMAR, V., COTRAN, R.S., ROBBINS, S. L. 1997. Lungs and the upper respiratory tract in: *Basic Pathology*, 6th edn., edited by V. Kumar, R.S. Cotran & S. L. Robbins: W.B. Saunders Company: 393 – 438.

LOMME, J.R., THOEN, C.O., HIMES, E.M., VINSON, J.W. & KING, R.E. 1976. Mycobacterium tuberculosis infection in two east African Oryxes. *Journal of the American Veterinary Medical Association*, 169: 912 – 914.

LÓPEZ, A. 2001. Respiratory system, thoracic cavity, and pleura in: *Thomson's Special Veterinary Pathology*, 3rd edn., edited by M.D. McGavin, W.W. Carlton & J.F. Zachary. St. Louis: Mosby, Inc: 170 – 171.

MARTINAGLIA, G. 1930. A strain of *Mycobacterium tuberculosis* from the giraffe and further observations of *M.tuberculosis* from the koodoo and the duiker. *16th Report of the Director of Veterinary Services and Animal Industry, Union of South Africa*, 143 – 145.

MICHALAK, K., AUSTIN, C., DIESEL, S., BACON, J.M., ZIMMERMAN, P. & MASLOW, J.N. 1998. *Mycobacterium tuberculosis* infection as a zoonotic disease: transmission between humans and elephants. *Emerging Infectious Diseases*, 4: 283 – 287.

MICHEL, A.L. & HUCHZERMAYER, H.F.A.K. 1998. The zoonotic importance of *Mycobacterium tuberculosis*: transmission from human to monkey. *Journal of the South African Veterinary Association*, 69: 64 – 65.

MICHEL, A.L. & JONES, S. 1998. Non-specific reactions to the “gamma-interferon-assay” in buffalo in South Africa. *Proceedings of the ARC-Onderstepoort OIE International Congress with WHO-Cosponsorship on Anthrax, Brucellosis, CBPP, Clostridial and Mycobacterial diseases*. 9 – 15 August 1998. Pretoria: Sigma Press: 388 – 392.

MICHEL, A.L., VENTER, L., ESPIE, I.W. & COETZEE, M.L. 2003. *Mycobacterium tuberculosis* infections in eight species at the National Zoological Gardens of South Africa, 1991 – 2001. *Journal of Zoo and Wildlife Medicine*, 34: 364 – 370.

MONTALI, R.J., MIKOTA, S.K. & CHENG, L.I. 2001. *Mycobacterium tuberculosis* in zoo and wildlife species in: *Mycobacterial infections in domestic and wild animals*, edited by E.J.B. Manning & M.T. Collins. *OIE Scientific and Technical Review*, 20: 291 - 303.

NEILL, S.D., POLLOCK, J.M., BRYSON, D.B. & HANNA, J. 1994. Pathogenesis of *Mycobacterium bovis* infection in cattle. *Veterinary Microbiology*, 40: 41 – 52.

OH, P., GRANICH, R., SCOTT, J., SUN, B., JOSEPH, M., STRINGFIELD, C., THISDELL, S., STALEY, J., WORKMAN-MALCOLM, D., BERENSTEIN, L., LEHNKERING, E., RYAN, P., SOUKUP, J., NITTA, A. & FLOOD, J. 2002. Human exposure following *Mycobacterium tuberculosis* infection of multiple animal species in a metropolitan zoo. *Emerging Infectious Diseases*, 8: 1290 – 1293.

O'REILLY, L.M. & DABORN, C.J. 1995. The epidemiology of *Mycobacterium bovis* infections in animals and man: a review. *Tubercle and Lung Disease*, 76 Supplement 1: 1 – 46.

PAINE, R. & MARTINAGLIA, G. 1929. Tuberculosis in wild buck living under natural conditions. *Journal of the South African Veterinary Medical Association*, 1: 87 – 91.

RASTOGI, N., LEGRAND, E. & SOLA, C. 2001. The mycobacteria: an introduction to nomenclature and pathogenesis in: *Mycobacterial infections in domestic and wild animals*, edited by E.J.B. Manning & M.T. Collins. *OIE Scientific and Technical Review*, 20: 21 - 54.

ROBINSON, E.M. 1953. A few cases of tuberculosis. *Journal of the South African Veterinary Medical Association*, 24: 97 – 99.

ROBINSON, E.M. 1944. A note on strains of tuberculosis from the Cape kudu. *Onderstepoort Journal of Veterinary Science and Animal Industry*, 19: 23.

ROTHEL, J.S., JONES, S.L., CORNER, L.A., COX, J.C. & WOOD, P.R. 1990. A sandwich enzyme immunoassay for bovine interferon- γ and its use for the detection of tuberculosis in cattle. *Australian Veterinary Journal*, 67: 134 – 137.

STETTER, M.D., MIKOTA, S.K., GUTTER, A. F., MONTEROSSO, E.R., DALOVISIO, J.R., DEGRAW, C. & FARLEY, T. 1995. Epizootic of *Mycobacterium bovis* in a zoological park. *Journal of the American Veterinary Medical Association*, 207: 1618 – 1621.

TARARA, R., SULEMAN, M.A., SAPOLSKY, R., WABOMBA, M.J. & ELSE, J.G. 1985. Tuberculosis in wild olive baboons, *Papio cynocephalus anubis* (Lesson), in Kenya. *Journal of Wildlife Diseases*, 21: 137 – 140.

THOEN, C.O. 1988. Tuberculosis. *Journal of the American Veterinary Medical Association*, 193: 1045 – 1048.

THOEN, C.O. & HIMES, E.M. 1981. Tuberculosis in: *Infectious Diseases of Wild Animals*, edited by J.W. Davis, L.H. Karsted & D.O. Trainer. Ames: Iowa State University Press: 263 – 274.

THOEN, C.O., RICHARDS, W.D. & JARNAGIN, J.L. 1977. Mycobacteria isolated from exotic animals. *Journal of the American Veterinary Medical Association*, 170: 987 – 990.

THOMSON, R.G. 1984. *General Veterinary Pathology*. Philadelphia: W.B. Saunders Company

THORNBURN, J.A. & THOMAS, A.D. 1940. Tuberculosis in the Cape kudu. *Journal of the South African Veterinary Medical Association*, 11: 3.

WOOD, P.R. 1994. Gamma interferon assay and ELISA for the diagnosis of mycobacterial infections. *Proceedings of the Tuberculosis in Animals Symposium*, 17 – 18 March 1994, OVI, Pretoria, South Africa.

WOOD, P.R., CORNER, L.A., ROTHEL, J.S., BALDOCK, C., JONES, S.L., COUSINS, D.B., MCCORMICK, B.S., FRANCIS, B.R., CREEPER, J. & TWEDDLE, N.E. 1991. Field comparison of the interferon-gamma assay and the intradermal tuberculin test for the diagnosis of bovine tuberculosis. *Australian Veterinary Journal*, 68: 286 – 290.

WOOD, P.R. & ROTHEL, J.S. 1994. In vitro immunodiagnostic assays for bovine tuberculosis. *Veterinary Microbiology*, 40: 125 – 135.

WOODFORD, M.H. 1982 (a). Tuberculosis in wildlife in the Ruwenzori National Park, Uganda (Part 1). *Tropical Animal Health and Production*, 14: 81 – 88.

WOODFORD, M.H. 1982 (b). Tuberculosis in wildlife in the Ruwenzori National Park, Uganda (Part 2). *Tropical Animal Health and Production*, 14: 155 – 159.

ZIEGER, U., PANDEY, G.S., KRIEK, N.P. & CAULDWELL, A.E. 1998. Tuberculosis in Kafue lechwe (*Kobus leche kafuensis*) and in a bushbuck (*Tragelaphus scriptus*) on a game ranch in central province, Zambia. *Journal of the South African Veterinary Association*, 69: 98 – 101.