

## Krimpsiekte in a sheep following a single dose of *Tylecodon ventricosus* (Burm. f.) Toelken and the isolation of tyledoside D from this plant species

C.J. BOTHA<sup>1</sup>, T.S. KELLERMAN<sup>1, 2</sup>, R. ANITRA SCHULTZ<sup>2</sup>, G.L. ERASMUS<sup>2</sup>  
R. VLEGGGAAR<sup>3</sup> and ELIZABETH RETIEF<sup>4</sup>

### ABSTRACT

BOTHA, C.J., KELLERMAN, T.S., SCHULTZ, R. ANITRA, ERASMUS, G.L., VLEGGGAAR, R. & RETIEF, ELIZABETH. 1998. Krimpsiekte in a sheep following a single dose of *Tylecodon ventricosus* (Burm. f.) Toelken and the isolation of tyledoside D from this plant species. *Onderstepoort Journal of Veterinary Research*, 65:17–23

*Tylecodon ventricosus* induced severe respiratory distress in two penned sheep without any electrocardiographic abnormalities being recorded. Based on the results it appears as if *T. ventricosus* predominantly induces the neuromuscular syndrome referred to as krimpsiekte. A single, relatively large intraruminal dose of 10,0 g/kg induced krimpsiekte in one sheep. Treatment with 5,0 g/kg activated charcoal on two consecutive days did not prevent the development of krimpsiekte. A bufadienolide, tyledoside D, was isolated from semi-dried plant material.

**Keywords:** Bufadienolide, cardiac glycoside, krimpsiekte, sheep, *Tylecodon ventricosus*, tyledoside D

### INTRODUCTION

Poisoning of livestock with cardiac glycoside-containing plants is collectively the most important plant poisoning in the Republic of South Africa (Kellerman, Naudé & Fourie 1996). Based on symptomatology, cardiac glycoside intoxication is classified as either an acute or chronic condition. Krimpsiekte, a chronic form of cardiac glycoside poisoning, manifests as a paretic syndrome and predominantly occurs in small stock. Affected stock lag behind the flock; assume a characteristic posture, with feet together and back

arched (hence “krimpsiekte” or “shrinking disease”); display torticollis; often lie down and eventually become paralysed. In general, the cardiac, respiratory and intestinal symptoms, which are typical in acute poisoning, diminish and the neuromuscular signs increase (Kellerman, Coetzer & Naudé 1988; Kellerman *et al.* 1996).

Krimpsiekte occurs following ingestion of certain members of the Crassulaceae (*Cotyledon*, *Tylecodon* and *Kalanchoe* species) which are collectively and colloquially known as “plakkies”. This toxicosis is generally believed to be caused by cumulative bufadienolides with unique neurotoxic properties, encountered in these genera (Kellerman *et al.* 1988; Naudé, Anderson, Schultz & Kellerman 1992). Naudé & Schultz (1982) coined the term “cumulative bufadienolides” following the successful demonstration of a cumulative effect with cotyledoside isolated from *Tylecodon wallichii*. These authors determined the subcutaneous LD<sub>50</sub> of cotyledoside in guinea-pigs and then injected others subcutaneously with 25 % and 50 % of the subcutaneous LD<sub>50</sub> per day until they died. Although no clinical signs appeared before the LD<sub>50</sub> was reached, marked nervous signs occurred

<sup>1</sup> Department of Pharmacology and Toxicology, Faculty of Veterinary Science, University of Pretoria, Onderstepoort, 0110 South Africa

<sup>2</sup> Division of Toxicology, Onderstepoort Veterinary Institute, Onderstepoort, 0110 South Africa

<sup>3</sup> Department of Chemistry, Faculty of Science, University of Pretoria, Pretoria, 0002 South Africa

<sup>4</sup> National Botanical Institute, Private Bag X101, Pretoria, 0001 South Africa

when 5 x 25 % or 3 x 50 % the LD<sub>50</sub> were administered (Naudé & Schultz 1982).

Krimpsiekte can be a limiting factor for small stock production in the little Karoo and southern fringes of the great Karoo (Fig. 1) (Kellerman *et al.* 1996). Vahrmeijer (1981) stated that krimpsiekte or "nenta" has been a serious problem in southern Africa since 1775. The condition was successfully reproduced in 1891 when Soga fed *Tylecodon ventricosus* to goats, the first plant poisoning to be experimentally-induced in South Africa (Soga 1891).

As the clinical signs of krimpsiekte may be confused with general weakness due to heart failure or even botulism, it was decided again to reproduce krimpsiekte with this historic plant. Since a novel neurotoxic substance could not be isolated from *T. wallichii* (Botha, Van der Lugt, Erasmus, Kellerman, Schultz & Vleggaar 1997) it was considered essential to determine whether the active principle(s) of *T. ventricosus* also were cardiac glycosides.

Although *T. ventricosus* was the first plant with which krimpsiekte was successfully reproduced (Soga 1891), a botanical description of the plant has not yet appeared in the veterinary literature and the toxic principle(s) has never been isolated.

### **TYLECODON VENTRICOSUS (BURM. F.) TOELKEN**

*Tylecodon ventricosus* (Fig. 2) belongs to the Crassulaceae, a cosmopolitan plant family with centres of diversity in southern Africa and central America. The species of the Crassulaceae are well-known leaf and stem succulents (Toelken 1985).

#### **DESCRIPTION**

Perennial, usually with a branched, tuberous base.

<b>Stems</b>	one to many, up to 0,3 m tall, fleshy, 13–20 mm in diameter, pale green or brown.
<b>Leaves</b>	linear to oblanceolate, 30–60 x 3–20 mm, apex acute, glandular-pubescent to glabrescent; old leaves remaining attached to phyllopodia.
<b>Inflorescence</b>	a thyrses, usually with one to three monochasia, each with one to three flowers; peduncle up to 0,38 m tall, brown, glandular-pubescent; pedicels up to 24 mm long, upright (Fig. 3).
<b>Calyx</b>	five-partite; lobes triangular, 8–12 mm long, sharply acute, glandular-tomentose, green.

**Corolla** glandular-tomentose to pubescent outside; tube cylindrical to obconical, but bulging about the middle, 16–19 x 8–11 mm; yellowish green below with purplish brown veins higher up; lobes 8–11 mm long, recurved at apex.

**Carpels** five, usually free, with distinct styles.

**Seeds** ellipsoid, covered with vertical ridges and dense horizontal striations in grooves (Toelken 1985).

#### **Flowering time**

September to March.

#### **Relationships**

*Tylecodon* species are characterized by their spirally arranged, non-waxy, herbaceous, deciduous leaves (Smith, Hobson, Meyer, Chesselet, Archer, Burgoyne, Glen, Herman, Retief, Smithies, Van Jaarsveld & Welman 1993). *Adromischus* taxa also have spirally arranged leaves, but they are fleshy. The genera *Crassula*, *Cotyledon*, *Kalanchoe* and *Bryophyllum* usually all have opposite leaves. *Tylecodon* can be divided into two groups. The group to which *T. ventricosus* belongs has leaves without a basal abscission layer, with the old leaves gradually wearing away. The other group has a basal abscission layer with no remains of old leaves attached to the stems. According to Toelken (1978), *T. ventricosus* is an extremely variable species which is distinguished from a number of very similar species by its thick stems, phyllopodia even when young and long, yellowish green petals with purplish brown veins. *Tylecodon ventricosus* is closely related to *T. grandiflorus* (Burm. f.) Toelken. The relevant species, however, has actinomorphic flowers and a yellowish green corolla with purplish brown veins in contrast to *T. grandiflorus* which is the only member of the Crassulaceae with orange to red, zygomorphic flowers (Toelken 1985).

#### **HABITAT**

Rock crevices, usually in the shade of smaller shrublets.

#### **DISTRIBUTION**

*Tylecodon ventricosus* is widespread in the Northern, Western and Eastern Cape Provinces of the Republic of South Africa (Fig. 4). It is usually only known from isolated localities. The species occurs in various veld types, as defined by Acocks (1988), namely, Strandveld, Fynbos, Succulent Karoo, Mountain Renosterveld, Orange River Broken Veld, Karoo and karroid types.

**COMMON NAME**

Klipnenta or nenta.

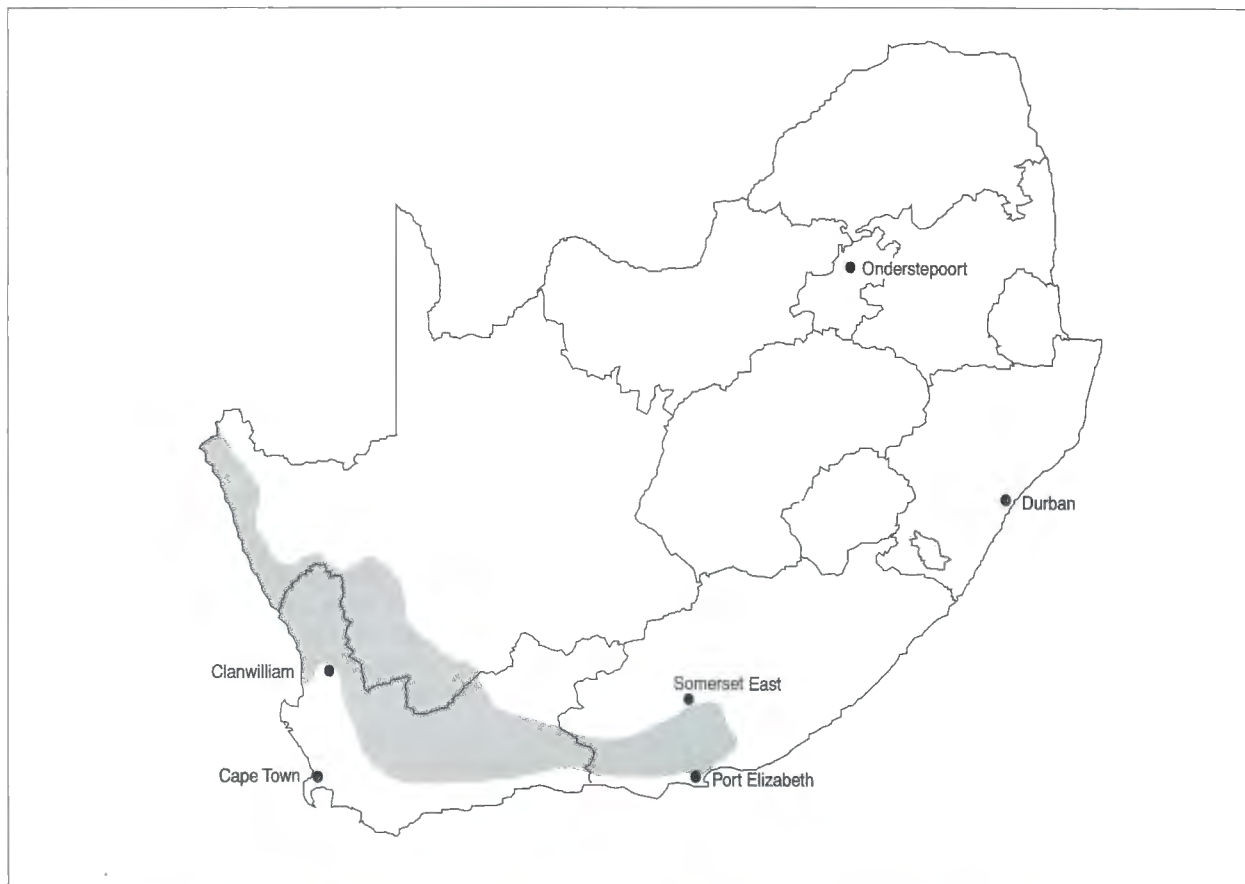


FIG. 1 The distribution of krimpsiekte in the Republic of South Africa

FIG. 2  
*Tylecodon ventricosus* (Burm. f.) Toelken




FIG. 3  
The inflorescence of *T. ventricosus* with the flowers in an upright position

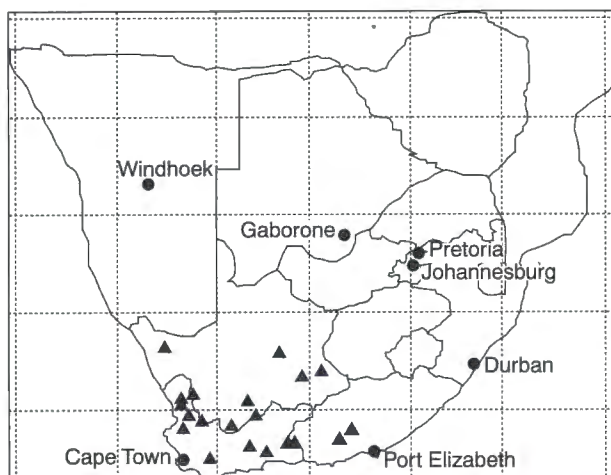


FIG. 4 The distribution of *T. ventricosus* in the Republic of South Africa



FIG. 5 Sheep 2 exhibiting the typical krimpsiekte-posture

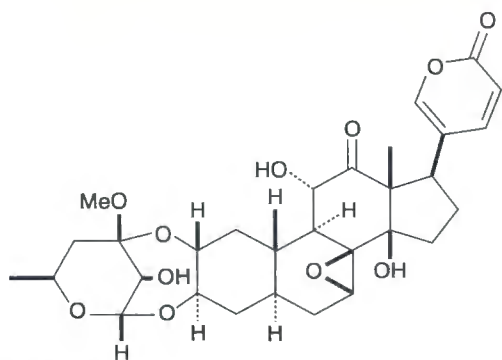


FIG. 6 Tyledoside D

## TYLECODON VENTRICOSUS DOSING TRIAL

### Materials and methods

Two adult sheep, fitted with large rumen cannulae, were individually penned on concrete floors at the Laboratory Animal Facility of the Toxicology Division,

Onderstepoort Veterinary Institute. They had free access to water and were fed chopped hay and a pelleted maize concentrate. During the adaptation period, daily clinical examinations and ECG (Ectromed) recordings, using Lead II, were carried out to establish baseline values (Schultz, Pretorius, & Terblanche 1972). Fresh *T. ventricosus* grown at the Facility from cuttings collected at Willowmore, Eastern Cape Province, was dosed via the rumen cannulae to two sheep as described in Table 1. Once signs of poisoning were noticed, the clinical examinations were more frequently carried out. When clinical signs of poisoning became severe activated charcoal (Joubert & Schultz 1982a,b,c) was administered at 2,0 and 5,0 g/kg to sheep 1 and sheep 2, respectively.

## RESULTS

The clinical signs are summarized in order of appearance in Table 1. *Tylecodon ventricosus* was administered at an incremental dose rate of 2,5; 5,0 and 10,0 g/kg, on three consecutive days, to sheep 1. The most prominent clinical signs were asphyxiation (presumably as a result of respiratory paralysis) and tachycardia. Save for an increase in heart rate a normal ECG was recorded. The sheep died on day 3 following a respiratory crisis minutes after being dosed with activated charcoal.

Sheep 2, dosed only once with 10,0 g/kg plant material intraruminally, displayed severe dyspnoea on day 1. No ECG abnormalities, even at this relatively high dose, were recorded. Physical removal of the rumen contents through the cannula and two treatments of 5,0 g/kg activated charcoal probably saved the life of the animal, but did not prevent the progression to krimpsiekte. Typical signs of krimpsiekte were evinced by the sheep from day 6 to day 22 (Fig. 5).

## ISOLATION OF THE TOXIC PRINCIPLE(S)

### Materials and methods

*Tylecodon ventricosus* was collected on the farm Carmel (33°13'S, 25°57'E) in the Somerset East district, Eastern Cape Province. Five kilograms of the semi-dried milled plant was extracted twice with ethyl acetate; the residue was discarded and the supernatant concentrated by rotary evaporation under reduced pressure (Büchi, Switzerland). The extracted fraction was dissolved in methanol and water (95:5) before being defatted with an equal volume of hexane. The hexane fraction was discarded. Separation of the compounds was achieved using column chromatography (silica gel 60 and LiChroprep RP-8, Merck). Fractions were analyzed by thin-layer chromatography on silica gel 60 F<sub>254</sub> plates (Merck). Fractions containing compounds with similar R<sub>f</sub> values were combined. These different fractions were dosed

TABLE 1 Dosing regimen, clinical signs and treatment of two sheep following intraruminal administration of fresh *T. ventricosus* plant material

Sheep						Clinical signs and treatment
No.	Breed	Age (years)	Sex	Body mass (kg)	Dosing regimen	
					Day	Dose (g/kg)
1	Merino	2	Wether	68	0 1 2 3	2,5 5,0 10,0 —
						<p>N/a</p> <p>N/a</p> <p>N/a</p> <p>Forced respiration (09:00), abdominal breathing, neck stretched, mouth open (= asphyxiation). Tachycardia (150 beats/minute), but an otherwise normal ECG. Ruminant stasis. Administered activated charcoal (2,0 g/kg), died suddenly minutes later (13:30)</p>
2	Dorper	3	Wether	74	0 1 2–22	10,0 — —
						<p>N/a</p> <p>Ruminal stasis, dyspnoea (= abdominal respiration), treated by removing ingesta through cannula and administer 5,0 g/kg activated charcoal</p> <p>Shallow abdominal breathing with double respiratory effort, ruminal stasis, ECG normal, repeat activated charcoal treatment at 5,0 g/kg (D 2). Apathetic, but apparently recovered (D 3). Following survival of the acute phase, typical signs of krimpsteekte developed on D 6. Removed ruminal ingesta and inoculated with 10 l ruminal fluid (D 10 &amp; 11). Krimpsteekte (weak, head low, assumes typical stance with back arched and feet together, often lying down, difficulty in lying down) persisted for 2½ weeks (D 22)</p>

N/a = no abnormality

orally to male, albino guinea-pigs (190–251 g body mass) to ascertain toxicity (Botha *et al.* 1997). A single toxic compound was purified. An ultraviolet absorption spectrum was obtained (UV-260, Shimadzu) and the toxin was further analyzed by nuclear magnetic resonance (NMR) spectroscopy. The  $^1\text{H}$  and  $^{13}\text{C}$  NMR spectra were measured for solutions in  $\text{CDCl}_3$  on a Bruker AC-300 (7.0 T) spectrometer operating at 300 MHz for  $^1\text{H}$  and 75 MHz for  $^{13}\text{C}$ .

## RESULTS

Two toxic compounds were isolated from *T. ventricosus*, although only one principle (5,0 mg) could be purified. Maximum UV absorption occurred at 288 nm indicating a gamma-lactone ring. All NMR signals matched those of an authentic sample of tyledoside D (Fig. 6) previously isolated from *T. grandiflorus* (Anderson, Joubert, Prozesky, Kellerman, Schultz, Procos & Olivier 1983; Steyn, Van Heerden, Vleggaar & Anderson 1986). The other fraction which was also toxic to guinea-pigs could not be purified as the total yield was only 3,0 mg. An UV absorption spectrum of this impure compound registered maximum absorption at 286,8 nm, indicating a similar compound.

## DISCUSSION

The findings of this trial bore out historical evidence that krimpsiekte can occur in hungry, newly introduced stock, taking in large amounts of plakies on heavily infested veld (Henning 1926; Henning 1932). The results of this limited trial suggest that *T. ventricosus* induces only the neuromuscular syndrome. However, in the light of our current knowledge, it is difficult to explain how a single, high dose of *T. ventricosus* (supposedly containing cardiac glycosides) could induce krimpsiekte (a purely neurological effect) apparently without electrophysiological cardiac involvement. According to our current understanding, high doses of plants containing cumulative bufadienolides cause signs of acute cardiac glycoside poisoning while small doses over a period of time result in chronic poisoning or krimpsiekte (Naudé & Schultz 1982; Kellerman *et al.* 1988). Since there was no indication of a cumulative effect in the trial described here, it implied that an unidentified non-cardiac glycoside neurotoxin may be the causative agent. However, in the current as well as in the previous study (Botha *et al.* 1997) no corroborating evidence could be found that a neurotoxin other than a cardiac glycoside is involved in the aetiology of krimpsiekte.

Anderson *et al.* (1983) demonstrated that tyledoside D is cumulative. These authors administered small, consecutive daily doses (3 x 50 % or 5–6 x 25 % of the approximate subcutaneous  $\text{LD}_{50}$ ) of tyledosides A, C, D, E and F subcutaneously to guinea-pigs. The

manifestation of clinical signs (i.e. tremors, neck paresis and paralysis) and/or mortality at such doses of tyledosides A, D and F were considered as indicative of their cumulative effect. Since the guinea-pigs injected with tyledoside C and E recovered between successive doses, these bufadienolides were deemed non-cumulative.

Sheep 1 died suddenly of suspected respiratory paralysis soon after the administration of activated charcoal. Joubert & Schultz (1982b) also reported that animals acutely poisoned with cardiotoxic glycosides (e.g. tulp poisoning) succumb during the treatment process, possibly as result of "stress" induced by the handling, intubation and restraint of these physiologically compromised animals. Hypoxaemia resulting from pulmonary dysfunction is central to the pathophysiological derangements encountered before death in this type of acute poisoning (Button, Reyers, Meltzer, Mülders & Killeen 1983; Button & Mülders 1984).

Sheep 2 developed krimpsiekte in spite of twice being treated with activated charcoal. Activated charcoal at 5,0 g/kg is usually very effective in the treatment of acute cardiac glycoside poisoning (Joubert & Schultz, 1982a,b). This implies that once the cumulative bufadienolides have been absorbed, activated charcoal is not as effective in treating krimpsiekte as acute poisoning. Activated charcoal has been shown to enhance the clearance of digoxin administered intravenously to human volunteers (Lalonde, Deshpande, Hamilton, McLean & Greenway 1985). The beneficial effect of activated charcoal possibly involves disruption of the enterohepatic circulation of digoxin as well as adsorption of digoxin molecules diffusing into the gastrointestinal lumen, thereby also maximizing the diffusion gradient (Lalonde *et al.* 1985). In this study, treatment with activated charcoal did not prevent krimpsiekte and it is surmised that once absorbed, these particular neurotoxic bufadienolides might have such a strong affinity for and/or a very stable binding to receptor sites that it renders the binding not readily reversible.

No signs of cardiac involvement could be detected in either of these acutely poisoned sheep, even with the aid of an ECG. The apparent lack of conductive changes in the heart is consistent with previous reports (Anderson *et al.* 1983; Botha *et al.* 1997).

A laevorotatory sugar at  $\text{C}_3$  of the aglycone's A-ring which in all cases, except for the lanceotoxins, is very strongly (either doubly or triply) ether-linked to this ring appears to be the only common features to all the cumulative bufadienolides so far identified. This could be the reason for possible kinetic and dynamic differences resulting in the unique neurotoxic property exhibited by these compounds (Naudé *et al.* 1992). It has been shown that neurospecificity of some of the cumulative bufadienolides is not related to differences in  $\text{Na}^+/\text{K}^+$ -pump inhibition (Van der

Walt, Van Rooyen, Kellerman, Carmeliet & Verdonck 1997). Further studies are necessary to determine the precise pathogenesis of krimpsiekte.

## ACKNOWLEDGEMENTS

We would like to extend our gratitude to Dr M.P. van Aardt (Veterinary Regional Laboratory, Middelburg) who arranged the collection and sending of the plant material and to Mr B.P. Maartens for technical assistance.

## REFERENCES

- ACOCKS, J.P.H. 1988. *Veld types of South Africa*. [Pretoria]: Botanical Research Institute, Department of Agriculture and Water Supply, South Africa (Memoirs of the Botanical Survey of South Africa; no. 57).
- ANDERSON, L.A.P., JOUBERT, J.P.J., PROZESKY, L., KELLERMAN, T.S., SCHULTZ, R., ANITRA, PROCOS, J. & OLIVIER, PHILLIPA M. 1983. The experimental production of krimpsiekte in sheep with *Tylecodon grandiflorus* (Burm. F.) Toelken and some of its bufadienolides. *Onderstepoort Journal of Veterinary Research*, 50:301–307.
- BOTHA, C.J., VAN DER LUGT, J.J., ERASMUS, G.L., KELLERMAN, T.S., SCHULTZ, R., ANITRA & VLEGGAAR, R. 1997. Krimpsiekte, associated with thalamic lesions, induced by the neurotoxic cardiac glycoside, cotyledoside, isolated from *Tylecodon wallichii* (Harv.) Toelken subsp. *wallichii*. *Onderstepoort Journal of Veterinary Research*, 64:189–194.
- BUTTON, C., REYERS, F., MELTZER, D.G.A., MÜLDERS, MARIA S.G. & KILLEEN, VALERIE M. 1983. Some physiopathological features of experimental *Homeria glauca* (Wood & Evans) N. E. Br. poisoning in Merino sheep. *Onderstepoort Journal of Veterinary Research*, 50:191–196.
- BUTTON, C. & MÜLDERS, MARIA S.G. 1984. Further physiopathological features of experimental *Homeria glauca* (Wood & Evans) N. E. Br. poisoning in Merino sheep. *Onderstepoort Journal of Veterinary Research*, 51:95–96.
- HENNING, M.W. 1926. Krimpsiekte. *11th and 12th Reports of the Director of Veterinary Education and Research, Union of South Africa*, 1:331–365.
- HENNING, M.W. 1932. *Animal diseases in South Africa*, II. South African Agricultural Series. XII. Johannesburg: Central News Agency, Ltd.
- JOUBERT, J.P.J. & SCHULTZ, R., ANITRA 1982a. The treatment of *Urginea sanguinea* Schinz poisoning in sheep with activated charcoal and potassium chloride. *Journal of the South African Veterinary Association*, 53:25–28.
- JOUBERT, J.P.J. & SCHULTZ, R., ANITRA 1982b. The treatment of *Moraea polystachya* (Thunb) Ker-Gawl (cardiac glycoside) poisoning in sheep and cattle with activated charcoal and potassium chloride. *Journal of the South African Veterinary Association*, 53:249–253.
- JOUBERT, J.P.J. & SCHULTZ, R., ANITRA 1982c. The minimal effective dose of activated charcoal in the treatment of sheep poisoned with the cardiac glycoside containing plant *Moraea polystachya* (Thunb) Ker-Gawl. *Journal of the South African Veterinary Association*, 53:265–266.
- KELLERMAN, T.S., COETZER, J.A.W. & NAUDÉ, T.W. 1988. *Plant poisonings and mycotoxicoses of livestock in southern Africa*. Cape Town: Oxford University Press, South Africa.
- KELLERMAN, T.S., NAUDÉ, T.W. & FOURIE, N. 1996. The distribution, diagnosis and estimated economic impact of plant poisonings and mycotoxicoses in South Africa. *Onderstepoort Journal of Veterinary Research*, 63:65–90.
- LALONDE, R.L., DESHPANDE, R., HAMILTON, P.P., MCLEAN, W.M. & GREENWAY, D.C. 1985. Acceleration of digoxin clearance by activated charcoal. *Clinical Pharmacology and Therapeutics*, 37:367–371.
- NAUDÉ, T.W. & SCHULTZ, R., ANITRA 1982. Studies on South African cardiac glycosides. II. Observations on the clinical and haemodynamic effects of cotyledoside. *Onderstepoort Journal of Veterinary Research*, 49:247–254.
- NAUDÉ, T.W., ANDERSON, L.A.P., SCHULTZ, R., ANITRA & KELLERMAN, T.S. 1992. "Krimpsiekte": A chronic paralytic syndrome of small stock caused by cumulative bufadienolide cardiac glycosides. *Proceedings of the Third International Symposium on Poisonous Plants, Logan, Utah. 1989*: 392–396.
- SCHULTZ, R., ANITRA, PRETORIUS, P.J. & TERBLANCHE, M. 1972. An electrographic study of normal sheep using a modified technique. *Onderstepoort Journal of Veterinary Research*, 39:97–106.
- SMITH, G.F., HOBSON, S.R., MEYER, N.L., CHESSELET, R.H., ARCHER, R.H., BURGOYNE, P.M., GLEN, H.F., HERMAN, P.P.J., RETIEF, E., SMITHIES, S.J., VAN JAARSVELD, E.J. & WELMAN, W.G. 1993. Southern African succulent plants—an updated synopsis. *Aloe* 30(2):31–74.
- SOGA, J.F. 1891. Disease "Nenta" in goats. *Agricultural Journal of the Cape of Good Hope*, 3:40–142.
- STEYN, P.S., VAN HEERDEN, F.R., VLEGGAAR, R. & ANDERSON, L.A.P. 1986. Structure elucidation and absolute configuration of the tyledosides, bufadienolide glycosides from *Tylecodon grandiflorus*. *Journal of the Chemical Society. Perkin Transactions I*: 429–435.
- TOELKEN, H.R. 1978. New taxa and new combinations in *Cotyledon* and allied genera. *Bothalia*, 12:377–393.
- TOELKEN, H.R. 1985. Crassulaceae, in *Flora of southern Africa*, edited by O.A. Leistner. Pretoria: Botanical Research Institute, 14:19–35.
- VAHRMEIJER, J. 1981. *Poisonous plants of southern Africa that cause stock losses*. Cape Town: Tafelberg Publishers Limited.
- VAN DER WALT, J.J., VAN ROOYEN, J.M., KELLERMAN, T.S., CARMELIET, E.E. & VERDONCK, F. 1997. Neurospecificity of some phytobufadienolides is not related to differences in Na<sup>+</sup>/K<sup>+</sup>-pump inhibition. *European Journal of Pharmacology*, 329:201–211.