

Popliteal artery entrapment syndrome misdiagnosed as chronic exertional compartment syndrome in a young male athlete: Role of dynamic ultrasound

Zanet Oschman, Elouise Metherell

Department of Sports Medicine, University of Pretoria

Zanet Oschman, MB ChB, MSc Sports Medicine

Elouise Metherell, MB ChB

Corresponding author: Z Oschman (zanet@mweb.co.za)

Abstract

Popliteal artery entrapment syndrome (PAES) is an uncommon cause of exercise-induced pain in the lower extremity of young athletes. However, it might explain the symptoms of those athletes who do not respond to treatment for the more common overuse syndromes. We present a case of a young professional male athlete who was diagnosed with bilateral chronic exertional compartment syndrome (CECS), for which he was operated on twice. His symptoms persisted for 5 years before PAES was diagnosed with dynamic ultrasound, and after bilateral surgical release a few months apart, he was completely symptom-free except for some discomfort in the fasciotomy scars.

S Afr J SM 2012;24(2):65-66.

Case report

A 21-year-old provincial rugby player complained of exercise-induced pain in both his calves in 2007, which had been treated as shin splints, but worsened progressively over the subsequent 2 years. In 2009 he consulted a sports doctor, who measured the intramuscular pressure with a slith catheter (make of catheter unknown) diagnosing bilateral chronic exertional compartment syndrome (CECS) of the anterior compartment. He was referred to an orthopaedic surgeon who did a fasciotomy of the anterior compartments. After 6 months of rehabilitation he started playing rugby again, but the pain and discomfort in his calves became so severe that he was unable to walk after a match. In 2010 he saw another orthopaedic surgeon who consulted with the surgeon who had done the previous fasciotomy; they decided that he should also do a fasciotomy of the lateral and deep posterior compartments. In 2011 he tried to play again, but again had to stop because of the severe pain in his calves. He consulted another sports doctor who referred him for a dynamic ultrasound examination. The examination was conducted by a sports doctor (>10 years' experience in musculoskeletal ultrasound) on a Toshiba ultrasound machine equipped with a 5 - 7.5 MHz linear-array transducer. Popliteal artery entrapment syndrome (PAES) was diagnosed with dynamic duplex Doppler ultrasonography. Fortunately no arterial damage was present and after bilateral surgical release a few months apart he was symptom-free, except for some discomfort in the fasciotomy scars.

PAES is a relatively underdiagnosed cause of exercise-induced lower limb claudication. The syndrome usually affects young athletes who undertake vigorous exercise leading to muscle hypertrophy of the calf muscles which unmasks the occult disorder.¹

Discussion

PAES was first described by a medical student Anderson Stuart in 1879. However, the term PAES was established by Love and Whelan in 1965. PAES is a partial or complete occlusion of the popliteal artery as a result of aberrant anatomy in the popliteal fossa.² The syndrome usually affects males younger than 30 years of age, with a male to female ratio of 15:1. Bilateral involvement has been reported in up to 67% of cases.^{1,2}

Vascular causes of exercise-induced pain can be difficult to exclude from the more common overuse syndromes, such as CECS, medial tibial stress syndrome, shin splints and stress fractures. Vascular causes include PAES, endofibrosis (intimal hyperplasia), kinking or stenosis of the iliac artery and cystic adventitious disease.³ The differential diagnoses should also include muscle rupture, tendinopathy, effort-induced venous thrombosis, nerve impingements and fascial defects.¹

A classification of popliteal vessel entrapment has been described. There are essentially four types of anatomical anomalies causing PAES (types I - IV). Type V includes any of the anatomical variants in types I - IV but also involves the popliteal vein. Type VI is a functional PAES caused by hypertrophied muscle.⁴

Entrapment may also occur in the absence of any anatomical abnormality. Functional popliteal entrapment refers to neuromuscular claudication with lower extremity paraesthesias due to repetitive overuse or injury that causes neuromuscular irritation. These patients are younger than 24 years, mostly female, and their resting and post-exercise non-invasive tests are normal. This type of entrapment occurs in the same population at risk of chronic compartment syndrome.⁵ Classic presentation of PAES is recurrent exercise-induced pain that usually occurs at a predictable distance or activity intensity which prevents further activity. Pain relief occurs with cessation of activity.³ Leg weakness, paraesthesias, transient tingling and coldness of the foot may also be present. If the diagnosis is delayed, irreversible arterial damage that can impair viability of the affected limb may occur.¹ It is also common for CECS to coexist with PAES, but with CECS on its own the distal pulses remain normal.^{2,3}

The physical examination may be completely normal if certain provocative manoeuvres and exercise are not included. To elicit a

pulse deficit the knee is hyperextended and the foot placed in forced plantar flexion. Pulse loss during these manoeuvres is considered pathognomonic although pulse reduction can occur in individuals without any abnormalities.¹

Non-invasive duplex Doppler ultrasonography allows dynamic visualisation of the popliteal artery, and during the manoeuvres described above can help establish the diagnosis. Normally the flow in the distal tibialis posterior artery and dorsalis pedis artery is high-resistance triphasic flow (Fig.1); during forced plantar flexion the flow becomes very weak or disappears – with release of the forced plantar flexion the flow changes to low-resistance monophasic flow (Fig.2). At present magnetic resonance imaging or magnetic resonance angiography remains the diagnostic method of choice. Treatment of PAES typically involves surgical correction of the vascular anomaly; if there is damage to the popliteal artery, constructive surgery is needed.¹

In conclusion, this case serves as a reminder that young athletes can develop PAES, an uncommon cause of exercise-induced

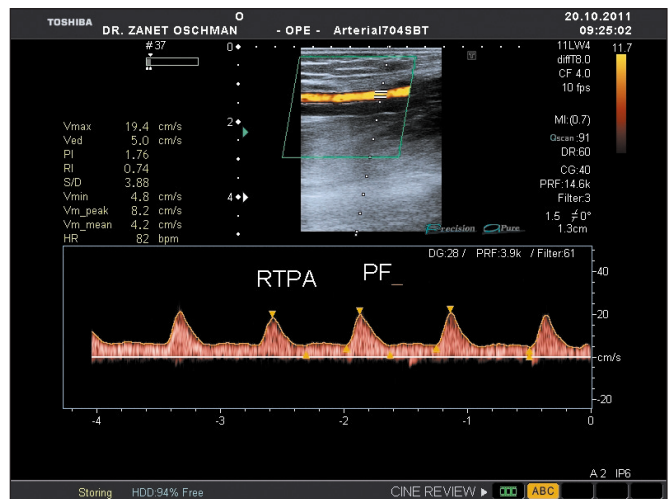


Fig 2. Post forced plantar flexion, low-resistance monophasic flow.

claudication in the lower extremity. It is important to have a broad knowledge and a clear understanding of the common overuse causes and the less common vascular causes of exercise-induced pain in the lower leg to improve care of young competitive athletes.

REFERENCES

1. Roche-Nagle G, Wong KT, Oreopoulos G. Vascular claudication in a young patient: popliteal entrapment syndrome. *Hong Kong Med J* 2009;15:388-390.
2. Hershman EB, Tauliopoulos S. Lower leg pain – diagnoses and treatment of compartment syndromes and other pain syndromes of the leg. *Sports Med* 1999;27(3):193-204.
3. Pham TT, Kapur R, Harwood MI. Exertional leg pain: Teasing out arterial entrapments. *Current Sports Medicine Reports* 2007;6(6):371-375.
4. Pillai J. A current interpretation of popliteal vascular entrapment. *J Vasc Surg* 2008;48(6 Suppl):61-65.
5. Turnipseed WD. Popliteal entrapment syndrome. *J Vasc Surg* 2002;35:910-915.

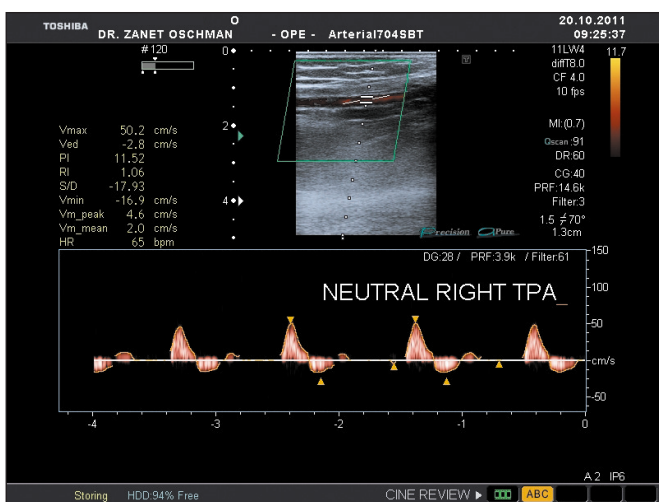


Fig. 1. Normal high-resistance triphasic flow.TPA = tibialis posterior artery.