

Paranasal sinus variants

Zaeem I Ebrahim, MB BCH

Zarina I Lockhat, FFRad (D) (SA)

Department of Radiology, University of Pretoria

Corresponding author: Z Ebrahim (zaeem@iafrica.com)

Abstract

Normal variations of the the paranasal sinuses tend to be overlooked but can have pathological consequences, making identification important.

Introduction

The paranasal sinuses have many variations of their normal anatomy. The variants are usually revealed as incidental findings that are overlooked. The aetiology is congenital or developmental. Although the variations are normal, they can have pathological consequences, therefore making identification important.

This pictorial essay was created from the records of patients attending Kalafong Hospital's CT scanning department. The patients presented with pathology not related to the paranasal sinuses.

Agger nasi cells

The agger nasi cells (Latin for 'nasal mound') are the most anterior ethmoid cells. They are extramural cells (not confined within the ethmoid bone) and extend anteriorly into the lacrimal bone. They are anterior to the anterior attachment of the middle turbinate to the skull base. Viewed in the sagittal plane, they are located anteriorly and inferiorly to the frontal recess. On coronal CT, they appear as inferior to the frontal recess and lateral to the middle turbinate (Figs 1 and 2).

The bulla ethmoidalis is a prominent anterior ethmoid air cell (Fig. 3). A degree of pneumatisation may vary, and failure to pneumatise is termed torus ethmoidalis.

Haller cells are located below the bulla ethmoidalis and extend beneath the floor of the orbit (Figs 4 and 5).

The intersphenoid septum is often deflected to one side, attaching to the bony wall covering the carotid artery (Fig. 6). This artery can be injured if the septum is avulsed during surgery.

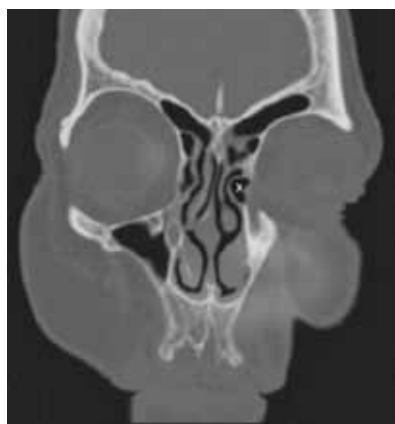

Fig. 1. Agger nasi – left (X).

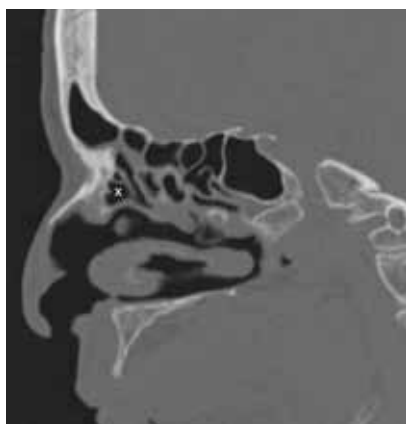

Fig. 2. Agger nasi – sagittal (X).

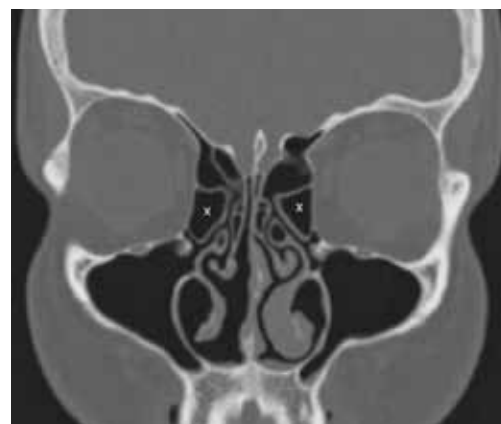

Fig. 3. Bilateral bulla ethmoidalis (X)

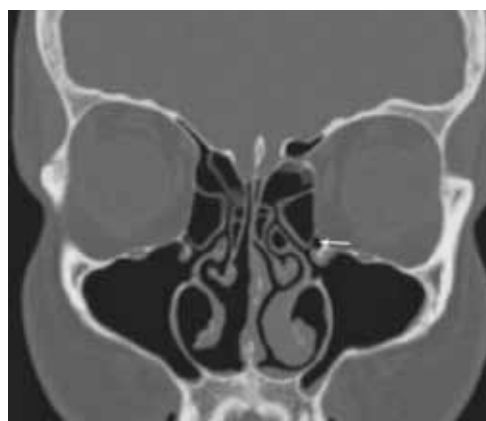

Fig. 4. Haller cells – left (arrow).

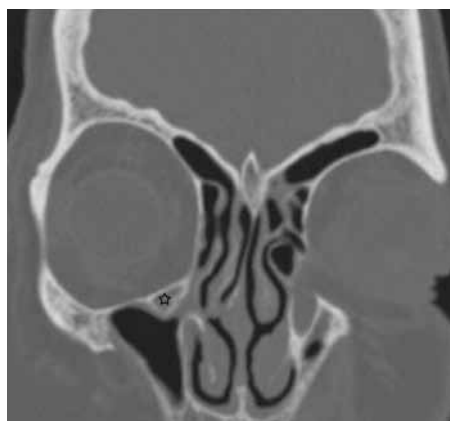


Fig. 5. Haller cells – right (star).

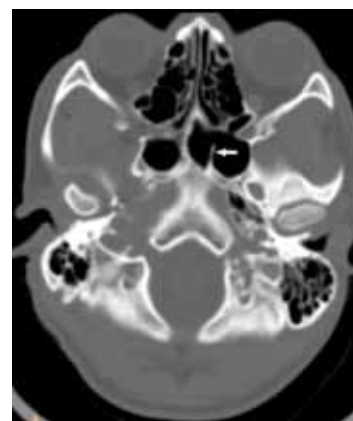


Fig. 6. Intersphenoid septum (arrow).

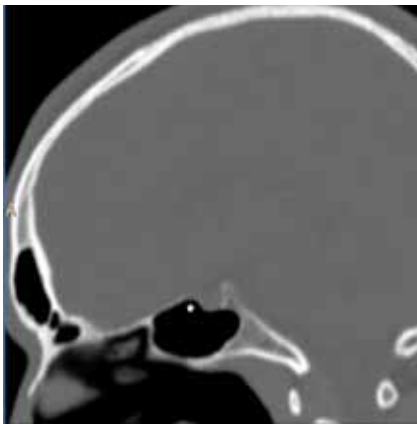


Fig. 7. Pneumatized anterior clinoid process (star).

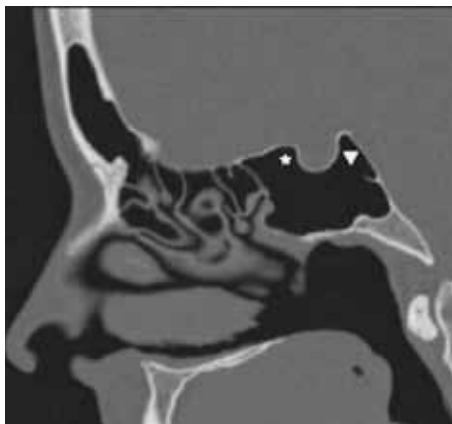


Fig. 8. Pneumatized clinoid processes (star – anterior; triangle – posterior).

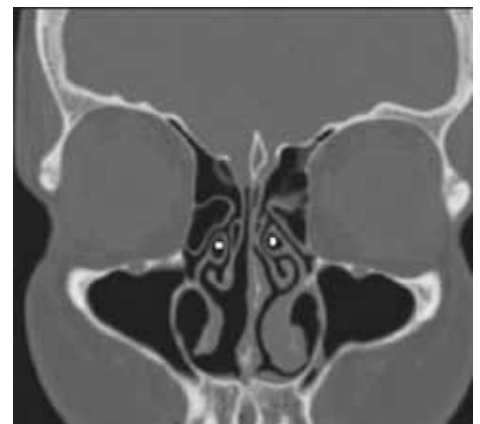

Fig. 9. Pneumatized uncinate processes, bilaterally (dots).

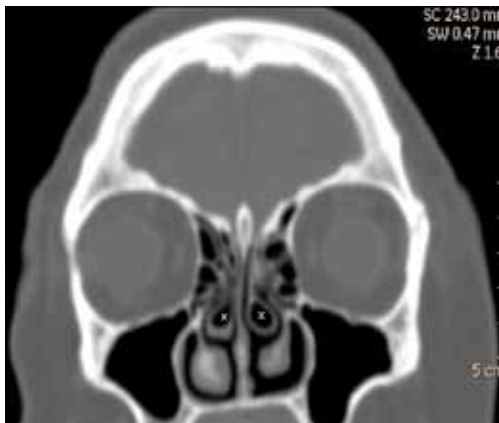

Fig. 10. Bilateral concha bullosa (X).

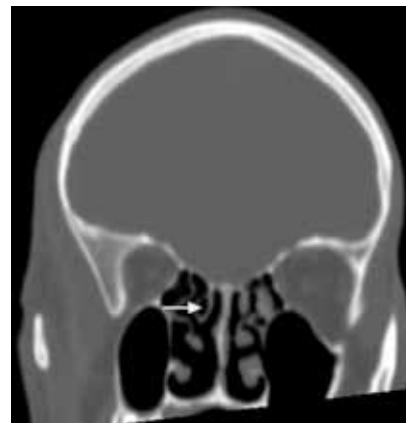

Fig. 11. Pneumatized superior nasal turbinate (arrow).

Pneumatization of the uncinate process may be encountered in up to 4% of the population (Fig. 9).

A concha bullosa is a pneumatized middle turbinate and has a reported prevalence of 34%. Concha bullosa is readily identified on CT (Fig. 10).

1. Dahnert W. Radiology Review Manual. 5th ed. Philadelphia, USA: Lippincott Williams and Wilkins, 2003.
2. Chong VFH, Fan YF, Sethi DS. Pictorial review functional endoscopic sinus surgery (FESS). Clinical Radiology 1998; 53(9):650-658.
3. Weissleder R, Wittenberg J, Mukesh GH, et al. Primer of Diagnostic Imaging. Philadelphia, USA: Mosby Elsevier, 2011.