



UNIVERSITY OF LEEDS

This is a repository copy of *Myositis in the Head and Neck: Challenges in Diagnosis and Management*.

White Rose Research Online URL for this paper:  
<http://eprints.whiterose.ac.uk/115250/>

Version: Accepted Version

---

**Article:**

Ratansi, R, Fabbroni, G and Kanatas, A [orcid.org/0000-0003-2025-748X](https://orcid.org/0000-0003-2025-748X) (2017) Myositis in the Head and Neck: Challenges in Diagnosis and Management. *British Journal of Oral and Maxillofacial Surgery*, 55 (7). pp. 722-723. ISSN 0266-4356

<https://doi.org/10.1016/j.bjoms.2017.05.018>

---

© 2017 The British Association of Oral and Maxillofacial Surgeons. Published by Elsevier Ltd. All rights reserved. Licensed under the Creative Commons Attribution-NonCommercial-NoDerivatives 4.0 International  
<http://creativecommons.org/licenses/by-nc-nd/4.0/>

**Reuse**

Items deposited in White Rose Research Online are protected by copyright, with all rights reserved unless indicated otherwise. They may be downloaded and/or printed for private study, or other acts as permitted by national copyright laws. The publisher or other rights holders may allow further reproduction and re-use of the full text version. This is indicated by the licence information on the White Rose Research Online record for the item.

**Takedown**

If you consider content in White Rose Research Online to be in breach of UK law, please notify us by emailing [eprints@whiterose.ac.uk](mailto:eprints@whiterose.ac.uk) including the URL of the record and the reason for the withdrawal request.



[eprints@whiterose.ac.uk](mailto:eprints@whiterose.ac.uk)  
<https://eprints.whiterose.ac.uk/>

## **Myositis in The Head and Neck Area - Challenges in The Diagnosis and Management**

**R Ratansi<sup>1</sup>, G Fabbroni<sup>2</sup>, and A Kanatas<sup>3</sup>**

1. Reshma Ratansi, BDS (Hons). Dental Core Trainee, Leeds Teaching Hospitals
2. Gillon Fabbroni, FRCS. Consultant, Leeds Teaching Hospitals
3. Anastasios Kanatas, FRCS. Consultant, Leeds Teaching Hospitals, Leeds Dental Institute.

### **Address for correspondence:**

Anastasios Kanatas

Consultant Head and Neck Surgeon / Honorary Professor University of Leeds

BSc (Hons), BDS, MBChB (Hons), MFDSRCS, MRCSRCS, FRCS (Max Fac), PhD, MD, PGC

Leeds Teaching Hospitals NHS Trust, St James's Institute of Oncology, Great George St, Leeds

LS1 3EX

Tel: 0113 243 2799

email: a.kanatas@doctors.org.uk

**Key words: Myositis, base of skull, head and neck**

## **Abstract**

Myositis in the head and neck area may be difficult to diagnose. It may be presented with non-specific symptoms and radiographically may mimic malignancy. Often a multidisciplinary team management is essential. Here we discuss the challenges and we aim to raise the awareness of this condition.

## **Introduction**

Focal inflammatory myositis is muscle inflammation that targets a focal muscle group, aetiology unknown, generally presenting as pseudotumour with localised pain(1) and a rapidly enlarging neck mass(2), more commonly affecting skeletal muscles. Clinical and imaging presentations both can lead to incorrect diagnoses, particularly mimicking malignancy(3). The condition is rare, particularly in the head and neck region, and fine-needle aspiration/radiology can often lead to unilateral neck masses being differentially diagnosed as infection or neoplasia. (2)

## **Case presentation**

A 41-year-old female, presented to a local general dental practitioner (GDP) complaining of pain, swelling on the right temporal area and trismus, unresolving with extraction of a carious upper right wisdom tooth. With a history of recent jaw locking as well as a previous jaw click, and ear crackling sensations, temporomandibular joint (TMJ) dysfunction pain was diagnosed. However conservative management, that included TMJ steroid injections failed to resolve the symptoms. Subsequently she developed epistaxis and double vision. Imaging demonstrated an infiltrating lesion in the right temporal region, leading to differential diagnoses of infection or malignancy. From the results of the cone-beam CT, an MRI indicated a plaque-like tissue at the right orbit floor and a defect at the right orbital wall (Figure 1). A CT scan was requested, which displayed a right infra-temporal and a right maxillary antral soft tissue lesion (Figure 2). Additionally, a full body PET scan showed low grade uptake in the right infratemporal fossa and masticator spaces. Hematological tests returned with a raised acute phase response, a raised ESR, neutrophilia, increased IgM, and negative results for ANA, ANCA and rheumatoid factor. Temporal muscle tissue cultures showed no growth. A tru-cut biopsy revealed only inflammatory tissue, and from here, the investigation progressed to open tissue biopsy, which confirmed an inflammatory infiltrate of lymphocytes and macrophages, degeneration and muscle fibre necrosis. An endoscopic infratemporal biopsy resulted only in an inflamed maxillary antral lining. A temporal and the core biopsy showed striated degenerating muscle changes and no evidence of neoplasia.

During the time taken to achieve a diagnosis, the developed pterygoid muscle contraction and visual symptoms - blurring, inflammatory cells in the vitreous of her eyes, macular oedema, and inflammatory bilateral retinal vasculitis of the veins evident from fluorescein angiography. Her rheumatology report was one of an infiltrative mass related to a pseudotumour.

## **Discussion**

Focal myositis is a benign condition, but a thorough tissue diagnosis is required for active inflammatory processes before any treatment was commenced (4). It presents as a localised, painful enlargement of tissue, hinting at malignant causes, but without associated systemic symptoms(1). Misdiagnosis can lead to wrong treatment, which can be harmful to the patient, so an exhaustion of resources to get a correct diagnosis is imperative. Generally oral corticosteroids are good for treatment, however chronic cases benefit from immunosuppression/radiotherapy(5). In this case, steroid treatment started with initially intravenous (IV) methylprednisolone, 30mg prednisolone, and six pulses of IV cyclophosphamide. Our patient has been symptom free for the last six months although radiographically there is no change. Immunosuppressants, with all their risks, are beneficial to those with myositis where they may not be with other myopathies(6).

Masticatory muscle myositis, is uncommon. Circulating antibodies target muscles of mastication, and patients often present with jaw pain (7). Histopathological overlap and inflammatory biochemical findings are not uncommon with myositis (4). A multidisciplinary team is required to diagnose and manage these cases holistically - maxillofacial surgery, ENT, ophthalmology and rheumatology. Inflammatory myopathies are rare, and poorly understood (8), and management with steroid therapy can produce side effects of steroid-induced myopathy that mimic relapse (5).

The author would urge any practitioner faced with unilateral, radiographically infiltrative, pathology (9), to consider myositis as a cause after confirming the absence of malignancy.

**Conflict of interest:** The authors have no conflict of interest to report.

## **REFERENCES**

- (1) Teixeira F, Peixoto D, Costa J, Bogas M, Taipa R, MeloPires M, et al. Recurrent Focal Myositis: a rare inflammatory myopathy. Acta reumatologica portuguesa 2014 Apr-Jun;39 (2):172-173, 174, 175.
- (2) Tan CY, Chong S, Shaw CL. Core biopsy as a simple and effective diagnostic tool in head and neck focal myositis. Ear Nose Throat J 2015 Dec;94(12): E10-3.
- (3) Bennett O, Ravi Kumar AS, Agnew J. Focal Inflammatory Myositis on 18F-FDG PET/CT. Clin Nucl Med 2016 Jun;41(6):469-471.
- (4) Nirmalanathan N, Holton JL, Hanna MG. Is it really myositis? A consideration of the differential diagnosis. Curr Opin Rheumatol 2004 Nov;16(6):684-691.
- (5) Carstens PO, Schmidt J. Diagnosis, pathogenesis and treatment of myositis: recent advances. Clin Exp Immunol 2014 Mar;175(3):349-358.
- (6) Michelle EH, Mammen AL. Myositis Mimics. Curr Rheumatol Rep 2015 Oct;17(10):63-015-0541-0.
- (7) Melmed C, Shelton G, Bergman R, Barton C. Masticatory Muscle Myositis: Pathogenesis, diagnosis, and treatment. Compendium on Continuing Education for the Practising Veterinarian - North American Edition 2004 Aug;26(8):590-591,592, 593, 594, 595, 596, 597, 598, 599,600, 601, 602, 603, 604, 605.
- (8) Ngo LQ, Wu AG, Nguyen MA, McPherson LE, Gertner E. A case report of autoimmune necrotizing myositis presenting as dysphagia and neck swelling. BMC Ear Nose Throat Disord 2016; 16:7.
- (9) Naumann M, Toyka KV, Goebel HH, Hofmann E, Reichmann H. Focal myositis of the temporal muscle. Muscle Nerve 1993 Dec;16(12):1374-1376.

*Figure 1: MRI (Coronal view) scan of the right temporal region*

*Figure 2: MRI (Sagittal view) scan indicating the lesion*

Figure 1.

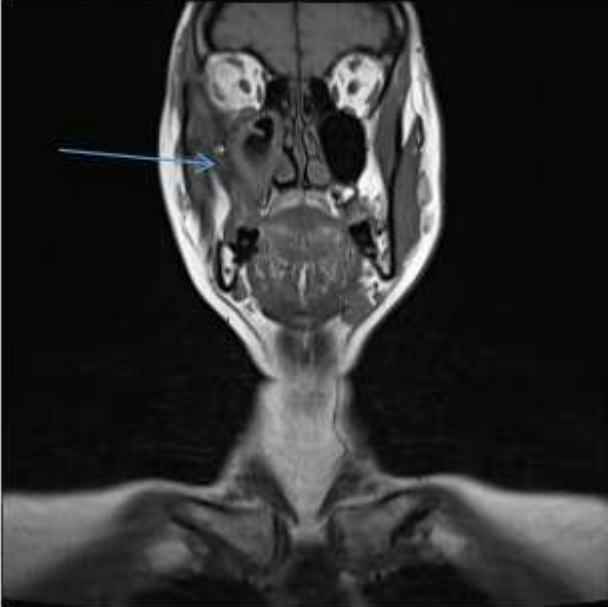


Figure 2.

