

DOI: 10.5455/msm.2016.28.66-70

Received: 18 October 2015; Accepted: 25 December 2015

© 2016 Andon Chibishev, Velo Markoski, Ivica Smokovski, Emilija Shikole, Aleksandra Stevcevska

This is an Open Access article distributed under the terms of the Creative Commons Attribution Non-Commercial License (<http://creativecommons.org/licenses/by-nc/4.0/>) which permits unrestricted non-commercial use, distribution, and reproduction in any medium, provided the original work is properly cited.

## PROFESSIONAL PAPER

Mater Sociomed. 2016 Feb; 28(1): 66-70

# NUTRITIONAL THERAPY IN THE TREATMENT OF ACUTE CORROSIVE INTOXICATION IN ADULTS

Andon Chibishev<sup>1</sup>, Velo Markoski<sup>2</sup>, Ivica Smokovski<sup>1</sup>, Emilija Shikole<sup>3</sup>, Aleksandra Stevcevska<sup>1</sup><sup>1</sup>University Clinic for Toxicology and Urgent Internal Medicine, Skopje, Republic of Macedonia<sup>2</sup>University "Goce Delcev", Medical faculty, Shtip, Republic of Macedonia<sup>3</sup>Institute for Preclinical Pharmacology and Toxicology, Skopje, Republic of MacedoniaCorresponding author: Prof. Andon Chibishev, MD, PhD. E-mail: [toksikourgentna@gmail.com](mailto:toksikourgentna@gmail.com)**ABSTRACT**

**Introduction:** Acute intoxications with corrosive substances can cause severe chemical injuries of the upper gastrointestinal tract, most often located in the mouth, pharynx, esophagus, stomach and duodenum. If a patient survives the acute phase of intoxication, regenerative response may result in esophageal and/or gastric stenosis, and increased risk of esophageal and gastric cancer. Such intoxication may be fatal due to perforation or tracheal necrosis. Enteral nutrition is a nutritional method when nutritional substances are administered through specially designed tubing placed through the nose or percutaneously, directly into the GIT. **Aim:** The aim of this study is to describe the methods of artificial nutrition in patients with acute corrosive intoxications and the importance of nutritional support in the treatment of these intoxications. **Discussion:** Nutrition in the treatment of acute corrosive intoxications is one of the most important therapeutic processes that largely contribute to faster recovery of the post-corrosive injuries of upper GIT, stabilization of biologic, immunologic and metabolic parameters, and reduction of length of stay in hospital. Aim of the treatment of acute corrosive intoxications is to prevent perforation and progressive fibrosis, and esophageal and gastric stenosis. There are different and often conflicting positions, on the conservative treatment of acute corrosive intoxications in adults. Such treatment mainly consists of anti-secretory treatment, antibiotics and intensive hyper-alimentation, aiming to prevent late post-corrosive intoxications. **Conclusion:** It is considered that nutritional support plays a major role in maintenance of metabolic processes and prevention of severe metabolic complications that could additionally aggravate the condition and impair the treatment.

**Key words:** corrosive poisonings, deglutition, deglutition disorders, nutritional therapy, enteral nutrition, parenteral nutrition

## 1. INTRODUCTION

Acute intoxications with corrosive substances can cause severe chemical injuries of the upper gastrointestinal tract, most often located in the mouth, pharynx, esophagus, stomach and duodenum. If a patient survives the acute phase of intoxication, regenerative response may result in esophageal and/or gastric stenosis, and increased risk of esophageal and gastric cancer. Such intoxication may be fatal due to perforation or tracheal necrosis. Unlike pediatric population where corrosive intoxications are most often accidental, corrosive intoxications in adult patients are intentional or suicidal in more than 90% of the cases (1-3). Severity of the resulting chemical injuries depend on several factors: nature of the corrosive substance, quantity, concentration, duration of exposition, swallowing, food presence, gastroesophageal reflux, or various previous pathological conditions of the upper gastrointestinal tract (4). Post-corrosive injuries can be reversible and irreversible. Injured mucosa, submucosa and muscular layer are regenerating poorly due to the sur-

rounding inflammation, necrosis and secondary complications. Resulting fibrosis and adhesions or circular stenosis greatly impair the upper gastrointestinal function such as impaired peristaltic and passage. Latter leads to further deterioration of patient's general condition, inability for physiologic nutrition, weight loss, prostration and cachexia. Such development can result in fatal outcome due to inadequate nutrition, i.e. inability for normal feeding caused by complications (5). Severe GIT injuries prevent normal nutrition of patients. Patients are in poor general condition, characterized by hypercatabolic state and negative nitrogen balance. Therefore, early nutritional support is of great importance for the treatment and outcome of these patients. Effects of the nutrition substitution in patients with life-threatening disorders, including the reduction of infection risk, aspiration pneumonia or pulmonary embolism, as well as stimulation and facilitated healing of injuries, are main reasons for use of artificial nutritional support in patients with acute corrosive intoxications (6, 7).

## 2. AIM OF THE STUDY

Aim of this study is to describe the methods of artificial nutrition in patients with acute corrosive intoxications and the importance of nutritional support in the treatment of these intoxications. Therapeutic management of acute

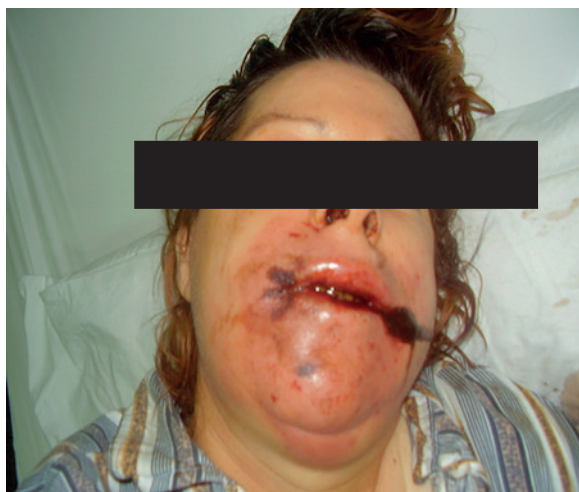

Figure 1. Patient with severe corrosive intoxication (extensive local injuries)

corrosive intoxications includes symptomatic treatment and nutritional support. These patients require intensive hyperalimentation in the first 20 days during the healing of post-corrosive stenosis, that can continue for the next 2-4 months if post-corrosive stenosis develops. Such nutritional requirement persists and might impair patient's well-being, causing difficulties for treating physician until conditions are met for surgical intervention of the stenosis that impairs physiologic nutrition (8, 9). Nutritional support in corrosive intoxications until recently was based on total parenteral nutrition.

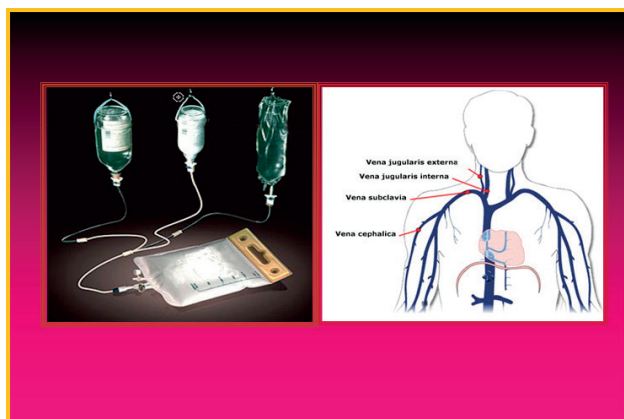


Figure 2. Presentation of veins for administration of nutritional solutions

Due to the resulting complications, expensive nutritional solutions and invasive investigational procedures, enteral nutrition through nasoenteral tubes and enterostoma is the preferred nutritional method in the last 10 years.

Parenteral nutrition is administered in 2 ways: a) peripheral vein and b) Central vein. During the administration in peripheral vein, most commonly used are the cubital veins, and the administration should last no longer than 7-10 days (Figure 2). During the application in the central vein, most commonly used are subclavian veins and the administra-

tion could last longer than 30 days (10).

Parenteral application of nutritional solutions is followed by complications that may impair the nutrition of patients and may cause difficulties for the treating physician in the planning and implementation of the nutritional support. Most frequent complications are: complications related to the central or peripheral venous catheter, infections, metabolic complications, disturbance of acid-base balance.

As a result of the numerous complications and the associated considerable financial costs, parenteral access of nutritional substances is substituted by the enteral administration due to its simplicity, safety and lower associated costs (11). Enteral nutrition is a nutritional method when nutritional substances are administered through specially designed tubing placed through the nose or percutaneously, directly into the GIT. Contemporary definition of enteral nutrition includes all forms of nutritional support requiring use of nutrition for specific medical aims, as defined in the European legal regulation from 25 March 1999. According to the latest consensually accepted findings, enteral nutrition is a sophisticated nutritional support regimen, practiced and implemented by professional in trained nutritional teams (12).

Indications for enteral nutrition are related to all conditions when the ingestion of adequate nutrients with functional GIT, is not possible (Figure 3).

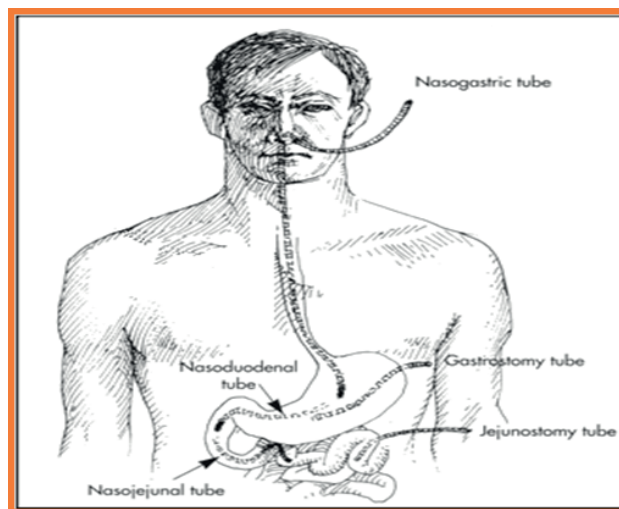


Figure 3. Presentation of potential sites for enteral nutrition

Main indications for enteral nutrition are:

Poor nutritional status, malnutrition, anorexia, chemical injuries of the upper GIT, short-bowel syndrome, inflammatory bowel diseases, prolonged diarrhea, chronic hepatic diseases, encephalopathy, dysphagia of various etiology, CNS tumors, patient receiving chemotherapy, patients with burns, nutritional support in patients in terminal conditions.

Absolute contraindications for enteral nutrition, as well as parenteral nutrition, are: shock of any etiology, serum lactates higher than 3-4 mmol/L, hypoxia ( $\text{PaO}_2 < 50 \text{ mmHg}$ ), ethical reasons. Absolute contraindications for enteral nutrition, when parenteral nutrition is not possible, are: intestinal ischemia, acute abdomen, intestinal perforation, acute GIT bleeding, mechanical obstruction (13).

Extensive injuries of GIT prevent physiologic nutrition in patients with acute corrosive intoxications. Nutrition

provides life-sustaining treatment for such patients, who are at risk of malnutrition (14). Nutrition in the treatment of acute corrosive intoxications is one of the most important therapeutic processes that largely contribute to faster recovery of the post-corrosive injuries of upper GIT, stabilization of biologic, immunologic and metabolic parameters, and reduction of length of stay in hospital (15). The type of artificial nutritional support depends on the endoscopic stage of esophageal or gastric injury (16). Classification of post-corrosive injuries in our patients is based on the 5-stage of Kikendal classification (Table 1) (17).

Stage I	mucosal edema and erythema
Stage II A	hemorrhage, erosions, superficial ulcerations
Stage II B	circumferential lesions
Stage III	deep gray or brown-black ulcers
Stage IV	perforation

Table 1. Kikendal classification

In patients with Stage I according to Kikendal classification, total parenteral nutrition (TPN) is used until urgent esophagogastroduodenoscopy is performed. By taking precise medical history and hetero-anamnesis, information is received if the patient used any other chemical substance or medicine. After consultation with psychiatrist, that is mandatory in our protocol, nutrition is liberalized and the patient is discharged.

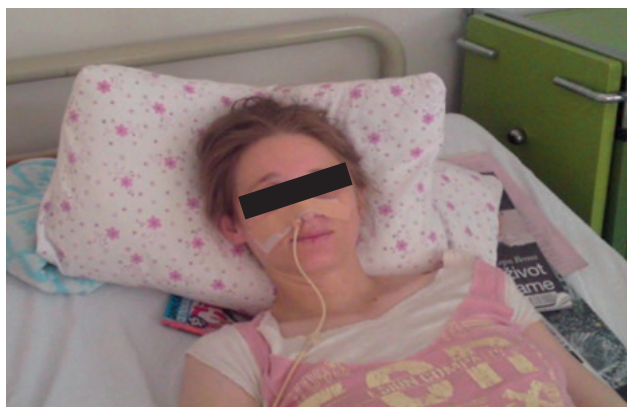

Figure 4. Patient with naso-jejunal tubing for artificial nutrition

In patients with Stage II A, total parenteral nutrition is used for the first 24-48 hours, followed by liquid diet until day 10. Same procedure is performed in these patients as in patients with Stage I, including consultation with psychiatrist. Nutrition can be liberalized thereafter (18).

In patients with Stage II and III, it is recommended not to take food through mouth, or 'esophageal rest' (NPO – Nill per os) (Figures 5, 6). During the 'rest', patient is fed enterally with nasogastric or naso-ental tubing, gastrostoma or jejunostoma, and parenterally through peripheral or central vein (Figure 7, 8) (19). Extensive esophageal and gastric injuries lead to additional injuries due to the food particles penetrating in granulocytes of the esophageal and gastric wall, thus worsening the inflammation. Such processes in the esophageal and gastric wall continue for several days, and precede a bacterial invasion, inflammatory response and development of granulomatous tissue. All above result in special emphasis on the feeding, where the patient will not receive anything through mouth for 10-15 days and will

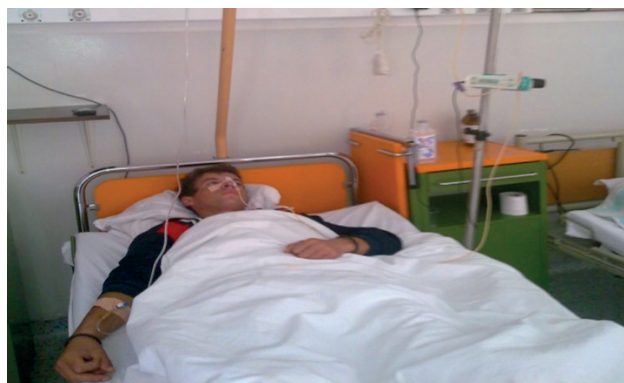

Figure 5. Patient with naso-jejunal tubing and use of solution for enteral nutrition

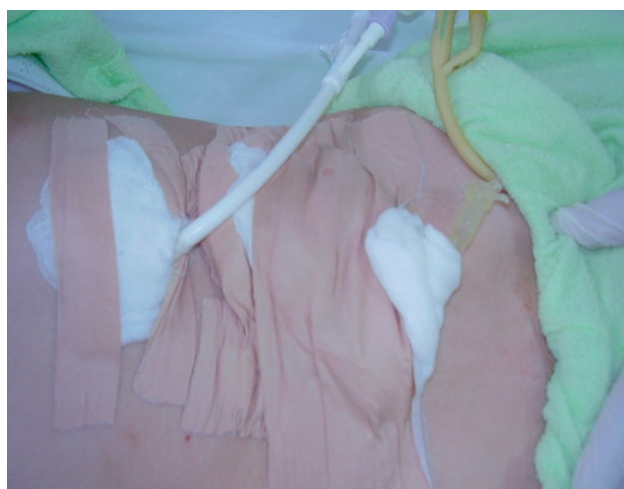


Figure 6. Patient with gastro-jejuno-stoma

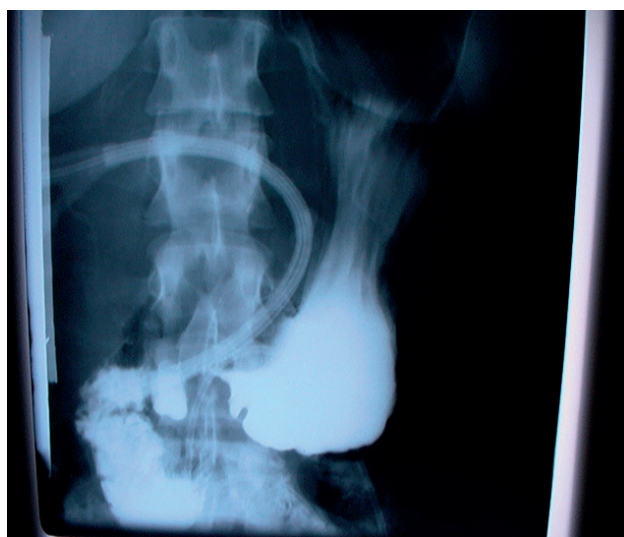

Figure 7. X-ray of gastro-jejuno-stoma

enable the esophageal and gastric mucosa to regenerate faster without additional trauma (20,21).

### 3. DISCUSSION

Aim of the treatment of acute corrosive intoxications is to prevent perforation and progressive fibrosis, and esophageal and gastric stenosis. There are different, and often conflicting positions, on the conservative treatment of acute corrosive intoxications in adults. Such treatment mainly consists of anti-secretory treatment, antibiotics and intensive



hyper-alimentation, aiming to prevent late post-corrosive intoxications (22, 23). It is considered that nutritional support plays a major role in maintenance of metabolic processes and prevention of severe metabolic complications that could additionally aggravate the condition and impair the treatment.

Nutritional support has been one of the most controversial procedures in modern medicine for a very long time. Twenty years ago, Koretz commented on the nutritional support that there are no sufficient evidence-based medical information to conclude on the indications and the need of nutritional support. However, in the past period, position has changed completely, and currently, there is a strong evidence confirming that malnutrition is independent risk factor for higher morbidity, lower quality of life, longer hospital stay, delayed recovery time, higher hospital costs and higher mortality (24).

A consensus was reached in 2006 in all areas where clinical nutrition is practiced, respecting the individual specificities and characteristics of the medical areas where the enteral support is applied. Consensus was reached on all specific and disputed issues, stating that inappropriate nutrition in critically ill patients leads to higher morbidity, longer hospital stay, delayed recovery, lower quality of life, higher hospital costs and higher mortality (25).

In critically ill patients complications increase 4-fold, and mortality 6-fold if the albumin level is below 35 g/L (26).

Artificial nutritional support dates from 1850 year when a gastro-stoma for nutritional support was implanted for the first time in a child with severe esophageal injuries caused by caustic. Actually, discussing the nutrition in acute corrosive intoxications, debates are still ongoing on the most adequate type of artificial support before physiologic feeding per mouth is initiated. DiConstanzo followed the patients who suffered acute corrosive intoxications with serious post-corrosive esophageal and gastric complications. He suggested use of intensive hyper-alimentation in the first 7 days after intoxication and did not recommend feeding through mouth during the treatment, as it might lead to additional worsening of the patient's condition (27).

Some authors consider that patients with Stage II B and III should have 'esophageal rest', i.e. are not allowed to have any food by mouth (NPO—nil per os). Patients are fed enterally through special naso-enteral tubing or entero-stoma, or parenterally through peripheral or central vein.

Esophageal rest can last up to day 10 after ingestion or, according to some authors, up to day 15, until the first endoscopic follow-up. Other authors recommend introduction of liquids 48 hours after ingestion if the patient can swallow its own saliva (28,29). Our position is that NPO should last 10-12 days after the ingestion, and the patient should be on liquid diet until day 21. Nutritional care is fundamental component of the clinical treatment and care. Optimized quality of life should be the primary aim in patients on any form of nutritional support and care. This could only be achieved by the use of most suitable practice and adaptation of integrated and multi-profession approach towards nutritional support. It will be more successful if the hospital care is part of the development healthcare strategy (30).

The still open issue of most optimal nutritional support in acute corrosive intoxications led to different positions on

the advantages and disadvantages of parenteral or enteral nutrition.

Some authors consider that optimal approach and treatment of critically ill patients is fast and early enteral nutrition over parenteral nutrition with no nutritional support. Enteral nutrition results in reduction of initial morbidity and reduces the length of stay in hospital. Controversy exists whether a pre-pyloric or post-pyloric nutritional support should be deployed. Inserting of nasogastric tubings is easier than inserting of naso-jejunal tubings. Unlike the nasogastric tubings that demonstrate physiologic benefits, post-pyloric nutrition is associated with less frequent discontinuation, more rapid achievement of caloric benefit, and reduction of risk for gastro-esophageal reflux and obstipation. Difference between the two types of nutritional support is minimal and the choice is based on the experience and adoption of the risk and tolerance protocols (31).

There are positions that TPN should be initiated immediately after the endoscopic verification of intoxication and should last until day 15, i.e. until the first endoscopic follow-up, when the enteral nutritional support through naso-enteral tubing should be started lasting until day 31, before the oral feeding or other form of enteral nutrition (gastro-stoma or jejuno-stoma) is in place. According to other authors, in patients with Stage IIB and III of post-corrosive injury of upper GIT, a naso-enteral tubing for nutritional support should be placed in the first 24 hours, and first small quantities of liquids should be inserted in the first 48 hours. American Association of Critically Ill Patients adopted an algorithm for the treatment of acute corrosive intoxications, recommending nutrition through naso-enteral tubing, gastro-stoma and/or jejuno-stoma, additional to the other treatment (32-34). Numerous studies from various authors in the treatment of acute corrosive intoxications recommend enteral nutrition through tubings or entero-stomae. Rationale for such approach is based on the reduction of complications, improvement of patient well-being, easier adjustment of the patient in home conditions (home enteral nutrition) and reduction of hospital costs. General recommendation include installment of gastro-stomae or jejuno-stomae that will enable continuous and quality nutrition for a longer period, maintenance of metabolic-electrolyte balance and stable nutritional status (35-38).

Despite the fact that nutritional treatment in acute corrosive intoxications has a major role in the treatment, there is a relatively small number of relevant investigations focused on this issue. European Society of Enteral and Parenteral Nutrition (ESPEN) publishes consensus on the use of enteral nutrition, including the indications for the use of enteral nutrition. These conclusions can also be used in the treatment of patients with corrosive intoxications.

In the recent years, several investigations were performed in large groups of patients on the use of enteral nutrition through naso-enteral tubings or entero-stomae, more frequently jejuno-stomae, despite parenteral nutrition, in acute corrosive intoxications. Favorable results are reported in the maintenance of body weight in the patients, electrolyte, metabolic and nitrogen balance. Maintenance of these parameters in physiologic limits has a major importance in the treatment of critically ill patients and their stabilization.

Improved results are reported related to patient comorbidities, late post-corrosive complications and possibility of home treatment (39, 40).

#### 4. CONCLUSION

Intoxications with corrosive substances are one of the most severe conditions seen in clinical toxicology. They usually occur among young people, during their most productive years of life, and they often end up with a certain degree of invalidity. Acute corrosive intoxications are burden for every healthcare system. Artificial nutritive support allows control of the nutritive status in our patients and it also reduces the duration of stay in the intensive care unit.

- Author's contribution: all authors in this paper have contributed in all phases in it's preparing. First author made final proof reading.
- Authors declare that there are no conflict of interest related to this manuscript.

#### REFERENCES

1. Allakhverdian AS, Maurin VS. Antisecretory therapy for prevention of stenosis of bouginage after-burn of esophageal strictures, *Eksp KLin Gastroenterol.* 2003; (4): 36-9, 114.
2. Andreoni B, Biffi R, Padalino P, Marini A, Marzona L, Belloli S, Farina ML, Tiberio G. Artificial nutrition in the management of lesions caused by caustic ingestion. *Chir Ital.* 1994; 46(6): 42-8.
3. Christesen HB. Ingestion of caustic agents. Epidemiology, pathogenesis, course, complications and prognosis. *Ugeskr laeger.* 1993; 155(31): 2379-82.
4. Jovancević L, Dankuc D. Corrosive substance ingestions management. *Med Pregl.* 2008; 61(2): 41-6.
5. Chibishev A, Chibisheva B, Bozinovska C, Naumovski J. Oesophageal and gastric stenoses are common complications after acute oral poisoning with corrosive agents, *Macedonian J of Med.* 2005; 51: 139-46.
6. Claw G A, Randall HT. Aminoacid and energy metabolism in septic traumatized patients *JPEN.* 1988; 4-19.
7. Zabelegui A, Miján de la Torre, Severe gastroesophageal lesions due to caustics. The role of nutritional support. *Nutr Hosp.* 1995 Nov-Dec; 10(6): 364-7.
8. Zargar SA, Kochhar R, Mehta S, et al. The role of fiberoptic endoscopy in the management of corrosive ingestion and modified endoscopic classification of burns. *Gastrointest Endosc.* 1991; 37: 165-9.
9. Zargar SA, Kochhar R, Nagi B, et al. Ingestion of strong corrosive alkalis: spectrum of injury to upper gastrointestinal tract and natural history. *Am J Gastroenterol.* 1992; 87: 337-41.
10. Lubos S. Basics in Clinical nutrition. Edited for ESPEN. Third Edition. 2004; 11-34.
11. Annalynn S. Dietitians handbook of enteral and parenteral nutrition; Second edition, Chapter 8. 1998; 167-79.
12. Campbell IT. Nutrition support in patients with multiple organ failure. *Curr Opin Clin Nutr Metab Care.* 1998 Mar; 1(2): 211-6.
13. Jeejeebhoy KN. Enteral and parenteral nutrition, Evidence based approach. *Proc Nutr Soc.* 2001; 60(3): 399-402.
14. Alinejad A. Caustic injury to upper gastrointestinal tract, Shiraz university of medical sciences, Department of internal medicine, Available from: [pearl.sums.ac.ir/semj/vol4/jan2003/causticinj.htm](http://pearl.sums.ac.ir/semj/vol4/jan2003/causticinj.htm)
15. Chibishev A, Simonovska-Veljanovska N, Pereska Z. Artificial Nutrition in Therapeutic Approach of Acute Caustic Poisonings. *Macedonian Journal of Medical Sciences.* 2010 Jun 15; 3(2): 180-7.
16. Abakumov MM, Kostichenko LN, Kudrichoba NE, Enteral infusion-nutritional correction of homeostasis in patients with post burn cicatricial stenosis of the esophagus and stomach. *Vestn KhirIm II Grek.* 1999; 155(5) 30-30.
17. Kikendal JW. Caustic ingestion injuries. *Gastroenterol Clin North Am.* 1991; 20: 847-8.
18. Chibishev A, Bozinovska C, Chibisheva V, Simonovska N, Pereska Z, Glasnovic M. Nutritional Therapy in Adult Patients with Post-corrosive Injuries of Gastrointestinal Tract. *Mater Sociomed.* 2011; 23(2): 64-8
19. Katzka A, David MD. Caustic Injury to the Esophagus. *Current Treatment Options in Gastroenterology.* 2001; 4: 59-60.
20. Chibishev A. Post-corrosive late complications in esophagus and stomach - role of the esophageal rest. *Med Arch.* 2010; 64: 320-3.
21. Kardon E. Caustic ingestion.com [homepage on the Internet]. *Emergency Medicine Toxicology.* [updated 2010 may; cited june 2010]. Available from: [emedicine.medscape.com](http://emedicine.medscape.com)
22. Zhou JH, Jiang YG, Wang RW, et al. Management of corrosive esophageal burns in 149 cases. *J Thorac Cardiovasc Surg.* 2005; 130: 449-55.
23. Ramasamy K, Gumaste V V. Corrosive ingestion in adults. *J Clin Gastroenterol.* 2003; 37: 119-24.
24. Lochs H, Allison SP, Meier R, Kondrup J, et al, Introductory to the Guidelines on enteral nutrition: Terminology, definitions and general topics. *Clinical Nutrition.* 2006; 25: 180-6.
25. Lochs H, Pichard C, Allison SP. Evidence supports nutritional support. *Clinical Nutrition.* 2006; 25: 177-9.
26. Chernosov AF, Ognesian AV. Treatment of a burn stricture of the esophagus complicated with a fistula. *Khirurgia (Mosk).* 2005; (4): 4-8
27. Di Constanzo J, Noirclerk M, Jouglard J, et al. New therapeutic approach to corrosive burns of the upper gastrointestinal tract. *Gut.* 1980; 21: 370-5.
28. Deskin R. Caustic ingestion, 1995; Available: [www. Utmb. Edu/otoref/grnds.../aerodigestive-2001-04.HTM](http://www.Utmb.Edu/otoref/grnds.../aerodigestive-2001-04.HTM)
29. Triadafilopoulos G, Caustic esophageal injury in adults. Up To Date, June, 2006. Available from: [www.informapharmascience.com./doi/abs/10.1080/13880200701585592](http://www.informapharmascience.com./doi/abs/10.1080/13880200701585592). Accessed on June, 2006
30. Howard P, Furnis L, Kyle U, et al. Managing the Patient Journey through Enteral Nutritional Care. *Clinical Nutrition.* 2006; 25: 187-95.
31. Jabbar A, Mc Clave S. Pre-pyloric versus post-pyloric feeding. *Clinical nutrition.* 2005; 719-26.
32. Bates N, Driver PK, Methyl ethyl ketone peroxide ingestion: toxicity and outcome in a 6-year-old child, *Pediatrics.* 2001; 108(2): 473-6.
33. Havanond G, Is there a difference between the management of grade 2b and 3 corrosive gastric injuries., *J Med Assoc Thai.* 2002 Mar; 85 (3): 340-4.
34. Zwischenberger R , Joseph B, Savage C, Bidan A, Surgical Aspects of Esophageal Disease Perforation and Caustic Injury *Am J Respir Crit Care Med.*
35. Berthet B, Bernardini D, Lonjon T. Treatment of caustic stenosis of the upper digestive tract. *Chir (Paris).* 1995 Nov; 132(11): 447-50.
36. Gadea V, Petrescu D, Bosman A, Our attitude in esophageal and gastric post-caustic lesions. *Chirurgia (Bucur).* 2000 May-Jun; 95 (3); 273-7.
37. Rakhmetov NR, Zhetiomkarimov DS, Surgical treatment of combined burn strictures of the esophagus and the stomach. *Khirurgia (Mosk).* 2003; (11): 17-9.
38. Young H, Qing-Shu C, Xiao-Fei L, Xiao-Ping W, Surgical management of esophageal strictures after caustic burns: A 30 years of experience *World J Gastroenterol.* 2004 October 1; 10(19): 2846-9.
39. Kochhar R, Poornachandra KS, Puri P, Dutta U et al. Comparative evaluation of nasoenteral feeding and jejunostomy feeding in acute corrosive injury: a retrospective analysis. *Gastrointest Endosc.* 2009; 70(5): 874-80.
40. Muñoz Botero NA, Pérez Cano AM, Rodríguez Herrera R, Rojas Gómez MP, Soler Páez FA. Nutrition therapy for adult patients with caustic injuries to gastrointestinal tract. *J Nutr Hosp.* 2010; 25(2): 231-7.