

Contents lists available at [ScienceDirect](http://ScienceDirect.com)

EBioMedicine

journal homepage: [www.ebiomedicine.com](http://www.ebiomedicine.com)

Research Paper

# White Matter Abnormalities in Post-traumatic Stress Disorder Following a Specific Traumatic Event



Lei Li <sup>a,1</sup>, Du Lei <sup>a</sup>, Lingjiang Li <sup>b</sup>, Xiaoqi Huang <sup>a</sup>, Xueling Suo <sup>a</sup>, Fenglai Xiao <sup>c,d,e</sup>, Weihong Kuang <sup>c,d,e</sup>, Jin Li <sup>c,d,e</sup>, Feng Bi <sup>c,d,e</sup>, Su Lui <sup>a</sup>, Graham J. Kemp <sup>f</sup>, John A. Sweeney <sup>a,g</sup>, Qiyong Gong <sup>a,\*</sup>

<sup>a</sup> Huaxi MR Research Center (HMRR), Department of Radiology, West China Hospital of Sichuan University, Chengdu, China

<sup>b</sup> Mental Health Institute, The Second Xiangya Hospital of Central South University, Changsha, China

<sup>c</sup> Department of Neurology, West China Hospital of Sichuan University, Chengdu, China

<sup>d</sup> Department of Psychiatry, West China Hospital of Sichuan University, Chengdu, China

<sup>e</sup> Department of Oncology, State Key Laboratory of Biotherapy, West China Hospital of Sichuan University, Chengdu, China

<sup>f</sup> Magnetic Resonance and Image Analysis Research Centre and Institute of Ageing and Chronic Disease, University of Liverpool, Liverpool, England, UK

<sup>g</sup> University of Texas Southwestern, Dallas, USA

## ARTICLE INFO

### Article history:

Received 3 October 2015

Received in revised form 27 November 2015

Accepted 11 January 2016

Available online 13 January 2016

### Keywords:

Posttraumatic stress disorder

Mental disorders

Diffusion tensor imaging

Magnetic resonance imaging

Neuroimaging

Psychoradiology

## ABSTRACT

Studies of posttraumatic stress disorder (PTSD) are complicated by wide variability in the intensity and duration of prior stressors in patient participants, secondary effects of chronic psychiatric illness, and a variable history of treatment with psychiatric medications. In magnetic resonance imaging (MRI) studies, patient samples have often been small, and they were not often compared to similarly stressed patients without PTSD in order to control for general stress effects. Findings from these studies have been inconsistent. The present study investigated whole-brain microstructural alterations of white matter in a large drug-naïve population who survived a specific, severe traumatic event (a major 8.0-magnitude earthquake). Using diffusion tensor imaging (DTI), we explored group differences between 88 PTSD patients and 91 matched traumatized non-PTSD controls in fractional anisotropy (FA), as well as its component elements axial diffusivity (AD) and radial diffusivity (RD), and examined these findings in relation to findings from deterministic DTI tractography. Relations between white matter alterations and psychiatric symptom severity were examined. PTSD patients, relative to similarly stressed controls, showed an FA increase as well as AD and RD changes in the white matter beneath left dorsolateral prefrontal cortex and forceps major. The observation of increased FA in the PTSD group suggests that the pathophysiology of PTSD after a specific acute traumatic event is distinct from what has been reported in patients with several years duration of illness. Alterations in dorsolateral prefrontal cortex may be an important aspect of illness pathophysiology, possibly via the region's established role in fear extinction circuitry. Use-dependent myelination or other secondary compensatory changes in response to heightened demands for threat appraisal and emotion regulation may be involved.

© 2016 The Authors. Published by Elsevier B.V. This is an open access article under the CC BY-NC-ND license (<http://creativecommons.org/licenses/by-nc-nd/4.0/>).

## 1. Introduction

Posttraumatic stress disorder (PTSD) is a response to traumatic experiences characterized by four main symptom clusters: re-experiencing symptoms (e.g. flashback and nightmares), avoidance symptoms, negative cognitions and mood, and arousal symptoms (e.g. hypervigilance and exaggerated startle). Given its high lifetime prevalence of 6.8% in the American general population, and its significant morbidity (Kessler et al., 2005), there is an urgent need to better understand its neurobiology.

A recent meta-analysis from our group showed that PTSD is associated with gray matter abnormalities (Li et al., 2014). Fewer studies have investigated white matter integrity (for a recent review (Daniels et al., 2013)). Results of these studies have been inconsistent, with reports of decreased fractional anisotropy (FA) in corpus callosum (Kitayama et al., 2007; Villarreal et al., 2004), prefrontal cortex (PFC) (Schuff et al., 2011), anterior cingulum (Kim et al., 2005; Schuff et al., 2011; Zhang et al., 2011) and posterior cingulum (Fani et al., 2012b), but also of increased FA in anterior cingulum (Abe et al., 2006) and superior frontal gyrus (Zhang et al., 2011).

There are important methodological issues regarding imaging protocols and patient sample characteristics that may contribute to the variability in study findings. Most early white matter studies in PTSD used manual tracing analysis in predefined regions of interest

\* Corresponding author at: Huaxi MR Research Center (HMRR) and Department of Radiology, West China Hospital of Sichuan University, Chengdu, Sichuan 610041, China.

E-mail address: [qiyonggong@hmrrc.org.cn](mailto:qiyonggong@hmrrc.org.cn) (Q. Gong).

<sup>1</sup> Lei Li and Du Lei contributed to the work equally.

(ROI) (Daniels et al., 2013). Although this method can be sensitive, results are highly reliant on anatomically specific prior hypotheses (Lee et al., 2009). This ROI-bias is avoided by whole-brain voxel-based analysis (Bandettini, 2009). Second, most previous voxel-based studies had small patient samples, and this might limit the reliability of results and sensitivity to illness effects (Abe et al., 2006; Fani et al., 2012b; Kim et al., 2005; Schuff et al., 2011; Zhang et al., 2012). Third, most studies have examined chronically ill patients treated with psychotropic medications, so that multiple secondary factors might differentially impact neuroanatomic measurements in the PTSD patients. Fourth, most prior studies compared PTSD patients to non-traumatized healthy controls, making it difficult to determine whether observed effects were related to PTSD per se or simply to traumatic stress exposure (Li et al., 2014). Only a few studies have compared PTSD patients to controls who experienced similar psychological trauma but did not develop PTSD (Abe et al., 2006; Schuff et al., 2011), and those studies often were complicated by psychotropic medication. Fifth, the nature, intensity and duration of trauma often varied widely among study participants. Studies using voxel based approaches with large samples of individuals with PTSD who experienced discrete stress compared to similarly stressed healthy individuals may better clarify PTSD neurobiology.

Diffusion tensor imaging (DTI) is particularly powerful for evaluating microstructural integrity of white matter by analyzing the restricted diffusion of water molecules (Catani, 2006). It can detect early neuropathological changes using quantitative indicators such as FA, which is thought to reflect fiber density, axonal diameter and myelination in white matter (Basser et al., 1994a; Basser et al., 1994b). Other DTI parameters that in combination determine FA, such as axial diffusivity (AD, along the axon) and radial diffusivity (RD, perpendicular to the main axonal axis) yield potentially more specific information. In animal studies, AD and RD have been identified as reflecting axonal and myelin integrity, respectively, that underlie changes in FA (Song et al., 2003; Song et al., 2002). Although methodological factors qualify their interpretation (Wheeler-Kingshott and Cercignani, 2009), these parameters provide potentially useful insight into the neurobiology of brain disorders. Few previous DTI studies of PTSD exploited the specific directional diffusivities (AD and RD), or used deterministic tractography to delineate the origins of fibers passing through regions with altered white matter anisotropy.

This study used DTI to investigate whole-brain microstructural alterations of white matter in a large sample of PTSD patients and controls, both of whom had survived a major 8.0-magnitude earthquake that occurred near a highly populated region of West China. Those diagnosed with PTSD were compared to those who did not develop the disorder ('non-PTSD') to control for general stress effects. The potential power of this study to illuminate the neuropathophysiology of PTSD is enhanced by several factors: 1) the unique characteristic of the trauma event involving a single, discrete period of acute emotional distress, 2) the relatively homogeneous demographic characteristics of the trauma survivors, 3) the use of non-PTSD controls exposed to similar trauma to control for general stress effects, 4) a relatively large study population free from psychotropic medication, and 5) the use of advanced techniques for analyzing the DTI data including the separation of radial and axial diffusivity and deterministic DTI tractography. Our previous functional magnetic resonance imaging (fMRI) studies using some of the present study participants found altered function in prefrontal-limbic system (Jin et al., 2014; Lei et al., 2015a; Yin et al., 2012; Yin et al., 2011a; Yin et al., 2011b). However, anatomic alterations underlying the functional abnormalities were not examined. Based on prior findings from our sample and other laboratories, we hypothesized that there are white matter abnormalities in prefrontal cortex in PTSD patients, and that they are related to PTSD severity.

## 2. Materials and Methods

### 2.1. Subjects

We recruited subjects who survived a severe earthquake (magnitude 8.0) in Sichuan Province of western China. A large-scale PTSD survey was conducted among 4200 survivors who were screened with the PTSD checklist (PCL) (Weathers et al., 1993). To be included in our study, the survivors needed to have (i) physically experienced the earthquake, and (ii) personally witnessed death, serious injury or the collapse of buildings, but (iii) suffered no physical injury, head trauma or loss of consciousness for >5 min. These criteria ensured that all survivors were exposed to generally similar traumatic stress intensity. Survivors with PCL scores  $\geq 35$  points were screened using the clinician-administered PTSD scale (CAPS) (Blake et al., 1995) and the Structured Clinical Interview for the Diagnostic and Statistical Manual of Mental Disorders, fourth edition (SCID) to confirm the PTSD diagnosis. Four hundred and fifteen eligible PTSD patients were identified from the survey. The SCID was also used to exclude individuals with current or past psychiatric illness, and any history of alcohol or drug abuse ( $n = 134$ ). Participants also were excluded with any history of or current brain injury ( $n = 12$ ), any significant medical or neurological conditions ( $n = 58$ ), pregnancy ( $n = 0$ ), any MRI contraindication ( $n = 81$ ), left handed ( $n = 16$ ), brain lesions identified at the MRI examination ( $n = 5$ ), CAPS scores <50 points ( $n = 11$ ) or age  $\leq 18$  years ( $n = 10$ ). All patients included had no psychotropic medication use in the prior two months (to limit possible confounding effects on brain structure). Finally, 88 PTSD and 91 demographically matched non-PTSD study-eligible individuals were selected for this study. This study was approved by the local university ethics committee. Written fully-informed consent was obtained from all participants.

### 2.2. Imaging Acquisition

MRI data were acquired on a 3 T MRI system (EXCITE; General Electric) at the Department of Radiology in West China Hospital using an 8-channel phased-array head coil. The head was stabilized with cushions and ear plugs were used. DTI data, with 15 noncollinear directions ( $b = 1000 \text{ s/mm}^2$ ), as well as a reference image without diffusion weighting ( $b = 0$ ), were acquired using a single-shot spin-echo echo planar image (SE-EPI) sequence. Array spatial sensitivity encoding was used to reduce susceptibility and eddy-current artifacts. Scan parameters were as follows: repetition time (TR) = 12,000 ms; echo time (TE) = 70.8 ms; matrix =  $128 \times 128 \text{ mm}^2$  on  $240 \times 240 \text{ mm}^2$  field of view (FOV); slices 3 mm without gap. Pairs of images during acquisition were averaged to increase resolution of MRI data.

### 2.3. Image Analysis

DTI preprocessing, including skull stripping using the Brain Extraction Tool (BET, <http://fsl.fmrib.ox.ac.uk/fsl/bet2/>) and eddy current correction for distortions induced by the head movement and eddy currents, were performed using the FMRIB Software Library (FSL 4.1, Oxford, U.K., <http://www.fmrib.ox.ac.uk/fsl/>). A diffusion tensor model was fitted to each voxel to create FA and eigenvalue ( $\lambda_i, i = 1, 2, 3$ ) images. The parametric map of eigenvalue  $\lambda_1$  represents that of AD ( $\lambda_{||} = \lambda_1$ ), while RD was calculated by using the image manipulation subroutine (ImCalc) function in SPM8 [ $\lambda_{\perp} = (\lambda_2 + \lambda_3) / 2$ ].

A whole-brain voxel-wise analysis was then performed with SPM8 software (<http://www.fil.ion.ucl.ac.uk/spm/>) running in MATLAB 2010 (MathWorks, Natick, Mass). For each subject, the FA, AD and RD images were normalized to the standard Montreal Neurological Institute (MNI) space, based on the deformation information generated from the unweighted image ( $B_0$  image) and using the echo-planar imaging (EPI) template supplied with SPM8, each voxel being  $2 \times 2 \times 2 \text{ mm}^3$ . The

normalized images were smoothed using an isotropic Gaussian kernel (6-mm full width at half maximum) for statistical analysis.

#### 2.4. Statistical Analysis

The normalized and smoothed FA values for each voxel across the whole brain for PTSD patients and controls were compared using two-sample t-test in SPM8. The statistical maps were thresholded at  $p < 0.05$  at the voxel level after false discovery rate (FDR) correction, using an extent threshold of  $p < 0.005$  (uncorrected) with a minimum cluster size of 50 voxels. The average FA, AD and RD values of all voxels in each significant cluster identified from the FA maps were extracted by using a volume-of-interest approach through the MarsBaR toolbox in SPM8, and analyzed by using SPSS to contrast groups using two sample t-tests. Partial correlation analysis was performed in PTSD patients between FA values in each region with significant group differences and CAPS scores, using age and gender as covariates. The time from trauma until scanning, which was relatively narrow in our study, was not related to MRI parameters so it was not included as a covariate.

#### 2.5. Deterministic Tractography

Deterministic DTI tractography was performed in Diffusion Toolkit and Trackvis software ([www.trackvis.org](http://www.trackvis.org)), after preprocessing datasets using SPM8 software. For each subject there were 4 steps. First the transformation matrix (T), i.e. the normalized  $B_0$  image, was converted to the inverse transformation ( $T^{-1}$ ). This  $T^{-1}$  was then applied to the ROI segmentations identified by the FA maps in standard MNI space in order to warp the images to DTI native space. These two steps were performed in SPM8 software. Third, the preprocessed datasets of both groups were reconstructed to generate tractography maps using Diffusion Toolkit software. Lastly, the fiber tracts passing through regions with abnormal white matter in the PTSD patients identified in the FA maps were reconstructed and displayed by Trackvis software for each subject to identify which major tracts projected through regions with white matter abnormalities.

#### 2.6. Role of the Funding Source

The funding source had no role in the study design, data collection, data analyses, or data interpretation. The corresponding author had full access to all the data in the study and had final responsibility for the decision to submit for publication.

### 3. Results

#### 3.1. Demographic and Clinical Comparisons

Demographic and clinical characteristics of study participants are summarized in Table 1. There were no significant differences between the PTSD and control subjects in age, gender, education or time since trauma.

#### 3.2. Voxel-Based Analysis

The voxel-based analysis showed significantly increased FA in the PTSD group in two regions of left dorsolateral prefrontal cortex (DLPFC), localized beneath the left superior and middle frontal gyri, and in the left forceps major of the corpus callosum (Fig. 1, Table 2).

#### 3.3. Axial and Radial Diffusivity Analysis

Focusing on the high-FA ROIs identified in the left superior and middle frontal gyri, *post hoc* analysis showed decreased RD ( $p = 0.009$  and  $p < 0.0001$ , respectively) and decreased AD ( $p = 0.012$  and  $p < 0.0001$ ,

**Table 1**  
Demographic and clinical characteristics of PTSD patients and non-PTSD controls<sup>a</sup>.

Characteristics	PTSD patients (n = 88)	Non-PTSD controls (n = 91)	t or $\chi$ -test P value
	Mean $\pm$ SD	Mean $\pm$ SD	
Age (years) <sup>b</sup>	43.0 $\pm$ 10.4	43.7 $\pm$ 9.9	0.662
Education (years) <sup>d</sup>	7.0 $\pm$ 3.0	6.9 $\pm$ 3.4	0.781
M:F	28:60	25:66	0.524 <sup>c</sup>
Time since trauma (month) <sup>b</sup>	11.1 $\pm$ 2.3	11.6 $\pm$ 2.2	0.193
CAPS	62.9 $\pm$ 10.6	23.3 $\pm$ 10.4	<0.001
PCL	47.3 $\pm$ 12.6	28.1 $\pm$ 7.1	<0.001

Abbreviations: PTSD: posttraumatic stress disorder; CAPS: clinician-administered PTSD scale; PCL: PTSD checklist.

<sup>a</sup> Analyses of demographics and clinical data were performed in SPSS 20.0 software (<http://www.spss.com>). All tests were two-tailed. No significant differences were found between PTSD patients and non-PTSD controls in age, gender, education and time since trauma.

<sup>b</sup> Age and time since trauma were defined at the time of magnetic resonance scanning.

<sup>c</sup> The P value was calculated by Chi-squared-test.

<sup>d</sup> Years of education refers to the total number of years of completed education as reported by participant.

respectively) in PTSD patients relative to non-PTSD controls. Though a decrease in AD tends to be associated with decreased FA, this effect is outweighed by changes in the dominant effect of RD decrease. The reduction in RD was 9.0% compared to only 3.9% for AD in PTSD patients relative to controls. For the left middle frontal gyrus, there was a 9.2% reduction in RD compared to a 5.6% reduction for AD values in PTSD patients relative to controls. By contrast, in the high-FA region in the left forceps major, analysis showed decreased RD ( $p = 0.001$ ) but increased AD ( $p = 0.004$ ) (Fig. 2). FA, AD, RD means and standard deviations with p values are presented in Table S1. In addition, an exploratory whole-brain voxel-based analysis for RD and AD is shown in Supplementary Materials, with altered-RD or AD brain areas overlapping closely with high-FA areas (Table S2, Figure S1).

#### 3.4. Partial Correlation Analysis

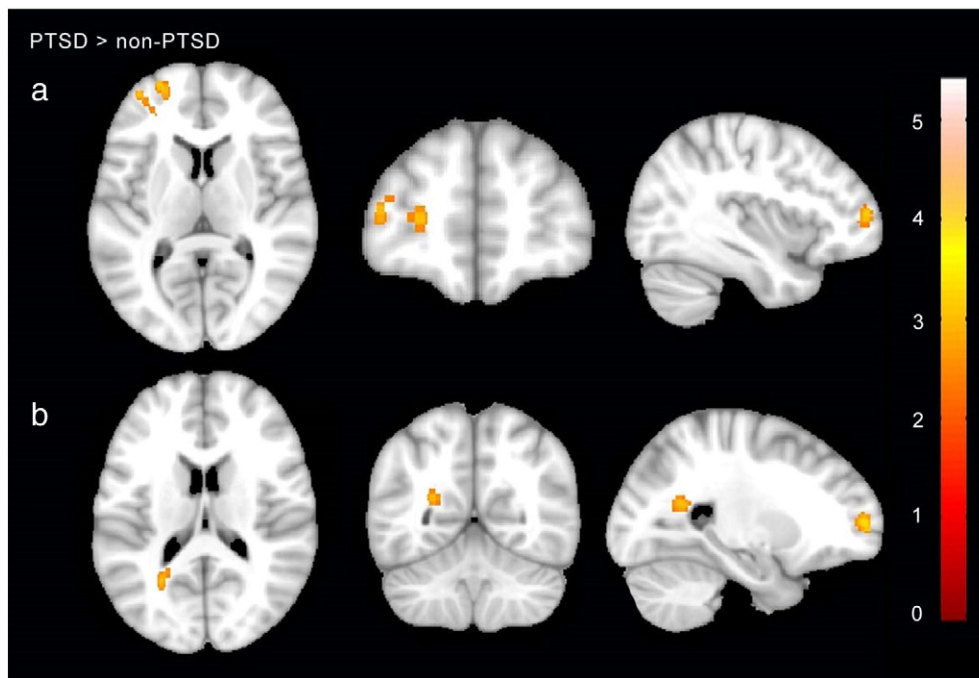
Partial correlation analysis between clinical measures and DTI parameters in regions with demonstrated FA abnormalities revealed a positive correlation between FA in the middle frontal gyrus and CAPS scores in patients with PTSD ( $r = 0.349$ ,  $p = 0.001$ ) (Fig. 3B). Correlations between CAPS scores with FA in the superior frontal gyrus and the forceps major were not significant.

#### 3.5. Deterministic Tractography

The tractography analysis indicated that the cluster of increased FA in the left superior frontal gyrus received the most robust projections from the genu of the corpus callosum and the left anterior thalamic radiation. The left middle frontal gyrus was identified as the terminal aspect of the thalamic radiation (Mori et al., 2005). The forceps major is located at the interface between crossing fibers from the splenium of the corpus callosum and the inferior longitudinal fasciculus. The tractography map is presented in Fig. 3A.

### 4. Discussion

The present study explored white matter abnormalities in individuals who had experienced a discrete and severe psychological trauma, some who later developed PTSD after the trauma and a comparison group who did not. Notably, the two participant groups had similar, severe trauma exposure and homogenous demographic characteristics, and were not receiving psychiatric medications. Further, the PTSD group had a relatively high homogeneity of illness duration and time since trauma. Analysis of the DTI data included not only the conventional parameter FA, but its component elements of



**Fig. 1.** Regions with significantly increased fractional anisotropy in PTSD patients compared with non-PTSD controls. Images are presented in neurological orientation. In PTSD patients relative to non-PTSD controls, FA was increased in A) the left prefrontal cortex, including the left superior and middle frontal gyrus, and B) left forceps major of the corpus callosum. Statistical inferences were made with a voxel-level statistical threshold ( $p < 0.05$ ) after false discovery rate correction, and an extent threshold of  $p < 0.005$  (uncorrected), with a minimum cluster size of 50 voxels. Abbreviations: PTSD = posttraumatic stress disorder; non-PTSD = traumatized survivors without PTSD.

radial and axial diffusivity that reflect different aspects of white matter integrity. The main findings included white matter abnormalities in two regions of left DLPFC, localized to the left superior and middle frontal gyri, and in left forceps major. Diffusion alterations in the left middle frontal gyrus were related to PTSD clinical ratings. These results suggest specific and clinically relevant associations between PTSD symptomatology and patterns of diffusion alterations in dorso-lateral prefrontal cortex in a relatively large group of single-incident, severely traumatized individuals with PTSD relative to similarly stressed controls.

This FA increase in left superior frontal gyrus is consistent with a previous study that reported increased FA in drug-free PTSD patients who survived a severe coal mine accident at 2 months post-trauma, generally similar to the sample in the present study (Zhang et al., 2011). In contrast, most studies of PTSD patients with multiple, diverse traumatic events and longer symptom duration of several years have reported decreased FA (Daniels et al., 2013; Schuff et al., 2011). For example, Schuff et al. reported decreased FA in the prefrontal cortex in male military veterans with PTSD (mean illness duration: 14 years) (Schuff et al., 2011). This difference in findings between studies of first-episode medication-

free patients after specific acute trauma and patients ill with PTSD for several years may be related to a distinct pathophysiology of relatively early illness manifestations, and perhaps also to PTSD that results from a specific single-incident stressor. They also might reflect adaptations and compensations for chronic PTSD, or effects of chronic drug treatment. Another possible explanation for differences in our findings relative to some prior studies of more chronically ill patients may be that we included stressed non-PTSD samples as controls instead of non-exposed community controls. The non-PTSD subjects who were resilient to the same traumatic event may have prior brain characteristics that contributed to the resilience, such as a well-organized DLPFC inhibition system manifest in a FA decrease (Chen et al., 2013). While our findings help understand the brain differences in those who do and do not develop PTSD after major stress, future comparative studies of non-exposed controls within the first year after stress may also be informative for understanding illness consequences and perhaps for identifying general stress effects that do not lead to PTSD. In particular, the observation of FA abnormalities in the present study suggests a critical role of alterations in prefrontal cortex in first-episode medication-free PTSD. However, whether and how white matter alterations in this region may change over the longer term course of illness remains to be determined by longitudinal studies.

Changes in FA in relation to changes in RD and AD suggest that the greatest change in white matter microstructure was a reduction in RD that led to an increase in FA values. FA is an aggregate index of white matter integrity. It essentially reflects the prominence of diffusion along axons relative to diffusion perpendicular to the wall of the axon. It thus reflects complex tissue properties such as intra- and extracellular volume, fiber coherence, axonal density and degree of myelination, and thus interpretation about any specific alteration in white matter from FA measures must be made with caution (Jones et al., 2013). Analysis of axial and radial diffusivities can help define the neurobiological determinants of altered white matter microstructure. Data from animal studies suggest that AD is primarily an

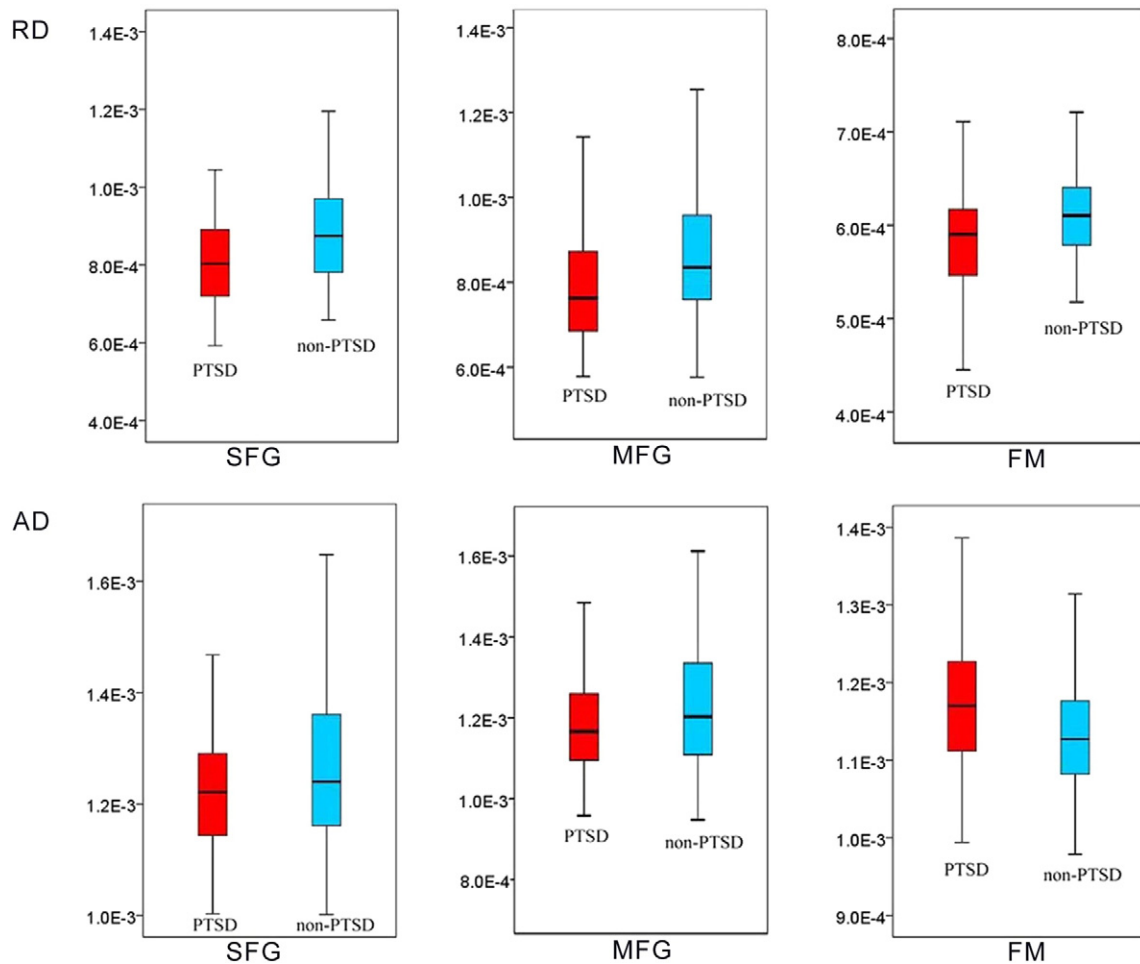
**Table 2**

Regions showing significantly increased fractional anisotropy in PTSD patients compared with non-PTSD controls.

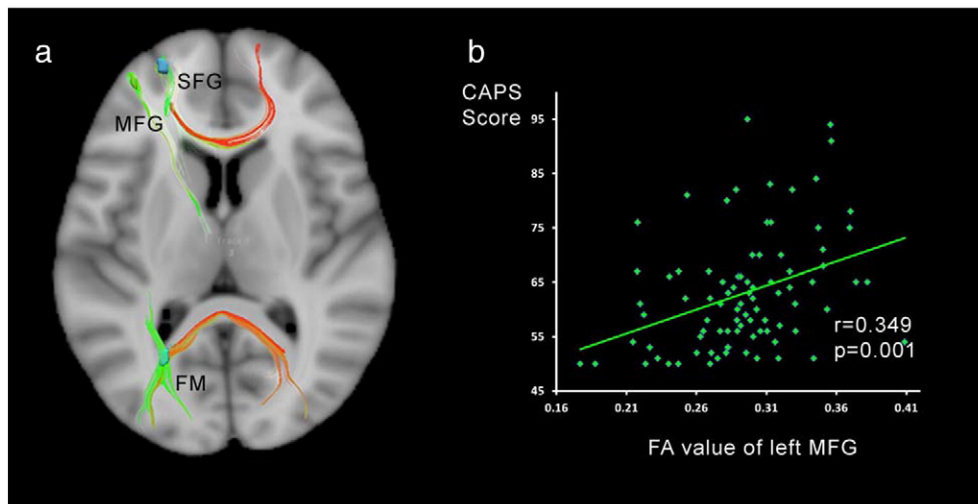
Anatomical regions	T value <sup>b</sup>	Cluster size (voxels)	MNI coordinate (X, Y, Z) <sup>a</sup>
Left superior frontal gyrus	5.39	45	−24 58 4
Left middle frontal gyrus	4.67	9	−38 52 8
Left forceps major	4.77	26	−26 −58 18

<sup>a</sup> MNI location is peak of cluster.

<sup>b</sup> All effects survived a voxel-wise statistical threshold ( $p < 0.05$ ) at the voxel level after false discovery rate correction, and an extent threshold of  $p < 0.005$  (uncorrected), with a minimum cluster size of 50 voxels.



**Fig. 2.** Radial diffusivity and axial diffusivity in PTSD patients and non-PTSD controls. RD and AD values differed significantly in the left superior frontal gyrus, left middle frontal gyrus and left forceps major between the two groups. Abbreviations: RD = radial diffusivity; AD = axial diffusivity; PTSD = posttraumatic stress disorder; non-PTSD = traumatized survivors without PTSD; SFG = superior frontal gyrus; MFG = middle frontal gyrus; FM = forceps major.



**Fig. 3.** Brain regions showing relationships between FA and clinician-administered PTSD scale scores in PTSD patients, and the tractography map. A) The DTI tractography map shows the tracts traversing clusters with increased FA in a representative subject color-coded by fiber direction. The clusters in the left prefrontal cortex lie in the terminal of the genu of corpus callosum and the anterior thalamic radiation, and the forceps major at the intersection of crossing fibers from the splenium of corpus callosum and longitudinal fasciculus. B) The correlation analysis showed that, in PTSD patients, FA values in the middle frontal gyrus significantly correlated with CAPS scores ( $p = 0.001$ ). Abbreviations: CAPS = clinician-administered PTSD scale; FA = fractional anisotropy; SFG = superior frontal gyrus; MFG = middle frontal gyrus; FM = forceps major; PTSD = posttraumatic stress disorder; non-PTSD = traumatized survivors without PTSD.

axonal marker and RD is primarily a myelin marker (Song et al., 2003; Song et al., 2002; Song et al., 2005). In the region of increased FA in the left superior and middle frontal gyri in PTSD, we saw a decrease both in AD and in RD relative to controls. Thus, the pattern of effects we observed is likely the manifestation of complex microstructural changes affecting both axon and myelin. This is consistent with our DTI study in children with PTSD that also identified both AD and RD alterations (Lei et al., 2015b).

While interpretation needs to be made with caution, the findings from the present study are most consistent with a pattern of decreased axonal density or disturbed intracellular structure suggested by the reduced AD, and increased glial cell density or higher myelination suggested by the reduced RD. The increase in FA appeared to be primarily a result of increased myelination (lower RD), which could be induced by increased oligodendrocyte growth or migration through a glial-axonal communication mechanism activated by increased rates of action potentials in fibers of passage forming affected fiber tracts (Demerens et al., 1996; Schlegel et al., 2012). The increased oligodendrocytes could account for both increased myelin (lower RD) and reduced axonal density (lower AD) (Caprihan et al., 2015).

The pattern of MRI findings in the present study contrast with findings from studies of patients with several years duration of illness in which diminished neuronal plasticity appears to represent the more prominent deficit (Schuff et al., 2011). We note that in our cross-sectional clinical study it is not possible to exclude the possibility that more myelin preexists in those at risk to develop PTSD. Other possibilities and factors also require consideration. For example, an FA increase can result from greater directional coherence of diffusion resulting from more coherent fiber tract organization and less neuronal branching (van Ewijk et al., 2012). A mechanism such as this might explain the increased FA we observed in the forceps major of the corpus callosum. Tractography shows that the increased FA in left forceps major is at the intersection of crossing fibers from the splenium of the corpus callosum and the inferior longitudinal fasciculus. FA increase at locations where fibers cross can reflect increased thickness of a dominant tract or degeneration of the non-dominant crossing fibers (Radua et al., 2014).

PFC dysfunction has been linked to stress-related disorders such as PTSD in animal models as well as patient studies (Arnsten, 2009). The DLPFC is critical for “top-down” cognitive control, working memory, control of attention, and mood regulation (Aupperle et al., 2012; Goldman-Rakic, 1996; Stein, 2008), and has reciprocal connections to limbic system regions such as the amygdala and hippocampus via projections from ventromedial PFC (Hartley and Phelps, 2010). Studies have shown the crucial role of these regions and their functional relationships in fear extinction learning (Maren and Quirk, 2004; Milad et al., 2006), and thus our finding of white matter alterations in DLPFC is consistent with the idea that abnormalities in these regions are pivotal in PTSD (Lyo et al., 2011; Rauch et al., 2006).

Increased neuronal activation could lead to cellular swelling and also activity-dependent myelin-modulation via increased astrocyte activity (Messina et al., 2015), which could account for the diffusion alterations in our findings. Therefore, one plausible and perhaps most likely explanation for our findings is that use-dependent myelination in dorsolateral prefrontal neurocircuitry may alter the underlying structure in this brain region in first-episode medication-free PTSD patients. The very slow ontogeny of the PFC, whose maturation extends to the third decade, may be another factor to explain why this region shows high plasticity in our adult sample and in PTSD (Chen et al., 2013). While our findings identify circuitry affected, the reasons why this specific circuitry is vulnerable to stress effects remain important to clarify in future clinical and preclinical research.

We found a significant correlation between increased FA in the left middle frontal gyrus and clinical severity of PTSD symptoms. The

association between PFC alterations and PTSD severity is consistent with conceptualizations of PTSD pathophysiology which propose an important role of dorsal frontal networks in threat cue appraisal, which is dramatically altered in PTSD (Etkin et al., 2011). The increased FA in DLPFC may reflect a dysfunction in neural systems that leads to amplified threat evaluation via a selective disruption in cognitive evaluation of events and reduced top-down modulation of emotional reactivity (Fani et al., 2012a). Reports of altered brain function in prefrontal cortex in PTSD are consistent with this possibility (Patel et al., 2012), and our findings suggest that an alteration in the anatomic structures in this region may underlie these physiological and behavioral features of PTSD.

Corpus callosum abnormalities have been relatively consistent findings in PTSD (Daniels et al., 2013). The cluster we identified was predominantly in a posterior aspect consisting largely of transcallosal fibers of the occipital lobe. Tractography of that region showed fibers projecting into the cuneus and lingual gyrus, central components of occipital lobe visual processing. According to recent clinical fMRI studies, a hallmark symptom of PTSD, flashback, is often associated with increased activation in the ventral occipital cortex, a region involved in higher-level visual processing and mental imagery (Bourne et al., 2013; Kosslyn et al., 2001). Thus, abnormalities in this region may be related to persistent flashback experiences, which are a prominent clinical feature of PTSD because of their nature as highly emotional, visual memories of threatening situations. This raises the possibility that white matter alterations might be secondary to increased physiological activity related to visual reprocessing, which might parallel the increased FA in PFC which could be related to heightened demands for threat appraisal and emotion modulation. While our findings indicate that white matter alterations occur relatively early in the course of PTSD, it remains to be determined whether they identify at-risk individuals, cause functional alterations, or result from functional alterations.

Thus while our findings represent a significant advance in understanding region-specific white matter changes relatively early in the course of PTSD, they raise important next-step questions for future research. First, the extent to which the diffusion alterations we observed represent pre-existing risk factors or effects of illness remains to be determined. Second, longitudinal studies are needed to determine whether illness progression effects suggested by comparison of cross-sectional studies of PTSD patients shortly after illness onset and after a chronic course of illness truly reflect course of illness effects. Further, longer-term follow-up would more definitively differentiate those who eventually do and do not develop PTSD. Third, studies are needed over the course of illness to determine whether anatomic changes disrupt function, or functional changes are driving changes in brain anatomy. Fourth, non-traumatized healthy controls need to be evaluated together with stressed non-PTSD controls in future research for several reasons including delineation of stress effects independent of PTSD. Fifth, a technical limitation of the current work is the comparatively low number of gradient directions, which limits the quality of the available data. Future studies with more gradient directions in DTI acquisition are needed to improve the accuracy of tractography and explore the neurocircuitry in PTSD using connectivity analyses.

Our study provides new insight into the microstructural abnormalities of white matter in a relatively large unmedicated group of single-incident trauma PTSD patients which differs from observations seen in patients followed after years of multiple and diverse trauma and treatments. We identified key areas of distinct white matter alteration in dorsolateral prefrontal cortex and left forceps major. Our observation of increased FA in PFC, together with previous reports of increased neural activity in dorsolateral prefrontal circuitry, is most consistent with the possibility of increased oligodendrocyte growth or other secondary compensatory changes in response to heightened demands for threat appraisal and emotion regulation that could lead to use-dependent myelination.

## Contributions

Q. Gong conceived the idea for the study and managed the project. L. Li, D. Lei, and Q. Gong designed the study. L. Li, D. Lei, L.J. Li, X. Suo, F. Xiao, W. Kuang, and J. Li acquired the data, which L. Li, D. Lei, F. Bi, G. Kemp, and J. Sweeney analyzed. L. Li and D. Lei wrote the article, and G. Kemp and J. Sweeney reviewed the article, which all authors approved for publication.

## Conflict of Interest

None of the authors has conflicts of interests to report with regard to this manuscript, except Dr. Sweeney who has consulted to Takeda, Roche and Lilly.

## Acknowledgments

This study was supported by the National Natural Science Foundation (Grant Nos. 81220108013, 81227002 and 81501452), and Program for Changjiang Scholars and Innovative, Research Team in University (PCSIRT, Grant No. IRT1272) of China. Dr. Gong would also like to acknowledge the support from his Changjiang Scholar Professorship Award (Award No. T2014190) of China and the CMB Distinguished Professorship Award (Award No. F510000/G16916411) administered by the Institute of International Education, USA.

## Appendix A. Supplementary data

Supplementary data to this article can be found online at <http://dx.doi.org/10.1016/j.ebiom.2016.01.012>.

## References

- Abe, O., Yamasue, H., Kasai, K., Yamada, H., Aoki, S., Iwanami, A., et al., 2006. Voxel-based diffusion tensor analysis reveals aberrant anterior cingulum integrity in posttraumatic stress disorder due to terrorism. *Psychiatry Res.* 146, 231–242.
- Armsten, A.F., 2009. Stress signalling pathways that impair prefrontal cortex structure and function. *Nat. Rev. Neurosci.* 10, 410–422.
- Aupperle, R.L., Allard, C.B., Grimes, E.M., Simmons, A.N., Flagan, T., Behrooznia, M., et al., 2012. Dorsolateral prefrontal cortex activation during emotional anticipation and neuropsychological performance in posttraumatic stress disorder. *Arch. Gen. Psychiatry* 69, 360–371.
- Bandettini, P.A., 2009. What's new in neuroimaging methods? *Ann. N. Y. Acad. Sci.* 1156, 260–293.
- Basser, P.J., Mattiello, J., LeBihan, D., 1994a. Estimation of the effective self-diffusion tensor from the NMR spin echo. *J. Magn. Reson. B* 103, 247–254.
- Basser, P.J., Mattiello, J., LeBihan, D., 1994b. MR diffusion tensor spectroscopy and imaging. *Biophys. J.* 66, 259–267.
- Blake, D.D., Weathers, F.W., Nagy, L.M., Kaloupek, D.G., Gusman, F.D., Charney, D.S., et al., 1995. The development of a clinician-administered PTSD scale. *J. Trauma. Stress.* 8, 75–90.
- Bourne, C., Mackay, C.E., Holmes, E.A., 2013. The neural basis of flashback formation: the impact of viewing trauma. *Psychol. Med.* 43, 1521–1532.
- Caprihan, A., Jones, T., Chen, H., Lemke, N., Abbott, C., Qualls, C., et al., 2015. The paradoxical relationship between white matter, psychopathology and cognition in schizophrenia: a diffusion tensor and proton spectroscopic imaging study. *Neuropsychopharmacology* 40, 2248–2257.
- Catani, M., 2006. Diffusion tensor magnetic resonance imaging tractography in cognitive disorders. *Curr. Opin. Neurol.* 19, 599–606.
- Chen, L., Lui, S., Wu, Q.Z., Zhang, W., Zhou, D., Chen, H.F., et al., 2013. Impact of acute stress on human brain microstructure: an MR diffusion study of earthquake survivors. *Hum. Brain Mapp.* 34, 367–373.
- Daniels, J.K., Lamke, J.P., Gaebler, M., Walter, H., Scheel, M., 2013. White matter integrity and its relationship to PTSD and childhood trauma—a systematic review and meta-analysis. *Depress Anxiety* 30, 207–216.
- Demerens, C., Stankoff, B., Logak, M., Anglade, P., Allinquant, B., Couraud, F., et al., 1996. Induction of myelination in the central nervous system by electrical activity. *Proc. Natl. Acad. Sci. U. S. A.* 93, 9887–9892.
- Etkin, A., Egner, T., Kalisch, R., 2011. Emotional processing in anterior cingulate and medial prefrontal cortex. *Trends Cogn. Sci.* 15, 85–93.
- Fani, N., Jovanovic, T., Ely, T.D., Bradley, B., Gutman, D., Tone, E.B., et al., 2012a. Neural correlates of attention bias to threat in post-traumatic stress disorder. *Biol. Psychol.* 90, 134–142.
- Fani, N., King, T.Z., Jovanovic, T., Glover, E.M., Bradley, B., Choi, K., et al., 2012b. White matter integrity in highly traumatized adults with and without post-traumatic stress disorder. *Neuropsychopharmacology* 37, 2740–2746.
- Goldman-Rakic, P.S., 1996. The prefrontal landscape: implications of functional architecture for understanding human mentation and the central executive. *Philos. Trans. R. Soc. Lond. Ser. B Biol. Sci.* 351, 1445–1453.
- Hartley, C.A., Phelps, E.A., 2010. Changing fear: the neurocircuitry of emotion regulation. *Neuropsychopharmacology* 35, 136–146.
- Jin, C., Qi, R., Yin, Y., Hu, X., Duan, L., Xu, Q., et al., 2014. Abnormalities in whole-brain functional connectivity observed in treatment-naïve post-traumatic stress disorder patients following an earthquake. *Psychol. Med.* 44, 1927–1936.
- Jones, D.K., Knosche, T.R., Turner, R., 2013. White matter integrity, fiber count, and other fallacies: the do's and don'ts of diffusion MRI. *NeuroImage* 73, 239–254.
- Kessler, R.C., Berglund, P., Demler, O., Jin, R., Merikangas, K.R., Walters, E.E., 2005. Lifetime prevalence and age-of-onset distributions of DSM-IV disorders in the National Comorbidity Survey Replication. *Arch. Gen. Psychiatry* 62, 593–602.
- Kim, M.J., Lyoo, I.K., Kim, S.J., Sim, M., Kim, N., Choi, N., et al., 2005. Disrupted white matter tract integrity of anterior cingulate in trauma survivors. *Neuroreport* 16, 1049–1053.
- Kitayama, N., Brummer, M., Hertz, L., Quinn, S., Kim, Y., Bremner, J.D., 2007. Morphologic alterations in the corpus callosum in abuse-related posttraumatic stress disorder: a preliminary study. *J. Nerv. Ment. Dis.* 195, 1027–1029.
- Kosslyn, S.M., Ganis, G., Thompson, W.L., 2001. Neural foundations of imagery. *Nat. Rev. Neurosci.* 2, 635–642.
- Lee, J.E., Chung, M.K., Lazar, M., DuBray, M.B., Kim, J., Bigler, E.D., et al., 2009. A study of diffusion tensor imaging by tissue-specific, smoothing-compensated voxel-based analysis. *NeuroImage* 44, 870–883.
- Lei, D., Li, K., Li, L., Chen, F., Huang, X., Lui, S., et al., 2015a. Disrupted functional brain connectome in patients with posttraumatic stress disorder. *Radiology* 276, 818–827.
- Lei, D., Li, L., Suo, X., Huang, X., Lui, S., Li, J., et al., 2015b. Microstructural abnormalities in children with post-traumatic stress disorder: a diffusion tensor imaging study at 3.0 T. *Sci. Rep.* 5, 8933.
- Li, L., Wu, M., Liao, Y., Ouyang, L., Du, M., Lei, D., 2014. Grey matter reduction associated with posttraumatic stress disorder and traumatic stress. *Neurosci. Biobehav. Rev.* 43, 163–172.
- Lyoo, I.K., Kim, J.E., Yoon, S.J., Hwang, J., Bae, S., Kim, D.J., 2011. The neurobiological role of the dorsolateral prefrontal cortex in recovery from trauma. Longitudinal brain imaging study among survivors of the South Korean subway disaster. *Arch. Gen. Psychiatry* 68, 701–713.
- Maren, S., Quirk, G.J., 2004. Neuronal signalling of fear memory. *Nat. Rev. Neurosci.* 5, 844–852.
- Messina, R., Rocca, M.A., Colombo, B., Pagani, E., Falini, A., Comi, G., 2015. White matter microstructure abnormalities in pediatric migraine patients. *Cephalalgia* 35, 1278–1286.
- Milad, M.R., Rauch, S.L., Pitman, R.K., Quirk, G.J., 2006. Fear extinction in rats: implications for human brain imaging and anxiety disorders. *Biol. Psychol.* 73, 61–71.
- Mori, S., Wakana, S., Nagae-Poetscher, L.M., Van Zijl, P.C.M., 2005. MRI atlas of human white matter. Elsevier.
- Patel, R., Spreng, R.N., Shin, L.M., Girard, T.A., 2012. Neurocircuitry models of posttraumatic stress disorder and beyond: a meta-analysis of functional neuroimaging studies. *Neurosci. Biobehav. Rev.* 36, 2130–2142.
- Radua, J., Grau, M., van den Heuvel, O.A., de Schotten, M.T., Stein, D.J., Canales-Rodriguez, E.J., et al., 2014. Multimodal voxel-based meta-analysis of white matter abnormalities in obsessive-compulsive disorder. *Neuropsychopharmacology* 39, 1547–1557.
- Rauch, S.L., Shin, L.M., Phelps, E.A., 2006. Neurocircuitry models of posttraumatic stress disorder and extinction: human neuroimaging research—past, present, and future. *Biol. Psychiatry* 60, 376–382.
- Schlegel, A.A., Rudelson, J.J., Tse, P.U., 2012. White matter structure changes as adults learn a second language. *J. Cogn. Neurosci.* 24, 1664–1670.
- Schuff, N., Zhang, Y., Zhan, W., Lenoci, M., Ching, C., Boreta, L., et al., 2011. Patterns of altered cortical perfusion and diminished subcortical integrity in posttraumatic stress disorder: an MRI study. *NeuroImage* 54 (Suppl. 1), S62–S68.
- Song, S.K., Sun, S.W., Ramsbottom, M.J., Chang, C., Russell, J., Cross, A.H., 2002. Demyelination revealed through MRI as increased radial (but unchanged axial) diffusion of water. *NeuroImage* 17, 1429–1436.
- Song, S.K., Sun, S.W., Ju, W.K., Lin, S.J., Cross, A.H., Neufeld, A.H., 2003. Diffusion tensor imaging detects and differentiates axon and myelin degeneration in mouse optic nerve after retinal ischemia. *NeuroImage* 20, 1714–1722.
- Song, S.K., Yoshino, J., Le, T.Q., Lin, S.J., Sun, S.W., Cross, A.H., et al., 2005. Demyelination increases radial diffusivity in corpus callosum of mouse brain. *NeuroImage* 26, 132–140.
- Stein, D.J., 2008. Emotional regulation: implications for the psychobiology of psychotherapy. *CNS Spectr.* 13, 195–198.
- van Ewijk, H., Heslenfeld, D.J., Zwiers, M.P., Buitelaar, J.K., Oosterlaan, J., 2012. Diffusion tensor imaging in attention deficit/hyperactivity disorder: a systematic review and meta-analysis. *Neurosci. Biobehav. Rev.* 36, 1093–1106.
- Villarreal, G., Hamilton, D.A., Graham, D.P., Driscoll, I., Qualls, C., Petropoulos, H., et al., 2004. Reduced area of the corpus callosum in posttraumatic stress disorder. *Psychiatry Res.* 131, 227–235.
- Weathers, F.W., Litz, B.T., Herman, D.S., Huska, J.A., Keane, T.M., 1993. The PTSD checklist: reliability, validity, & diagnostic utility. Annual Meeting of the International Society for Traumatic Stress Studies, San Antonio, TX.
- Wheeler-Kingshott, C.A., Cercignani, M., 2009. About “axial” and “radial” diffusivities. *Magn. Reson. Med.* 61, 1255–1260.
- Yin, Y., Jin, C., Hu, X., Duan, L., Li, Z., Song, M., et al., 2011a. Altered resting-state functional connectivity of thalamus in earthquake-induced posttraumatic stress

- disorder: a functional magnetic resonance imaging study. *Brain Res.* 1411, 98–107.
- Yin, Y., Li, L., Jin, C., Hu, X., Duan, L., Eyler, L.T., et al., 2011b. Abnormal baseline brain activity in posttraumatic stress disorder: a resting-state functional magnetic resonance imaging study. *Neurosci. Lett.* 498, 185–189.
- Yin, Y., Jin, C., Eyler, L.T., Jin, H., Hu, X., Duan, L., et al., 2012. Altered regional homogeneity in post-traumatic stress disorder: a resting-state functional magnetic resonance imaging study. *Neurosci. Bull.* 28, 541–549.
- Zhang, L., Zhang, Y., Li, L., Li, Z., Li, W., Ma, N., et al., 2011. Different white matter abnormalities between the first-episode, treatment-naïve patients with posttraumatic stress disorder and generalized anxiety disorder without comorbid conditions. *J. Affect. Disord.* 133, 294–299.
- Zhang, L., Li, W., Shu, N., Zheng, H., Zhang, Z., Zhang, Y., et al., 2012. Increased white matter integrity of posterior cingulate gyrus in the evolution of post-traumatic stress disorder. *Acta Neuropsychiatr.* 24, 34–42.