

Veterinary Record

Assessment of Cardiovascular Disease in the Donkey: Clinical, Echocardiographic and Pathologic Observations

Journal:	<i>Veterinary Record</i>
Manuscript ID	vetrec-2016-103733.R1
Article Type:	Paper
Date Submitted by the Author:	n/a
Complete List of Authors:	Roberts, Susan; SLR Cardiology Referrals, Plumpton Farm, Pecket Well, Dukes-McEwan, Joanna; University of Liverpool School of Veterinary Science, Leahurst Campus, Chester High Road
Abstract:	<p>The Donkey Sanctuary (DS) owns 3500 – 4000 donkeys, estimated to be about 35% of the UK population. Although post-mortem surveys suggest a high prevalence of cardiovascular disease in donkeys, there is sparse clinical information about cardiovascular examination findings and echocardiographic findings in health and disease. In this cross-sectional study, auscultation findings were recorded, and in a subset of donkeys, echocardiography was used to screen for structural and functional cardiac disease. 202 donkeys were examined; 117 geldings and 85 females. Heart sounds S1 and S2 were detected in all donkeys, but none had audible S3. S4 was detected in 9 (4.5%; significantly older than those without S4; $P < 0.001$). A heart murmur was detected in 4 donkeys. Echocardiography identified these to be due to a ventricular septal defect in one, and aortic regurgitation in 3. An additional 43 donkeys had echocardiography. A further 10 donkeys were identified to have aortic insufficiency, but no other valvular regurgitation. 76/202 donkeys subsequently underwent necropsy. Three showed degenerative aortic valve changes. One donkey had nodular lesions in the intima of proximal aorta and sinus of Valsalva. Histopathology showed multifocal chronic nodular eosinophilic arteritis, consistent with verminous arteritis. The DS pathology database identified other similar cases.</p>

SCHOLARONE™
Manuscripts

1
2
3
4
5
6
7
8
9
10
11
12
13
14
15
16
17
18
19
20
21
22
23
24
25
26
27
28
29
30
31
32
33
34
35
36
37
38
39
40
41
42
43
44
45
46
47
48
49
50
51
52
53
54
55
56
57
58
59
60

1
2 **Assessment of Cardiovascular Disease in the Donkey:**
3 **Clinical, Echocardiographic and Pathologic Observations**

6 Manuscript prepared for *Veterinary Record*

7 By

8 Susan L. Roberts¹

9 &

10 Joanna Dukes-McEwan²

11 *Author addresses:*

12 ¹ SLR Cardiology Referrals, Plumpton Farm, Pecket Well, Hebden Bridge, West
13 Yorkshire HX7 8QU

14 ² Small Animal Teaching Hospital, School of Veterinary Science, University of
15 Liverpool, Chester High Road, Neston, Cheshire CH64 7TE

16 JDMcE is corresponding author: J.Dukes-McEwan@liv.ac.uk

20 **Assessment of Cardiovascular Disease in the Donkey:**
21 **Clinical, Echocardiographic and Pathologic Observations**

22 **Abstract**

23 The Donkey Sanctuary (DS) owns 3500 – 4000 donkeys, estimated to be about 35% of the
24 UK population. Although post-mortem surveys suggest a high prevalence of cardiovascular
25 disease in donkeys, there is sparse clinical information about cardiovascular examination
26 findings and echocardiographic findings in health and disease. In this cross-sectional study,
27 auscultation findings were recorded, and in a subset of donkeys, echocardiography was
28 used to screen for structural and functional cardiac disease. 202 donkeys were examined;
29 117 geldings and 85 females. Heart sounds S1 and S2 were detected in all donkeys, but none
30 had audible S3. S4 was detected in 9 (4.5%; significantly older than those without S4;
31 $P < 0.001$). A heart murmur was detected in 4 donkeys. Echocardiography identified these to
32 be due to a ventricular septal defect in one, and aortic regurgitation in 3. An additional 43
33 donkeys had echocardiography. A further 10 donkeys were identified to have aortic
34 insufficiency, but no other valvular regurgitation. 76/202 donkeys subsequently underwent
35 necropsy. Three showed degenerative aortic valve changes. One donkey had nodular lesions
36 in the intima of proximal aorta and sinus of Valsalva. Histopathology showed multifocal
37 chronic nodular eosinophilic arteritis, consistent with verminous arteritis. The DS pathology
38 database identified other similar cases.

39
40 Key words:

41 *Equus asinus*, cardiac ultrasound, verminous arteritis, ventricular septal defect, aortic regurgitation

42

43 Introduction

44 The donkey (*Equus asinus*) is an important working animal in many areas of the world, but in the
45 U.K., donkeys are predominantly companion or leisure animals. The total number of donkeys
46 worldwide has been estimated as 44×10^6 but in the UK, estimated numbers are 10 000 (Starkey and
47 Starkey 1996). Approximately 35% of these UK donkeys are maintained by The Donkey Sanctuary
48 (DS), Devon.

49 Given the importance of this animal for work in many parts of the world there is a dearth of
50 information about the donkey and it is often wrongly treated as a small horse (Senior 2013). There
51 are publications about physiological variables for donkeys for working animals (Ayo and others 2008;
52 Maloiy and others 2003; Matthews and others 1998; Mueller and others 1994) including clinical
53 pathology reference data (Folch and others 1997; Palanivel and others 2008; Stanisic and others
54 2015). Parasitism is of considerable importance in this species, and a range of publications reflect
55 this (Asefa and others 2011; Bu and others 2009; Matthews and Burden 2013; Tolliver and others
56 1985; Uslu and Guclu 2007; Wells and others 1998). A large, retrospective review of post-mortem
57 results from 1444 sedentary donkeys (DS records) has recently provided valuable information about
58 the frequency of conditions resulting in donkey morbidity (Morrow and others 2011). The mean age
59 was 30.6 years, so geriatric diseases are likely to be over-represented. Valvular (33%) and
60 myocardial heart lesions (11.2%) were not infrequent (Morrow and others 2011), although severity
61 of these were not assessed. Since this survey reported pathological evidence of valvular heart
62 disease in one-third of donkeys, it is surprising that there is sparse clinical information regarding the
63 pre-mortem diagnosis of cardiac disease in donkeys, or the clinical relevance of lesions identified.
64 Heart murmurs and degenerative valvular disease are common in geriatric horses (Ireland and
65 others 2012; Sage 2002), particularly affecting the aortic valve (Else and Holmes 1972a). There are
66 individual case reports of pacemaker implantation in donkeys with third degree atrioventricular

1
2
3 67 block (Pibarot and others 1993) and a published letter about cardiac myopathy in a donkey foal
4
5 68 (Dyson 1975).
6
7

8 69 Echocardiography is increasingly available as a tool to non-invasively screen for or diagnose cardiac
9
10 70 disease in all species. Echocardiographic studies of healthy donkeys have been published in the
11
12 71 literature to provide reference intervals (Amory and others 2004; Delvaux and others 2001; Hassan
13
14 72 and Torad 2015), but information about structural or functional cardiac disease is lacking in this
15
16 73 species, particularly in geriatric donkeys.
17
18

19 74 In the pathological survey (Morrow and others 2011), the prevalence of aneurysms was 43.1%
20
21 75 (typically the cranial mediastinal artery) and prevalence of other vascular disease was 60.9%, with
22
23 76 both occurring together in some animals (32.9%). Whether vascular disease is an ageing change in
24
25 77 donkeys, or is associated with Strongyle infestation as in horses (Else and Holmes 1972a) is not clear.
26
27

28
29 78 The aims of this observational, cross-sectional study were therefore (i) to screen a selection of
30
31 79 apparently healthy, sedentary donkeys at the DS over a wide age range and to document
32
33 80 auscultation findings including presence and frequency of arrhythmias and heart murmurs, (ii) to use
34
35 81 echocardiography to screen for structural or functional heart disease in those with murmurs and a
36
37 82 subset without, (iii) to review The Donkey Sanctuary Pathology Database for evidence and
38
39 83 prevalence of cardiac and vascular disease, including some donkeys assessed by echocardiography.
40
41 84 Finally, we wanted to compare veterinarians' perceptions of the importance of heart disease in
42
43 85 donkeys with the frequency of heart disease identified in this population at the DS.
44
45
46

47 86

48
49 87

50
51 88
52
53
54
55
56
57
58
59
60

1
2
3 89 **Materials and Methods**
4

5
6 90 *Donkeys and environment*
7

8
9 91 Donkeys were owned by the DS, near Sidmouth, Devon, UK. They were maintained in groups, under
10
11 92 similar conditions and management, housed in barns, with free access to an outdoor yard and
12
13 93 grazing. Individuals were identified by name and number on collars. Clinical records for each donkey
14
15 94 were available, since their arrival time at the DS. Age, gender and weight were retrieved. Current
16
17 95 diet, whether on supplemental feed, recent faecal egg count and concurrent illnesses were all noted.
18
19 96 Donkeys were examined by one observer (SLR) between over two visits in February 2010 (4 days)
20
21 97 and October 2012 (3 days).
22
23

24
25 98 *Physical examination and auscultation*
26

27
28 99 Individual donkeys were randomly selected based on their natural curiosity and willingness to be
29
30 100 approached and examined by the examiner. The examinations were carried out during quiet periods,
31
32 101 at a time when the donkeys were not being fed or otherwise handled. The weather was calm and
33
34 102 dry, without wind.
35

36
37 103 Information recorded included demeanour, body condition score, respiratory rate and effort.
38
39 104 Cardiac auscultation was systematically carried out (Blissitt 2010) using a Littman Cardiology III
40
41 105 stethoscope over 5 – 10 minutes. The coat was not clipped or shaved prior to auscultation. Pulse
42
43 106 quality was assessed from the facial artery. Heart rate and rhythm were recorded. The heart sounds
44
45 107 detected (S1, S2, S3, S4) were noted for each case. The presence of any heart murmur was noted,
46
47 108 and characterised by point of maximal intensity, grade of murmur (out of 6, Levine classification
48
49 109 (Patteson and Cripps 1993) and timing. Body condition score out of 5 was determined (Svendson
50
51 110 2008).
52

53
54
55 111 *2 Dimensional (2D) and colour flow Doppler echocardiography (CFDE)*
56
57
58
59
60

1
2
3 112 2D and CFDE was performed to investigate heart murmurs detected and to assess presence of
4
5 113 clinically silent cardiac lesions. All donkeys with murmurs were included, and 43 donkeys with
6
7 114 normal auscultation results were randomly selected from the population. Transthoracic
8
9 115 echocardiography was performed using an Esaote MyLab30 Vet Gold ultrasound machine with a 2.5-
10
11 116 3.5 MHz phased array sector transducer. Right parasternal standard cardiac 2D views were obtained
12
13 117 in standing donkeys as previously described for horses (Marr and Patteson 2010), after clipping and
14
15 118 applying gel. An electrocardiogram was simultaneously acquired to time cardiac events. The
16
17 119 presence of structural heart disease and cardiac remodelling was assessed by 2D echocardiography.
18
19
20 120 CFDE was used to screen for the presence of any turbulent flow, indicated by the presence of colour
21
22 121 variance. Each valve was interrogated, to identify the presence of valvular regurgitation and the
23
24 122 inter-atrial septum and interventricular septum were assessed for shunting congenital heart defects
25
26 123 (Marr and Patteson 2010; Marr and Reef 1995; Reef 1995). Severity of aortic regurgitation was semi-
27
28 124 quantitatively assessed by jet area and estimating width of the aortic jet at its origin compared with
29
30 125 aortic annulus diameter (Marr 2010b; Reef and others 2014).

31 32 33 34 126 *Pathology*

35
36
37 127 Some of the donkeys in the auscultation part of the study which died or were euthanased,
38
39 128 underwent full post-mortem examination at the DS as previously described (Morrow and others
40
41 129 2011). Cause of death / euthanasia was retrieved and post-mortem reports reviewed, particularly in
42
43 130 regard to cardiac or vascular lesions.

44
45
46 131 The full DS pathology archive of all post-mortem examinations of donkeys which died / were
47
48 132 euthanased between 2006 and 2010 was searched for "cardiac lesions" and cardiac death, and
49
50 133 numbers of cases retrieved.

51 52 53 54 134 *Questionnaire*

1
2
3 135 To investigate the opinions of practising veterinary surgeons working in 12 equine, large animal or
4
5 136 mixed veterinary practices from different geographical regions on whether cardiac disease is a
6
7 137 significant problem in pet donkeys, a survey was sent out. A total of 104 veterinary surgeons were
8
9 138 invited to participate.

10
11
12 139 *Statistical methods*

13
14
15 140 Data were recorded in an Excel spreadsheet. Data were imported into SigmaPlot 13.0 for Windows
16
17 141 (Systat software Inc.). Basic descriptive data are reported as means and standard deviation if data
18
19 142 were normally distributed or as medians (minimum – maximum) if not. The Shapiro-Wilk test was
20
21 143 used to assess for normality. Comparisons between males and females used the Student's unpaired
22
23 144 two-tailed T-test for normally distributed data, or the Mann-Whitney test for non-normal
24
25 145 distribution of data. Linear regression was used to explore associations between sets of variables.

26
27
28
29 146 For the questionnaire data, Chi squared analysis was used to assess the opinions of veterinarians as
30
31 147 to the importance of clinically evident heart disease in donkeys (yes / no) with experience of
32
33 148 examining donkeys (0, <6 and >6 donkeys/year).

34
35
36 149 A P value of <0.05 was accepted as representing statistical significance.

37
38
39 150

40
41
42
43 151
44
45
46
47
48
49
50
51
52
53
54
55
56
57
58
59
60

1
2
3 152 **Results**
4
5

6 153 *The donkey population evaluated*
7
8

9 154 A total of 202 donkeys underwent physical examination by auscultation. There were 117 males (all
10
11 geldings) and 85 females. The ages, weights and body condition scores of donkeys are given in Table
12
13 1. There was no significant difference in ages between the genders, but females were significantly
14
15 lighter, despite having a larger weight range than the geldings (Table 1; Figure 1); BCS was not
16
17 significantly different between genders. Respiratory rate counted prior to handling in the
18
19 auscultated donkeys was 20 breaths / minute, with no difference between males and females (Table
20
21 1). Respiratory rate showed a negative association with body weight and a positive association with
22
23 advancing age (Table 2; Figures 2A, 2B).
24
25
26

27 162 *Auscultation findings and echocardiographic assessment of heart murmurs*
28
29

30 163 The median heart rate was 40 bpm (range 36 – 80 bpm) for the whole population, with no significant
31
32 difference between the genders (Table 1). There was a weak positive association between heart rate
33
34 and respiratory rate (Table 2; Figure 2C). The predominant heart rhythm evident on auscultation was
35
36 regular sinus rhythm. In three donkeys, occasional second degree atrioventricular block was
37
38 identified. No donkey had a pathological arrhythmia identified. All donkeys had S1 and S2 heart
39
40 sounds clearly audible. S3 was not detected in any donkey. Only nine donkeys (4.5%) had an audible
41
42 S4; five geldings and four females. The mean age of the donkeys with audible S4 (33.78 ± 3.90 years)
43
44 was significantly older than those without (24.45 ± 8.00 years) ($P < 0.001$).
45
46
47

48 171 A heart murmur was identified in 4 donkeys. One 10 year old gelding had a bilateral grade 2/6,
49
50 basilar early to mid-systolic murmur, without any diastolic component. On investigation by
51
52 echocardiography, this was confirmed to be due to a restrictive ventricular septal defect (VSD)
53
54 (Figure 3A) associated with aortic prolapse (Figure 3B), but no significant aortic regurgitation. Peak
55
56 VSD velocity recorded was 3.8 m/s, despite lack of optimal alignment with the VSD jet, suggesting
57
58
59
60

1
2
3 176 preserved normal left ventricular to right ventricular pressure gradient. The other three, all geldings,
4
5 177 aged 28, 29 and 35 years old, all had left basilar diastolic decrescendo murmurs, graded 2, 3 and 5/6
6
7 178 respectively, confirmed on echocardiography to be due to aortic regurgitation (moderate in two,
8
9 179 severe in the donkey with the grade 5/6 murmur) (Figure 4A; 4B). Pulse quality was considered
10
11 180 normal in each. These three all had sinus rhythm, with heart rates of 40, 40 and 66 bpm respectively.
12
13 181 One of these donkeys, the 35 year old with a widely radiating grade 5/6 diastolic murmur due to
14
15 182 severe aortic regurgitation was subsequently euthanased and underwent necropsy, confirming
16
17 183 aortic valve thickening (Figure 5A), consistent with degenerative valvular disease (Else and Holmes
18
19 184 1972a).

20
21
22
23 185 *Echocardiographic findings*

24
25
26 186 An additional 43 donkeys which had not had any cardiac auscultation abnormality, from the original
27
28 187 202 donkeys, also underwent 2D and CFDE. A total of 21.7 % of auscultation-normal donkeys were
29
30 188 therefore examined. The simultaneously acquired ECG showed regular sinus rhythm in 46/47
31
32 189 donkeys, and one donkey (auscultation normal) showed occasional, physiological, 2nd degree
33
34 190 atrioventricular block. Normal 2D and CFDE examinations were recorded in 33 (76.7%). Ten donkeys
35
36 191 (five geldings; five females) were identified to have aortic insufficiency (Aoi) (23.3%) in the absence
37
38 192 of an audible diastolic heart murmur. Aoi was mild in nine cases and one case had moderate Aoi.
39
40 193 Aortic valve abnormalities in a total of four cases were identified on 2D echo of those with Aoi on
41
42 194 CFDE, with aortic valve prolapse of the right coronary cusp in one mild case and aortic valve
43
44 195 thickening and increased echogenicity in all four.

45
46
47
48 196 Of these 10 cases with CFDE Aoi, eight donkeys underwent subsequent post-mortem examination.
49
50 197 Two donkeys had thickened aortic valves coded at post-mortem examination, which had also been
51
52 198 noted on echocardiography (including the moderate case), but two did not.
53
54
55
56
57
58
59
60

1
2
3 199 When heart murmur free Aol donkeys (N=10) were compared with heart murmur free normal echo
4
5 200 donkeys (N=33), the Aol donkeys tended to be older (median age 29; range 25 – 44 years versus
6
7 201 median age 23; range 3 – 45 years) but this did not achieve statistical significance (P=0.107).
8
9 202 Including the three donkeys with diastolic murmurs associated with Aol (median age 29 years), the
10
11 203 older age of the Aol donkeys was still not statistically significant (P=0.077). There was no difference
12
13 204 in weight (P=0.730) or heart rate (P=0.593) between the groups.

14
15
16
17 205 No mitral, tricuspid or pulmonic regurgitation was identified in any of the donkeys by CFDE from
18
19 206 these right parasternal views.

20 21 22 207 *Pathology*

23
24
25 208 Out of the 202 donkeys auscultated, 76 (37.6%) underwent full post-mortem examination. Five had
26
27 209 died under treatment or were found dead, and 71 had been euthanased for various reasons (Table
28
29 210 3), with the major reasons for death or euthanasia identified at post-mortem being liver disease,
30
31 211 colic or gastro-intestinal conditions and respiratory diseases. Of the post-mortem examination
32
33 212 population, there were 39 geldings and 37 females.

34
35
36 213 Of the 76 donkeys with post-mortem data, 12 had prior echocardiography as part of this study. The
37
38 214 echocardiography was normal in three and showed Aol in 9 out of the 12 (1 severe, 1 moderate and
39
40 215 7 mild cases). Post-mortem coding of “thickened aortic valve” was only reported in three of these
41
42 216 cases (1 severe (Figure 5B), 1 moderate and 1 mild case). Aortic valve thickening was not reported in
43
44 217 the three echocardiographically normal cases, but one 40 year old gelding (Figure 6A) from the echo-
45
46 218 normal group had nodular lesions within the proximal aorta including the sinus of Valsalva and sinus
47
48 219 aspect of the aortic valves themselves (Figures 6B; 6C).

49
50
51
52 220 Histopathology was obtained from these lesions (Figure 7A-C), which showed multifocal chronic
53
54 221 nodular eosinophilic arteritis with chronic intimal fibrosis (arteriosclerosis) and intra-lesional
55
56 222 mineralization consistent with chronic degenerative disease of the intima. Although parasites were
57
58
59
60

1
2
3 223 not evident in the sections, the lesions were most suggestive of chronic arteriosclerotic plaques
4
5 224 described in other species (including horses) due to verminous arteritis (Else and Holmes 1972a). No
6
7 225 gross myocardial lesions were identified, but systematic myocardial histopathology was not carried
8
9 226 out.

10
11 227 From the full pathology archive from necropsies carried out at the DS, the total number of post-
12
13 228 mortems and the number of donkeys identified with "cardiac lesions" as a major code are noted by
14
15 229 year (2006 – 2010) in Table 4. These were either valvular or vascular; myocardial lesions were not
16
17 230 coded as a major finding in these numbers. Similar nodular lesions within the proximal aorta as
18
19 231 described above were reported.
20
21
22

23 232

24
25
26
27 233 *Questionnaire*

28
29 234 A total of 35 respondents out of 104 invitations (response rate 33.7%) replied to the questionnaire
30
31 235 regarding opinions and familiarity with donkeys and heart disease in donkeys (data shown in Figure
32
33 236 8). Only 25 vets reported examining a total of 176 donkeys over the preceding year. Only one vet
34
35 237 reported the presence of a heart murmur in a single donkey, and none of the respondents had
36
37 238 treated cardiac disease in this species. However, of the vets treating donkeys, 10/25 vets considered
38
39 239 that donkeys were subject to cardiac disease and 15/25 did not. The vets seeing more donkeys
40
41 240 (average 7.9 donkeys/vet/year) thought that cardiac disease was not common, in contrast to those
42
43 241 who did consider it a clinical problem (average 5.8 donkeys/vet/year). However, there was no
44
45 242 statistically significant difference between vets considering heart disease was important (yes / no)
46
47 243 and whether they examined >6, <6 or 0 donkeys a year (P=0.187).
48
49
50

51
52 244

53
54
55 245
56
57
58
59
60

1
2
3
4
5
6
7
8
9
10
11
12
13
14
15
16
17
18
19
20
21
22
23
24
25
26
27
28
29
30
31
32
33
34
35
36
37
38
39
40
41
42
43
44
45
46
47
48
49
50
51
52
53
54
55
56
57
58
59
60

246

Confidential: For Review Only

247 **Discussion**

248 This study identified a low prevalence of clinically important cardiac disease across a wide age range
249 in this representative subset of the UK donkey population (estimated to be 5 – 6% of the total cared
250 for by the DS). Both echocardiography and post-mortem examination identified degenerative
251 valvular disease, particularly affecting the aortic valve, similar to horses. This tended to be in older
252 donkeys although this did not achieve statistical significance, likely due to low numbers.

253 The physical examination findings, in particular heart rate and respiratory rate, are in accordance
254 with other publications from healthy, non-working (Delvaux and others 2001; Svendsen 2008) and
255 working (Ayo and others 2008) donkeys. Sinus arrhythmia was not identified in any donkey in our
256 study, in contrast to 39% of donkeys (2 – 18 years old) reported by Delvaux and others (2001).
257 Second degree atrioventricular block was documented in three donkeys, but not reported in any of
258 the 22 in the Delvaux and colleagues' (2001) study. The association between heart rate and
259 respiratory rate may merely reflect stress level. The association between respiratory rate and
260 advancing age may reflect concurrent respiratory disease such as pulmonary fibrosis (Thiemann
261 2012).

262 S4 was detected in 9 donkeys, which were significantly older than donkeys without an audible S4.
263 This is consistent with the findings in humans, where S4 is reported in a total of 15.6% healthy
264 subjects, but increasing age increased the odds of S4 being detected (Collins and others 2005). With
265 ageing in human patients, the left ventricle is less able to relax and ventricular filling is more
266 dependent on atrial contraction, which may explain this finding (Lewis and Maron 1992). Detection
267 of the transient S3 and S4 sounds is common in horses, but less common in ponies (Blissitt 2010). S3
268 was not detected in any donkey in this study. The presence of S3 and S4 was not commented on in
269 other studies in donkeys (Amory and others 2004; Delvaux and others 2001; Svendsen 2008).

1
2
3 270 In this population, only 4 donkeys had murmurs identified on cardiac auscultation (2.0%). One of
4
5 271 these was identified with a VSD. This is a fairly common congenital heart defect in foals and adult
6
7 272 horses and ponies (Hall and others 2010; Marr 1999, 2010a; Reef 1995). The authors are unaware of
8
9 273 published case reports about VSD in donkeys.
10

11
12 274 In three aged donkeys (1.5%), aortic insufficiency was identified by presence of a heart murmur,
13
14 275 confirmed by Doppler echocardiography and, in one, confirmed as being associated with
15
16 276 degenerative valvular disease on post-mortem. The prevalence is slightly less than that reported for
17
18 277 older horses (Marr 2010b; Patteson and Cripps 1993), but the pathology in donkeys (Morrow and
19
20 278 others 2011) is similar to that described for horses (Else and Holmes 1972a). None of the donkeys
21
22 279 had other clinical signs consistent with haemodynamically significant aortic regurgitation (Reef and
23
24 280 others 2014).
25
26
27

28 281 Heart murmurs appeared to be much less common than in horses (Patteson and Cripps 1993), but
29
30 282 when present, in the four donkeys here, the murmur did reflect the presence of structural cardiac
31
32 283 disease. Of particular note is that we did not identify the ejection or flow murmurs recognised
33
34 284 frequently in thoroughbred horses (Kriz and others 2000; Patteson and Cripps 1993). This may be
35
36 285 related to the sedentary lifestyle of donkeys at the DS compared with athletic horses. This is in
37
38 286 contrast to the ejection-type murmurs identified in 9/22 (41%) of donkeys in another study (Amory
39
40 287 and others 2004). Heart murmurs were not mentioned in another echocardiography study of
41
42 288 working donkeys (Hassan and Torad 2015). In geriatric horses, 20% prevalence of heart murmurs
43
44 289 (Ireland and others 2012), is much higher than this study. Three of the four donkeys with a heart
45
46 290 murmur were less than the median weight of the gelding population (Table 1; weighing 142, 148 and
47
48 291 156 kg respectively; the heaviest weighed 184 kg). Speculatively, murmurs may be less likely to be
49
50 292 detected in over-weight donkeys, and those with thick hair-coats.
51
52
53

54
55 293 CFDE identified AoI without an audible diastolic heart murmur, confirming its superior sensitivity
56
57 294 over auscultation (Blissitt and Bonagura 1995). Of note, no mitral, tricuspid or pulmonic
58
59
60

1
2
3 295 regurgitation was identified in this study. Valvular incompetence in donkeys may be much less
4
5 296 prevalent than in horses (Blissitt and Bonagura 1995; Kriz and others 2000; Marr 2010b). However,
6
7 297 CFDE was only carried out from right parasternal views, and if also carried out from the left
8
9 298 hemithorax, it is possible that more valvular incompetence would have been identified.

10
11
12 299 Only 12 donkeys underwent both echocardiography and post-mortem examination. For the three
13
14 300 echo-normal cases, no aortic valvular pathology was noted. However, nine donkeys had Aoi
15
16 301 identified on echocardiography, but only in the severe, the moderate and in one out of the 7 mild
17
18 302 cases classified by echocardiography, was gross aortic valve thickening documented at post-mortem.
19
20 303 This indicates that there may be functional aortic regurgitation prior to any gross pathology, as
21
22 304 reported in horses (Blissitt and Bonagura 1995; Marr 2010b).

23
24
25
26 305 The retrieved post-mortem records of the donkeys from this study were very brief, and some
27
28 306 referred to more than one body system affected by pathology, but only the major finding was
29
30 307 recorded in Table 3. Liver disease, gastro-intestinal disease and respiratory conditions were most
31
32 308 frequent in this group of donkeys, and were also identified as being significant in another post-
33
34 309 mortem survey from the DS (Morrow and others 2011). Often, euthanasia decisions were based on
35
36 310 multiple co-morbidities affecting quality of life of each donkey. Unfortunately, we only had brief
37
38 311 coding records of the cause of death and post-mortem findings, which likely led to some differences
39
40 312 between this report and the study of Morrow and colleagues (2011). Vascular lesions were
41
42 313 commonly identified in the Morrow and others (2011) study but was only coded in one case in our
43
44 314 study. Similarly, only one case had cardiac disease listed as the most important post-mortem finding
45
46 315 in our study (the case with severe aortic regurgitation) although aortic valve thickening was recorded
47
48 316 in a total of four donkeys (9.2%). The severe aortic regurgitation case, and the single case where
49
50 317 vascular disease was coded as the major post-mortem finding (the 40 year old with proximal aortic
51
52 318 nodular lesions) were euthanized due to other quality of life issues, including laminitis, arthritis and
53
54 319 reduced appetite rather than their cardiovascular conditions. Morrow and others (2011) reported a
55
56
57
58
59
60

1
2
3 320 prevalence of 33% with valvular disease. The differences are likely due to differing goals. In our
4
5 321 study, we only retrieved the pathology major codes and cause of death, and did not retrieve detail of
6
7 322 the post-mortem findings, but the goal of the Morrow and colleagues (2011) was to categorise all
8
9 323 the conditions identified at necropsy.

10
11
12 324 The raised granulomatous lesions identified in the proximal aorta in one case in this study, and from
13
14 325 more donkeys from the archive were thought to reflect verminous arteritis by the pathologist's
15
16 326 report, even though no parasites were identified. Similar lesions were also described by Morrow and
17
18 327 colleagues (2011), although their cause was not attributed to prior parasitism such as *Strongylus*
19
20 328 *vasorum* infestation. There was a strong association between vascular lesions and aneurysm,
21
22 329 particularly of the cranial mesenteric artery, speculated to be associated with ageing, possibly
23
24 330 because endoparasites were apparently uncommon in that study (Morrow and others 2011). The
25
26 331 location, gross pathology and histopathology findings are strikingly similar to those described in
27
28 332 horses (Else and Holmes 1972a, b), associated with previous *Strongylus vulgaris* migration, as also
29
30 333 shown with experimental infestation (Duncan and Pirie 1975). There is also a strong association
31
32 334 described between Strongylosis and myocardial lesions (Cranley and McCullagh 1981). *Strongylus*
33
34 335 *vulgaris* affects donkeys, including the cranial mesenteric artery (Asefa and others 2011; Tolliver and
35
36 336 others 1985). However, to the authors' knowledge, the association of the proximal aortic nodular
37
38 337 lesions and Strongylosis has not previously been documented in donkeys, despite evidence in horses
39
40 338 (Else and Holmes 1972a).

41
42
43
44
45 339 The percentage of donkeys recorded in the pathology archive over each year with "cardiac lesions"
46
47 340 as a major code was very high (approximately 70% per year). However, this includes any
48
49 341 cardiovascular pathology, including the vascular lesions (arteriosclerosis, aortic lesions, aneurysms)
50
51 342 as well as valvular and myocardial lesions, so these data are likely similar to those of (Morrow and
52
53 343 others 2011). That study ranged from 2001-2008, so there will be overlap between the two studies.
54
55 344 In the data presented here, any cardiac or vascular lesion considered to be minor would not have
56
57
58
59
60

1
2
3 345 been retrieved, and vascular lesions more peripheral than the proximal aorta would also not have
4
5 346 been included, and so the numbers in table 4 likely under-represent the frequency of these findings.
6
7

8 347 The questionnaire showed that this small group of veterinary surgeons had very little experience
9
10 348 with pet donkeys, with only 25/35 vets examining this species and the maximum number of donkeys
11
12 349 seen per year by one vet was 35, but the respondents saw a median of 3 donkeys a year. Despite
13
14 350 this, a minority of vets considered that clinically detectable heart disease may be a problem in the
15
16 351 species, ranging from 30% (vets not examining donkeys) to 40% (vets examining donkeys). In fact,
17
18 352 the vets examining more donkeys (average 7.9/vet) were less likely to consider that heart disease
19
20 353 was significant than those examining fewer donkeys (average 5.9/vet). Only one out of a total of 176
21
22 354 donkeys examined was identified with a heart murmur and none were treated for cardiac disease.
23
24 355 These results are intriguing, as they show most vets expect a much higher frequency of clinically
25
26 356 detectable heart disease than was actually diagnosed, or that the authors identified in the DS
27
28 357 population of donkeys. The survey of vets also confirms the dearth of veterinary literature about
29
30 358 cardiac disease in donkeys, or lack of knowledge of sources of information. Three vets cited the
31
32 359 Professional Handbook of the Donkey (Svendsen 2008) as their primary reference, but clinical heart
33
34 360 disease is not mentioned in this text, although aortic valvular pathology is.
35
36
37
38

39 361 There are a number of limitations to this study. Only one observer carried out the auscultation and
40
41 362 echocardiography, therefore inter-observer agreement or variation could not be determined.
42
43 363 Auscultation and the detection of quiet heart murmurs can be affected by a number of factors,
44
45 364 including environmental noise (minimised as far as possible), stethoscope quality and hearing acuity.
46
47 365 Donkeys have thicker skin and hair coat than horses, tended to have increased fat, and also have a
48
49 366 thicker cutaneous colli muscle, all of which may make auscultation less rewarding than in horses. It is
50
51 367 therefore certainly possible that quieter murmurs could be missed. In addition, the donkey with a
52
53 368 restrictive VSD, expected to have a loud right sided systolic heart murmur, only had a grade 2/6
54
55 369 murmur noted, which supports the "muffling" effects of the chest wall on auscultation.
56
57
58
59
60

1
2
3 370 Echocardiography only included the right sided views to identify CFDE evidence of valvular
4
5 371 regurgitations, and the left sided views may have added greater sensitivity. Only a small proportion
6
7 372 of the donkeys which underwent echocardiography also had necropsy, and we could not provide
8
9 373 gross pathology and echocardiography images from many of the same cases, as pathology
10
11 374 photographs were not routinely obtained. Finally, review of the pathology archive was dependent
12
13 375 on the major coding applied at that time of necropsy, so lesions considered less significant or minor
14
15 376 would not have been retrieved. This likely explains differences between this study and the
16
17 377 systematic categorization of all pathological lesions by Morrow and colleagues (2011).
18
19
20
21 378
22
23
24 379
25
26
27 380 **Conclusions**
28
29
30 381 This cross-sectional study shows that donkeys may be affected by congenital and acquired
31
32 382 degenerative valvular disease, but no donkey in this study showed significant cardiac
33
34 383 remodelling or clinically relevant disease. Heart murmurs reflect structural heart disease.
35
36 384 Peripheral vascular disease, with intimal nodular lesions, can affect the proximal aorta,
37
38 385 thought to reflect prior and probably extinct Strongyle infestation.
39
40
41
42
43 386
44
45
46 387
47
48
49 388
50
51
52
53
54
55
56
57
58
59
60

1
2
3 389 **Acknowledgements**
4
5

6 390 This study was carried out with the support of The Donkey Sanctuary in Sidmouth, Devon with
7
8 391 permission and approval of The Board of Trustees, and the authors are extremely grateful for their
9
10 392 cooperation. We are also indebted to all the veterinary and support staff at The Donkey Sanctuary
11 393 without whom data collection would have been impossible.

12
13 394 In particular, we acknowledge Dr Faith Burden and Dr Getachew Mulugeta from The Donkey
14
15 395 Sanctuary, and Michael Rozmanec at Cytopath Ltd for permissions to use the images of donkey
16
17 396 aortic pathology and histopathology, and for their pathological expertise. We also thank Dr. Faith
18 397 Burden for her constructive criticism of this manuscript.

19
20 398

21
22 399
23
24
25
26
27
28
29
30
31
32
33
34
35
36
37
38
39
40
41
42
43
44
45
46
47
48
49
50
51
52
53
54
55
56
57
58
59
60

400 Tables

401 Table 1: Population description for the auscultated donkeys (n=202)

402

	All	Geldings	Females	P value between G/F
Weight (kg) Median (range)	176 (119 – 363)	180 (124 – 277)	170 (119 – 363)	P=0.014
BCS (/5) Median (range) (no. with data)	3.5 (1-5) (n=170)	3.5 (1-5) (n=102)	3.5 (2.5-5) (n=68)	P=0.481
Age (years) (mean \pm sd) (Min-Max)	24.86 \pm 8.09 (3 – 45)	24.43 \pm 8.73 (3 – 45)	25.47 \pm 7.12 (6 – 40)	P=0.367
Heart rate (bpm) Median (Range)	40 (36 – 80)	40 (36 – 80)	40 (36 – 80)	P=0.223
Respiratory rate (breaths per minute) Median (Range)	20 (15 – 30)	20 (15 – 30)	20 (16-30)	P=0.667

403

404 Abbreviations: BCS: body condition score, no.: number, sd: standard deviation, Min:
405 minimum value, Max: maximum value, bpm: beats per minute.

406 **Table 2: Associations between physiological variables in the auscultated**
407 **donkey population**

408

Association	R value	R ²	P value	Linear regression equation
Age and respiratory rate	0.393	0.154	P< 0.001	RR = 17.230 + (0.129 * AGE years)
Weight and respiratory rate	0.273	0.075	P= 0.001	RR = 21.761 - (0.00727 * WEIGHT kg)
Heart rate and respiratory rate	0.237	0.056	P< 0.001	RR = 16.928 + (0.0780 * HEART RATE)

409

410 Corresponding graphs are shown in Figure 2.

411

412

Table 3: Donkeys undergoing post-mortem examination (N=76)

413

Major post-mortem finding or cause of death	No. of cases (%)	Major post-mortem finding or cause of death	No. of cases
Cardiac	1 (1.3%)	Laminitis / feet	4 (5.3%)
Vascular	1 (1.3%)	Arthritis	7 (9.2%)
Respiratory	13 (17.1%)	Neurological	3 (3.9%)
Hepatopathy	15 (19.7%)	Collapse	1 (1.3%)
Colic / Gastro-intestinal	14 (18.4%)	Weight loss	3 (3.9%)
Dental	4 (5.3%)	Dull / anorexic	7 (9.2%)
Hyperlipidaemia	2 (2.6%)	Other	1 (1.3%) (ovarian torsion as cause of collapse)

414

415

416

417

418

419 **Table 4: Numbers of donkeys identified with “cardiac lesions” as a major code by year**
 420 **compared with numbers of deaths and numbers of necropsies**

421 *(Reproduced with permission of The Donkey Sanctuary)*

422

Year	Total died	Total necropsied	Cardiac lesions identified
2006	390	305	209 (68%)
2007	393	289	227 (78%)
2009	381	303	224 (73%)
2009	394	294	214 (72%)
2010	395	260	184 (70%)
TOTAL	1953	1451	1058 (73%)

423

424

425

1
2
3 426 **Figure Legends**
4
5

6 427 **Figure 1: Weight distribution between females and geldings**
7

8
9 428 Box and Whisker plots, with box defining the 25th and 75th percentile (median line included),
10
11 429 and whiskers indicating the 10th and 90th percentiles; outlying data points shown. (P=0.014)
12
13

14
15 430

16
17
18 431 **Figure 2. Associations with respiratory rate, by linear regression analyses**
19

20
21 432 For all graphs, the regression line is shown, with 95% confidence intervals for the line, and
22
23 433 95% prediction intervals for the data. For R² and P values, see Table 2.
24
25

26
27 434 **2A. Association between respiratory rate and body weight.**
28

29
30 435 **2B. Association between respiratory rate and age.**
31

32
33 436 **2C. Association between respiratory rate and heart rate.**
34
35

36
37 437
38

39 438 **Figure 3: Ventricular Septal Defect (VSD) in a donkey gelding (10 years old):**
40

41
42 439 **A.** Right parasternal long axis view including left ventricular outflow tract (LVOT) during
43
44 440 systole, optimised to show flow through the VSD by colour flow Doppler echocardiography.
45

46
47 441 The * shows turbulent flow cross the interventricular septum into the right ventricle (RV).
48
49

50
51 442 **B.** Right parasternal view including aorta; early diastolic frame showing prolapse of the right
52
53 443 coronary cusp of the aortic valve (yellow arrow). The cusp prolapses into the left ventricular
54

55 444 outflow tract (LVOT) beyond the annulus hinge-point. Ao: proximal aorta.
56
57
58
59
60

1
2
3 445
4
5

6 446 **Figure 4. Echo images from a 35 year old donkey gelding with severe aortic regurgitation**
7
8 447 **with grade 5/6 diastolic murmur.**

9
10
11 448 **A.** Right parasternal long axis view including the left ventricular outflow tract, with colour
12
13 449 flow echocardiography during diastole showing the eccentric jet of aortic regurgitation. LV:
14
15 450 left ventricle, Ao: proximal aorta, LA: left atrium. The aortic regurgitation affects the
16
17 451 anterior mitral valve leaflet.

18
19
20
21
22 452 **B.** M-mode echocardiogram at mitral valve level of the same donkey with aortic
23
24 453 regurgitation as in A; this shows diastolic flutter (yellow arrows) of open anterior leaflet of
25
26 454 the mitral valve, between the E and A peaks, as a consequence of aortic regurgitation. IVS:
27
28 455 interventricular septum. LVFW: left ventricular free-wall.

29
30
31
32 456
33
34

35 457 **Figure 5. Aortic valvular lesions**

36
37
38 458 **A.** Right parasternal long axis echocardiographic image from a 35 year old gelding,
39
40 459 optimised to illustrate nodular thickening of the aortic valve, which was associated with
41
42 460 aortic regurgitation. LV: left ventricle, Ao: proximal aorta. **B.** Gross pathology image
43
44 461 from the same donkey (euthanased for quality of life reasons, associated with dental
45
46 462 disease and chronic laminitis). One of the aortic valves cusps is thickened (yellow arrow),
47
48 463 and was associated with moderate aortic insufficiency. A small nodular lesion can also
49
50 464 be seen on the sinus aspect of another (non-thickened) cusp.

51
52
53
54
55
56 465
57
58
59
60

1
2
3 466 **Figure 6. Proximal aortic intimal nodular lesions**
4
5

6 467 **A.** Right parasternal long axis echocardiographic image from a 40 year old gelding
7
8 468 showing no apparent major aortic valve pathology, and there was no aortic
9
10 469 regurgitation.
11

12
13
14 470 **B, C.** Gross pathology of the sinus aspect of the aortic valves (**B**) and proximal aorta (**C**)
15
16 471 and from the same 40 year old echo-normal gelding, showing nodular lesions. The
17
18 472 thickened region of tip of the cusp close to the forceps (**C**) is a normal anatomical
19
20 473 finding, the nodes of the semilunar cusps, at the point of apposition of the three
21
22 474 cusps. The pathological nodules are deep within the sinus of Valsalva.
23
24
25

26 475

27
28
29 476 **Figure 7. Histopathology of nodular lesions** as in Figure 6B, 6C. Histopathology images
30
31 477 courtesy of and with full permissions of Michael Rozmanec; Cytopath Ltd.
32
33

34 478 **A.** H and E stained, paraffin embedded section of artery. Large arrows indicate the
35
36 479 expanded lamina intima of the vessel wall. Small arrows indicate degenerate
37
38 480 mineralised foci. Size bar = 500 μ m.
39

40
41 481 **B.** H and E stained, paraffin embedded section of artery. Black arrow indicates focus of
42
43 482 vascular intima mineralisation. Red arrows indicate adjacent fibrocartilaginous /
44
45 483 chondroid metaplasia. Size bar = 500 μ m.
46

47
48 484 **C.** H and E stained, paraffin embedded section of artery. Black arrows indicate the
49
50 485 junction between lamina intima and media of the blood vessel. The degenerate foci
51
52 486 contain amorphous to granular eosinophilic coagulum – possible degenerate
53
54 487 eosinophils or neutrophils. Size bar = 1 mm.
55
56
57
58
59
60

1
2
3
4
5
6
7
8
9
10
11
12
13
14
15
16
17
18
19
20
21
22
23
24
25
26
27
28
29
30
31
32
33
34
35
36
37
38
39
40
41
42
43
44
45
46
47
48
49
50
51
52
53
54
55
56
57
58
59
60

488
489
490
491
492
493

Figure 8. Questionnaire to Veterinary Surgeons about experience of donkeys with heart disease, and summary of responses.

Confidential: For Review Only

494 **References**

- 495 AMORY, H., BERTRAND, P., DELVAUX, V. & C., S. (2004) Doppler Echocardiographic Reference Values
496 in Healthy Donkeys. In *Veterinary Care of Donkeys*. Eds N. S. MATTHEWS, T. S. TAYLOR. Ithaca, New
497 York, USA, International Veterinary Information Service (www.ivis.org)
- 498 ASEFA, Z., KUMSA, B., ENDEBU, B., GIZACHEW, A., MERGA, T. & DEBELA, E. (2011) Endoparasites of
499 Donkeys in Sululta and Gefersa Districts of Central Oromia, Ethiopia. *Journal of Animal and*
500 *Veterinary Advances* **10**, 1850-1854
- 501 AYO, J. O., DZENDA, T. & ZAKARI, F. O. (2008) Individual and diurnal variations in rectal temperature,
502 respiration, and heart rate of pack donkeys during the early rainy season. *Journal of Equine*
503 *Veterinary Science* **28**, 281-288
- 504 BLISSITT, K. J. (2010) Auscultation. Chapter 8. In *Cardiology of the horse*. 2nd edition. Eds. Marr, C.M,
505 Bowen, M. Edinburgh, W.B Saunders pp 91 - 104
- 506 BLISSITT, K. J. & BONAGURA, J. D. (1995) Colour flow Doppler echocardiography in normal horses
507 *Equine Veterinary Journal* **27**, Supplement S19, 47-55
- 508 BU, Y. Z., NIU, H. X., GASSER, R. B., BEVERIDGE, I. & ZHANG, L. P. (2009) Strongyloid nematodes in
509 the caeca of donkeys in Henan Province, China. *Acta Parasitologica* **54**, 263-268
- 510 COLLINS, S. P., ARAND, P., LINDSELL, C. J., PEACOCK, W. F. T. & STORROW, A. B. (2005) Prevalence of
511 the third and fourth heart sound in asymptomatic adults. *Congestive Heart Failure* **11**, 242-247
- 512 CRANLEY, J. J. & MCCULLAGH, K. G. (1981) Ischaemic myocardial fibrosis and aortic strongylosis in
513 the horse. *Equine Veterinary Journal* **13**, 35-42
- 514 DELVAUX, V., KIRSCHVINK, N., AMORY, H., BUSONI, V., ART, T. & LEKEUX, P. (2001) Spécificités de la
515 fonction cardiorespiratoire de l'âne (*Equus asinus*). *Pratique Veterinaire Equine* **33**, 21-28

- 1
2
3 516 DUNCAN, J. L. & PIRIE, H. M. (1975) The pathogenesis of single experimental infections with
4
5 517 *Strongylus vulgaris* in foals. *Research in Veterinary Science* **18**, 82-93
6
7
8 518 DYSON, D. A. (1975) Cardiac Myopathy in a Donkey Foal. *Veterinary Record* **97**, 295-296
9
10
11 519 ELSE, R. W. & HOLMES, J. R. (1972a) Cardiac pathology in the horse. 1. Gross pathology. *Equine*
12
13 520 *Veterinary Journal* **4**, 1-8
14
15
16 521 ELSE, R. W. & HOLMES, J. R. (1972b) Cardiac pathology in the horse. 2. Microscopic pathology.
17
18 522 *Equine Veterinary Journal* **4**, 57-62
19
20
21 523 FOLCH, P., JORDANA, J. & CUENCA, R. (1997) Reference ranges and the influence of age and sex on
22
23 524 haematological values of the endangered Catalanian donkey. *The Veterinary Journal* **154**, 163-168
24
25
26 525 HALL, T. L., MAGDESIAN, K. G. & KITTLESON, M. D. (2010) Congenital cardiac defects in neonatal
27
28 526 foals: 18 cases (1992-2007). *Journal of Veterinary Internal Medicine* **24**, 206-212
29
30
31 527 HASSAN, E. A. & TORAD, F. A. (2015) Two-Dimensional and M-Mode Echocardiographic
32
33 528 Measurements in the Healthy Donkey (*Equus asinus*). *Journal of Equine Veterinary Science* **35**, 283-
34
35 529 289
36
37
38
39 530 IRELAND, J. L., CLEGG, P. D., MCGOWAN, C. M., MCKANE, S. A., CHANDLER, K. J. & PINCHBECK, G. L.
40
41 531 (2012) Disease prevalence in geriatric horses in the United Kingdom: veterinary clinical assessment
42
43 532 of 200 cases. *Equine Veterinary Journal* **44**, 101-106
44
45
46 533 KRIZ, N. G., HODGSON, D. R. & ROSE, R. J. (2000) Prevalence and clinical importance of heart
47
48 534 murmurs in racehorses. *Journal of the American Veterinary Medical Association* **216**, 1441-1445
49
50
51 535 LEWIS, J. F. & MARON, B. J. (1992) Cardiovascular consequences of the aging process.
52
53 536 *Cardiovascular Clinics* **22**, 25-34
54
55
56
57
58
59
60

- 1
2
3 537 MALOIY, G. M. O., RUGANGAZI, B. M. & ROWE, M. F. (2003) Heart rate and energy expenditure at
4
5 538 rest and exercise in the domestic donkey and one humped camel. *Integrative and Comparative*
6
7 539 *Biology* **43**, 1042-1042
8
9
10 540 MARR, C. M. (1999) Cardiac murmurs: congenital heart disease. Chapter 13. In *Cardiology of the*
11
12 541 horse. Ed., Marr, C.M. London, W.B. Saunders pp 210-232
13
14
15 542 MARR, C. M. (2010a) Cardiac murmurs: Congenital heart disease. Chapter 15. In *Cardiology of the*
16
17 543 horse. 2nd edition. Eds. Marr, C.M, Bowen, M. Edinburgh, W.B. Saunders pp 193-205
18
19
20 544 MARR, C. M. (2010b) Cardiac murmurs: valvular regurgitation and insufficiency. Chapter 16. In
21
22 545 *Cardiology of the horse*. 2nd edition. Eds. Marr, C.M, Bowen, M. Edinburgh, W.B. Saunders pp 207-
23
24 546 216
25
26
27 547 MARR, C. M. & PATTESON, M. W. (2010) Echocardiography. Chapter 9. In *Cardiology of the horse*.
28
29 548 2nd edition. Eds. Marr, C.M, Bowen, M. Edinburgh, W.B.Saunders pp 105-126
30
31
32
33 549 MARR, C. M. & REEF, V. B. (1995) Physiological valvular regurgitation in clinically normal young
34
35 550 racehorses: prevalence and two-dimensional colour flow Doppler echocardiographic characteristics.
36
37 551 *Equine Veterinary Journal* **27**, Supplement S19, 56-62
38
39
40 552 MATTHEWS, J. B. & BURDEN, F. A. (2013) Common helminth infections of donkeys and their control
41
42 553 in temperate regions. *Equine Veterinary Education* **25**, 461-467
43
44
45 554 MATTHEWS, N. S., TAYLOR, T. S. & POTTER, G. D. (1998) Physiologic responses during an exhaustive
46
47 555 driving test in donkeys: effect of conditioning. *Applied Animal Behaviour Science* **59**, 31-38
48
49
50 556 MORROW, L. D., SMITH, K. C., PIERCY, R. J., DU TOIT, N., BURDEN, F. A., OLMOS, G., GREGORY, N. G.
51
52 557 & VERHEYEN, K. L. (2011) Retrospective analysis of post-mortem findings in 1,444 aged donkeys.
53
54 558 *Journal of Comparative Pathology* **144**, 145-156
55
56
57
58
59
60

- 1
2
3 559 MUELLER, P. J., JONES, M. T., RAWSON, R. E., VANSOEST, P. J. & HINTZ, H. F. (1994) Effect of
4
5 560 Increasing Work Rate on Metabolic Responses of the Donkey (*Equus asinus*). *Journal of Applied*
6
7 561 *Physiology* **77**, 1431-1438
8
9
10 562 PALANIVEL, K. M., KORANDI, A. V., DHANOTIYA, R. S., SURESH, R. V. & SELVASUBRAMANIAN, S.
11
12 563 (2008) Hamatological and biochemical values in donkey. *Indian Veterinary Journal* **85**, 97-98
13
14
15 564 PATTESON, M. W. & CRIPPS, P. J. (1993) A survey of cardiac auscultatory findings in horses. *Equine*
16
17 565 *Veterinary Journal* **25**, 409-415
18
19
20 566 PIBAROT, P., VRINS, A., SALMON, Y. & DIFRUSCIA, R. (1993) Implantation of a programmable
21
22 567 atrioventricular pacemaker in a donkey with complete atrioventricular-block and syncope. *Equine*
23
24 568 *Veterinary Journal* **25**, 248-251
25
26
27
28 569 REEF, V. B. (1995) Heart murmurs in horses: determining their significance with echocardiography.
29
30 570 *Equine Veterinary Journal* **27**, Supplement S19, 71-80
31
32
33 571 REEF, V. B., BONAGURA, J., BUHL, R., MCGURRIN, M. K. J., SCHWARZWALD, C. C., VAN LOON, G. &
34
35 572 YOUNG, L. E. (2014) Recommendations for management of equine athletes with cardiovascular
36
37 573 abnormalities. *Journal of Veterinary Internal Medicine* **28**, 749-761
38
39
40 574 SAGE, A. M. (2002) Cardiac disease in the geriatric horse. *Veterinary Clinics of North America Equine*
41
42 575 *Practice* **18**, 575-589
43
44
45 576 SENIOR, J. M. (2013) Not small horses: improving treatments for donkeys. *Veterinary Record* **173**,
46
47 577 292-293
48
49
50 578 STANISIC, L., DIMITRIJEVIC, V., SIMEUNOVIC, P., LAKIC, N., RADOVIC, I., IVANKOVIC, A., STEVANOVIC,
51
52 579 J. & STANIMIROVIC, Z. (2015) Morphological, Biochemical and Hematological Characterization of
53
54 580 Endangered Balkan Donkey Breed. *Acta Veterinaria Beograd* **65**, 125-136
55
56
57
58
59
60

- 1
2
3 581 STARKEY, P. & STARKEY, M. (1996) Regional and world trends in donkey populations. In: Donkeys,
4
5 582 people and development. A resource book of the Animal Traction Network for Eastern and Southern
6
7 583 Africa (ATNESA). Eds. Starkey, P. & Fielding D. Wageningen, The Netherlands., ACP-EU Technical
8
9 584 Centre for Agricultural and Rural Cooperation (CTA) p 244
10
11
12 585 SVENDSEN, E. D. (2008) The professional handbook of the donkey. 4th edition. London, Whittlet
13
14 586 books
15
16
17 587 THIEMANN, A. K. (2012) Respiratory disease in the donkey. *Equine Veterinary Education* **24**, 469-478
18
19
20 588 TOLLIVER, S. C., LYONS, E. T. & DRUDGE, J. H. (1985) Species of small Strongyles and other internal
21
22 589 parasites recovered from Donkeys at necropsy in Kentucky. *Proceedings of the Helminthological*
23
24 590 *Society of Washington* **52**, 260- 265
25
26
27 591 USLU, U. & GUCLU, F. (2007) Prevalence of endoparasites in horses and donkeys in Turkey. *Bulletin*
28
29 592 *of the Veterinary Institute in Pulawy* **51**, 237-240
30
31
32 593 WELLS, D., KRECEK, R. C., WELLS, M., GUTHRIE, A. J. & LOURENS, J. C. (1998) Helminth levels of
33
34 594 working donkeys kept under different management systems in the Moretele 1 district of the North-
35
36 595 West Province, South Africa. *Veterinary Parasitology* **77**, 163-177
37
38
39
40
41
42
43
44
45
46
47
48
49
50
51
52
53
54
55
56
57
58
59
60

1
2
3
4
5
6
7
8
9
10
11
12
13
14
15
16
17
18
19
20
21
22
23
24
25
26
27
28
29
30
31
32
33
34
35
36
37
38
39
40
41
42
43
44
45
46
47
48
49
50
51
52
53
54
55
56
57
58
59
60

Weight distribution: geldings and females

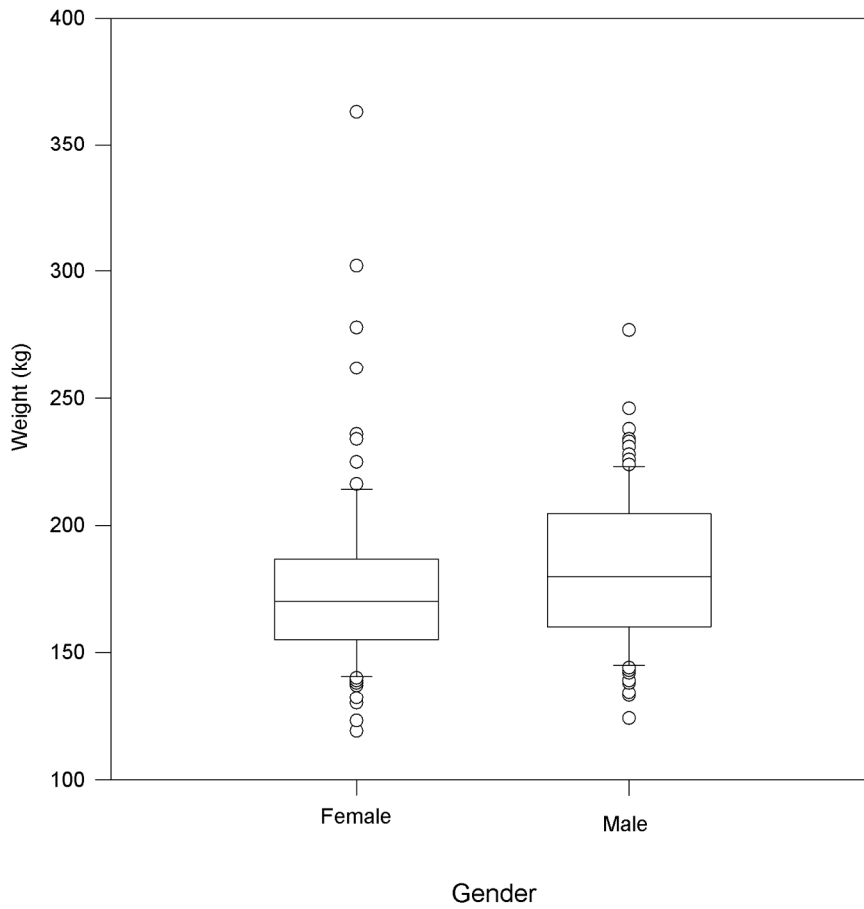


Figure 1: Weight distribution between females and geldings
Box and Whisker plots, with box defining the 25th and 75th percentile (median line included), and whiskers indicating the 10th and 90th percentiles; outlying data points shown. (P=0.014)

155x199mm (300 x 300 DPI)



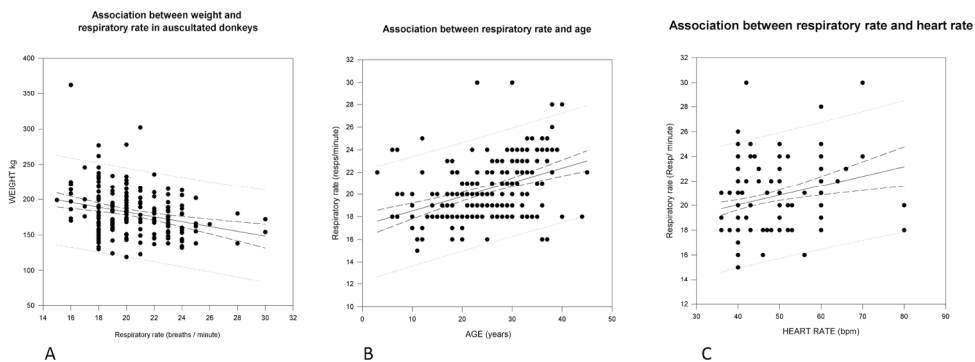


Figure 2. Associations with respiratory rate, by linear regression analyses. For all graphs, the regression line is shown, with 95% confidence intervals for the line, and 95% prediction intervals for the data. For R^2 and P values, see Table 2. 2A. Association between respiratory rate and body weight. 2B. Association between respiratory rate and age. 2C. Association between respiratory rate and heart rate.

530x202mm (300 x 300 DPI)

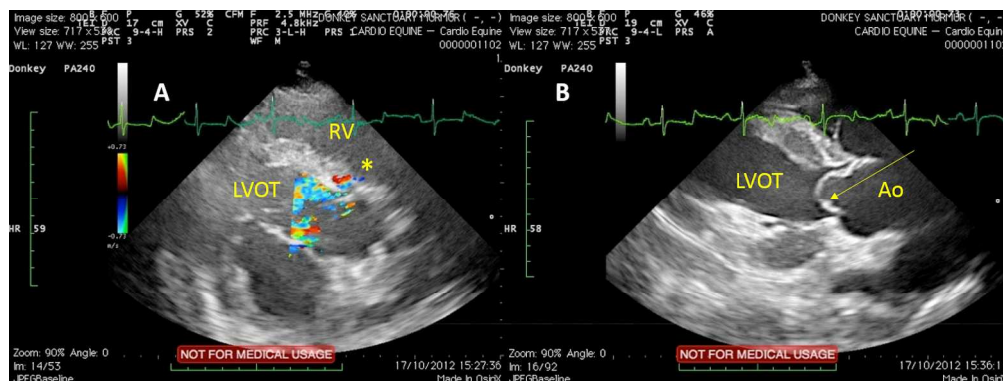


Figure 3: Ventricular Septal Defect (VSD) in a donkey gelding (10 years old):

- A. Right parasternal long axis view including left ventricular outflow tract (LVOT) during systole, optimised to show flow through the VSD by colour flow Doppler echocardiography. The * shows turbulent flow cross the interventricular septum into the right ventricle (RV).
- B. Right parasternal view including aorta; early diastolic frame showing prolapse of the right coronary cusp of the aortic valve (yellow arrow). The cusp prolapses into the left ventricular outflow tract (LVOT) beyond the annulus hinge-point. Ao: proximal aorta.

532x200mm (300 x 300 DPI)

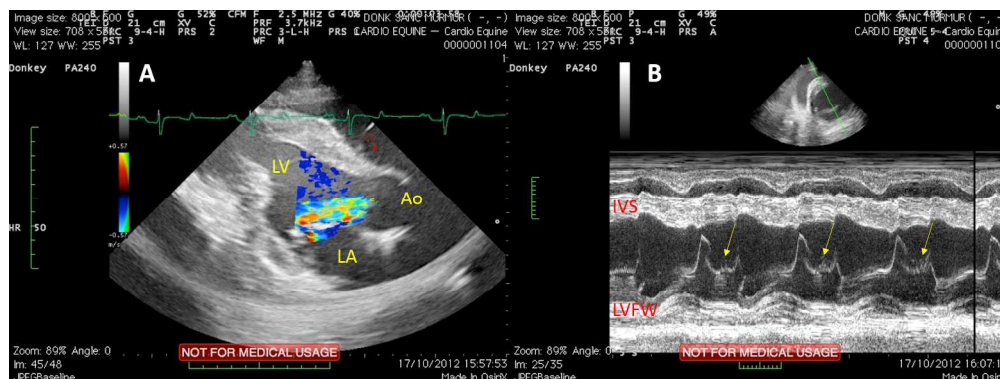


Figure 4. Echo images from a 35 year old donkey gelding with severe aortic regurgitation with grade 5/6 diastolic murmur.

A. Right parasternal long axis view including the left ventricular outflow tract, with colour flow echocardiography during diastole showing the eccentric jet of aortic regurgitation. LV: left ventricle, Ao: proximal aorta, LA: left atrium. The aortic regurgitation affects the anterior mitral valve leaflet.
 B. M-mode echocardiogram at mitral valve level of the same donkey with aortic regurgitation as in A; this shows diastolic flutter (yellow arrows) of open anterior leaflet of the mitral valve, between the E and A peaks, as a consequence of aortic regurgitation. IVS: interventricular septum. LVFW: left ventricular free-wall.

532x199mm (300 x 300 DPI)

For Review Only

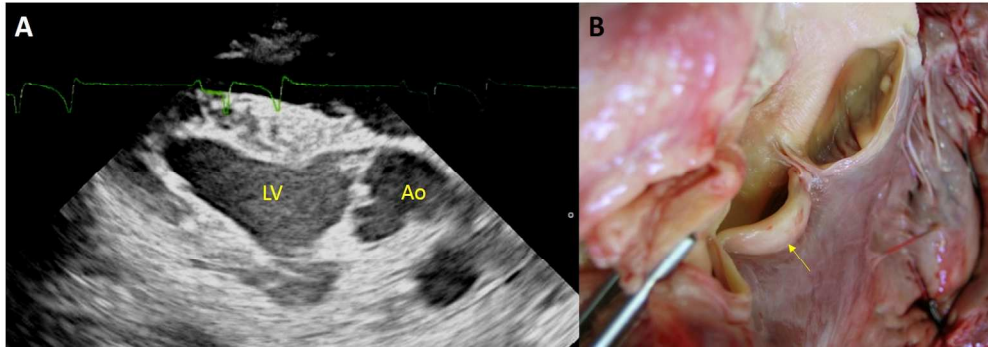


Figure 5. Aortic valvular lesions

A. Right parasternal long axis echocardiographic image from a 35 year old gelding, optimised to illustrate nodular thickening of the aortic valve, which was associated with aortic regurgitation. LV: left ventricle, Ao: proximal aorta.

B. Gross pathology image from the same donkey (euthanased for quality of life reasons, associated with dental disease and chronic laminitis). One of the aortic valves cusps is thickened (yellow arrow), and was associated with moderate aortic insufficiency. A small nodular lesion can also be seen on the sinus aspect of another (non-thickened) cusp.

574x200mm (300 x 300 DPI)

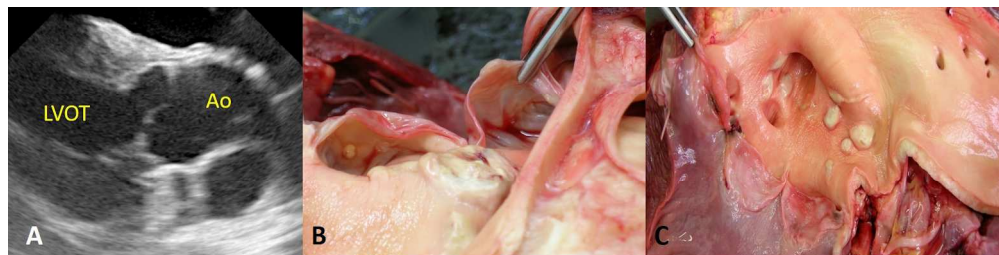

Figure 6. Proximal aortic intimal nodular lesions. !! †

A. Right parasternal long axis echocardiographic image from a 40 year old gelding showing no apparent major aortic valve pathology, and there was no aortic regurgitation. !! †
B, C. Gross pathology of the sinus aspect of the aortic valves (B) and proximal aorta (C) and from the same 40 year old echo-normal gelding, showing nodular lesions. The thickened region of tip of the cusp close to the forceps (C) is a normal anatomical finding, the nodes of the semilunar cusps, at the point of apposition of the three cusps. The pathological nodules are deep within the sinus of Valsalva. !! †

806x209mm (300 x 300 DPI)

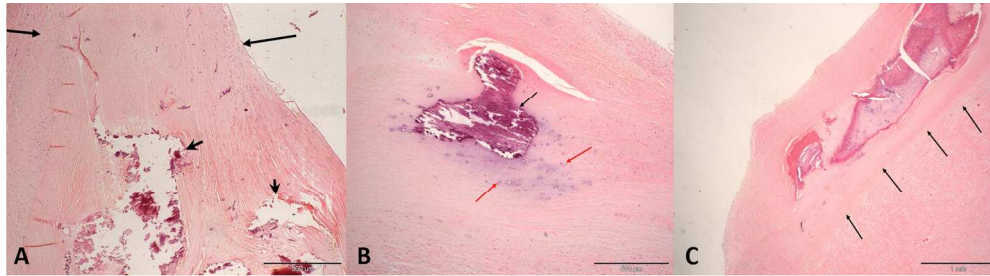


Figure 7. Histopathology of nodular lesions as in Figure 6B, 6C. Histopathology images courtesy of and with full permissions of Michael Rozmanec; Cytopath Ltd. !! + A. H and E stained, paraffin embedded section of artery. Large arrows indicate the expanded lamina intima of the vessel wall. Small arrows indicate degenerate mineralised foci. Size bar = 500 μ m. !! + B. H and E stained, paraffin embedded section of artery. Black arrow indicates focus of vascular intima mineralisation. Red arrows indicate adjacent fibrocartilaginous / chondroid metaplasia. Size bar = 500 μ m. !! + C. H and E stained, paraffin embedded section of artery. Black arrows indicate the junction between lamina intima and media of the blood vessel. The degenerate foci contain amorphous to granular eosinophilic coagulum – possible degenerate eosinophils or neutrophils. Size bar = 1 mm. !! +

709x200mm (300 x 300 DPI)

1
2
3
4
5
6
7
8
9
10
11
12
13
14
15
16
17
18
19
20
21
22
23
24
25
26
27
28
29
30
31
32
33
34
35
36
37
38
39
40
41
42
43
44
45
46
47
48
49
50
51
52
53
54
55
56
57
58
59
60

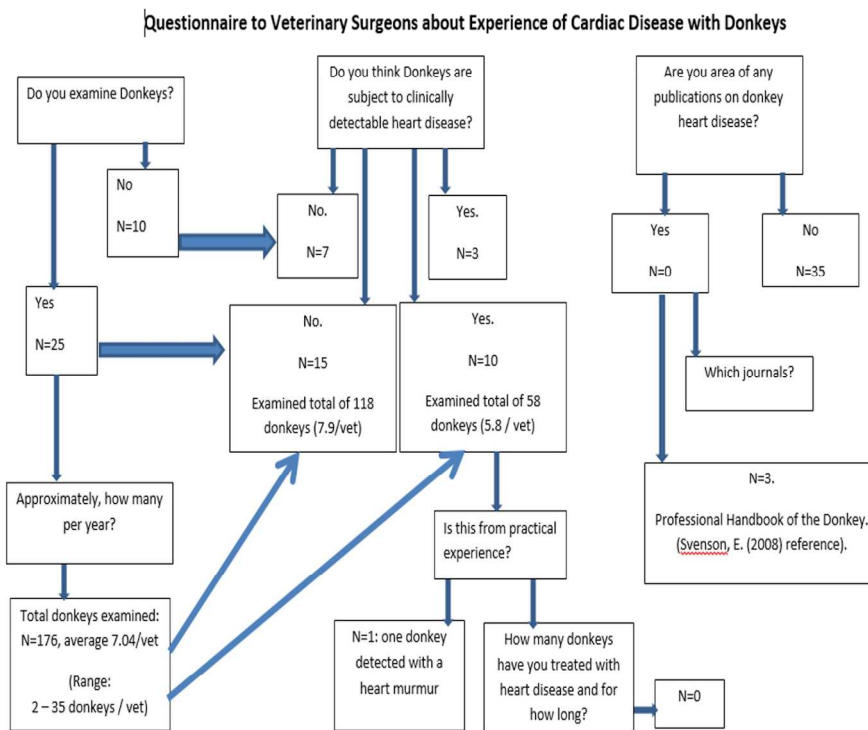


Figure 8. Questionnaire to Veterinary Surgeons about experience of donkeys with heart disease, and summary of responses.

250x199mm (300 x 300 DPI)

Review Only