

VERTIGO, NAUSEA, TINNITUS AND HYPOACUSIA DUE TO CENTRAL DISEQUILIBRIUM

VISUAL MECHANISMS IN BALANCE CONTROL

Proceedings of the XIXth Scientific Meeting of the
Neurootological and Equilibrimetric Society (NES)
Bad Kissingen - Germany, 27-29 March, 1992

Volume XX

Editors:

Claus-Frenz Claussen
Bad Kissingen, Germany

Milind V. Kirtane
Bombay, India

Dieter Schneider
Würzburg, Germany

medizin + pharmacie dr. werner rudat & Co Nachf.
edition m + p · Hamburg 1994

A STUDY OF CENTRAL COCHLEOVESTIBULAR FUNCTION IN AMAUROTIC CHILDREN

KISS, J.G., JANÁKY, M.*, LÁSZLÓ, A., SZABADOS, É., CZIGNER, J.**

DEPARTMENTS OF OTORHINOLARYNGOLOGY, OPHTHALMOLOGY* AND PEDIATRICS**

SZEGED, HUNGARY

Key words: BAEP, central hypoxic optic lesion, optic nerve atrophy, retinal degeneration, Usher's syndrome

Summary

19 amaurotic infants and children were investigated using the acoustic evoked potentials (BAEP) method. Distribution of the patients was:

1. Central hypoxic optic lesion's group (n=6),
2. Optic nerve atrophy (n=4),
3. Retinal degenerations (n=5),
4. Usher's syndrom (n=4).

1. In the central hypoxic optic lesion's group, there were 4 cases with normal responses, 1 case with an unilateral retrocochlear lesion and another with a bilateral cochlear lesion.

2. Among the children with optic nerve atrophy, 2 showed normal BAEP values, 1 had an unilateral retrocochlear and another a bilateral cochlear lesion.

3. In the group of retinal degenerations there were three families having genetic ground, 2 of them were X-linked recessive heredity, 4 cases had normal values, and 1 case proved to have a unilateral retrocochlear higher brainstem lesion.

4. All 4 cases with Usher's syndrom showed uni- or bilateral cochlear lesions and 2 of them showed bilateral retrocochlear lesions too.

According to our results in several types of amaurosis the BAEP investigation have diagnostic values for a central (brainstem) affection.

Introduction

The previous BAEP investigations have been made in demyelination syndromes, multiple sclerosis, motor system diseases (1,7,8), acoustic neurinomas, brain tumors etc. (5).

Infants and children suffering from different types of amaurosis were investigated by BAEP according to that for the evaluation of differential diagnostic values.

Patients and methods

19 amaurotic infants and children were investigated by BAEP method. Distribution of the patients was:

1. Central hypoxic optic lesion's group (n=6),
2. Optic nerve atrophy (n=4),

3. Retinal degenerations (n=5),

4. Usher's syndrome (n=4).

Responses to 2 000 click presentations were sampled over a 10 ms time window. In the rate study, the clicks were presented at 13/s, with an intensity of 80 dB SPL. The responses were recorded differentially between the vertex and the electrode fixed to the mastoid process of the tested ear, with the contralateral mastoid process electrode serving as ground. The latencies of the waves (I,II,III and IV/V) and inter-peak latencies (IPL I-III, III-IV/V, I-IV/V) were detected and automatically analysed by computer (3,4).

The otoneurologic investigation consisted of registration of spontaneous vestibular symptoms, foveal optokinetic nystagmus and caloric vestibular reaction according to Cawthorne-Fitzgerald-Hallpike method. The nystagmus was recorded electronystagmographically.

Results

Clinical electrophysiological and neurological data, interpeak latencies and BAEP curves are summarised in Table I., fig. 1a-b. and fig. 2 a-b-c-d.

The fig. 1a represents BAEP peak absolute latencies in ms with SD, in the 4 investigated groups. It can be seen that on the 1st group: 6 cases, 12 ears - 9 ears had a normal BAEP pattern and two cases - one person both ears and another child one side - BAEP waves were abnormal.

In the 2nd group (optic nerve lesion) we found 3 ears with abnormal BAEP pattern.

In the 3rd group we found only one ear with a delayed BAEP absolute latency.

In the last group all four patients had on both sides pathological evoked potentials (fig. 2a, b, c, d).

Fig. 1b represents a normal value of the inter-peak latencies (IPL) in msec of all 4 groups. In the 1st group (central optical hypoxic lesion) we found one case with one side delayed IPL III-IV/V and IPL I-IV/V indicating a retrocochlear lesion. In the 2nd group (Optic nerve lesion) also one was affected on one side from delayed IPL I-III and IPL I-IV/V, related to a retrocochlear lesion too: against to the previous case, the retrocochlear lesion proved to be a lower brainstem region (at the level of olivary superior). In the next group (retinal degeneration) we found one case and one side with a similar BAEP pattern to the previous case, it means a similar retrocochlear lesion (the I-III and the I-IV/V IPL were delayed). In the last group (Usher's syndrome) two cases had on both sides a pathological BAEP pattern in all IPL-s, indicating a more serious brainstem affection.

Table 1.**CLINICAL, ELECTROPHYSIOLOGICAL AND NEUROLOGICAL DATA**

NAME	AGE	VEP	ERG	AUDIOGRAM	BERA	CT	NEUROL.ST
Group 1. Dg: Central hypoxic optic laesion (n=6)							
1.K.D. f	11y	ext.	ext.	-	u.l.RCh.l.d.	norm.	muscl.hypotonia visuomot incoord
2.Z.S. m	8y	norm.	-	norm.	norm.	-corp.call.agenessia	no organic laesion
3.L.B. m	8m	ext.	-	-	norm	norm.	nystagn.norm.brain scint.
4.T.S. f	11y	min.response	norm.	norm.	norm	norm.	no organic laesion
5.T.R. m	7m	-	-	-	b.l.Ch.	norm.	chondrodyspl.microceph.
6.B.K. f	10m	min.response	norm	-	norm	norm.	strabizmus, astasia-abasia
Group 2. Dg: Optic nerve atrophy (n=4)							
1.C.H. m	13y	ext.	norm.	-	b.l.Ch.	norm.	no organic laesion
2.M.M. f	14y	ext.	norm.	macul.deg.	norm	norm.	no organic laesion
3.S.P. f	13y	ext.	ext.	-	u.l.RCh.l.d.	norm.	no organic laesion
cong. Leber amaurosis					abnorm.III.,V. l.s.		
4.M.O. f	12y	min.response	ext.	norm.	norm.	norm.	no organic laesion
familial opt.atrophy							

m = male, f = female, ext. = extinguished, Ch. = cochlear, RCh. = retrocochlear, u.l. = unilateral, b.l. = bilateral, norm. = normal

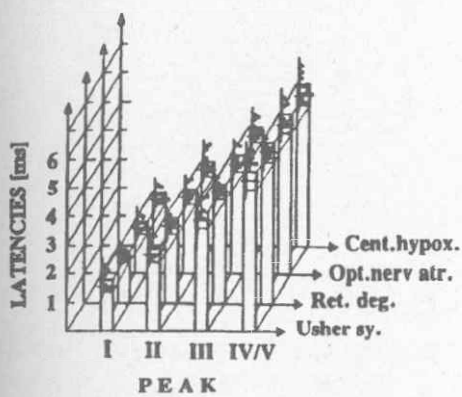
(See next page!)

Group 3. Dg: Retinal degeneration (n=5)

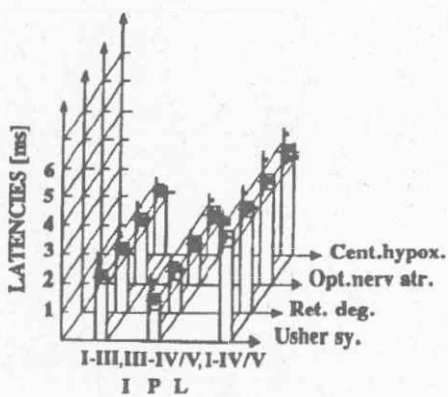
1.R.F. m 14y x-linked tapetoret deg.	subnorm.	norm.	norm.	norm.	norm.	horizontal nystagmus
2.J.K. m 12y Tapetoret. deg.aut.dom.	photopic scotopic ERG subnorm.	ext.	norm.	norm.	norm.	no organic laesion
3.S.K. f 10y Tapetoret. deg.aut.dom.	photop.ERG scotopic ERG subnorm.	ext.	norm.	norm.	norm.	no organic laesion
4.E.S. f 15y atypic ret. deg.familial	l.s.unregular l.d.ext	min.resp.	norm. l.d.ext.	u.l.Rch.l.s.	norm.	no organic laesion
5.K.M. f 14y x-linked tapetoret.deg.	norm.	norm.	norm.	norm.	norm.	17 D myop.cong.nyst.

Group 4. Dg: Usher sy.(n=4)

1.L.R. m 5y	l.s.ext. l.d.min.resp	ext.	-	b.l.Ch.	-	cong. defn. deg.pigm.retinae (DPR)
2.S.R. 4m	l.s.ext. l.d.min.resp	ext.	-	u.l.Ch.l.s.	CT.:cortic.atrophy.	n.optic atrophy DPR deafn. mutism
3.A.P. f 11y	ext.	-	-	u.l.Ch.l.d. b.l.RCh.	-	dysbasia, ataxia, ment.retard. IQ.: <30, mutism, EEG low ampl., DPR
4.Z.P. m 3y	ext.	-	-	b.l.Ch. b.l.RCh.	-	cong. deafn. ment.retard., mutism, DPR
						psychomot.ret. EEG: theta-delta act. beta superpos.rot.nyst.



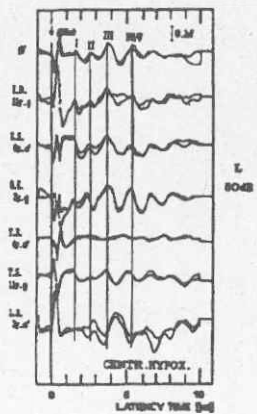
a.



b.

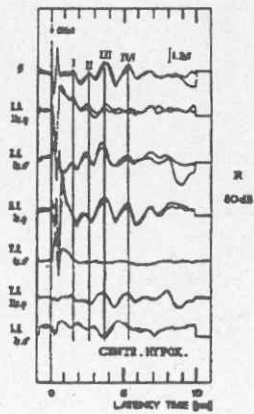
Fig. 1

Fig. 2

L
SO4B

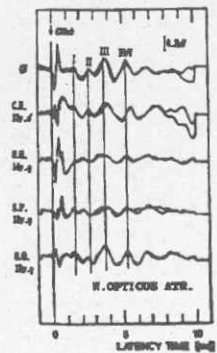
CENTR. HYPOX.

LATENCY TIME [ms]

R
SO4B

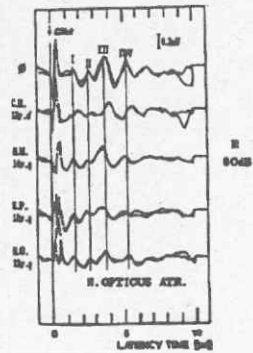
CENTR. HYPOX.

LATENCY TIME [ms]

L
SO4B

N. OPTICUS ATR.

LATENCY TIME [ms]

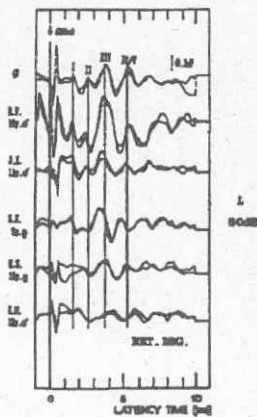
R
SO4B

N. OPTICUS ATR.

LATENCY TIME [ms]

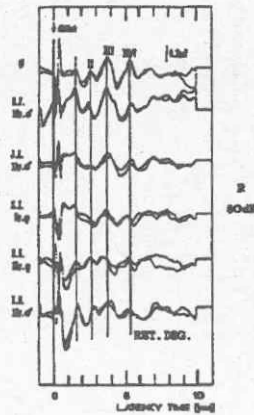
a.

b.

L
SO4B

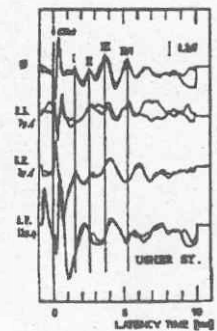
NXT. HDG.

LATENCY TIME [ms]

R
SO4B

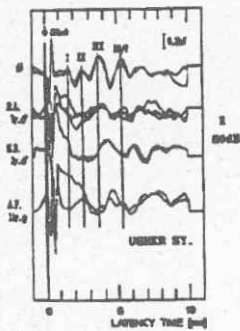
NXT. HDG.

LATENCY TIME [ms]

L
SO4B

UNDER ST.

LATENCY TIME [ms]

R
SO4B

UNDER ST.

LATENCY TIME [ms]

c.

d.

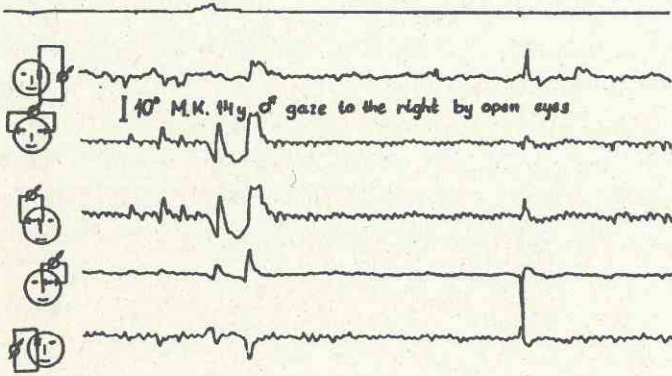


Fig. 3 a

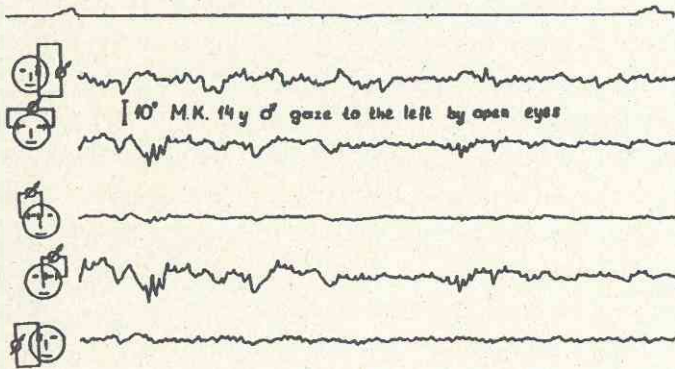


Fig. 3 b

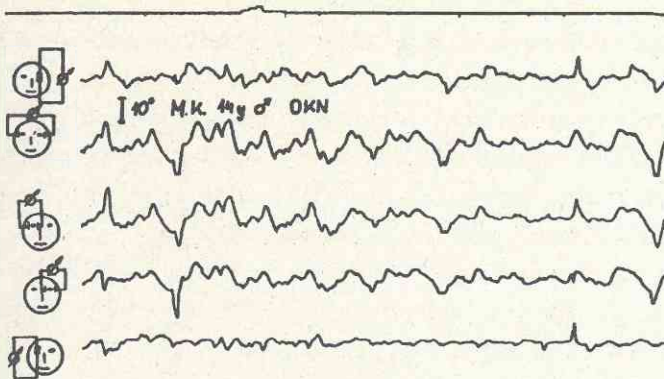


Fig. 4

Discussion

Ist group. (Central hypoxic optic atrophy): Pathological VEP, normal ERG except K.D. (No=1) where both of VEP and ERG were extinguished (Table 1. and fig 2.a). The pathological VEP means cortical damage of the visual cortical region, and the normal ERG means the visual pathway were intact. Guimard et al. (2) have investigated auditory brainstem responses (BAEP) and ultrasound changes in a high-risk infants population. BAEP abnormalities were found in 40% of the patients. The more extensive the cerebral hypoxic-ischaemic lesions were, the more severe the BAEP abnormalities were. The latter were of audiological type in 14%, neurological abnormalities were rare (6%). They concluded, that ABR represents the method of first choice for the detection of hearing loss, in the Neonatal Unit, while it seemed to be of limited value in assessing the brainstem function. We have similar results. All members of this group were mature neonates, the perinatal hypoxic lesions were retrospectively detected during the pathomechanical investigation of the central optic atrophy.

Vestibulometry: In the group with central hypoxic optic lesion with open eyes a pendular eye movement was found in 1 and eye-oscillation also in 1 subject. The optokinetic reactions were irregular. The caloric vestibular investigations revealed unilateral hypaesthesia in 2 patients and a marked nystagmus preponderance in an other.

IInd group (N. optic atrophy): In early childhood the ERG pattern are normal, later (depending on the age) will be progressively damaged. VEP were generally extinguished. Two cases (No: 1&3 in Table 1 and fig 2b) proved to be Leber amaurosis: with pathological BAEP bilateral cochlear and unilateral cochlear laesion. Another two of them had another type of optic atrophy without any cochlear or retrocochlear disturbances. One of the last two cases showed positive familial anamnesis, the father of the 4th case suffered from DPR.

Leber's disease is a hereditary optic neuropathy linked to a mitochondrial DNA defect (9), with demyelination of the optic nerve. BAEP-s were anomalous in 64% of patients without hearing defects (6).

IIIrd group (Retinal degenerations, in: Table 1 and fig 2.c): Two types of these have been identified: central and mixed. For the differentiation of the above mentioned types photopic and scotopic ERG investigations are necessary. In the 1st and 5th cases x-linked tapetoretinal degeneration were detected, both of them were affected boys. When the degeneration is a photopic type the ERG is extinguished indicating the cones are affected, while in scotopic type, the ERG pattern is subnormal but not extinguished, according to the degeneration of the rodes. In case of No. 4 the retineal degeneration proved to be a mixed type, with the dominance of the scotopic lesion. The BAEP showed unilateral retrocochlear lesion.

The brother and sister of the family K. proved to have autosomal dominant tapetoretinal degeneration (father was amaurotic too) with the disfunction of the rods and cones.

All member of these group except No. 4 were audiologically intact.

Vesibulometry: In the retinal degeneration's group spontaneous nystagmus was recorded in 2 patients only whit open eyes. The nystagmus was predominant on the side of eye abduction (fig.

3a-b). During optokinetic stimulation the slow phases of the nystagmus were irregular. In 1 case pendular nystagmus non susceptible to optokinetic stimuli, was observed (fig. 4). The caloric reaction revealed unilateral vestibular hypoesthesia associated with nystagmus dysmetry in one patient, whereas the caloric response was totally missing in another.

IVth group (Usher's syndrome, in: Table 1 and fig. 2d): All of them had an autosomal recessively inherited degeneratio pigmentosa retinae with disacusis syndrome, manifested in the same family in a brother and a sister (first cousins). These patients had variable serious degeneration both of rods and cones with extinguished ERG patterns. VEP investigations gave only a minimal response or extinguished. In all cases of these group were detected cochlear hearing loss and the P. sister and brother had an accessoriously different degree of retrocochlear lesion.

According to our results in several types of amaurosis the BAEP investigation have diagnostic values for a central (brainstem) affection (Table 2).

Table 2. Amaurotic children (n=19)

Gr.	Bera examinations			
	Case	Norm	RCh.l.	Ch.l.
Centr.hypox.o.l.	6	4	1 u.l.	1 b.l.
Opt. nerve atr.	4	2	1 u.l.	1 b.l.
Ret. deg.	5	4	1 u.l.	-
Usher sy.	4	-	2 b.l.	2 u.l.+2 b.l.

RCh.l. = retrocochlear lesion
 Ch.l. = cochlear lesion
 u.l. = unilateral
 b.l. = bilateral

Among the amaurotic children in spite of the vestibular lesions a spontaneous vestibular nystagmus was not recorded. The ocular nystagmus caused various disorders in the optokinetic responses. The vestibular lesions proved to be of a central type. These were more marked in the cases of retinal degeneration, but further investigations have to be carried out.

References

1. Cascino, G.D., Ring, S.R., King, P.J.L., Brown, R.H., Chiapps, K.H.
 Evoked potentials in motor system diseases.
Neurology 38, 231-238 /1988.
2. Guinard, C., Fawer, C.L., Despland, P.A., Calme, A.
 Auditory brainstem responses and ultrasound changes in a high-risk infants population.
Helv.paediat. Acts. 43, 377-388 /1988.
3. Jewett, D.L., Romano, M.H., Williston, J.S.
 Human auditory evoked potentials: possible brain stem components detected on the scalp.
Science 167. 1517. /1970.

4. Kjaer M.

Evoked potentials. With special reference to its diagnostic value.

Acta Neurol. Scand. 61, 265. /1980.

5. Mauerer K., Rochel M., Lowitzsch K.

Early auditory evoked potentials: developmental aspects and validity in neuro-paediatric and audiological disorders.

Eur. J. Pediatr. 143, 13-17 /1984.

6. Mondelli M., Rossi A.

BAEP changes in Leber's hereditary optic atrophy: further confirmation of multisystem involvement.

Acta Neurol. Scand 81, 349-353 /1990.

7. Rossini P.M., Cracco J.B.

Somatosensory and brainstem auditory evoked potentials in neurodegenerative system disorders.

Eur. Neurol. 26, 176-188 /1987.

8. Tackmann W., Vogel, P.

Brainstem auditory evoked potentials evoked by clicks of different polarity in multiple sclerosis patients.

Eur. Neurol. 36, 193-198 /1987.

9. Wallace D.C., Singh G., Lott M.T., Hodge J.A., Schurr T.G., Lezza A.M.S., Elses L.J.,

Nikoskelainen, E.

Mitochondrial DNA mutation associated with Leber's hereditary optic atrophy.

Science 242, 1427-1430 /1988.